

# Paraneoplastic optic neuritis as the first manifestation of periampullary carcinoma

Rudrajit Paul, Asim K Ghosh<sup>1</sup>, Avirup Sinha, Raja Bhattacharya

Departments of Medicine and <sup>1</sup>Ophthalmology, Medical College Kolkata, Kolkata, West Bengal, India

## ABSTRACT

Paraneoplastic optic neuritis is a rare phenomenon that often presents as a diagnostic challenge. It has been mostly reported with small cell cancers or thymoma. Prompt treatment of the malignancy is the only effective therapy for the condition. Visual loss, once established usually becomes irreversible. We here report a case of paraneoplastic optic neuritis in a 40-year-old female with periampullary carcinoma. This is probably the first report of this association in the medical literature.

**Key words:** Ascites, optic neuritis, paraneoplastic, periampullary carcinoma visual loss

**Submission:** 19-01-2014 **Accepted:** 13-08-2014

## INTRODUCTION

Optic neuritis is a very rare paraneoplastic phenomenon.<sup>[1]</sup> It has been reported in association with malignancies such as small cell carcinoma and melanoma.<sup>[1,2]</sup> Paraneoplastic optic neuropathy (PON) presents with gradual visual loss, and the underlying disease is often missed for a long time. We here report a case of PON in association with periampullary carcinoma. This is probably the first report of this association in literature.

## CASE REPORT

A 40-year-old female housewife presented with sudden onset painless dimness of vision of left eye for 1-month. She had no redness of the eye and no restriction of ocular movement. However, on moving the eye there was mild retro-orbital pain. The left pupil was sluggishly reactive to light. The right eye was completely normal. Ophthalmoscopy of the left eye revealed

swelling of the optic disc [Figure 1]. This, along with other clinical features, was suggestive of optic neuritis. The patient was started on oral steroids and her visual dimness slightly improved. Magnetic resonance imaging of the brain did not reveal any other lesion. There was no mass in the cavernous sinus or the orbit. The patient had no nystagmus or proptosis.

Six weeks after this episode, the patient presented again with jaundice and generalized abdominal pain. Her visual dimness was still persisting. On examination, she was found to have ascites. She also complained of loss of weight and anorexia. Her stool was clay colored and urine was dark yellow in color. There was no history of gastrointestinal bleeding and no lymphadenopathy. On abdominal examination, liver was mildly enlarged and firm in consistency. Repeat direct ophthalmoscopy revealed persisting swelling of the optic disc.

Laboratory examinations revealed hemoglobin 12.1 g/dl, total leukocyte count 15,000/cmm (N90L8) and platelet count of 250,000/cmm. Blood sugar was 125 mg/dl (random) and urea/creatinine was 18 and 0.7 mg/dl respectively. Liver function test revealed total bilirubin of 8.5 mg/dl with direct fraction of 7.5 mg/dl; serum glutamic pyruvic transaminase 76 IU/L, serum glutamic oxaloacetic transaminase 69 IU/L; alkaline phosphatase 3117 IU/L ( $N < 306$ ); total protein: 6.3 g/dl and albumin 3.3 g/dl. Prothrombin time was 12 s (control: 11 s). Ultrasonography (USG) of the abdomen revealed dilated intrahepatic biliary radicles with ascites and right pleural effusion. No mass was seen in abdominal USG. Ascitic fluid study revealed a cell count of 1200/cmm with 35% lymphocytes and 60% mesothelial cells. Total protein was 4.3 g/dl with albumin of 2.5 g/dl (serum-ascites albumin

Address for correspondence: Dr. Rudrajit Paul,  
15/5, Bose Pukur Road, Kolkata - 700 039, West Bengal, India.  
E-mail: docr89@gmail.com

Access this article online	
Quick Response Code:	Website: www.ijabmr.org
	DOI: 10.4103/2229-516X.149255

gradient: 0.8 g/dl). Ascitic fluid for malignant cell study was negative. Ascitic fluid lactic dehydrogenase level was elevated at 1200 IU/L ( $N < 200$ ). The pleural fluid study also showed no malignant cells. While in the hospital, the patient developed hyponatremia (Na: 120 mEq/L) which was corrected with hypertonic saline. Among other tests, serum Vitamin B12 levels were normal, and hepatitis viral serologies were negative. Blood alpha-fetoprotein level was normal.

Cerebrospinal fluid (CSF) study revealed 30 cells/cmm with sugar 51 mg/dl and protein 128 mg/dl ( $N < 45$ ). No malignant cells were found in CSF also. Oligoclonal band (OCB) was absent. Anti-collapsin response mediator protein (CRMP) antibody test is not available in our city.

Contrast-enhanced computed tomography (CT) scan of the abdomen revealed a mass in periampullary region with dilated bile duct radicles in liver [Figure 2]. There were few peritoneal nodules and omental thickening. No liver invasion was seen. CT guided fine-needle aspiration cytology from the mass revealed markedly dysplastic cells with hyperchromatic nuclei. Mitotic index was high. Unfortunately, just after this diagnosis, before any treatment could be started, the patient expired.

Hence, the case was diagnosed as optic neuritis secondary to periampullary carcinoma. Optic neuritis was the first clinical presentation of this malignancy.

## DISCUSSION

Paraneoplastic optic neuropathy is a rare clinical syndrome. The exact etiology of this disease is unknown. However, it is thought that tumor associated antigens generate antibodies that cross-react with neuronal and glial proteins.<sup>[1]</sup> The antibodies found most commonly include CRMP-5 IgG. The antibody causes permanent loss of neuronal plasticity. This antibody has been found in patients with small cell lung carcinoma, thymoma, renal or thyroid malignancies.<sup>[3]</sup> Rarely, this antibody has also been detected in prostatic malignancy.<sup>[4]</sup> This antibody can give rise to not only optic neuritis but also a neuromyelitis optica like condition.<sup>[4]</sup> Ideally, anti-CRMP-5 antibody should be tested in a suspected case of PON. However, in our set up we could not do it due to logistic difficulties.

Paraneoplastic optic neuropathy is not limited to optic nerve inflammation only. The disease spectrum also includes retinitis and vitreous cellular reaction.<sup>[3]</sup> In our patient, there were few vitreous cells. The retinitis may not be clinically evident. However, electroretinography (ERG) is usually abnormal in these cases. In our patient too, ERG was markedly abnormal. The CSF picture was suggestive of an inflammatory condition. In PON, the CSF picture may resemble meningitis with

increased cells and protein.<sup>[3]</sup> Even OCBs may be found in many cases, although, in our patient, OCB was absent. CRMP-5 antibody may also be found in CSF.

Periampullary carcinoma is a large group of malignancies that usually includes adenocarcinoma and cholangiocarcinoma. Very rarely, small cell carcinoma has been reported in periampullary region along with paraneoplastic phenomena like SIADH.<sup>[5]</sup> Another rare paraneoplastic phenomenon reported with carcinoma in this site is reactive perforating collagenosis.<sup>[6]</sup> However, PON has never been reported till now.

Since PON is a rare entity, there is no consensus on treatment, and it is based only on few published case reports. In general, immunosuppressive therapy is not very effective, and prompt treatment of the underlying malignancy seems to be the only way to halt disease progression.<sup>[7]</sup> However, since there is an

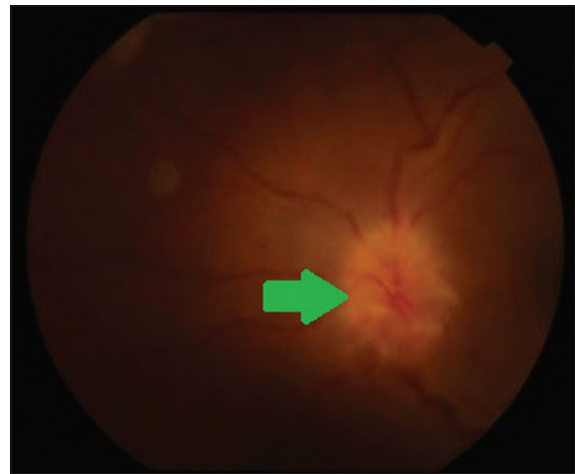

Figure 1: Fundus photography of left eye of the patient shows edematous disc with blurred margins (green arrow) and tortuous vessels, suggestive of optic neuritis

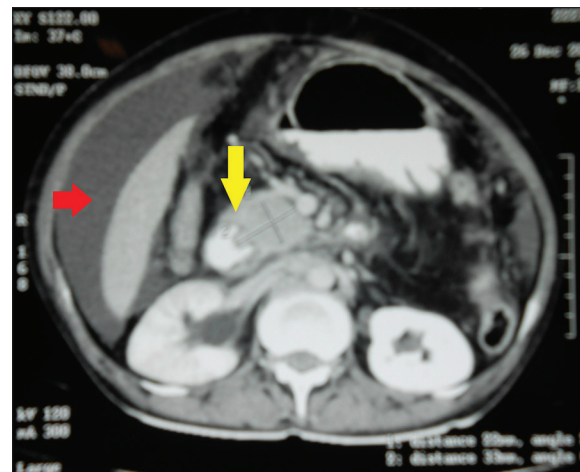


Figure 2: Contrast enhanced computed tomography of abdomen of the patient showing a periampullary mass (yellow arrow) with ascites (red arrow) and dilated intrahepatic biliary radicles

underlying autoimmune basis for PON, steroids and other drugs should probably be also used. Plasmapheresis has also been tried in some cases. The best course of action is a high index of suspicion to detect the underlying disease early because the optic nerve changes secondary to PON are largely irreversible.<sup>[8]</sup>

## CONCLUSION

Paraneoplastic optic neuropathy is a diagnostic possibility in elderly patients, especially when other common causes of optic neuropathy have been ruled out. Appropriate search for underlying malignancy is to be undertaken. Anti-CRMP-5 antibody is the ideal test, but it is often not available. Hence, other tests like CSF study or electroretinogram should be used in suspected cases.

## REFERENCES

1. Malik S, Furlan AJ, Sweeney PJ, Kosmorsky GS, Wong M. Optic neuropathy: A rare paraneoplastic syndrome. *J Clin Neuroophthalmol* 1992;12:137-41.
2. Schoenberger SD, Kim SJ, Lavin P. Paraneoplastic optic neuropathy from cutaneous melanoma detected by positron emission tomographic and computed tomographic scanning. *Arch Ophthalmol* 2012;130:1223-5.
3. Cross SA, Salomao DR, Parisi JE, Kryzer TJ, Bradley EA, Mines JA, *et al.* Paraneoplastic autoimmune optic neuritis with retinitis defined by CRMP-5-IgG. *Ann Neurol* 2003;54:38-50.
4. Jarius S, Wandinger KP, Borowski K, Stoecker W, Wildemann B. Antibodies to CV2/CRMP5 in neuromyelitis optica-like disease: Case report and review of the literature. *Clin Neurol Neurosurg* 2012;114:331-5.
5. Ghahreman A, Booth M, Cutfield R, Wright C. Small-cell carcinoma of the ampulla of Vater and a paraneoplastic syndrome. *N Z Med J* 2003;116:U686.
6. Chae KS, Park YM, Cho SH, Cho BK. Reactive perforating collagenosis associated with periampullary carcinoma. *Br J Dermatol* 1998;139:548-50.
7. Damek DM. Paraneoplastic Retinopathy/Optic Neuropathy. *Curr Treat Options Neurol* 2005;7:57-67.
8. Murakami Y, Yoshida S, Yoshikawa H, Yamaji Y, Ikeda Y, Ueno A, *et al.* CRMP-5-IgG in patient with paraneoplastic optic neuritis with lung adenocarcinoma. *Eye (Lond)* 2007;21:860-2.

**How to cite this article:** Paul R, Ghosh AK, Sinha A, Bhattacharya R. Paraneoplastic optic neuritis as the first manifestation of periampullary carcinoma. *Int J App Basic Med Res* 2015;5:73-5.

**Source of Support:** Nil. **Conflict of Interest:** None declared.