



Arthroscopic Resection of Osteochondroma of Hip Joint Associated with Internal Snapping: A Case Report

Heung-Tae Jung, MD, Deuk-Soo Hwang, MD*, Yoo-Sun Jeon, MD, Pil-Sung Kim, MD†

*Department of Orthopedic Surgery, Busan Bumin Hospital, Busan, Korea,
Department of Orthopedic Surgery, Chungnam National University School of Medicine, Daejeon, Korea*,
Department of Orthopedic Surgery, Seoul Bumin Hospital, Seoul, Korea†*

A 16-year old male patient visited the hospital complaining of inguinal pain and internal snapping of right hip joint. In physical examination, the patient was presumed to be diagnosed femoroacetabular impingement (FAI) and acetabular labral tear. In radiologic evaluation, FAI and acetabular labral tear were identified and bony tumor associated with internal snapping was found on the posteromedial portion of the femoral neck. Despite of conservative treatment, there was no symptomatic improvement. So arthroscopic labral repair, osteoplasty and resection of bony tumor were performed. The tumor was pathologically diagnosed as osteochondroma through biopsy and all symptoms improved after surgery. There was no recurrence, complication or abnormal finding during 1 year follow up. Osteochondroma located at posteromedial portion of femoral neck can be a cause of internal snapping hip and although technical demands are challenging, arthroscopic resection can be a good treatment option.

Key Words: Hip, Arthroscopy, Osteochondroma

Osteochondroma is a benign tumor usually discovered at knee, forearm, and ankle. But, osteochondroma of the proximal femur is relatively rare¹⁾. Clinical manifestations by osteochondroma of the hip joint include trochanteric bursitis, sciatic nerve compression²⁾, an external snapping

hip³⁾, femoroacetabular impingement (FAI)^{4,5)} or fracture at the stalk of the tumor^{1,6)}. Internal snapping is uncommon pathology of the hip joint; however, it may make the pain of the hip joint and disturbance of gait. As internal snapping hip is occurred by movement of iliopsoas tendon, the bony lesion caught in iliopsoas tendon can also make snapping phenomenon of the hip joint. For treatment of intraarticular osteochondroma of the hip joint, open resection of the hip was usually performed but the procedure may be somewhat invasive. So, arthroscopic resection for intraarticular bony lesion can be considered. However, if the bony tumor is located at far distal portion of peripheral compartment, arthroscopic resection may be very difficult. Also, there is no report about an osteochondroma related to internal snapping hip, yet. The authors report the case that underwent arthroscopic resection of osteochondroma related to internal snapping hip.

Submitted: July 19, 2014 1st revision: November 17, 2014
2nd revision: February 3, 2015 3rd revision: February 17, 2015
Final acceptance: February 23, 2015
Address reprint request to
Pil-Sung Kim, MD
Department of Orthopedic Surgery, Seoul Bumin Hospital, 389
Gonghang-daero, Gangseo-gu, Seoul 157-930, Korea
TEL: +82-2-2620-0008 FAX: +82-2-2620-0167
E-mail: mskps@naver.com

This is an Open Access article distributed under the terms of the Creative Commons Attribution Non-Commercial License (<http://creativecommons.org/licenses/by-nc/3.0>) which permits unrestricted non-commercial use, distribution, and reproduction in any medium, provided the original work is properly cited.

CASE REPORT

A 16-year old male patient visited the hospital complaining of pain of right hip joint starting from 2 years ago. The patient complained of inguinal pain and limping. Visual analogue scale (VAS) pain score was 8. In physical examination, anterior hip impingement test and Patrick test were positive. When the leg of the patient was rotated internally and extended distally, the snapping movement happened in his hip joint. Plain radiograph showed pincer type of FAI which has positive crossover sign of the acetabulum. On the frog leg lateral view, a bony protuberance was found at posteromedial portion of the femoral neck (Fig. 1). Computed tomography (CT) images showed cranially retroverted acetabulum and a bony tumor which located

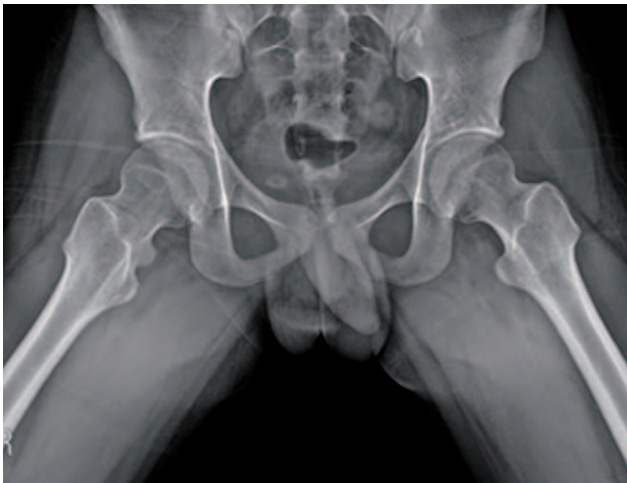

Fig. 1. Frog-leg lateral view. The bony lesion was found at posteromedial portion of right femoral neck.

just above the lesser trochanter with a size of 1.7 cm by 0.6 cm (Fig. 2). On magnetic resonance arthrography images, labral tear at the anterosuperior portion of acetabulum and a bony tumor with cartilaginous cap at posteromedial area of femoral neck were demonstrated (Fig. 3). We observed snapping motion between iliopsoas tendon and bony tumor at peripheral compartment in ultrasonographic examination. Since the pain did not subside even after conservative treatment using non-steroid anti-inflammatory drugs and physical therapy for 6 weeks, arthroscopic management for FAI with labral tear and bony tumor was performed.

We put the patient under general anesthesia and took a supine position on the fracture table for traction of the hip joint. We treated problems of central compartment first, and the procedure for peripheral compartment was executed later. Anterolateral and anterior portal were established in ordinary manner. In whole procedure, 70° arthroscope was used only. After making two portals, we made transverse capsulotomy connecting anterior to anterolateral portal using arthroscopic knife. For visualization of bony tumor, transverse capsulotomy was more extended medially rather than usual capsulotomy. In arthroscopic findings, labral displaced tear was found at anterosuperior aspect of the acetabulum. Acetabuloplasty was performed using a 4.5 mm arthroscopic spherical burr (Conmed Linvatec, Largo, FL, USA) and acetabular labral repair using two 2.7 mm absorbable suture anchor (Bioraptor; Smith & Nephew, Andover, MA, USA) was performed at anterior and anterolateral portion of the acetabulum (Fig. 4). After the procedure of central compartment, the patient's hip was flexed to 60° and arthroscope was

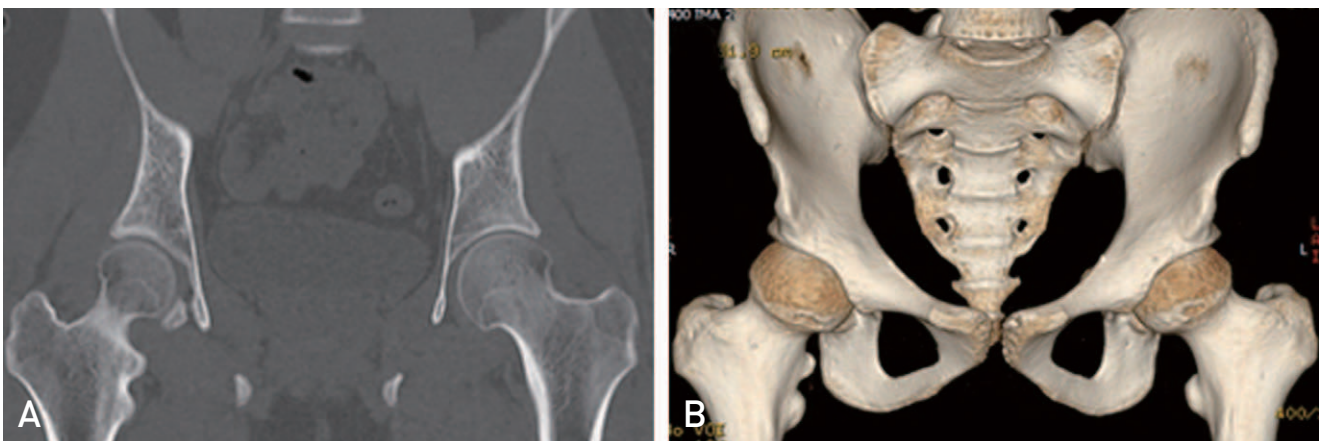


Fig. 2. (A) Preoperative computed tomography (CT). Bony protuberance was located just above lesser trochanter. (B) Preoperative CT. Bony protuberance was located just above lesser trochanter.

moved toward peripheral compartment, and additional capsulotomy using the hook type radiofrequency (Arthrocare; Arthrocare Corporation, Austin, TX, USA) was performed distally for easier access of arthroscopic instruments to peripheral compartment. After femoroplasty for decompression of FAI, we rotated the patient's leg externally and made his posture a frog leg position for arthroscopic visualization of medial portion where bony tumor was existent (Fig. 5). For resection of the tumor, we used anterior and anterolateral portal as working portal and viewing portal, respectively. We extracted bony specimens which contained cartilaginous cap and bony tissue for biopsy and remnant bony protuberance was removed completely using arthroscopic spherical burr. To prevent femoral neck fracture that might occur after tumor resection, whole

procedure was performed under the guidance of the fluoroscopic image intensifier. Because of widened capsulotomy, arthroscopic capsular repair using 2-0 Ethibond (Ethicon, Somerville, NJ, USA) was performed for stabilization of the hip joint. Postoperative rehabilitation included continuous passive motion and pendulum exercise of the hip joint from postoperative 1 day and the patient was permitted non-weight bearing for 6 weeks after surgery.

Complete resection of osteochondroma was confirmed using postoperative X-ray and CT images (Fig. 6) and osteochondroma was pathologically confirmed (Fig. 7). The VAS pain score was decreased from 8 preoperatively to 1 postoperatively and the inguinal pain and internal snapping were disappeared completely at postoperative 3 month. At last follow up, modified Harris hip score was improved from 52 preoperatively to 90 postoperatively and hip outcome score of activity of daily living and sport related activity were improved from 58 and 56 preoperatively to 91 and 90 postoperatively, each. The plain radiography and physical examination at postoperative 1 year showed no recurrence of osteochondroma and internal snapping hip (Fig. 8).

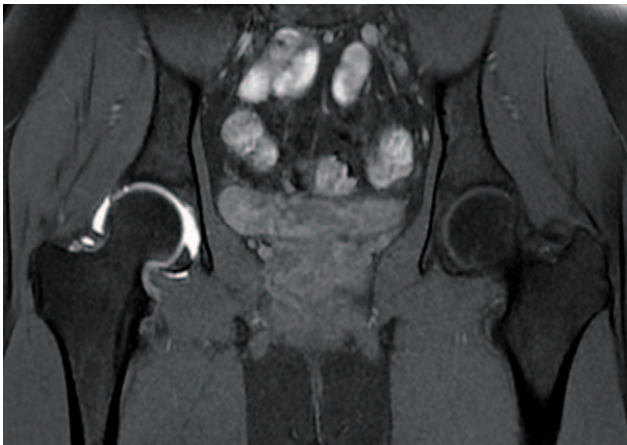

Fig. 3. Intraarticular bony lesion was suggestive of osteochondroma with cartilaginous cap in magnetic resonance arthrography image.

DISCUSSION

After FAI and acetabular labral tear have gained attention as a cause of hip pain, arthroscopic treatment for lesions of the hip joint has improved remarkably ever since. Whereas arthroscopic treatment for the hip lesions mainly focused on resolution for problems of the central compartment in the past, the operative indications are extended to pathologies of the peripheral compartment

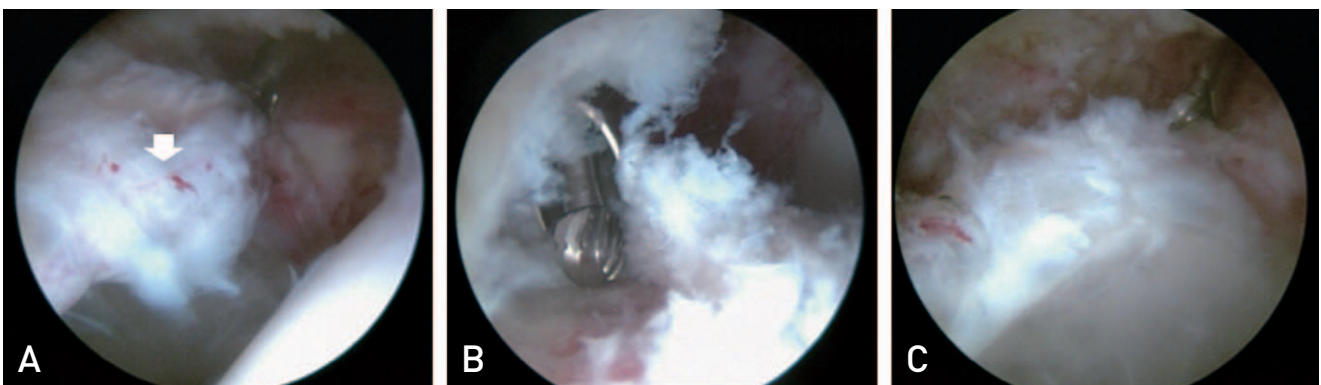


Fig. 4. (A) Arthroscopic finding of acetabular labral tear [arrow] at anterosuperior portion of acetabulum. Anterolateral and anterior portal were used as viewing and working portal, each. (B) Acetabuloplasty using arthroscopic spherical burr (Linvatec, Largo, FL, USA) for correction of pincer femoroacetabular impingement. (C) Acetabular labral repair with two bioabsorbable suture anchors (Bioraptor; Smith & Nephew, Andover, MA, USA).

such as cam type FAI, synovial osteochondromatosis, loose bodies, internal snapping hip, etc⁷⁾. Recently, arthroscopic treatment for extraarticular hip lesions such as gluteus tendon tear, greater trochanteric pain syndrome, piriformis syndrome, external snapping hip, etc is being attempted. Although some cases about osteochondroma in the hip joint involved FAI and acetabular labral tear were reported^{4,5)}, there is not any report about that which occurred internal snapping hip. As the location of tumor was the posteromedial area of the femoral neck, that is superior portion to lesser

trochanter, arthroscopic approach for resection of osteochondroma is difficult more than other cases⁸⁾. The main problems of this case were acetabular labral tear and internal snapping hip. For treatment of pathologies of central compartment such as acetabular labral tear and pincer type FAI, we performed arthroscopic acetabuloplasty and labral repair with two bioabsorbable suture anchors (Bioraptor). Arthroscopic treatment for internal snapping hip by iliopsoas tendinopathy is usually performed around femoral head-neck junction. But, because snapping phenomenon of this case was occurred by bony tumor, resection of osteochondroma was needed for resolution of this pathology. Authors usually used ordinary anterior and anterolateral portal, but as classic transverse capsulotomy is not enough to secure the space for resection of tumor in the peripheral compartment, T-shaped capsulotomy forward peripheral compartment was performed for widening of operative field. Lee et al.⁹⁾ have reported the results of arthroscopic treatment by medial approach using medial portal and the site of medial portal is close to the passing route of obturator nerve and artery. So, risk of neurovascular injury can be not excluded, completely. In this reason, arthroscopic resection of bony tumor of far distal portion of peripheral compartment through widened T-shaped capsulotomy was attempt and we obtained successful result.

Complications of arthroscopic treatment of the hip joint include neurovascular injury and avascular necrosis of femoral head by long traction time, femoral neck fracture or hip joint instability after excessive

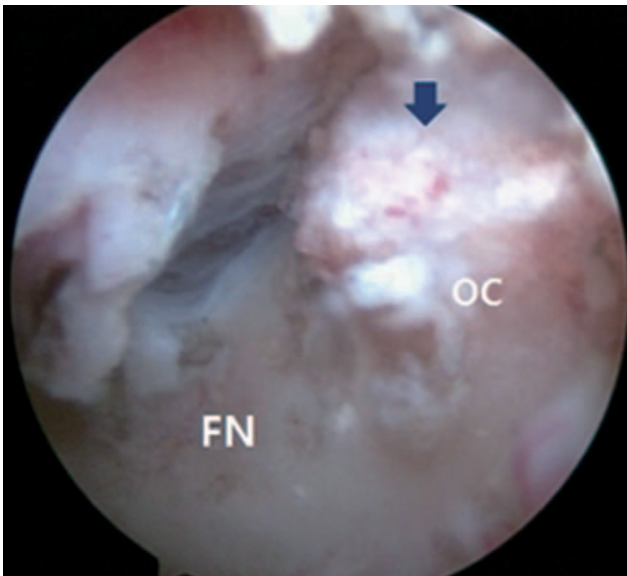


Fig. 5. Arthroscopic finding of osteochondroma with cartilaginous cap (arrow) at posteromedial portion of femoral neck. FN: femoral neck, OC: osteochondroma.

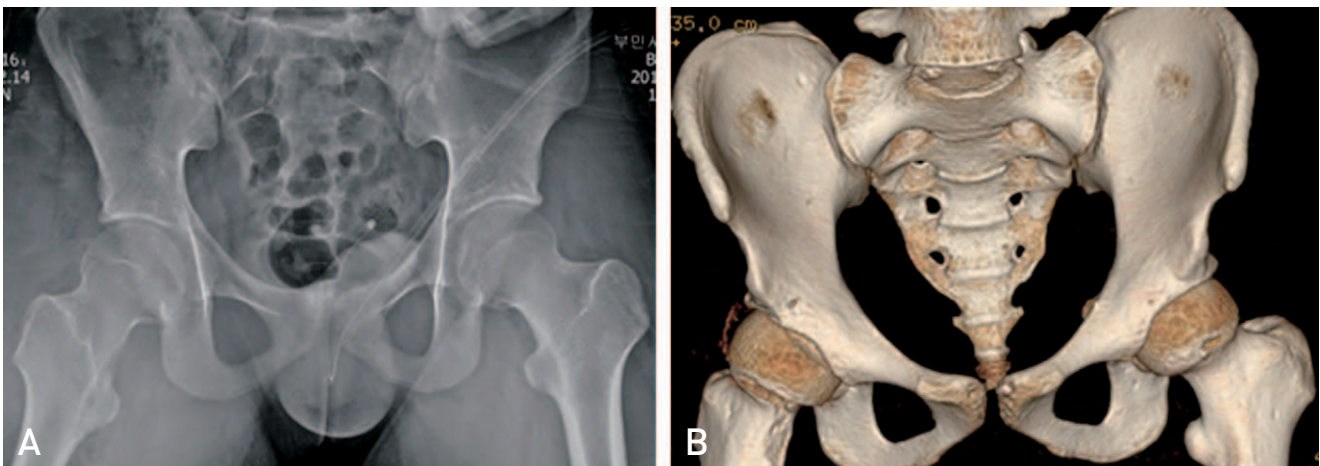


Fig. 6. (A) Postoperative simple radiography. The bony mass was removed successfully. (B) Postoperative 3 dimensional computed tomography image. Complete resection of osteochondroma was identified and degree of osteoplasty was evaluated postoperatively.

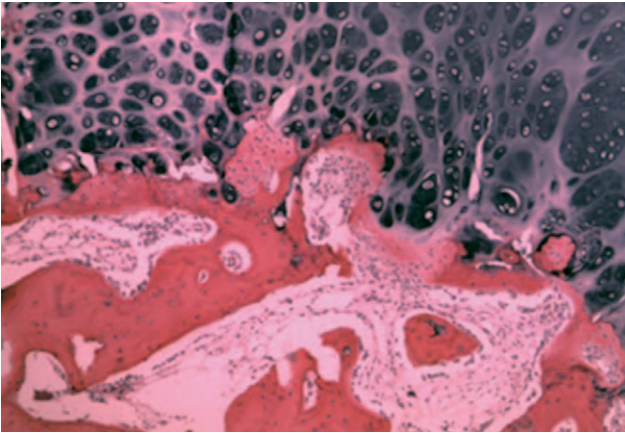


Fig. 7. The cartilaginous cap was identified in biopsy and the cap has a smooth round surface of a pathologic finding of osteochondroma (hematoxylin and eosin stain, $\times 40$).

osteoplasty, lateral femoral cutaneous nerve injury and extraarticular leakage of arthroscopic fluid. Arthroscopic procedure in far distal portion of peripheral compartment like this case may have an occurring chance of avascular necrosis of femoral head because this procedure need widened T-shaped capsulotomy which may make injury of medial femoral circumflex artery. So, we used small size osteotome for resection of stalk of osteochondroma and collection of biopsy specimen and removed remnant tumor using only arthroscopic burr. For preventing probable other complications, we used a plastic cannula for protecting neurovascular structure and performed femoroplasty under a fluoroscopic image intensifier. Though there was small amount of extraarticular leakage of the arthroscopic fluid and air bubbles along the

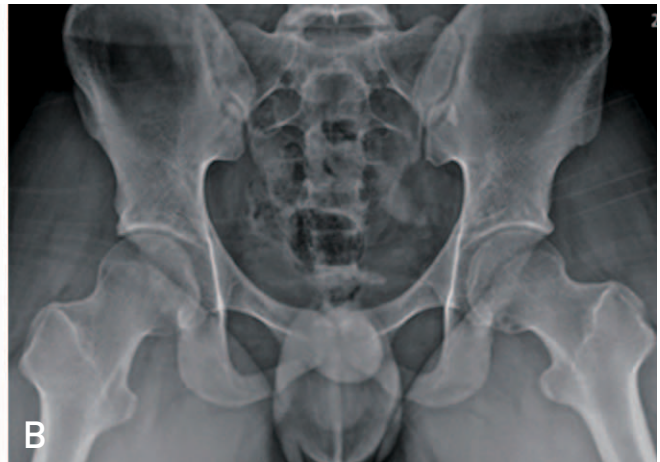
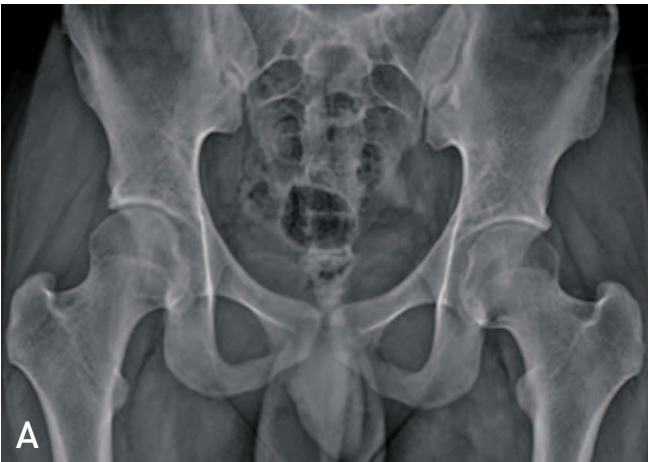
Fig. 8. (A) Hip anteroposterior simple radiography at postoperative 1 year. Posteromedial cortex of the femoral neck was reformed and any bony recurrence was not shown. (B) Hip frog leg lateral radiography at postoperative 1 year.

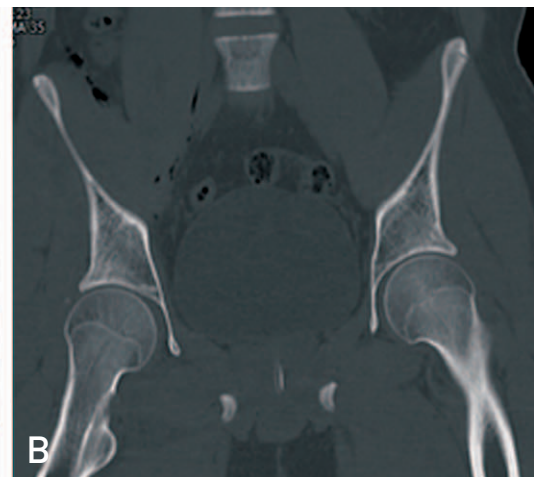
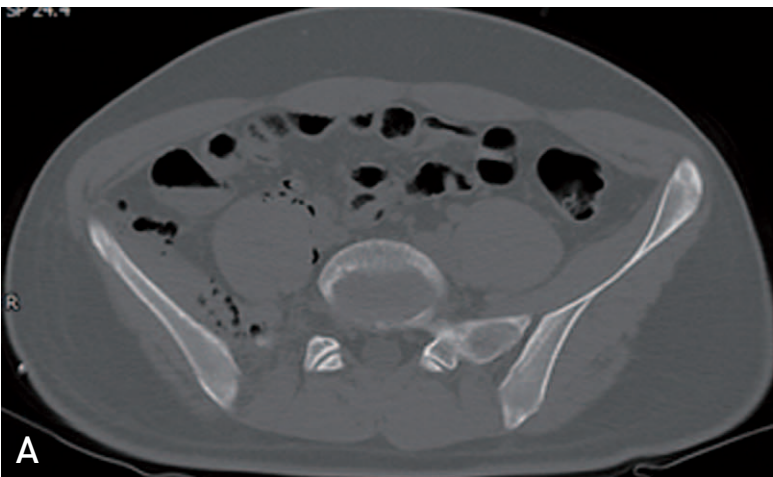


Fig. 9. (A) In postoperative axial image, leakage of arthroscopic fluid and air bubbles were shown around iliopsoas muscle. (B) In coronal computed tomography image, air bubbles were found along iliopsoas muscle.

iliopsoas muscle in postoperative CT images, that leakage did not make any symptom or complication (Fig. 9).

This case suggests that arthroscopic resection of intraarticular bony lesion of the hip joint can be applied depending on clinical situation. The patient needed arthroscopic treatment for FAI, acetabular labral tear and resection of osteochondroma and all procedures were performed simultaneously. When the operator have a plan for resection of intraarticular bony lesion, they must consider and find other intraarticular pathologies through preoperative evaluation. Arthroscopic management for coexistent problems must be performed for resolution of clinical symptoms of the patient.

Osteochondroma located in posteromedial portion of femoral neck can make a pathology of internal snapping hip and although technical demands are challenging, arthroscopic resection can be a good treatment option.

REFERENCES

1. Kanauchi T, Suganuma J, Kawasaki T, et al. *Fracture of an osteochondroma of the femoral neck caused by impingement against the ischium. Orthopedics. 2012;35:e1438-41.*
2. Yu K, Meehan JP, Fritz A, Jamali AA. *Osteochondroma of the femoral neck: a rare cause of sciatic nerve compression. Orthopedics. 2010;33:doi: 10.3928/01477447-20100625-26.*
3. Inoue S, Noguchi Y, Mae T, Rikimaru S, Hotokezaka S. *An external snapping hip caused by osteochondroma of the proximal femur. Mod Rheumatol. 2005;15:432-4.*
4. Hussain W, Avedian R, Terry M, Peabody T. *Solitary osteochondroma of the proximal femur and femoral acetabular impingement. Orthopedics. 2010;33:51.*
5. Siebenrock KA, Ganz R. *Osteochondroma of the femoral neck. Clin Orthop Relat Res. 2002;394:211-8.*
6. Carpintero P, León F, Zafra M, Montero M, Berral FJ. *Fractures of osteochondroma during physical exercise. Am J Sports Med. 2003;31:1003-6.*
7. Dienst M, Gödde S, Seil R, Hammer D, Kohn D. *Hip arthroscopy without traction: In vivo anatomy of the peripheral hip joint cavity. Arthroscopy. 2001;17:924-31.*
8. Feeley BT, Kelly BT. *Arthroscopic management of an intraarticular osteochondroma of the hip. Orthop Rev (Pavia). 2009;1:e2.*
9. Lee JB, Kang C, Lee CH, Kim PS, Hwang DS. *Arthroscopic treatment of synovial chondromatosis of the hip. Am J Sports Med. 2012;40:1412-8.*