

Carcinoma ex Pleomorphic Adenoma in the Floor of the Mouth: An Unusual Diagnosis in a Rare Location

Shalini Krishnan, Varsha Salian¹, Shubha Bhat², Vikram Shetty

Departments of Oral and Maxillofacial Surgery and ¹Oral Pathology, A.B. Shetty Memorial Institute of Dental Sciences, Nitte Deemed to be University, ²Department of Pathology, K.S. Hegde Medical Academy, Nitte Deemed to be University, Mangalore, Karnataka, India

Abstract

Carcinoma ex pleomorphic adenoma (CXPA) is a rare malignant salivary gland tumor, mostly involving the parotid and submandibular glands. Minor salivary gland involvement is even rarer, palate being the most common site. Other reported sites are upper lip, sinonasal tract, and buccal mucosa. Here, we report a case of CXPA in an unusual location, the floor of the mouth.

Keywords: Carcinoma ex pleomorphic adenoma, minor salivary glands, floor of the mouth

INTRODUCTION

Salivary gland tumors are most commonly associated with the parotid gland (61%–80%), most of which are benign, followed by minor salivary glands (9%–28%), the submandibular glands (8%–11%), and the sublingual gland (1%). The incidence of malignancy is highest in the sublingual gland (70%–95%), followed by the minor salivary glands (38%–49%), submandibular gland (26%–45%), and parotid gland (15%–32%).^[1]

In both the major and minor salivary glands, the most common benign tumor is pleomorphic adenoma (PA). Mucoepidermoid carcinoma is the most common malignant tumor, especially in the parotid glands, whereas adenoid cystic carcinoma is the most common malignancy in the submandibular and minor salivary glands.^[2,3] Malignant mixed tumors are uncommon neoplasms, which are broadly categorized into three different clinical and pathological entities: carcinoma ex mixed tumor, carcinosarcoma, and metastasizing mixed tumor.^[4]

Carcinoma ex pleomorphic adenoma (CXPA) is a malignant mixed tumor, where the carcinoma arises from a primary or recurrent PA. Carcinoma ex mixed tumor, carcinoma ex adenoma, and carcinoma ex benign PA are the other terminologies used.^[5] It is a rare malignant salivary gland tumor commonly occurring in parotid and submandibular glands. CXPA involving the minor salivary glands of the

palate, nasal mucosa, and buccal mucosa have been reported. Here, we report a case of CXPA in a very rare location, the floor of the mouth.

CASE REPORT

A 52-year-old female presented to the Department of Oral and Maxillofacial Surgery with a painless swelling in the floor of the mouth on the right side since 1-year, with no obvious increase in size. The swelling was not associated with any changes in salivation, but she had difficulty in articulation due to its size. Her medical history was insignificant. She had no history of tobacco use or any other adverse habits.

On retraction of the tongue, a solitary 5 cm × 4 cm swelling was noted in the floor of the mouth on the right side, crossing the midline till the lower left central incisor, completely obliterating the lingual vestibule and occupying the entire floor of the mouth on that side [Figure 1]. The mucosa overlying

Address for correspondence: Dr. Shalini Krishnan, Department of Oral and Maxillofacial Surgery, A.B. Shetty Memorial Institute of Dental Sciences, Nitte Deemed to be University, Mangalore, Karnataka, India. E-mail: dr_shaluk@rediffmail.com

Received: 12-06-2018

Accepted: 08-01-2020

Revised: 30-08-2019

Published: 08-06-2020

This is an open access journal, and articles are distributed under the terms of the Creative Commons Attribution-NonCommercial-ShareAlike 4.0 License, which allows others to remix, tweak, and build upon the work non-commercially, as long as appropriate credit is given and the new creations are licensed under the identical terms.

For reprints contact: WKHLRPMedknow_reprints@wolterskluwer.com

How to cite this article: Krishnan S, Salian V, Bhat S, Shetty V. Carcinoma ex pleomorphic adenoma in the floor of the mouth: An unusual diagnosis in a rare location. *Ann Maxillofac Surg* 2020;10:238-42.

Access this article online

Quick Response Code:



Website:
www.amsjournal.com

DOI:
10.4103/ams.ams_171_18

the swelling was adherent to the lingual gingiva in the region of the lower right premolars [Figure 2]. On palpation, the swelling was well defined, firm in consistency, regular surface, nontender, nonpulsatile, and not bimanually palpable. The mucosa overlying the swelling was freely movable except at the region of attachment to the gingiva. The submandibular ducts were patent and milking of the gland yielded normal saliva.

There was no evidence of salivary calculi or bony erosion in the mandibular occlusal radiograph. Contrast-enhanced computed tomography (CT) showed an enhancing mass lesion in the right sublingual region [Figures 3 and 4]. In view of the history, clinical features, and CT findings, we came to the diagnosis of a salivary gland tumor in the sublingual region. Fine-needle aspiration cytology was reported as sialadenitis of minor salivary gland. An incisional biopsy was thus carried out, which revealed the presence of mucous acini suggestive of minor salivary gland showing periductal inflammation and a very small portion of tumor cells arranged in cribriform pattern and cystic spaces filled with eosinophilic coagulum [Figure 5]. Hence, we came to a diagnosis of salivary gland tumor arising from the minor salivary gland with high suspicion of malignancy. Excisional biopsy of the lesion was hence planned under general anesthesia. Intraoperatively, the swelling was found to be submucosal and well-encapsulated [Figure 6]. Wide excision of the lesion, including the overlying mucosa and the distal portion of the submandibular duct was carried out. On gross examination of the excised specimen, there was no evidence of major salivary gland seen. Histopathological examination showed areas with features of PA with an overlying capsule containing ducts and acini. The ducts showed an inner epithelial cell layer and outer myoepithelial cell layer embedded in myxohyalinous background matrix, presence of transitional zones showing capsular invasion with cells arranged in cribriform and tubular pattern having cytomorphic features of adenoid cystic carcinoma. Invasion into the surrounding capsule as well as adjoining minor salivary glands was evident, with no perineural invasion. Based on the histopathological

findings, we arrived at a diagnosis of Carcinoma ex pleomorphic adenoma (CXPA) of the minor salivary gland with capsular infiltration. The patient was hence referred for postoperative radiotherapy. The patient is doing well and no evidence of recurrence has been noted after 1-year.

DISCUSSION

CXPA is the sixth most common malignant salivary gland tumor, with incidence ranging from 1.9% to 23.3%. It depicts a mixed tumor where the second neoplasm develops from the epithelial component that fulfills the criteria for malignancy, which include invasiveness, destruction of normal tissues, cellular anaplasia, cellular pleomorphism, atypical mitosis, and abnormal architectural patterns.^[4]

CXPA has been reported in the age group of 41–76 years in males and females. The palate is the most common intraoral site for CXPA of the minor salivary glands. Other reported sites are upper lip, sinonasal tract, and buccal mucosa.^[6-11]

Tumors of the salivary glands are firm, well-circumscribed, and differentiation of benign and malignant lesions is difficult clinically. In general, salivary tumors present in two forms, a well-defined, discrete, mobile lump, or a lump with significant associated symptoms such as pain, rapid growth, fixity to surrounding structures, nerve involvement or neck metastasis, the latter features suggestive of malignancy. A third of malignant tumors has an indolent nature and may be clinically indistinguishable from benign lesions. As a result, the definitive histology may not be available until after surgical resection. The diagnosis and management of these tumors should therefore be based on the clinical presentation, imaging, and cytology and/or histology results. Fine-needle aspiration cytology and core biopsy is the primary diagnostic tool for salivary lesions and can distinguish between benign and malignant disease in 90% of cases. Open biopsy is not recommended in major salivary gland lesions but may be performed in lesions of the minor salivary glands.^[12]

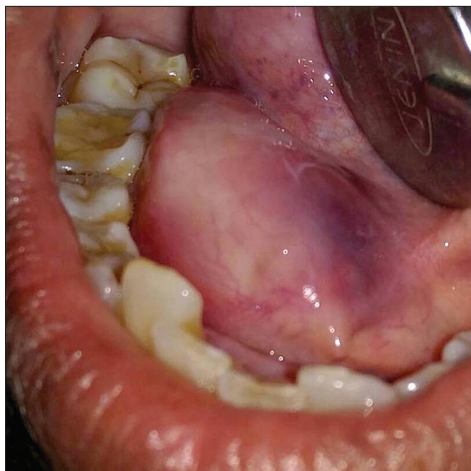


Figure 1: Swelling in the floor of mouth obliterating the lingual vestibule

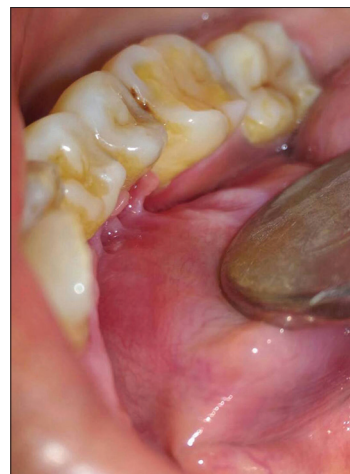

Figure 2: Mucosa over swelling adherent to lingual gingiva in the region of 44, 45

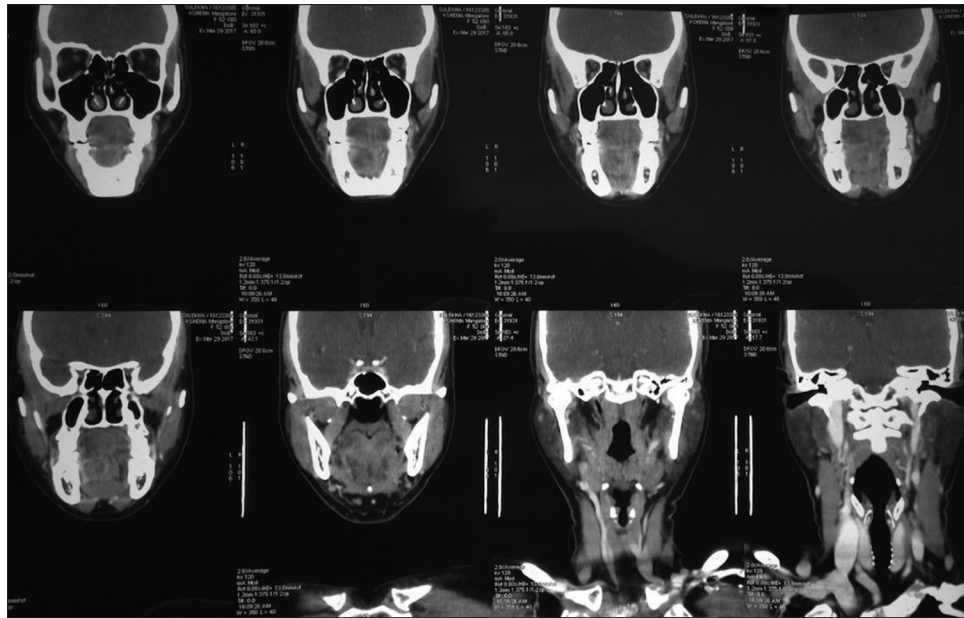


Figure 3: Contrast-enhanced computed tomography coronal sections showing enhancing mass lesion in the right sublingual region

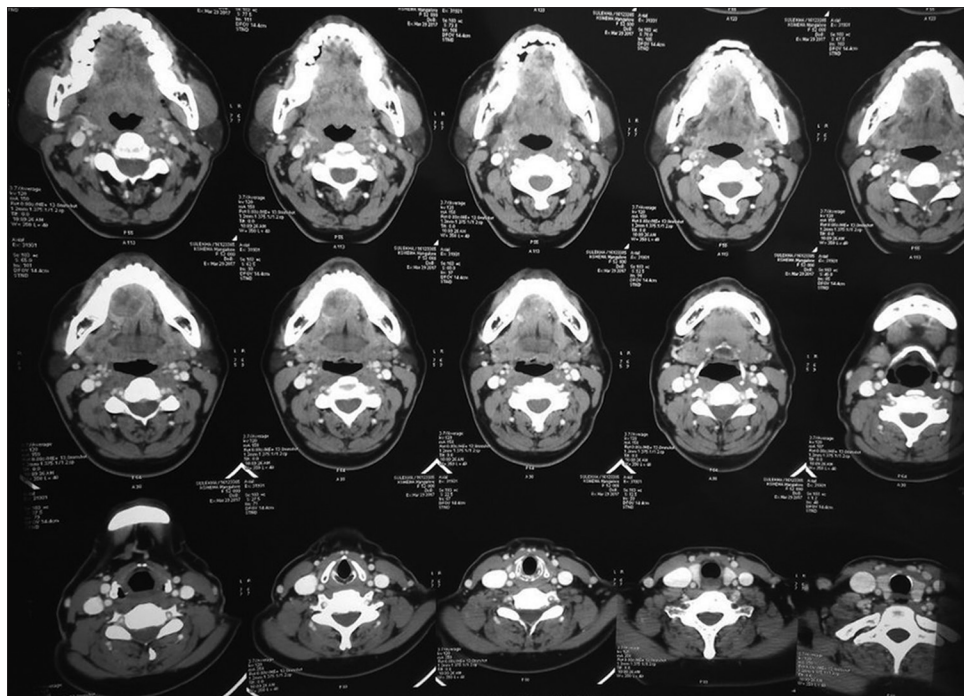


Figure 4: Contrast-enhanced computed tomography axial sections showing enhancing mass lesion in the right sublingual region

Preoperative clinical diagnosis of CXPA is difficult, and pathological assessment is the gold standard. Increased preoperative duration of PA increases the risk of malignant transformation into CXPA. The presenting symptoms of CXPA are similar to that of the benign tumor, and hence, it is important for clinicians to maintain a high degree of clinical suspicion, which is challenging as the tumor is quite rare.^[13]

Imaging modalities such as ultrasound, CT, and magnetic resonance imaging help to determine the size, position, and

relationship of the lesion to adjacent structures apart from identifying features of malignancy such as nonhomogeneity, muscle infiltration, and suspicious regional lymph node appearances. CT is useful in proven malignancy to exclude distant metastases, which carry a poor prognosis.^[4]

CXPA may either arise due to the accumulation of genetic instabilities in long-standing PAs or *de novo* in cases with a short history of the preexisting tumor. The most important prognostic factor is the extent of extracapsular invasion.

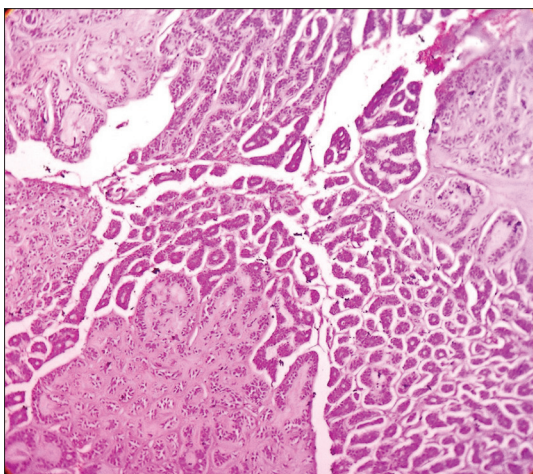


Figure 5: Histopathology photomicrograph

CXPAs are subclassified into noninvasive, minimally invasive (≤ 1.5 mm penetration into extracapsular tissue) and invasive (>1.5 mm of invasion).^[14] Our case showed the presence of adenoid cystic carcinoma with invasive component, which could mean poor prognosis. The clinical behavior of early or minimally invasive tumors is similar to that of PA. Only the malignant foci that extend beyond the tumor capsule is associated with clinically malignant behavior. Such tumors tend to be high grade with a high incidence of hematogenous metastasis.

Histopathologically, CXPA can be mistaken for a benign PA or a high-grade salivary gland adenocarcinoma. Other malignancies such as salivary duct carcinoma, polymorphous low-grade adenocarcinoma, and adenoid cystic carcinoma also form important differential diagnosis since all these tumors show features of extensive hyalinization. Hence, in histopathological examination, it is important to find remnants of benign PA with myxoid, chondroid, or bland ductal/myoepithelial component to diagnose it as CXPA.^[15]

Surgical management of the primary tumor in CXPA of the minor salivary glands is similar to that of squamous cell carcinoma, that is, *en bloc* resection with adequate resection margins followed by appropriate repair of the defect. Therapeutic neck dissection is indicated along with primary surgery in the presence of clinically positive cervical lymph nodes, followed by adjuvant radiotherapy.^[12] Elective treatment of the clinical N0 neck is controversial and includes observation, elective neck dissection, and prophylactic radiation.^[16] In our case, the cervical lymph nodes were not clinically palpable, but due to the invasive component of the tumor, the patient was referred for postoperative radiotherapy. From a clinical perspective, it may be more important to diagnose minimally invasive CXPA from invasive CXPA since it may affect decisions regarding the need for lymph node dissection and adjuvant radiotherapy and thus the prognosis.

T stage, lymph node involvement, histological grade, perineural invasion, and extent of invasion are important

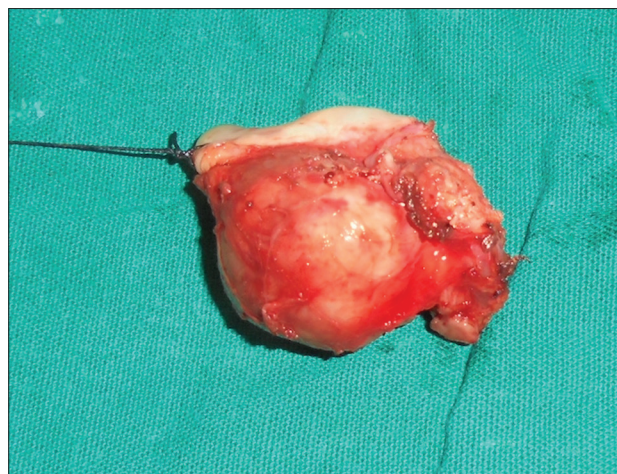


Figure 6: Excised surgical specimen showing well-encapsulated tumor; superficial mucosa seen excised along with the tumor

prognostic factors of CXPA in the major salivary glands. Surgery is the primary treatment modality, and postoperative radiation therapy may be used in patients with factors for poor prognosis.^[14]

Acknowledgments

We would like to acknowledge the contribution of Prof. Dr. Pushparaja Shetty, Head of Department of Oral Pathology, A.B. Shetty Memorial Institute of Dental Sciences, Mangalore, in the diagnosis of this case.

Declaration of patient consent

The authors certify that they have obtained all appropriate patient consent forms. In the form the patient(s) has/have given his/her/their consent for his/her/their images and other clinical information to be reported in the journal. The patients understand that their names and initials will not be published and due efforts will be made to conceal their identity, but anonymity cannot be guaranteed.

Financial support and sponsorship

Nil.

Conflicts of interest

There are no conflicts of interest.

REFERENCES

1. Neville BW, Damm DD, Allen CM, Chi AC. In: Salivary Gland Pathology. Oral and Maxillofacial Pathology. 1st South Asia ed. Elsevier; 2015.
2. Agulnik M, McGann C, Mittal B, Gordon S, Epstein J. Management of salivary gland malignancies: Current and developing therapies. *Oncol Rev* 2008;2:86-94.
3. Lukšić I, Virag M, Manojlović S, Macan D. Salivary gland tumours: 25 years of experience from a single institution in Croatia. *J Craniomaxillofac Surg* 2012;40:e75-81.
4. Ellis GL, Auclair PL, Gnepp DR. In: Surgical Pathology of the Salivary Glands. Philadelphia: WB Saunders; 1991.
5. Gnepp DR. Malignant mixed tumors of the salivary glands: A review. *Pathol Annu* 1993;28 Pt 1:279-328.
6. McNamara ZJ, Batstone M, Farah CS. Carcinoma ex pleomorphic adenoma in a minor salivary gland of the upper lip. *Oral Surg Oral Med Oral Pathol Oral Radiol Endod* 2009;108:e51-3.

7. Sedassari BT, Dos Santos HT, Mariano FV, da Silva Lascane NA, Altemani A, Sousa S. Carcinoma ex pleomorphic adenoma of minor salivary glands with major epithelial-myoeithelial component: Clinicopathologic and immunohistochemical study of 3 cases. *Ann Diagn Pathol* 2015;19:164-8.
8. Goyal P, Sehgal S, Ghosh S, Agrawal D, Singh S. Rare carcinoma ex-pleomorphic adenoma of buccal mucosa: Case report and review of literature. *Rare Tumors* 2016;8:6138.
9. Toluie S, Thompson LD. Sinonasal tract adenoid cystic carcinoma ex-pleomorphic adenoma: A clinicopathologic and immunophenotypic study of 9 cases combined with a comprehensive review of the literature. *Head Neck Pathol* 2012;6:409-21.
10. Dyalram D, Huebner T, Papadimitriou JC, Lubek J. Carcinoma ex pleomorphic adenoma of the upper lip. *Int J Oral Maxillofac Surg* 2012;41:364-7.
11. Kini Y, Desai C, Mahindra U, Kalburge J. Rare carcinoma ex pleomorphic adenoma of the buccal minor salivary gland causing a therapeutic dilemma. *Contemp Clin Dent* 2012;3:209-11.
12. Sood S, McGurk M, Vaz F. Management of salivary gland tumours: United Kingdom national multidisciplinary guidelines. *J Laryngol Otol* 2016;130:S142-9.
13. Antony J, Gopalan V, Smith RA, Lam AK. Carcinoma ex pleomorphic adenoma: A comprehensive review of clinical, pathological and molecular data. *Head Neck Pathol* 2012;6:1-9.
14. Zhao J, Wang J, Yu C, Guo L, Wang K, Liang Z, *et al.* Prognostic factors affecting the clinical outcome of carcinoma ex pleomorphic adenoma in the major salivary gland. *World J Surg Oncol* 2013;11:180.
15. Gnepp DR, Brandwein-Gensler MS, El-Naggar AK, Nagao T. Carcinoma ex Pleomorphic Adenoma. In: Barnes L, Eveson JW, Reichart P, Sidransky D, editors. *World Health Organization classification of tumours: pathology and genetics of head and neck tumours*. Lyon: IARC; 2005: 242-3.
16. Wang X, Luo Y, Li M, Yan H, Sun M, Fan T. Management of salivary gland carcinomas: A review. *Oncotarget* 2017;8:3946-56.