

EARLY CHANGES FOLLOWING THE INJECTION OF
TUBERCLE BACILLI INTO THE METAPHYSIS
OF THE LONG BONES OF ANIMALS.

By JEAN OLIVER, M.D.

(From the Pathological Laboratory and the Laboratory of Surgical Pathology of the
Medical School of Leland Stanford Junior University, San Francisco.)

PLATE 4.

(Received for publication, April 2, 1920.)

It has long been recognized that tuberculous infection of long bones originates and is in great part confined to the metaphysis and epiphysis. There is a marked contrast in this localization to the diffuse process which follows infection with pyogenic organisms, and it is not surprising that many conjectures have been made to explain the observed facts. Notable among these is the suggestion of Lexer,¹ whose anatomical studies led him to believe that embolic deposit of bacteria in the region of the metaphysis is favored by the course of the arteries. On the other hand, Ely² claims that peculiarities in the structure of the bone marrow more clearly explain the facts.

The following experiments were done to examine the latter factor. No attempt was made to infect the bone in a manner analogous to spontaneous infection in man, as our interest is concerned with the cellular reaction which follows the infection, rather than with the path of the infection. As an aid in the determination of the various cell types the animals were vitally stained.

In normal vitally stained animals the leucocytes and the megacaryocytes show no deposits of the dye. The fibroblasts are as a rule also free from dye, though in intensely stained animals a few fine granules are seen at either end of the nucleus. The cell that shows the vital stain in greatest amount is the reticulo-endothelial cell which lines the venous spaces of the marrow. The protoplasm of

¹ Lexer, E., *Arch. klin. Chir.*, 1904, lxxiii, 481.

² Ely, L. W., *Joint tuberculosis*, New York, 1911.

these stellate or triangularly shaped cells is crowded with bright blue granules of varying size, so that the nucleus may be entirely hidden. It is these cells which have been described as phagocytosing blood pigments, and as normally possessing a brown pigment.³ The reaction of these cells to the vital stain has caused them to be included in the large group termed histiocytes,⁴ or resting wandering cells.⁵ They correspond roughly to the macrophages of Metchnikoff.

The histogenesis of the tubercle has been studied with the aid of vital staining by several investigators. Oppenheimer,⁶ Goldmann,⁷ and Evans, Bowman, and Winternitz⁸ have used this method in following the development of the tubercle in the liver, and Joest and Emshoff⁹ in the lymph glands. Kiyono mentions the bone marrow,⁴ but gives no details of his observations. All these investigators agree that the early groups of epithelioid cells forming the miliary tubercle are made up of, or derived from the vitally stained histiocytes found in these organs.

Technique.

Rabbits were given 20 cc. of a 1 per cent solution of trypan blue intravenously, and 2 days later, a trephine opening¹⁰ was made in the metaphysis of the tibia and one to two drops of a normal salt solution emulsion of bovine tubercle bacilli injected into the marrow. Similar experiments were made with guinea pigs and tubercle bacilli of the human type. After varying intervals, from 3 to 9 days, the animals were killed and portions of the bone removed and fixed in 10 per cent formaldehyde. After fixation the marrow was removed from the bone, embedded in paraffin, and sections were appropriately stained.

³ Brass, H., and Weidenreich, F., *Arch. mikr. Anat., 1te Abt.*, 1913, lxxxii, 61.

⁴ Kiyono, K., *Die vitale Karminspeicherung*, Jena, 1914.

⁵ Tschaschin, S., *Folia hæmatol.*, 1913-14, xvii, 317.

⁶ Oppenheimer, R., *Virchows Arch. path. Anat.*, 1908, cxciv, suppl., 254.

⁷ Goldmann, E. E., *Neue Untersuchungen über die Äussere und Innere Sekretion des gesunden und kranken Organismus in der "vitalen Färbung,"* Tübingen, 1912, 67.

⁸ Evans, H. M., Bowman, F. B., and Winternitz, M. C., *J. Exp. Med.*, 1914, xix, 283.

⁹ Joest, E., and Emshoff, E., *Virchows Arch. path. Anat.*, 1912, ccx, 188.

¹⁰ The operation was performed under ether anesthesia.

In all the animals so treated it was possible to demonstrate either the bacilli, definite tubercles and giant cells, or diffuse caseation, depending on the length of time that the animal lived after infection. Guinea pigs proved more satisfactory for the early stages, as the bovine bacilli used in the experiments on rabbits were difficult to stain.

EXPERIMENTAL.

In our experiments the earliest changes were observed 3 days following the operation. No lesion could be seen in the gross, and but little change was observed in sections with a low magnification. Around the area of injection, which showed little or no evidence of trauma, the lymphoid cells were decreased in number, while the vitally stained reticulo-endothelial cells were more numerous than in the normal marrow at a distance from the trephine opening.

With a higher magnification it was seen that a large number of the leucocytes showed evidences of nuclear degeneration, while the reticulo-endothelial cells contained two or more nuclei, and instead of being stellate in shape as normally, were now rounded and lay free in the sinuses of the marrow (Fig. 1). No mitotic figures were observed in these cells but the increase in their number and the presence of more than one nucleus to a single protoplasmic body warrant the assumption of an active proliferation on their part.

Another appearance noted in these cells was the presence of clear areas free from dye granules which showed no coloration with the counterstain. These were interpreted as vacuoles, and in sections stained for tubercle bacilli it was possible to demonstrate in them one or more acid-fast bacilli. With an increase in the number of bacilli in the cell there was a corresponding decrease in the number of dye granules. Fig. 2 shows a cell filled with bacilli and having many large vacuoles and a few faded dye granules.

In somewhat later stages of the infection groups of vitally stained reticulo-endothelial cells were seen consisting of from ten to twenty cells (Fig. 3). These cells contained acid-fast bacilli and showed varying degrees of the changes described above. It was impossible to determine whether these cells had proliferated *in situ* or wandered to the point of infection. The impression that the latter is the case

is obtained from the appearance of the cells, though both methods of increase doubtless occur.

A few giant cells were seen in the sections. These had the typical morphology of the Langhans type (Fig. 4). In their clear protoplasm could be seen dye granules and vacuoles, which in suitably stained specimens showed acid-fast bacilli. In many instances the contours of the individual reticulo-endothelial cells forming them could still be made out.

No attempt was made to follow the tuberculous process in its further development. Several animals were allowed to live a month or until death. In all these animals extensive tubercular lesions were found in the diseased bones, consisting of broad areas of caseation surrounded by granulation tissue. In this granulation tissue were many reticulo-endothelial cells still showing dye granules.

The demonstration by Lexer of numerous anastomoses in the metaphyses of long bones, though it may explain the more frequent embolic deposit of bacteria in that region, does not explain the difference observed in the localization of a tuberculous process, as contrasted with the diffuse lesion seen in pyogenic infections.

The present experiments emphasize the view that the observed difference may be due to peculiarities in the structure of the infected tissue, the bone marrow, for this tissue in the metaphyses of long bones as contrasted with the fatty marrow of the diaphyses, is rich in the cells which are particularly concerned in the reaction to infection with tubercle bacilli.

I wish to express my thanks to Dr. L. W. Ely and Dr. F. E. Blaisdell for their aid in the operations on the animals.

EXPLANATION OF PLATE 4.

All the figures were drawn with the aid of a camera lucida. Bausch and Lomb ocular 1, objective $\frac{1}{2}$.

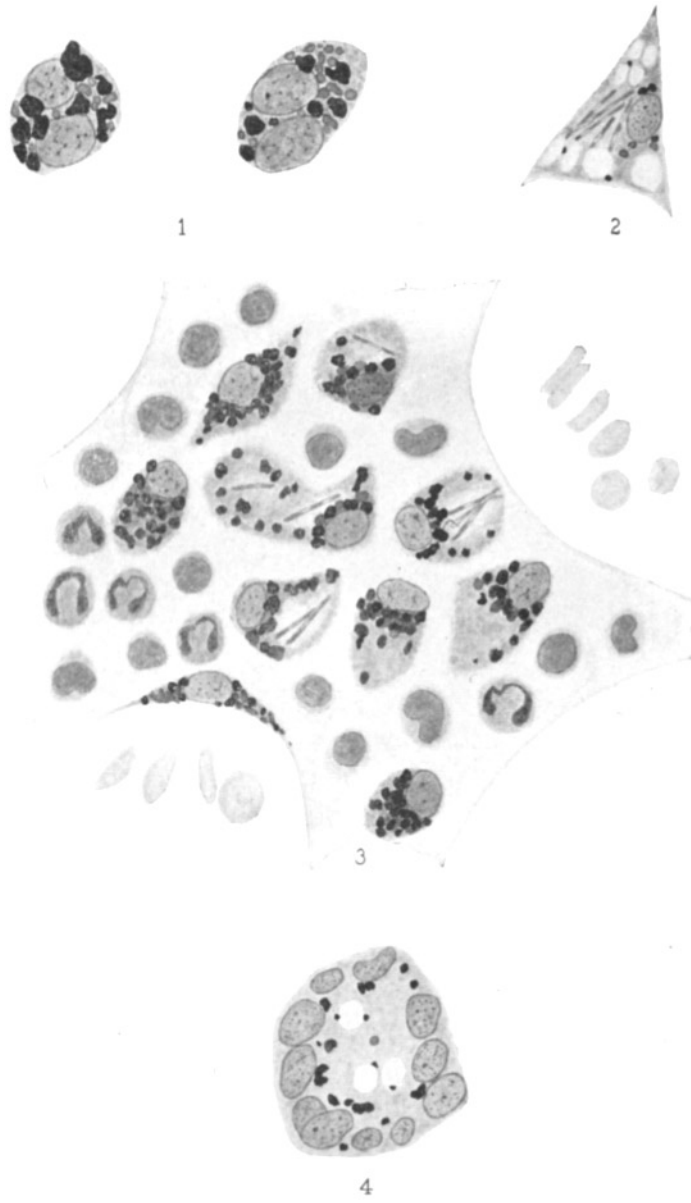
FIG. 1. Two reticulo-endothelial cells from the marrow of a vitally stained rabbit infected 4 days previously with bovine tubercle bacilli. The dye granules are of normal appearance, but each cell body contains two large nuclei. Carmine counterstain.

FIG. 2. Reticulo-endothelial cell from the marrow of a guinea pig 6 days after infection. Many vacuoles are seen and a large number of phagocytosed tubercle bacilli. The dye granules are few in number and pale. Stained with carbol-

fuchsin, decolorized with acid alcohol, and counterstained with methylene blue.

FIG. 3. A group of vitally stained cells in the marrow of a guinea pig 9 days after infection. The cells show varying degrees of vacuolation and six of them contain tubercle bacilli. The same stain as in Fig. 2.

FIG. 4. The same specimen as Fig. 3. A typical Langhans giant cell with dye granules and vacuoles in the central protoplasm. Carmine counterstain.



(Oliver: Tubercle bacilli.)