



## STANDARD ARTICLE

# Clinical, histopathologic, cystoscopic, and fluorescence in situ hybridization analysis of proliferative urethritis in 22 dogs

Moria A. Borys<sup>1</sup>  | Sean E. Hulsebosch<sup>2</sup> | F. Charles Mohr<sup>3</sup> | Katherine D. Watson<sup>3</sup> |  
Jane E. Sykes<sup>2</sup> | Kenneth W. Simpson<sup>4</sup> | Jodi L. Westropp<sup>2</sup> 

<sup>1</sup>Veterinary Medical Teaching Hospital, University of California-Davis School of Veterinary Medicine, California

<sup>2</sup>Department of Medicine and Epidemiology, Veterinary Medical Teaching Hospital, University of California-Davis School of Veterinary Medicine, California

<sup>3</sup>Department of Anatomic Pathology, Veterinary Medical Teaching Hospital, University of California-Davis School of Veterinary Medicine, California

<sup>4</sup>Department of Clinical Sciences, Cornell University College of Veterinary Medicine, New York

## Correspondence

Jodi L. Westropp, Department of Medicine and Epidemiology, Veterinary Medical Teaching Hospital, University of California-Davis School of Veterinary Medicine, One Shields Avenue, Davis, CA 95616.  
Email: jlwestropp@ucdavis.edu

## Funding information

Center for Companion Animal Health, School of Veterinary Medicine, University of California-Davis, Grant/Award Number: 2016-32-R

**Background:** Proliferative urethritis (PU) is a lower urinary tract disease of dogs characterized by frond-like lesions in the urethra. The etiology of PU is unknown, although an association with bacterial cystitis is reported.

**Objectives:** Deep-seated bacterial cystitis is associated with PU, particularly in dogs with neutrophilic or granulomatous inflammation.

**Animals:** Twenty-two client-owned dogs with PU and 5 control dogs euthanized for non-urinary disease.

**Methods:** In retrospective analysis, medical records of dogs with PU from 1986 to 2016 were reviewed. Signalment, clinical signs, cystoscopic findings, antimicrobial use, and results of urine, bladder, or urethral tissue cultures, if available, were recorded. Histopathology was reviewed and classified as lymphocytic-plasmacytic (LP), neutrophilic, LP-neutrophilic (LPN), granulomatous, or pleocellular. Eubacterial fluorescence in situ hybridization (FISH) was performed on 18 tissue samples (13 cases, 5 controls), with subsequent evaluation of bacterial species.

**Results:** Of the 22 dogs, 9 had LP urethritis, 6 had LPN, 4 had pleocellular, and 3 had neutrophilic urethritis. Of note, 7 of 13 PU samples were FISH+ for adherent or invasive bacteria; 1 of 5 controls were FISH+ for adherent bacteria. Five dogs had negative urine and tissue cultures when FISH was positive. There was no association detected between the type of urethral inflammation and the results of urine and tissue culture or FISH.

**Conclusions and Clinical Importance:** The type of inflammation varied widely in these 22 PU cases. Deep-seated bacterial urethritis could be contributing to the inflammatory process in some dogs, regardless of the inflammation type. Urine and tissue cultures likely underestimate bacterial colonization of the urethra in dogs.

## KEYWORDS

granulomatous disease, lower urinary tract disease, urethral obstruction, urinary tract infection

**Abbreviations:** ABUC, aerobic bacterial urine culture; FISH, fluorescence in situ hybridization; IBC, intracellular bacterial communities; LP, lymphocytic-plasmacytic; LPN, lymphocytic-plasmacytic neutrophilic; LUT, lower urinary tract; PU, proliferative urethritis; UTI, urinary tract infection; VMTH, Veterinary Medical Teaching Hospital.

This study was presented as an oral abstract at the 2017 ACVIM Forum in National Harbor, Maryland.

## 1 | INTRODUCTION

Proliferative urethritis (PU) in dogs is characterized by a “frond-like” inflammatory tissue within the urethral lumen. Affected dogs might exhibit clinical signs including stranguria, hematuria, pollakiuria, and dysuria, or can present with partial or complete urethral obstruction.

This is an open access article under the terms of the Creative Commons Attribution-NonCommercial License, which permits use, distribution and reproduction in any medium, provided the original work is properly cited and is not used for commercial purposes.

© 2018 The Authors. *Journal of Veterinary Internal Medicine* published by Wiley Periodicals, Inc. on behalf of the American College of Veterinary Internal Medicine.

Originally, the term “granulomatous urethritis” was given to this condition because of the presence of large numbers of macrophages in biopsy specimens; however, granulomatous inflammation is not always present.<sup>1,2</sup> Previous descriptions of urethral biopsies have included granulomatous,<sup>3</sup> lymphoplasmacytic,<sup>4</sup> neutrophilic,<sup>1</sup> and mixed inflammation with lymphocytes, plasma cells, neutrophils, and eosinophils.<sup>1</sup> Because of the variety of inflammatory cells reported and the abundant luminal tissue ingrowth typically visualized on urethroscopy, the term “proliferative urethritis” is now more commonly used in the veterinary literature to describe this disorder.

The etiology of PU has not been elucidated, and a number of treatments have been employed with variable outcomes. These treatments include administration of antimicrobials, nonsteroidal anti-inflammatories, glucocorticoids, and immunosuppressive medications.<sup>1</sup> When the urethritis is severe enough to cause urethral obstruction, surgical interventions involving urethral resection,<sup>2</sup> cystostomy tube placement,<sup>3</sup> and placement of transurethral metallic stents<sup>4</sup> have been utilized. PU might develop because of recurrent or deep-seated bacterial cystitis and urethritis, an immune-mediated process, or a combination of both.<sup>1</sup>

Although aerobic bacterial urine cultures (ABUC) can be positive at the time of diagnosis, it remains unclear if urinary tract infection (UTI) is a cause or consequence of the proliferative uroepithelial tissue. Some dogs have responded to antimicrobial treatment alone,<sup>1</sup> supporting an underlying infectious etiology. Culture of mucosal biopsies could be more informative than urine; 17% of bacterial cultures from bladder mucosa are positive with a concurrent negative urine culture, suggesting that ABUC underestimates bacterial colonization within mucosal tissues.<sup>5</sup> Furthermore, many clinicians initiate empiric antimicrobial treatment before urethral biopsy acquisition, complicating definitive identification of bacterial infection. Therefore, tissue cultures or advanced diagnostics to probe for deep-seated bacterial infections in PU cases might be required in some cases.

Fluorescence in situ hybridization (FISH) is a culture-independent technique that can be utilized to identify the presence, number, and spatial distribution of bacteria within formalin-fixed tissues.<sup>6</sup> Given the association between PU and UTI, FISH analyses of affected urethral tissues could further elucidate the etiopathogenesis of PU.

The aims of our study were to describe the clinical characteristics, cystoscopy findings, histopathology, and results of aerobic bacterial urine and tissue cultures in dogs with biopsy-confirmed PU. In addition, FISH was performed to probe for mucosally associated bacteria in urethral tissue biopsies. We hypothesized that mucosally associated bacteria drive urethritis and tissue proliferation in cases of PU and that these bacteria would be associated with suppurative or granulomatous urethritis.

## 2 | MATERIALS AND METHODS

### 2.1 | Study population

A retrospective search of the electronic veterinary medical record database of the William R. Pritchard Veterinary Medical Teaching Hospital (VMTH) at the University of California, Davis, for cases of

proliferative or granulomatous urethritis from 1986 to 2016 was performed. Any dog with this diagnosis based on a combination of clinical suspicion, cystoscopic, or necropsy findings, and histopathology was considered for inclusion. Dogs were excluded if histopathology of the urethra was not available or if evidence of neoplasia was present upon review.

The following data were recorded for each dog at the time PU was diagnosed: signalment, clinical signs, history of urolithiasis, body weight and body condition score (BCS), cystoscopic findings, administration of antimicrobials at the time of biopsy, and results of ABUC (both at the time of biopsy and for 6 months before biopsy) or tissue culture.

### 2.2 | Urine and tissue cultures

All urine and tissue specimens had been submitted to the University of California, Davis, VMTH microbiology laboratory for routine urinalysis, and aerobic bacterial culture was prepared by inoculation of either 10  $\mu$ L of urine or a sample of tissue onto 5% defibrinated sheep's blood agar and MacConkey agar; plates were subsequently incubated at 35°C in room air with added 5% CO<sub>2</sub>. Tissue specimens were also inoculated into tryptic soy enrichment broth, which was subsequently incubated at 35°C in room air; subculture onto 5% defibrinated sheep's blood agar and MacConkey agar was performed if any cloudiness was detected. Susceptibility testing using the Clinical Laboratory Standards Institute methodology was performed.<sup>6</sup>

### 2.3 | Histopathologic analysis

All biopsy specimens were reviewed by a board-certified anatomic pathologist (F.C.M.) and anatomic pathology resident (K.W.) and were categorized as primarily consisting of (1) lymphocytic-plasmacytic (LP), (2) neutrophilic, (3) LP and neutrophilic (LPN), (4) granulomatous, or (5) pleocellular inflammation. Postmortem tissues were also collected in a nonsterile manner from 5 dogs that were euthanized, in a median time of 20 hours (range 4–26 hours) after euthanasia, for non-lower urinary tract disease (LUTD), and were embedded in paraffin blocks and were used as control tissues, reviewed by the same pathology team. Gram staining was performed using standard techniques in all dogs (including controls) that had sufficient tissue remaining for FISH analysis.

### 2.4 | FISH analysis

Paraffin-embedded blocks, including those from the control dogs, with sufficient remaining urethral tissues were submitted to the Cornell University College of Veterinary Medicine for FISH analysis. FISH analysis was carried out as previously described.<sup>7</sup> In brief, 5 sections of each paraffin block were cut into 5- $\mu$ m thick sections and placed on separate charged glass slides. Eubacterial 16S rRNA probes (EUB338-Cy3) were utilized for the initial FISH analysis; the irrelevant probe non-EUB338-6FAM was also applied as a negative control. FISH analysis was considered positive if either tissue-adherent or adherent and invasive bacteria were seen and negative if no bacteria were visualized with fluorescent microscopy.

Subsequent FISH analyses targeted bacterial species of interest; this was based on the results of concurrent tissue or urine cultures, as well as bacterial morphology as visualized on initial FISH analysis. 16S rRNA probes specific to *Escherichia coli*, *Streptococcus*, and/or *Staphylococcus* were used where indicated.<sup>7</sup>

## 2.5 | Statistical analysis

Descriptive statistics were utilized to describe the signalment, clinical signs, and characteristics of the dogs with PU, cystoscopic findings, histopathology results, urine and tissue culture, and FISH analysis results.

## 3 | RESULTS

### 3.1 | Study and control populations

Twenty-three dogs with biopsy-confirmed PU were identified; 22 had sufficient formalin-fixed tissue available for histopathologic review. Of 22 urethral tissue specimens, 19 were procured via cystoscopy, whereas 3 were obtained via necropsy. Fourteen dogs were female (13 spayed, 1 intact), and 8 were male (7 castrated, 1 intact). The median age was 8.6 (range, 0.4-15.0) years. Weight and BCS data were available for 19 of 22 dogs; median weight was 32.4 (range, 7.3-50.1) kg, whereas median BCS was 5.5 (range, 3-9). Fourteen dogs (74%) weighed >20 kg. The German Shepherd dog was the most common breed (5/22; 23%), and the breed was overrepresented in the study population as compared to the hospital population during the study period (odds ratio [OR] 7.21, 95% confidence interval [CI]: 2.66-19.54;  $P < .001$ ). This was followed by mixed breed dogs (4/22; 18%) and Labrador Retrievers (3/22; 14%), neither of which were found to be overrepresented in the study population (mixed breeds: OR 0.87, 95% CI: 0.29-2.56,  $P = .80$ ; Labrador Retrievers: OR 1.78, 95% CI: 0.53-5.99,  $P = .36$ ). There were also 1 each of Shih Tzu, Lhasa Apso, Bull Mastiff, Cairn Terrier, Border Collie, Shetland Sheepdog, Dalmatian, Airedale Terrier, English Terrier, and Saint Bernard.

Five dogs that were euthanized or died of causes unrelated to LUTD were included as negative controls for FISH analysis of urethral tissue. Of these, 3 dogs were spayed females and 2 dogs were castrated males. Median age was 10.3 years (range, 5.2-15.1 years). Median weight was 26.0 kg (range, 3.5-35 kg). Breeds represented included Papillon, Labrador Retriever, Weimaraner, Cavalier King Charles Spaniel, and Rhodesian Ridgeback cross.

### 3.2 | Clinical signs

Clinical signs were available for 20 of 22 dogs (Table 1). Most had stranguria (12/20, 60%), urinary incontinence (9/20, 45%), or pollakiuria (8/20, 40%). In addition to these signs, 7 of 20 dogs (35%) had been diagnosed with urolithiasis at least once; 4 dogs had been removed before the time of cystoscopic biopsy, ranging from 3 weeks to 4 years prior. These uroliths were composed of struvite (2), silica and calcium oxalate (1), or were of unknown composition, because they were not submitted for analysis (1). Of the remaining 3 dogs, 1 had a calcium oxalate stone retrieved at the time of cystoscopic

**TABLE 1** Clinical signs in dogs with proliferative urethritis, where data were available (n = 20)

Clinical sign	Number
Stranguria	12 (60%)
Urinary incontinence	9 (45%)
Pollakiuria	8 (40%)
Urethral obstruction	7 (35%)
Polyuria/Polydipsia	6 (30%)
Periuria	5 (25%)
Inappetence	5 (25%)
Malodorous urine	3 (15%)
Hematuria	2 (10%)

Abbreviations: PU/PD, Polyuria/polydipsia.

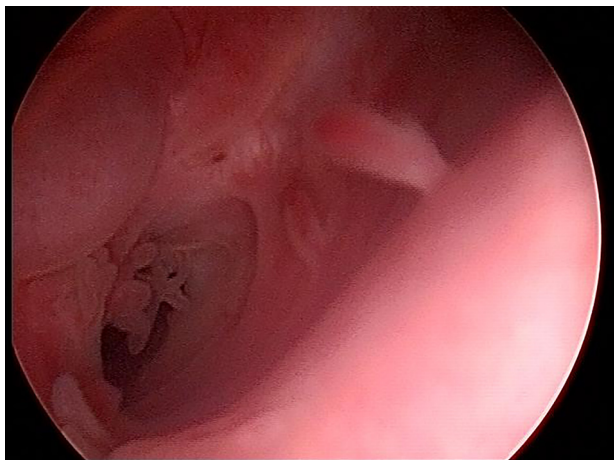
biopsy and 1 was euthanized because of urethral obstruction occurring secondary to both proliferative tissue and multiple uroliths composed of urate and silica. The final dog had small recurrent stones visualized on cystoscopy 2 years after original removal of stones; these stones were not submitted for evaluation at either time point. One additional dog had a urethral plaque lesion noted on cystoscopy, but no distinct stone was visualized.

Two of 8 male dogs had a reported history of bacterial prostatitis; one of these dogs was intact at the time of PU diagnosis. The other dog had been castrated approximately 2 years previously (at 10 years of age) because of stranguria and suspected prostatitis; however, clinical signs did not fully resolve after neuter, and this dog experienced recurrent intermittent stranguria and urinary incontinence until the time of evaluation when the PU was diagnosed.

Most dogs (13/21, 57%) had been treated with antimicrobials for >24 hours before biopsy collection; antimicrobial data were not available for 1 dog. Antimicrobials administered as well as the dosages and durations varied and included penicillins/cephalosporins (7 dogs), fluoroquinolones (4 dogs), sulfonamides (2 dogs), tetracyclines (1 dog), and chloramphenicol (1 dog). The 2 dogs treated with combination treatment both received a penicillin and a fluoroquinolone.

### 3.3 | Cystourethroscopy findings

Nineteen of the 22 dogs had cystoscopy performed. All 19 of these dogs had evidence of proliferative, "frond-like," or irregular tissue projections into the urethral lumen (Figure 1). Gross evidence of cystitis, based on the findings of hyperemic, or thickened bladder wall, was present in 13 of the 19 (68%) dogs. Of 13 female dogs, 8 had gross evidence suggestive for vestibulitis, which ranged from a mild cobblestone appearance in the vestibule to more severe proliferative tissue or purulent discharge surrounding the external urethral meatus. Fibrous bands, pseudomembranes, or strictures were noted within the urethra of 6 dogs. Discrete mass lesions within the urethra or at the external urethral meatus were noted in 5 dogs, 2 of which had proliferative tissue in the region of the "mass" only. One dog had multiple mineral plaques visualized within the urethra as well as within a urethral diverticulum. Lastly, 1 dog had an accumulation of foreign material (hair and viscous material that appeared grossly purulent) in the distal urethra, with tissue irregularities focused around this site.



**FIGURE 1** Representative urethroscopy image, showing typical “frond-like” appearance of proliferative urethral mucosa

### 3.4 | Histopathology, ABUC, tissue culture, and FISH results

Histopathology was performed on all 22 dogs (Table 2). Of the 19 dogs that had biopsies obtained via cystoscopy, 2 also had necropsy performed. Only 3 dogs had biopsies obtained at necropsy only. Almost all categories of inflammation were identified. LP inflammation was the most common inflammatory process noted (9/22, 40%), followed by LP and neutrophilic (LPN) in 6 of 22 dogs (27%). Pleocellular inflammation was noted in 4 of 22 dogs (18%); this category included 2 dogs with eosinophilic inflammation in addition to LPN and 2 dogs with histiocytic inflammation in addition to LP or LPN inflammation. Purely neutrophilic inflammation was noted in 3 of 22 dogs (14%). No dog had purely granulomatous inflammation. Representative hematoxylin and eosin urethritis histopathology is shown Figure 2A-C. Histopathologic abnormalities were absent in urethral tissue from the 5 negative control dogs.

Eleven of 22 dogs (50%) had  $\geq 1$  ABUC documented in the 6 months before biopsy collection, and one result was removed from further analysis because of unclear results (positive ABUC was documented in the electronic medical record but no further information was available). Of the remaining dogs, 9 of 10 (90%) were positive for bacterial growth at least once and 5 (50%) had a positive ABUC  $\geq 2$  times. Perioperative ABUC was performed in 19 of 22 (86%) dogs (1/3 dogs at the time of necropsy and 18/19 dogs at the time of cystoscopy). Six of 18 ABUC (33%) performed at the time of cystoscopy and the single ABUC performed at the time of necropsy were positive;

these cultures were distributed among all types of identified inflammatory groups (Table 2).

Tissue cultures were performed in 10 dogs (8 bladder, 4 urethral; 2 dogs had both cultured during the same cystoscopic procedure); ABUC was performed in 9 of 10 of these dogs (Table 2). All 8 bladder tissue cultures were negative, including 1 dog that had a positive culture for *E. coli* on urethral mucosal biopsy. Positive urethral cultures were noted in 3 of 4 dogs; organisms included *E. coli* (from enrichment broth only), coagulase-negative *Staphylococcus*, and mixed growth of *Staphylococcus pseudintermedius* and *Fusobacterium*. Urethral histopathology classifications for the 3 dogs with positive urethral cultures included LP, LPN, and pleocellular inflammation, respectively.

Thirteen dogs had sufficient urethral tissue remaining for FISH analysis. FISH was positive in 7 of 13 (54%) dogs, of which 2 of 13 (15%) dogs had adherent bacteria and 5 of 13 (39%) dogs had adherent and invasive bacteria (Table 2). These FISH+ samples were distributed among all 4 histopathological categories. Of the 7 dogs with FISH+ results, 5 had received antimicrobials for >24 hours preceding biopsy, as compared with 4 of 5 (80%) dogs with negative FISH results (data missing for 1 dog). Representative FISH images are shown in Figure 3A-C. One of the 5 negative control (necropsy) samples was FISH+ for adherent bacteria; however, all 5 control samples were FISH– for adherent and invasive bacteria.

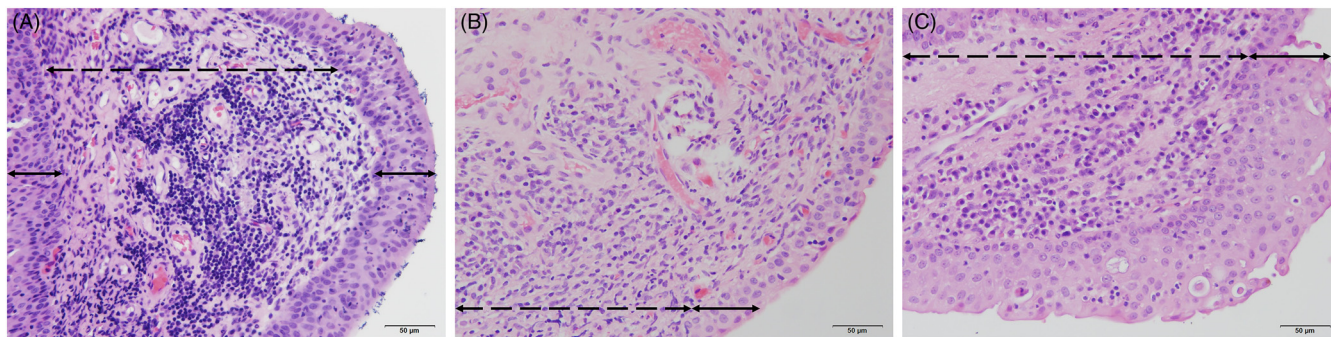
When comparing results of the 11 dogs with FISH analysis and perioperative ABUC, the ABUC was negative in 7 of 11 (64%) dogs, including 3 dogs with positive FISH results. Moreover, FISH was positive in 5 dogs when corresponding bladder, urethral tissue cultures, or both were negative. Four of 7 FISH+ dogs (57%) had positive urine or urethral tissue cultures at the time of biopsy; this included 1 dog with *Enterococcus faecium* cultured on ABUC only (bladder tissue culture negative), 1 dog with mixed growth from both urine and urethral tissue, and 2 dogs with *E. coli* cultured on ABUC. The 2 dogs with *E. coli* each had both bladder and urethral tissue cultured, with growth of *E. coli* from both samples in 1 dog and ABUC only in the other.

Follow-up FISH analyses, with species-specific probes guided by morphology and results of urine culture, were performed in all FISH+ samples. All 7 dog tissue samples were stained with *E. coli* and *Enterococcus* probes. Six dogs had rods visualized in urothelial tissues; 2 dogs had positive staining for *E. coli* (Figure 4), both of which had positive ABUC for this organism. Staining with probes specific for *Enterococcus* yielded 1 positive result, with small clusters of positive bacteria visualized in bladder mucosa. That dog had a negative ABUC at the time of biopsy. Probes specific for *Staphylococcus* (Figure 5) were positive in the case that contained the urethral plaque, with bacteria visualized

**TABLE 2** Urethral histopathology, ABUC, tissue culture, FISH analysis, and duration of antibiotics at the time of biopsy in 22 dogs with proliferative urethritis

Urethral histopathology	Number	ABUC+	Bladder mucosa culture+	Urethral mucosa culture+	FISH+	AB >24 hours
Lymphocytic $\pm$ plasmacytic	9	2/7	0/3	1/2	3/5	6/8
Lymphocytic $\pm$ plasmacytic, neutrophilic	6	1/6	0/4	1/1	2/4	5/6
Pleocellular	4	2/2	0/1	1/1	1/2	1/4
Neutrophilic	3	1/3	...	...	1/2	1/3
Total	22	6/18	0/8	3/4	7/13	13/21

Abbreviations: ABUC, aerobic bacterial urine culture; FISH, fluorescent in situ hybridization; +, the presence of bacteria on culture or FISH analysis; AB > 24 hours, antimicrobials administered to the dog for at least 24 hours or more before biopsy and culture being performed.



**FIGURE 2** Representative histopathology results. (A) Hematoxylin and eosin (H&E) stain (magnification,  $\times 200$ ) of a urethral tissue sample from a dog with pronounced lymphocytic-plasmacytic (LP) inflammation. Aerobic bacterial urine culture and bladder tissue culture were both negative in this dog. (B) Lymphocytic-plasmacytic neutrophilic (LPN) inflammation seen in a dog with a positive urine culture result for *Enterococcus faecium* (H&E, magnification,  $\times 200$ ). (C) Pleocellular inflammation (H&E, magnification,  $\times 200$ ). This sample displays LP and histiocytic inflammation; bacteria were also visible histopathologically within a urethral plaque lesion (not shown). Solid arrows indicate the epithelial layer; hatched arrows indicate the submucosa

both within the plaque lesion and in discrete clusters within the bladder epithelium; ABUC in that dog had mixed growth, including *S. pseudintermedius*. All 4 dogs with positive staining for species-specific pathogens had adherent and invasive bacteria visualized on FISH.

Gram staining was negative in 12 of 13 (92%) dogs in which sufficient tissues remained for analysis. Large numbers of gram-positive cocci were noted in a urethral plaque lesion in a single dog (where intralésional bacteria were visualized on histopathology); however, insufficient urethral tissues remained in that case to evaluate whether bacteria could also be seen within urethral mucosa. Gram staining was negative in all 5 control dogs.

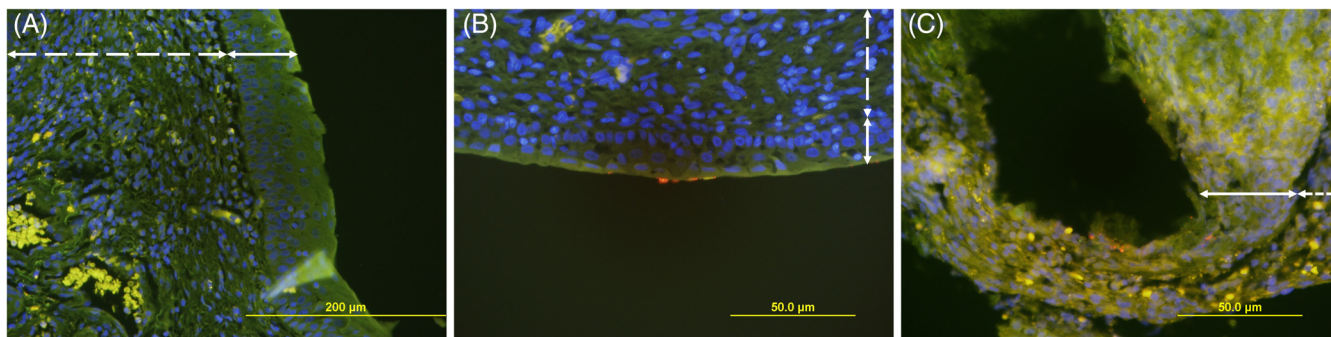
## 4 | DISCUSSION

The present study of 22 dogs with PU utilized FISH analysis to probe for mucosally associated bacteria in urethral tissue biopsies of dogs with PU. We have shown that a variety of types of urethral inflammation can be present in dogs with PU. Contrary to our hypothesis, there was no apparent association between the type of urethritis and the presence or absence of bacteria on ABUC, tissue culture, or FISH.

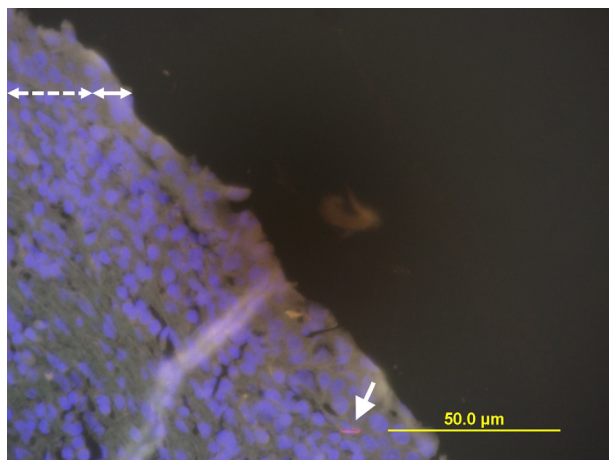
Although 54% of urethral specimens harbored deep-seated bacterial infection via FISH, corresponding ABUC were positive in only 3 of 7 FISH+ dogs. Urethral bacterial cultures were more often positive than bladder tissue cultures, even when obtained simultaneously from the same dog. Overall, these data suggest that urine and bladder tissue cultures underestimate the true prevalence of bacterial colonization of the urethra; both urethral tissue culture and urethral FISH analysis might provide useful complementary diagnostics for dogs with biopsy-confirmed PU in which a bacterial etiology is suspected.

All 4 dogs with pathogen-specific FISH+ staining had adherent and invasive bacteria. These dogs were positive for *E. coli* (2 dogs), *Enterococcus* (1 dog), and *Staphylococcus* (1 dog), all of which have the ability to invade the uroepithelium.<sup>8-12</sup> If a causative role of bacteria exists, our findings suggest that the syndrome of PU in some dogs might be a manifestation of a severe inflammatory response to invasion of uroepithelial tissues by a variety of pathogenic bacteria, rather than a pathogen-specific response.

Abnormal and inflamed urethral tissue in dogs could be prone to bacterial colonization. Although 16S rRNA techniques have been utilized to document a number of gram-positive bacterial species in men with urethritis,<sup>13</sup> these pathogens might colonize some patients because of the changes this disease process causes.<sup>14,15</sup> Thus, it is



**FIGURE 3** Representative fluorescent in situ hybridization (FISH) analysis results. (A) Negative FISH analysis, from same dog as in Figure 2A (magnification,  $\times 200$ ). (B) Superficially, adherent bacteria visualized on FISH; morphology difficult to ascertain (magnification,  $\times 400$ ), from same dog as in Figure 2B. (C) Adherent and invasive bacteria, with a mixture of cocci and short rods (magnification,  $\times 200$ ), from same dog as in Figure 2C. FISH analysis stains: blue, 4',6'-diamidino-2-phenylindole (nuclear stain); green, anti-vimentin (for tissue architecture); red, EUB338-Cy3 (16S rRNA probe, bacterial stain). Solid arrows indicate the epithelial layer; hatched arrows indicate the submucosa

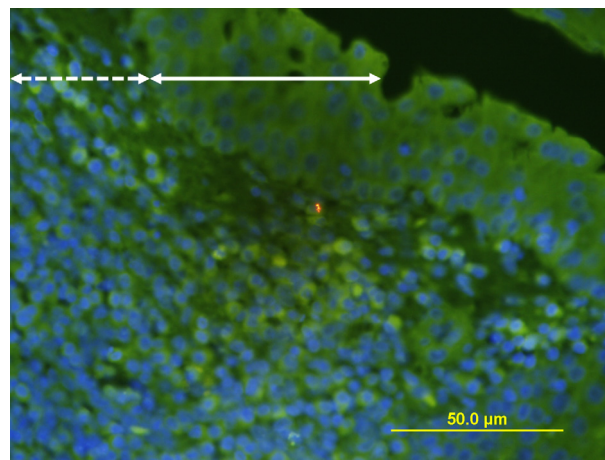


**FIGURE 4** Pathogen-specific fluorescent in situ hybridization (FISH) staining for *Escherichia coli* (magnification,  $\times 400$ ); single positive-staining rod visible within urethral mucosa (arrow). Aerobic bacterial urine culture was also positive for *E. coli* in this dog, despite receiving treatment with amoxicillin-clavulanic acid for  $>24$  hours at the time of biopsy. FISH analysis stains: blue, 4',6-diamidino-2-phenylindole (nuclear stain); green, anti-vimentin (for tissue architecture); red, *E. coli*-specific 16S rRNA probe. Solid arrows indicate the epithelial layer; hatched arrows indicate the submucosa

difficult to say with certainty whether bacteria observed in specimens from dogs incited the development of proliferative urethral tissue or whether their colonization was a consequence of the aberrant proliferative tissue itself. FISH analysis of normal dog urethral tissue did not consistently show bacterial colonization, with just 1 of 5 control specimens showing bacteria that were adherent but not invasive; this sample was collected at necropsy and might represent a contaminant, although true bacterial adherence cannot be ruled out. Broader studies of normal dog's urethral tissue could help to clarify this finding.

The lack of consistent association between some urethral FISH results and urine and urethral/bladder tissue culture results in the present study suggests that aerobic culture methods might underestimate bacterial colonization of urogenital tissues. Relapsing bacterial cystitis has been hypothesized to be due to intracellular bacterial communities (IBC), which can emerge days to weeks after cessation of antimicrobial treatment.<sup>11</sup> This has been described in uropathogenic *E. coli* (UPEC), which forms intracellular colonies just under the surface of the superficial urothelium.<sup>10</sup> IBC play a critical role in the pathogenesis of UPEC by providing a reservoir where massive replication can occur.<sup>11,16,17</sup> However, our study has not demonstrated that isolated intraurethral bacteria were intracellular or extracellular throughout the epithelium.

Not all dogs of the present study had evidence of bacterial infection at the time of biopsy. Nine of 19 dogs (47%) that underwent cystoscopy had no evidence of infection on ABUC, tissue culture, or FISH analysis; however, 8 of 9 dogs were receiving antimicrobials at the time of biopsy, complicating interpretation. Although chronic bacterial infection might play an important role in many cases of PU, it does not completely explain its pathogenesis. PU is often a clinical "visual diagnosis" made during cystoscopy that is then subcategorized via histopathology after urinary neoplasia has been excluded. It is probable that more than 1 underlying mechanism contributes to the



**FIGURE 5** Pathogen-specific fluorescent in situ hybridization (FISH) staining for *Staphylococcus* (magnification,  $\times 400$ ); cluster of positive-staining cocci visualized within urethral mucosa (same dog as in Figures 2C and 3C). *Staphylococcus pseudintermedius* was cultured from both aerobic bacterial urine culture and urethral tissue in this dog. FISH analysis stains: blue, 4',6-diamidino-2-phenylindole (nuclear stain); green, anti-vimentin (for tissue architecture); red, *Staphylococcus*-specific 16S rRNA probe. Solid arrows indicate the epithelial layer; hatched arrows indicate the submucosa

formation of proliferative urethral intraluminal tissue. However, a limitation of our study was the low number of cases identified; in searching 30 years of electronic records at a large veterinary teaching hospital, only 23 cases were identified.

We hypothesized there would be an association between the specific type of histopathologic inflammation and the presence or absence of bacteria detected via ABUC, tissue cultures, and FISH analysis of urethral tissues; however, positive urine and tissue cultures were noted for all categories of inflammation. We anticipated that the presence of bacteria would incite a neutrophilic or granulomatous inflammatory response; just 1 of 3 dogs with purely neutrophilic urethritis had a positive ABUC at the time of biopsy (*E. coli*), with no FISH analysis performed (and no history of antimicrobial administration). Of the other 2 cases, 1 had adherent/invasive rod-shaped bacteria visualized (also with no prior antimicrobial administration) and the other was FISH negative, while receiving treatment with trimethoprim-sulfamethoxazole for  $>24$  hours. Thus, neutrophilic inflammation was not associated directly with a bacterial etiology in this limited number of cases, although antimicrobial administration complicates interpretation of these data. Despite the historical nomenclature of "granulomatous urethritis," purely granulomatous inflammation was not present in any dog and a component of granulomatous inflammation was noted in only 2 of 22 (9%) cases.

The majority of biopsy specimens (19/22, 86%) contained at least some degree of LP inflammation, including all 4 pleocellular samples. This might suggest an underlying sterile inflammatory condition, as a previous case report has suggested.<sup>1</sup> However, LP inflammation in our study did not necessarily indicate an absence of bacteria on ABUC or FISH analysis, and its presence cannot be taken to imply a sterile or immune-mediated process on the basis of these data. Of 12 dogs with negative ABUC at the time of biopsy collection, 5 had LP inflammation, 2 had neutrophilic inflammation, and 5 dogs had LPN

inflammation. The presence of urolithiasis also did not seem to affect histopathologic results, with a wide variety of results in the 7 dogs with concurrent or previous urolithiasis. Thus, it appears that the type of urethral inflammation in PU is nonspecific and must be interpreted in combination with other findings.

Given the small number of cases and extended time span of the study period, it is difficult to make any conclusions regarding breed susceptibility; nonetheless, nearly one-quarter (5/22) of the dogs in the present study were German Shepherd dogs, and they were over-represented in the study population as compared to the hospital population at large. All 3 Labrador Retrievers in the study population were male, and they made up nearly half of the male population of the study. Although the majority (74%) of dogs were >20 kg, this likely partially represents sample bias, as obtaining cystoscopic biopsies is more challenging in smaller dogs (particularly small male dogs), and only 5 dogs in our study had biopsies obtained at necropsy. Cystoscopic findings in the present study were generally similar to those that have been described in other reports of PU. An unexpected finding was the relatively large number of dogs with documented urolithiasis (7/22, 32%), of which only 2 were composed of struvite. Histopathology findings in these dogs might have been primarily because of stone formation, with subsequent regional urethral inflammation and tissue proliferation; however, it is equally plausible that tissue proliferation occurred before stone formation, predisposing these dogs to urethral obstruction.

Our study is retrospective in nature, and definitive conclusions about cause and effect are not possible. Prospective studies would be needed to document and treat deep-seated bacterial infections, monitor for resolution of clinical signs, and obtain urethral biopsies for culture and FISH analyses after treatment; a similar approach has been utilized in previous studies utilizing this diagnostic for granulomatous colitis in Boxer dogs.<sup>6</sup> Data collection over an extended time period is another limitation of our study; inconsistent medical record-keeping, particularly from the older cases, made comparisons difficult. The quality and quantity of biopsy specimens available for review varied greatly, and pinch biopsies might not be reflective of the entire urethral disease process. The use of antimicrobials in many cases means negative culture and FISH results must be interpreted with caution. Cases were managed by various clinicians, which impacted treatment decisions, cystoscopic samples obtained, and diagnostic results available. In addition, only 13 of 22 (59%) cases had sufficient formalin-fixed paraffin-embedded tissue available for FISH analysis, limiting conclusions regarding deep-seated bacteria in the remaining 9 cases. Finally, a larger control population is also needed, that is age-matched and breed-matched.

In conclusion, although the present study further elucidates the syndrome of PU in dogs, it failed to demonstrate a consistent association between the type of urethral inflammation and the presence or absence of bacterial infection. Despite the former name of this syndrome, purely granulomatous urethritis was not observed in any dog. Bladder tissue culture and Gram staining were of limited use in this population of dogs. FISH appears to be a useful complementary modality to urine and urethral tissue cultures in identifying bacterial invasion into urethral tissue; this could impact treatment decisions, particularly with regard to antimicrobial selection and treatment

duration. Further prospective study is warranted to compare histopathology with FISH analysis and compare treatment outcomes.

## ACKNOWLEDGMENTS

This work was completed at the University of California, Davis, in Davis, California.

## CONFLICT OF INTEREST DECLARATION

Jane Sykes serves as Associate Editor for the Journal of Veterinary Internal Medicine. She was not involved in review of this manuscript.

## OFF-LABEL ANTIMICROBIAL DECLARATION

Authors declare no off-label use of antimicrobials.

## INSTITUTIONAL ANIMAL CARE AND USE COMMITTEE (IACUC) OR OTHER APPROVAL DECLARATION

Authors declare no IACUC or other approval was needed.

## HUMAN ETHICS APPROVAL DECLARATION

Authors declare human ethics approval was not needed for this study.

## ORCID

Moria A. Borys  <https://orcid.org/0000-0001-5058-1243>

Jodi L. Westropp  <https://orcid.org/0000-0003-1287-3979>

## REFERENCES

1. Hostutler RA, Chew DJ, Eaton KA, DiBartola SP. Cystoscopic appearance of proliferative urethritis in 2 dogs before and after treatment. *J Vet Intern Med.* 2004;18:113-116.
2. White RN, Davies JV, Gregory SP. Vaginourethroplasty for treatment of urethral obstruction in the bitch. *Vet Surg.* 1996;25:503-510.
3. Salinardi BJ, Marks SL, Davidson JR, Senior DF. The use of a low-profile cystostomy tube to relieve urethral obstruction in a dog. *J Am Anim Hosp Assoc.* 2003;39:403-405.
4. Hill TL, Berent AC, Weisse CW. Evaluation of urethral stent placement for benign urethral obstructions in dogs. *J Vet Intern Med.* 2014;28:1384-1390.
5. Sycamore KF, Poorbaugh VR, Pullin SS, Ward CR. Comparison of urine and bladder or urethral mucosal biopsy culture obtained by transurethral cystoscopy in dogs with chronic lower urinary tract disease: 41 cases (2002 to 2011). *J Small Anim Pract.* 2014;55:364-368.
6. Clinical and Laboratory Standards Institute. VET01-S: performance standards for antimicrobial disk and dilution susceptibility tests for bacteria isolated from animals: approved standard. 2008. Available from [www.clsi.org](http://www.clsi.org).
7. Simpson KW, Dogan B, Rishniw M, et al. Adherent and invasive *Escherichia coli* is associated with granulomatous colitis in boxer dogs. *Infect Immun.* 2006;74:4778-4792.
8. Horsley H, Malone-Lee J, Holland D, et al. *Enterococcus faecalis* subverts and invades the host urothelium in patients with chronic urinary tract infection. *PLoS One.* 2013;8:e83637.

9. Anderson GG, Martin SM, Hultgren SJ. Host subversion by formation of intracellular bacterial communities in the urinary tract. *Microbes Infect.* 2004;6:1094-1101.
10. Anderson GG, Palermo JJ, Schilling JD, Roth R, Heuser J, Hultgren SJ. Intracellular bacterial biofilm-like pods in urinary tract infections. *Science.* 2003;301:105-107.
11. Mulvey MA, Schilling JD, Hultgren SJ. Establishment of a persistent *Escherichia coli* reservoir during the acute phase of a bladder infection. *Infect Immun.* 2001;69:4572-4579.
12. Szabados F, Kleine B, Anders A, et al. *Staphylococcus saprophyticus* ATCC 15305 is internalized into human urinary bladder carcinoma cell line 5637. *FEMS Microbiol Lett.* 2008;285:163-169.
13. You C, Hamasuna R, Ogawa M, et al. The first report: an analysis of bacterial flora of the first voided urine specimens of patients with male urethritis using the 16S ribosomal RNA gene-based clone library method. *Microb Pathog.* 2016;95:95-100.
14. Liu L, Yang J, Lu F. Urethral dysbacteriosis as an underlying, primary cause of chronic prostatitis: potential implications for probiotic therapy. *Med Hypotheses.* 2009;73:741-743.
15. Shaged AR, Shoskes DA. Oxidative stress in prostatic fluid of patients with chronic pelvic pain. *J Androl.* 2000;21:669-675.
16. Justice SS, Hung C, Theriot JA, et al. Differentiation and developmental pathways of uropathogenic *Escherichia coli* in urinary tract pathogenesis. *Proc Natl Acad Sci U S A.* 2004;101:1333-1338.
17. Blango MG, Mulvey MA. Persistence of uropathogenic *Escherichia coli* in the face of multiple antibiotics. *Antimicrob Agents Chemother.* 2010;54:1855-1863.

**How to cite this article:** Borys MA, Hulsebosch SE, Mohr FC, et al. Clinical, histopathologic, cystoscopic, and fluorescence in situ hybridization analysis of proliferative urethritis in 22 dogs. *J Vet Intern Med.* 2019;33:184-191. <https://doi.org/10.1111/jvim.15349>