



## Alterations of Antioxidant Status and Mitochondrial Succinate Dehydrogenase Activity in the Liver of Wistar Strain Albino Rats Treated with by Ethanol Extracts of *Annona senegalensis* Pers (Annonaceae) Stem Bark

Rahmat Adetutu Adisa<sup>1</sup>, Naimat Kolawole<sup>1</sup>, Lateef A., Sulaimon<sup>1</sup>, Bathlomew Brai<sup>2</sup> and Abraham Ijaola<sup>1</sup>

<sup>1</sup>Department of Biochemistry, Faculty of Basic Medical Sciences, College of Medicine, Idi-araba, University of Lagos, Lagos, Nigeria

<sup>2</sup>Federal University, Oye -Ekiti, Ekiti State, Nigeria

### Abstract

Numerous ethnomedicinal uses have been attributed to different parts of *Annona senegalensis* (ASE), including its uses as food and food additives. The present study investigated toxicological and antioxidant effects of 28 days administration of ethanol extracts of ASE stem bark to Wistar strain albino rats. Acute toxicity test was done to determine lethal dose in Wistar rats while sub-acute toxicity test was conducted on rats divided into four groups (A - control, B - 50 mg/kg, C - 100 mg/kg, D - 150 mg/kg, respectively and treated for 28 days. Oxidative stress markers in liver and kidney as well as hepatic succinate dehydrogenase activity in the mitochondrial and post mitochondrial fractions (PMF) were evaluated. The LD<sub>50</sub> value of ASE was > 2,000 mg/kg. White blood cell counts gradually increased, but red blood cell counts and haematocrits level decreased significantly ( $p < 0.05$ ) by about 50%. Liver enzymes in the serum and mitochondrial succinate dehydrogenase activity increased significantly ( $p < 0.05$ ). Superoxide dismutase and catalase activities also increased in liver mitochondria and PMF while malondialdehyde (MDA) and reduced glutathione levels increased only in the PMF. Furthermore, only MDA levels increased significantly in the kidney after 28 days extract administration. Histopathological examination showed hepatic necrosis and no obvious signs of nephrotoxicity. *Annona senegalensis* is relatively safe, but prolonged ingestion could induce oxidative stress and impair ATP synthesis through the modulation of the activity of mitochondrial succinate dehydrogenase.

**Key words:** *Annona senegalensis*, Toxicity, Oxidative stress, Mitochondrial membrane succinate dehydrogenase

### INTRODUCTION

Medicinal plants contain potentially useful chemical compounds that serve as the basis for manufacturing modern medicines (1). In recent years, the clinical value of herbal medicines has received considerable attention. Plant poi-

soning of animals is a common phenomenon (2,3); some medicinal plants may produce long-term adverse effects such as hepatotoxicity and nephrotoxicity (4). The importance of the active ingredients of plants in agriculture and medicine has stimulated marked scientific interest in the biological activities of these substances (5). One such

Correspondence to: Rahmat Adetutu Adisa, Department of Biochemistry, Faculty of Basic Medical Sciences, College of Medicine, Idi-araba, University of Lagos, P.M.B. 12003, Lagos, Nigeria  
E-mail: radisa22@yahoo.com; radisa@unilag.edu.ng.com

This is an Open-Access article distributed under the terms of the Creative Commons Attribution Non-Commercial License (<http://creativecommons.org/licenses/by-nc/3.0>) which permits unrestricted non-commercial use, distribution, and reproduction in any medium, provided the original work is properly cited.

Abbreviations: ALP, Alkaline phosphatase; ALT, Alanine aminotransferase; ASE, *Annona senegalensis* extract; AST, Aspartate aminotransferase; CAT, Catalase; DCIP, Dichlorophenolindophenol; DTNB, 5,5'-dithio-bis-2-nitrobenzoic acid; GSH, Glutathione; H<sub>2</sub>O<sub>2</sub>, Hydrogen peroxide; HEPES, 4-(2 Hydroxy-ethyl)-1-piperazine ethanesulfonic acid; LD<sub>50</sub>, Median lethal dose; MDA, Malondialdehyde; PMF, Post mitochondrial fraction; PMS, Phenazine methosulfate; ROS, Reactive oxygen species; SDH, Succinate dehydrogenase; SOD, Superoxide dismutase; TP, Total protein.

plant with an abundance of phytochemicals is *Annona senegalensis* Persoon (Annonaceae; ASE).

ASE is a shrub or small tree about 2-6 m tall; it is mostly found in the savanna and parts of the tropical rain-forest regions. It is also found in several African countries, including Senegal, Nigeria, Cape Verde, Sudan, and South Africa and is especially common in northern Nigeria, primarily in Nasarawa, Kaduna, Kano, Plateau, Niger, and Abuja (6). It is commonly known as African custard apple, wild custard apple, and wild soursop (7,8) and has aromatic flowers, which are used to flavor food. The ripe fruit is yellow in color and has a sweet edible jelly with a pleasant odor and pineapple-like taste. The ASE fruit has many local names and is commonly known as “Uburu ocha” (Igbo), “gwandar daajii” (Hausa), “arere” or “abo” (Yoruba), “Ukpokpo” (Igala), “ngonowu” (Kanuri), “uwu” (Idoma), and “mkonokono” (Swahili) (9). It is widely used in ethnomedicine for the treatment of different types of ailments and as such enjoys a great reputation for its immense ethnomedicinal value. ASE extract has been reported to have antibacterial (10) and antidiarrheal activities (11). Furthermore, its whole root extract has been reported to have anticonvulsant effects (12) and has been investigated for analgesic, anti-inflammatory (13,14), trypanocidal (15,16), and anti-snake venom activities (9). Essential oils from the leaves (linalool) and fruits (car-3-ene) of ASE have also exhibited antibacterial activity (17). Further, ASE decoction is used in the treatment of sleeping sickness in northern Nigeria (18); it is also used for the treatment of cancer (19,20) and malarial infection (21) in folk medicine. Recently, anticonvulsant, muscle relaxant, and sedative effects of ASE root bark extract were reported (22). Neuropharmacological, antioxidant, and hepatoprotective activities of ASE leaf extract have also been reported (23,24). The stem bark of ASE has traditionally been used for the treatment of snake bite, hernia, and open sores (25,26). It has also been reported to possess antimicrobial and anti-trypanosomal properties (27). Terpene and flavonoid-containing essential oils with antimicrobial activity have also been isolated from the stem bark of ASE (28,29). Nevertheless, compared to the literature on the other parts of the plant (30), there is a dearth of scientific evidence-based information on the pharmacological and toxicological activities of ASE stem bark. Thus, in the present study, we investigated the hepatotoxicity and antioxidant potential of ASE stem bark extracts administered to Wistar strain albino rats for 28 days.

## MATERIALS AND METHODS

**Reagents and chemicals.** The following chemicals used for this experiment were of analytical grade and purchased from Sigma Aldrich: 4-(2-hydroxyethyl)-1-piperazine ethanesulfonic acid (HEPES), mannitol, potassium

hydroxide, bovine serum albumin, potassium chloride, sodium potassium tartrate, sodium succinate, sodium bicarbonate, and 5% trichloroacetic acid. N-Hexane, ethanol, and 10% formalin were from Thermo Fisher Scientific (Loughborough, UK). Other reagents and chemicals used were of analytical grade.

**Preparation of stem bark extract of ASE.** Fresh stem barks of the ASE plant were collected and authenticated at the herbarium of the Botany department of the University of Lagos (Voucher number LuH 6184). The stems were dried on a laboratory tray for about 2 weeks after which the barks were peeled off and dried further in an oven at 40°C for about 12 hr until they were completely dry. The dried barks were milled into a powder and defatted with n-hexane by using a Soxhlet apparatus. The marc obtained was allowed to dry before subsequent extraction with 95% ethanol by using the Soxhlet apparatus. The extract solution obtained was evaporated at 45°C by using a rotary evaporator and the residue, ASE extract, was collected and weighed.

**Animals maintenance.** Forty male Wistar strain albino rats weighing 120-150 g were obtained from the Animal House, College of Medicine, University of Lagos, Nigeria, and were kept in well-ventilated standard plastic cages. The rats were acclimatized for a period of 2 weeks and maintained on standard rat pellets (Pfizer Livestock Feeds, Lagos, Nigeria) and water *ad libitum*. All experiments were conducted without anesthesia, and the protocol was in conformity with the guidelines of the National Institute of Health (NIH publication 85-23, 1985) for laboratory animal care and use.

**Acute toxicity test.** The acute toxicity and lethality of ASE extract were determined using the method described by Lorke (31). Briefly, twelve male rats were randomly divided into four groups (I, II, III, and IV; n = 3 per group) and were orally administered distilled water, and 500, 1,000, and 2,000 mg/kg ASE, respectively. The animals were observed at 2, 6, 12, and 24 hr for behavioral changes, itching, pupil dilation, and death.

**Experimental design and treatment.** Twenty male rats were divided into four groups of five rats each (A, B, C, and D). Male rats solely were used in this study of the toxicological or toxicokinetic properties of the compounds because they are likely to be more sensitive than females would be due to hormonal influences (32). Animals in group A (control) received 10 mL/kg body weight of normal saline, and groups B, C, and D were given 50, 100, and 150 mg/kg body weight of ASE. The extract was prepared fresh each morning and administered through oral gavage for 28 days. The initial weights of the animals were recorded just before extract administration and before sac-

rifice on day 29. The rats were fasted overnight before they were sacrificed by cervical dislocation and were dissected to excise the liver and kidneys. The tissues were rinsed in 1.15% KCl, blotted, and weighed immediately after excision.

**Blood collection and tissue preservation.** Whole blood samples were obtained by retro-orbital puncture using capillary tubes just before sacrifice. The samples were collected in labeled lithium heparinized bottles for hematological profile analysis and in ethylene diamine tetraacetic acid anti-coagulated bottles for blood chemistry assays. Plasma was obtained by spinning whole blood samples for 10 min at 4,000 rpm in a Cencom Bench centrifuge. The supernatant (plasma) obtained was separated and kept frozen for the estimation of total protein (TP), alkaline phosphatase (ALP), alanine aminotransferase (ALT), and aspartate aminotransferase (AST) activities as well as levels of bilirubin, urea, and creatinine. A portion of the weighed liver and kidney were separately maintained using 10% buffered-formaldehyde (formalin) solution to preserve the tissues for histopathological evaluation.

**Hematological analysis.** Hematological parameters including red blood cell count, white blood cell count, packed cell volume, hemoglobin level, lymphocyte count, and neutrophil count were determined using the BC-3200 Auto Hematology analyzer, (Mindray Medical International Ltd, Shenzhen, China).

**Preparation of kidney homogenate and liver subcellular fractions.** The other portion of the excised liver and second kidney from the rats were washed separately with 1.15% KCl several times to remove blood, blotted, weighed, and suspended in 0.25 M sucrose (ice-cold) to prepare a 5% homogenate with a Potter-Elvehjem glass homogenizer. The kidney homogenate was aliquoted and stored at  $-80^{\circ}\text{C}$  until required for use. The liver homogenate was centrifuged in a cold MSE centrifuge at 2,300 rpm for 5 min to separate the nuclear fraction and cell debris. Mitochondria were pelleted from the supernatant obtained by centrifugation at 12,000 rpm for 15 min. The supernatant (post-mitochondrial fraction [PMF]) obtained was aliquoted and kept frozen while the mitochondrial pellets were washed twice with sucrose buffer at 10,000 rpm for 15 min each time. The washed mitochondria were immediately resuspended in 0.25 M sucrose buffer, aliquoted, and kept frozen at  $-80^{\circ}\text{C}$  (33) until use.

**Determination of liver and kidney function parameters.** Plasma ALP, ALT, and AST activities, and urea, creatinine, and direct bilirubin levels were determined using the Roche Hitachi 912 Chemistry Auto-Analyzer (GMI Inc., MN, USA).

**Assay of mitochondrial succinate dehydrogenase activity.** Succinate dehydrogenase (SDH) activity in isolated mitochondria was assayed using the method described by King (34). Briefly, the reaction mixture containing 0.2 M phosphate buffer, pH 7.8 (0.375 mL), 0.045 M KCN (0.05 mL), 0.6 M succinate (0.1 mL), 0.0015 M dichlorophenolindophenol (DCIP, 0.05 mL), 0.009 M phenazine methosulfate (PMS, 0.15 mL), and distilled water (2.95 mL) was added into a 4-mL spectrophotometer glass cuvette. The reaction was started by the addition of 0.05 mL of mitochondrial suspension. The change in absorbance at 600 nm ( $\Delta 600$  nm) was recorded at 1-min intervals by using a Beckman DU-640 spectrophotometer. The  $\Delta 600$  nm was converted to mmols of succinate oxidized by multiplying  $\Delta 600$  nm by 0.0476. Enzyme activity was expressed as nmol succinate oxidized/min and specific activity as units/mg of mitochondrial protein.

**Analysis of membrane macromolecular composition.** Mitochondrial membrane phospholipid concentrations were determined as described by Chen *et al* (35). Mitochondrial membrane solution (0.5 mL) was added to 9.5 mL of ethanol-ether and heated to  $80^{\circ}\text{C}$ . One milliliter of sulfuric acid in perchloric acid was added to the mixture followed by gentle heating for 45 min. The reaction mixture was cooled and 1 mL of distilled water was added and boiled for 15 s. To 4 mL of the reaction mix was added 4 mL of a mixture of 6 N sulfuric acid, 2.5% of ammonium molybdate, and 10% ascorbic acid (v/v). The mixture was incubated for 2 min at  $37^{\circ}\text{C}$  and absorbance was read spectrophotometrically at 600 nm. Cholesterol level was determined using Radox Kits and protein concentrations were determined as described by Lowry *et al.* (36) by using bovine serum albumin as a standard.

**Determination of antioxidant parameters in the mitochondria, PMF, and kidney homogenate.** Superoxide dismutase (SOD) activity was determined by its ability to inhibit the auto-oxidation of epinephrine at pH 10.2 and was monitored based on an increase in absorbance at 480 nm as described by Misra and Fridovich (37). The activity of mitochondrial MnSOD was measured in the presence of 1 mM KCN, and the cytosolic (PMF) Cu, Zn, and SOD activities were determined in the absence of KCN (38). One unit of SOD activity was defined as the amount of enzyme required for 50% inhibition of the oxidation of epinephrine to adrenochrome at  $480\text{ nm min}^{-1}$ . The reaction mixture (3 mL) contained 2.5 mL of 0.05 M sodium carbonate buffer (pH 10.2); 0.2 mL of kidney homogenate, PMF, or mitochondria (1:10) (containing SOD); and 0.3 mL of 0.3 mM epinephrine used to initiate the reaction. The reference cuvette contained 2.5 mL of buffer, 0.3 mL of substrate (epinephrine), and 0.2 mL of water. Enzyme activity was determined by measuring the change

in absorbance at 480 nm for 5 min.

Reduced glutathione (GSH) level was determined using Ellman's reagent, 5,5'-dithio-bis-2-nitrobenzoic acid (DTNB), as described by Sedlak and Lindsay (39) and Jollow *et al* (40). Briefly, 0.2 mL of the sample was mixed with 1.8 mL of distilled water and 3 mL of precipitating reagent (4% sulfosalicylic acid), and the mixture was allowed to stand for 10 min before centrifugation at 2,300 rpm for 5 min. The supernatant (0.5 mL) obtained was pipetted into 4 mL of 0.1 M phosphate buffer (pH 7.4) followed by 0.5 mL of Ellman's reagent. The blank was prepared with 4 mL of 0.1 M phosphate buffer (pH 7.4), 0.5 mL of diluted precipitating solution, and 0.5 mL of Ellman's reagent. The absorbance was read within 20 min of color development at 412 nm against the blank by using a spectrophotometer. The reduced GSH concentration was proportional to the absorbance at 412 nm.

Catalase (CAT) activity was determined as described by Sinha (41). The sample (0.1 mL) was mixed with 4.9 mL of distilled water. The assay mixture contained 4 mL of 0.2 M H<sub>2</sub>O<sub>2</sub> and 5 mL of 0.01 M phosphate buffer in a 10-mL flat bottom flask. One milliliter (1 mL) of the earlier diluted mitochondria, PMF, or kidney homogenate was rapidly mixed with the reaction mixture by gentle swirling motion at room temperature. The assay mixture (1 mL) was added to a test tube containing 2 mL of dichromate/acetic acid reagent at 60-s intervals for 3 min and heated for 10 min in boiling water. The mixture was allowed to cool and the absorbance was measured with a spectrophotometer at 570 nm.

The extent of lipid peroxidation in mitochondrial fractions and PMFs was determined using standard methods described by Buege and Aust (42) as follows. An aliquot of 0.4 mL of the mitochondria, PMF, and kidney homogenate was mixed with 1.6 mL of Tris KCl buffer. Then 0.5 mL of 30% TCA was added followed by 0.5 mL of 0.75% TBA and the mixture was placed in a water bath for 1 hr at a temperature of 90-95°C. Then, the mixture was cooled using ice and centrifuged at 3,000 rpm for 15 min. The clear pink supernatant was collected and absorbance was measured against a reference blank of distilled water at 532 nm by using a spectrophotometer.

**Histopathological examination.** A portion of liver and kidney tissues from each group was collected and preserved in 10% neutral-buffered formalin for histopathological studies. The tissues were processed and embedded in paraffin wax and thin sections (thickness, 5-6 µm) of liver tissue were cut before staining with hematoxylin and eosin. These thin sections of liver and kidney were made into permanent slides and examined photomicroscopically.

**Statistical analysis.** Data were statistically computed using Graph Pad Prism 6 Software (Graphpad Software

Inc., CA, USA) and expressed as mean ± SEM values. Differences between mean values were further analyzed using Tukey Honest Significant Difference (Tukey's HSD) test and values of  $p < 0.05$  were considered significant.

## RESULTS

**Acute toxicity.** The median lethal dose (LD<sub>50</sub>) was > 2,000 mg/kg as no death was recorded after 24 hr, as shown in Table 1, for the ethanol extract of ASE and there were no abnormal behavioral activities.

**Body and organ weights.** Table 2 shows the effects of 28 days of oral administration of ASE on body weight gain and relative organ weights of male Wistar rats. The percentage body weight gain of the rats after 28 days of oral administration with ASE indicates that the animals gained weight but the percentage weight gain decreased as the doses of ASE administered increased. In fact, the rats administered 150 mg/kg ASE showed only a 0.56% increment in their weights compared to 19.4 and 17.5% weight gain shown by the animals treated with 50 and 100 mg/kg ASE, respectively. However, compared to the controls, rats administered different doses of ASE over the 28 days period showed no significant ( $p > 0.05$ ) differences in the relative liver and kidney weights.

**Table 1.** Mean mortality during acute exposure to ethanol extract of *A. senegalensis* stem bark

Treatment	Death/Live ratio
I	0/3
II	0/3
III	0/3
IV	0/3

LD<sub>50</sub> value of ethanol extract of stem bark extracts of *A. senegalensis* > 2,000 mg/kg body weight, I: Control group; II, III and IV: 500 mg/kg, 1,000 mg/kg and 2,000 mg/kg of *Annona senegalensis*, respectively.

**Table 2.** Effect of 28 days oral administration of *Annona senegalensis* extract on body and relative organ weight of male wistar rats

Treatments	% Weight gain	Relative weight (g/g)	
		Liver	Kidney
A	20.0	0.033 ± 0.001	0.0062 ± 0.0006
B	19.40	0.028 ± 0.002	0.0059 ± 0.0005
C	17.49	0.030 ± 0.002	0.0058 ± 0.0007
D	0.56*	0.031 ± 0.007	0.0067 ± 0.0015

Data are expressed as mean ± standard deviation. ASE = *Annona senegalensis* extract. Values with \* are significantly ( $p < 0.05$ ) different from control. (A) Control group, (B, C, D) 50 mg/kg, 100 mg/kg and 150 mg/kg. *A. senegalensis* groups, respectively.

**Biochemical indices of hepatic and kidney toxicity.**

The biochemical indices in the plasma of Wistar rats administered ASE for 28 days are as presented in Table 3. Concentration-dependent increases were observed in the activities of ASP, ALT, and ALP and bilirubin levels. Significant increases ( $p < 0.05$ ) of 44% in ALT and ALP activities as well as a 27% increase in bilirubin levels were observed in rats treated with 150 mg/kg body weight of the extract. Compared to the control group, the treatment groups showed no significant ( $p > 0.05$ ) differences in the activity of AST and levels of creatinine and urea (Table 3).

**Hematological profile.** The hematological profile of the rats treated with ASE is shown in Table 4. Compared

to the control group, the groups that received 150 mg/kg body weight of ASE showed a significant increase ( $p < 0.05$ ) in white blood cell counts (25%). Red blood cell count and hematocrit level of all the treated groups decreased significantly ( $p < 0.05$ ) compared to those of the control group. The other hematological indices showed no significant ( $p > 0.05$ ) changes in the extract-treated rats compared to those in the control group (Table 4).

**Mitochondrial membrane components and SDH activity in ASE extract-treated rats.**

Table 5 shows the activity of SDH and the concentrations of mitochondrial membrane macromolecules after 28 days of ASE extract administration. The activity of SDH increased significantly ( $p <$

**Table 3.** Biochemical parameters in the plasma of Wistar rats administered *A. senegalensis* extracts for 28 days

Parameters	Groups			
	A	B	C	D
AST (U/L)	205.4 ± 5.8	176.8 ± 7.4	203.0 ± 30.9	231.5 ± 25.6*
ALT (U/L)	56.9 ± 6.3	42.5 ± 3.56	66.8 ± 19.2	81.9 ± 19.0*
ALP (U/L)	164.9 ± 9.7	158.4 ± 17.2	179.0 ± 42.9*	236.8 ± 50.3
BIL (µmol/L)	0.98 ± 0.2	0.90 ± 0.20	1.04 ± 0.21	1.24 ± 0.3*
CREAT (µmol/L)	38.6 ± 2.5	41.4 ± 1.9	41.9 ± 2.83	40.7 ± 2.3
UREA (mmol/L)	7.18 ± 0.4	6.02 ± 0.7	7.08 ± 0.71	6.12 ± 0.9

Data are presented as mean ± SEM. Values with \* are significantly ( $p < 0.05$ ) different from control. (A) Control group, (B, C, D, E) 50 mg/kg, 100 mg/kg and 150 mg/kg *Anona senegalensis* groups, respectively. AST: Aspartate Aminotransferase, ALT: Alanine Aminotransferase, ALP: Alkaline Phosphatase, BIL: Bilirubin, CREAT: Creatinine, Grps: Groups.

**Table 4.** Hematological indices in wistar rats administered *A. senegalensis* for 28 days

Parameters	Groups			
	A	B	C	D
WBC <sup>α</sup>	6.46 ± 1.21	6.04 ± 1.24	6.02 ± 0.55	8.06 ± 1.34*
LYMPH <sup>β</sup>	71.62 ± 1.93	68.94 ± 2.06	69.54 ± 1.73	70.36 ± 1.58
GRAN <sup>β</sup>	18.50 ± 1.42	22.68 ± 1.69	20.18 ± 0.92	21.04 ± 1.40
HGB <sup>μ</sup>	8.80 ± 0.84	7.84 ± 0.98	7.64 ± 0.65	7.88 ± 0.50
RBC <sup>ε</sup>	0.34 ± 0.11	0.16 ± 0.01*	0.14 ± 0.04*	0.16 ± 0.01*
HCT <sup>β</sup>	2.50 ± 0.67	1.1 ± 0.07*	1.06 ± 0.31*	1.22 ± 0.07*
MPV <sup>α</sup>	8.78 ± 0.10	8.60 ± 0.15	8.70 ± 0.11	8.62 ± 0.23

Data are presented as mean ± SEM. Values with \* are significantly ( $p < 0.05$ ) different from control. (A) Control group, (B, C, D, E) 50 mg/kg, 100 mg/kg and 150 mg/kg, respectively. WBC, White Blood Cell Counts; LYMPH, Lymphocytes; GRAN, Granulocytes; HGB, Hemoglobin; RBC, Red Blood Cell Counts; HCT, Hematocrit; MPV, Mean Platelet Volume; PDW, Platelet Distribution Width, Grps - Groups.  $\alpha = (1 \times 10^9 \text{ cells/L})$ ,  $\mu = \text{g/dL}$ ,  $\beta = \%$ ,  $\epsilon = (1 \times 10^{12} \text{ cells/L})$ .

**Table 5.** Liver mitochondrial membrane components and succinate dehydrogenase activity after 28 days administration of ethanolic extracts of *Annona senegalensis*

Groups	SDH (U/mg protein)	Total protein (g/dL)	Cholesterol (mmol/L)	Phospholipid (mg/dL)
A	0.8 ± 0.49	91.9 ± 6.21	134.4 ± 8.3	7.3 ± 1.11
B	2.8 ± 0.17*	76.0 ± 6.02	205.5 ± 19.0	5.0 ± 1.55
C	3.1 ± 0.07*	83.0 ± 5.83	151.4 ± 18.0	6.2 ± 1.70
D	3.0 ± 0.03*	86.2 ± 6.43	111.8 ± 13	6.1 ± 2.55

Data are presented as mean ± SEM. Values with \* are significantly ( $p < 0.05$ ) different from control. SDH: Succinate dehydrogenase. (A) Control group, (B, C, D, E) 50 mg/kg, 100 mg/kg and 150 mg/kg *Annona senegalensis* groups, respectively. Grps: Groups.

0.05) in all the treated (50, 100, and 150 mg/kg) groups by 248, 269, and 280%, respectively, compared to that in the control group. No significant difference in SDH activity was observed between groups that received 100 mg/kg and 150 mg/kg body weight of ASE (Table 5). Treatment with the ASE extract increased the levels of membrane cholesterol compared to that associated with the control treatment; however, an increase in the concentrations of the extract to 150 mg/kg body weight of ASE gradually decreased the cholesterol levels to below basal level. On the contrary, the mitochondrial membrane phospholipid level decreased to 31.6% in the 50 mg/kg-treated group compared to that in the control group. In groups treated with concentrations greater than 50 mg/kg (100 and 150 mg/kg body weight) mitochondrial membrane phospholipid level increased by 22% (Table 5).

**Antioxidant status of the liver and kidneys of the ASE extract-treated rats.** Levels of antioxidant parameters, including SOD, CAT, MDA, and GSH, in the liver

mitochondria and PMFs are presented in Table 6, 7, respectively. The levels of GSH in the mitochondria of the extract-treated rats were not significantly ( $p > 0.05$ ) different from those in the control group; however, a 53% increase was observed in the levels of these parameters in the PMF among the 100 and 150 mg/kg body weight extract-treated rats compared to the levels in the control group. The activities of SOD and CAT increased in a concentration-dependent manner in both PMF and mitochondria, with the activities in the PMF being higher. There was no significant ( $p > 0.05$ ) difference in liver mitochondrial GSH and MDA levels between the treatment and the control groups. On the other hand, there was a 53% and 80% increase in the GSH and MDA levels in PMF of the 150 mg/kg body weight extract-treated group compared to that in the control group (Table 6). Furthermore, SOD and CAT activities significantly ( $p < 0.05$ ) increased in the liver mitochondria and PMF of the treatment group compared to those in the control group. In particular, mitochondrial and PMF SOD activity increased by 78% and

**Table 6.** Antioxidant parameters in the liver mitochondria of rats orally administered *A. senegalensis* for 28 days

Groups	GSH (nmole/L)	SOD (U/mg protein)	CAT (U/mg protein)	MDA (nmole/L)
A	2.1 ± 0.37	1.4 ± 0.16	19.7 ± 2.60	0.20 ± 0.03
B	2.2 ± 0.23	1.9 ± 0.47	16.6 ± 1.35	0.25 ± 0.04
C	1.8 ± 0.21	1.9 ± 0.22	23.3 ± 1.90	0.19 ± 0.03
D	2.5 ± 0.18	2.4 ± 0.58*	23.7 ± 3.25	0.25 ± 0.03

Data are presented as mean ± SEM. Values with \* are significantly ( $p < 0.05$ ) different from control. (A) Control group, (B, C, D) 50 mg/kg, 100 mg/kg and 150 mg/kg of *A. senegalensis* groups, respectively. GSH: reduced glutathione, SOD: superoxide dismutase, CAT: catalase, MDA: malondialdehyde, Grps: Groups.

**Table 7.** Antioxidant parameters in the liver post mitochondrial fractions of rats orally administered *A. senegalensis* for 28 days

Groups	GSH (nmole/L)	SOD (U/mg protein)	CAT (U/mg protein)	MDA (nmole/L)
A	2.57 ± 0.30	5.34 ± 1.13	59 ± 7.42	0.57 ± 0.07
B	2.62 ± 0.41	4.16 ± 0.48	49 ± 4.23	0.53 ± 0.06
C	3.94 ± 1.61	4.84 ± 0.74	64.2 ± 6.36	0.73 ± 0.23
D	3.75 ± 1.26	8.62 ± 3.00*	109.7 ± 35.56*	1.03 ± 0.25*

Data are presented as mean ± SEM. Values with \* are significantly ( $p < 0.05$ ) different from control. (A) Control group, (B, C, D) 50 mg/kg, 100 mg/kg and 150 mg/kg. *A. senegalensis* groups, respectively. GSH: reduced glutathione, SOD: superoxide dismutase, CAT: catalase, MDA: malondialdehyde, Grps: Groups.

**Table 8.** Antioxidant parameters in the kidney homogenate of rats orally administered *A. senegalensis* for 28 days

Parameters	Groups			
	A	B	C	D
GSH <sup>μ</sup>	0.88 ± 0.08	1.06 ± 0.14	0.74 ± 0.09	0.92 ± 0.16
SOD <sup>α</sup>	1.89 ± 0.23	1.72 ± 0.15	1.50 ± 0.06	1.43 ± 0.09
CAT <sup>α</sup>	10.12 ± 1.55	12.32 ± 1.23	10.42 ± 1.82	10.56 ± 1.18
MDA <sup>μ</sup>	0.018 ± 0.00	0.027 ± 0.01*	0.024 ± 0.01*	0.30 ± 0.01*
PROT <sup>β</sup>	68.6 ± 6.35	54.6 ± 5.23	61.9 ± 2.93	63.4 ± 4.10

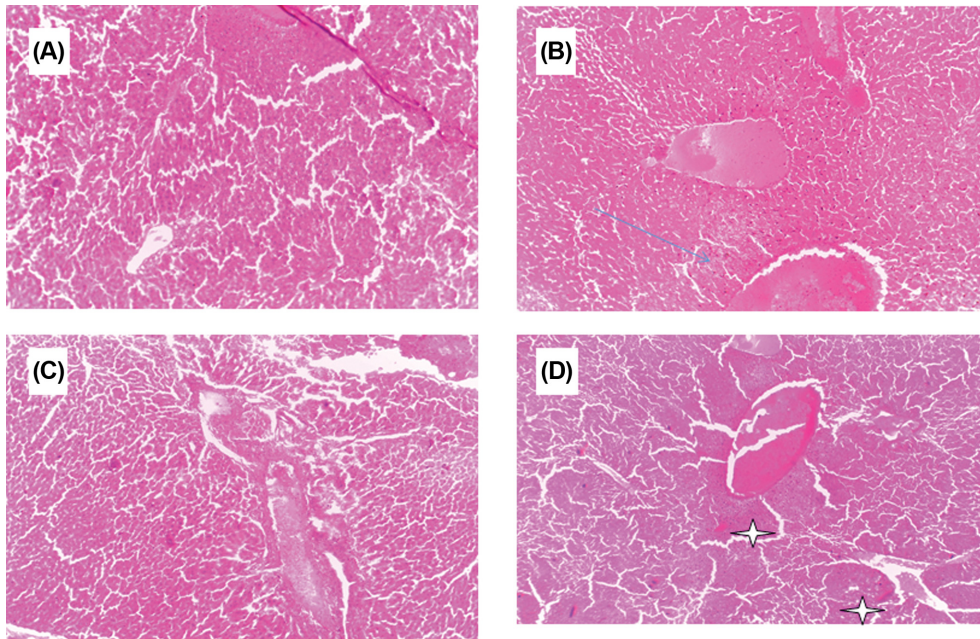
Data are presented as mean ± SEM. Values with \* are significantly ( $p < 0.05$ ) different from control. (A) Control group, (B, C, D) 50 mg/kg, 100 mg/kg and 150 mg/kg. *A. senegalensis* groups, respectively. GSH: reduced glutathione, SOD: superoxide dismutase, CAT: catalase, MDA: malondialdehyde, Grps: Groups, β - g/dL, α - U/mgprot, μ - nmole/L.



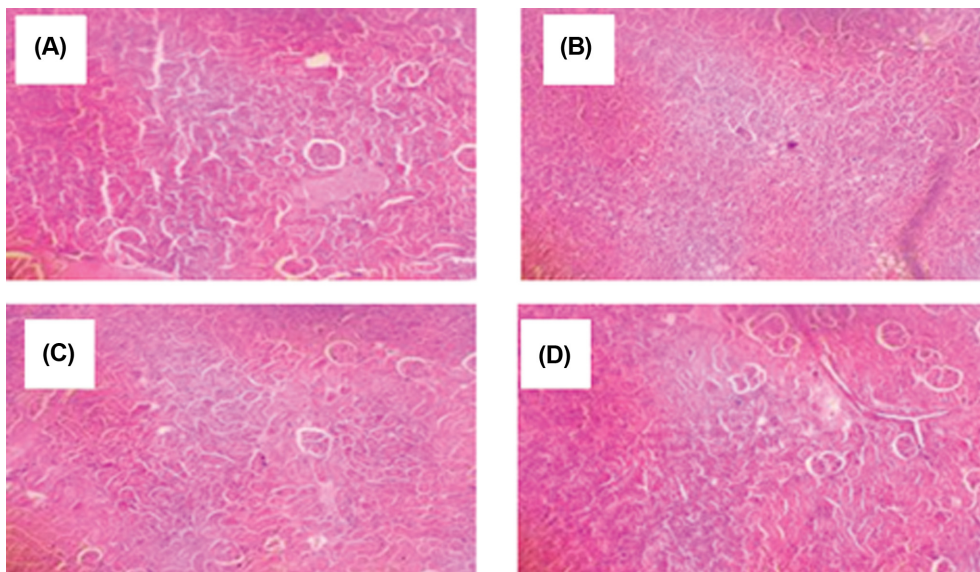
61%, while CAT activity increased by 21 and 85%, respectively, in the 150 mg/kg extract-treated group (Table 6, 7).

Table 8 shows the data obtained from the evaluation of antioxidant parameters in the kidneys of rats that orally received ethanol extracts of ASE for 28 days. There was

no significant ( $p > 0.05$ ) difference in GSH and MDA levels as well as SOD and CAT activities in the kidney of extract-treated groups compared to those in the control group. Administration of ASE extract decreased TP level compared to the level associated with the control treat-



**Fig. 1.** Photomicrographs of representative liver sections from rats administered ethanol extracts of ASE for 28 days as follows: (A) Control (normal saline) showing normal liver architecture. (B) 50 mg/kg ASE indicating slight focal area of perivenular necrosis. (C) 100 mg/kg ASE showing clear and distinct but non-patterned mild area of necrosis. (D) 150 mg/kg ASE showing severe necrosis at the perivenular and lobular areas. Hematoxylin and eosin stained. Magnification X10.



**Fig. 2.** Photomicrographs of representative kidney sections from rats administered ethanol extracts of ASE for 28 days as follows: (A) Control (normal saline) showing normal kidney architecture in rats administered (B) 50, 100 and 150 mg/kg ASE. (C) 100 mg/kg and (D) 150 mg/kg. Hematoxylin and eosin stained. Magnification X10.

ment, but the decrease was not significantly ( $p > 0.05$ ) (Table 8).

**Morphology of liver and kidney cells of the rats administered the ASE extract.** Fig. 1, 2 are photomicrographs of liver and kidney sections, respectively, of rats treated with the ethanol extract of ASE. Liver sections of the extract-treated animals showed a focal area of slight perivenular necrosis, and clear and distinct but non-patterned areas of mild necrosis and severe necrosis in the perivenular and lobular regions due to the 28-day oral administration of 50, 100, and 150 mg/kg ASE stem bark extract, respectively (Fig. 1). Kidney sections revealed glomeruli and tubules with a normal appearance in the control and extract-treated groups, respectively (Fig. 2).

## DISCUSSION

Medicinal plants are an important source of bioactive compounds and are used worldwide in traditional medicine for the treatment of various ailments. Although medicinal plants may have biological activities that are beneficial to humans, the potential toxicity of these bioactive substances has not been well established (43). Moreover, despite the widespread use, few scientific studies have been undertaken to ascertain the safety and efficacy of traditional remedies (44). Thus, the safety of these plants needs to be continuously studied thoroughly to avoid potential toxicity in humans. To this end, the present study evaluated the possible subacute toxic effects of ethanolic stem bark extracts of ASE, which is used in natural medicine in many African countries to alleviate many pathological conditions alone or in combination with other medicinal plants by traditional healers.

Acute toxicity tests are generally the first tests conducted in any toxicity study. They provide data on the relative toxicity likely to develop from a single brief exposure to any substance. Different plants extracts comprise different levels of bioactive compounds inherent in the plants (45). To evaluate the safety margin of ASE, an acute toxicity study was conducted and the LD<sub>50</sub> of this extract was investigated at doses up to 2,000 mg/kg (26) based on previously reported data on safe doses of other parts of this plant, which were greater than 5,000 mg/kg. However, it became important to investigate a lower concentration because the intended subacute toxicity study was at a far lower dose. The LD<sub>50</sub> of the stem bark extract of ASE was found to be greater than 2,000 mg/kg and no behavioral changes were observed (Table 1). This finding correlates with those of Okoye *et al.* (46) in which the LD<sub>50</sub> of the methanol fraction of ASE root bark was greater than 2,000 mg/kg. Since there was no observable toxicity recorded in the acute toxicity study, a subacute toxicity study was conducted to further generate inclusive toxicity reports on

ASE.

Subacute toxicity studies provide information on dosage requirement and target organ toxicity and help identify observable adverse effects affecting the average lifespan of experimental animals. Body weight changes serve as sensitive indications of the general health status of animals (47,48). They have also been used as an indicator of adverse effects of drugs and chemicals (49). If body weight loss is more than 10% of the initial weight, it is considered statistically significant in the animal (50,51). In this study, the rats gained weight over the 28-day oral administration period of ASE extract (50-150 mg/kg). However, this weight gain decreased in a concentration-dependent manner as the extract doses increased. Indeed, the animals treated with 150 mg/kg of ASE extract barely gained about 1% weight during the administration period (Table 2). This finding is a sign of toxicity attributable to the ASE extract, which might be involved in appetite suppression in the rats administered this extract dose, which consequently may lead to a reduction in weight. Organ weight is also an important index of physiological and pathological status. Relative organ weight is usually used to evaluate organ injury (52) in terms of atrophy, hypertrophy, or swelling (53,54). Primarily, the liver and kidneys are prone to adverse effects during biotransformation of toxicants (54). In this study, the relative weights of the liver and kidneys of the ASE extract-treated rats were not significantly different ( $p > 0.05$ ) from those of the control rats. This is an indication that the extract doses were not toxic to these organs (Table 2).

Liver enzymes including ALT, AST, and ALP are useful diagnostic biomarkers of liver damage usually found in large quantities in the plasma or serum when hepatic cellular membrane permeability changes or when necrosis and cellular injury occurs (55). ALP activity and plasma bilirubin levels were significantly increased ( $p < 0.05$ ) by 43.6% and 26.5%, respectively, in the 150 mg/kg ASE extract-treated animals compared to those in the control animals (Table 3). Taken together, these findings indicate that treatment with 150 mg/kg extract could cause hepatic toxicity, cirrhosis, and degeneration, which was corroborated by the necrotic morphological changes in the hepatocytes (56). These findings were supported by those reported in a previous study in which some plant extracts showed significant effects on specific biochemical parameters after subacute administration of ASE root bark extracts to Wistar rats.

Furthermore, the significant increase in white blood cell counts at the dose of 150 mg/kg is indicative of stimulation of the immune system, although without an increase in the differentials. Thus, the possible non-allergic nature of the extract or its immune system-stimulating effects may be attributable to secondary infection; this finding is in agreement with those of Adebayo *et al.* (57) and Adebiji and Abatan (58). The decreased level of hematocrit and



red blood cell count at the highest concentration of the ethanolic stem bark extract of ASE indicate toxicity probably resulting from hemolysis, which may cause anemia (59). These findings are in agreement with those recently reported by Bello *et al.* (60), who reported that subacute administration of the stem bark of *Alstonia scholaris* reduced packed cell volume and hemoglobin level in rats (Table 4).

SDH is a mitochondrial enzyme complex involved in the oxidation of succinate to fumarate in the Krebs cycle. This enzyme feeds electrons from this cycle into the ubiquinone pool in the respiratory chain (61) and together with ubiquinol has been implicated as a powerful antioxidant in mitochondria (62). The significant increase in SDH activity observed at the 150 mg/kg dose implies that ASE could be responsible for the induction and expression of SDH, support electron transfer, and ultimately increase ATP production in mitochondria. Many of the inner mitochondrial membrane proteins are involved in oxidative phosphorylation and their activity depends on the phospholipid composition of the membrane. Altered phospholipid composition affects mitochondrial respiration (63), as has been implicated in a variety of human diseases including Barth syndrome, ischemia, heart failure (64,65), and hepatotoxicity (66). ASE extract administration did not significantly compromise mitochondrial membrane cholesterol and phospholipids (Table 5). Nevertheless, the 50 mg/kg dose increased membrane cholesterol levels, which may suggest ASE to be steroidogenic at low concentrations.

An assessment of the antioxidant status of the rat liver and kidneys upon subacute administration of ASE extract was attempted by determining the activities of CAT and SOD, and levels of GSH and MDA. Oxidative stress is caused by the presence of reactive oxygen species (ROS) in excess of the available antioxidant buffering capacity (67). Many studies have shown that ROS can damage lipids, proteins, and DNA, thus altering the structures and functions of the cell, tissue, organ, and system, respectively (68). The cellular antioxidant buffering system includes factors such as SOD, CAT, GSH, GSH peroxidase and reductase, uric acid, and vitamin E. SOD is an effective defense enzyme that catalyzes the dismutation of superoxide anions into hydrogen peroxide ( $H_2O_2$ ). CAT is a heme-protein in aerobic cells that catalyzes the conversion of  $H_2O_2$  into oxygen and water. It protects the tissue from oxidative damage by highly reactive oxygen free radicals and hydroxyl radicals (69). GSH is an extremely efficient intracellular buffer for oxidative stress; it acts as a non-enzymatic antioxidant that reduces  $H_2O_2$ , hydroperoxides (ROOH), and xenobiotic toxicity (70). Lipid peroxides or other ROS inactivate the antioxidant defense system, which results in reduced activities of antioxidant enzymes and an increase in the level of MDA (71). Findings from this

study showed a significant dose-dependent increase ( $p < 0.05$ ) in the activities of SOD and CAT in the liver mitochondria (Table 6) and PMFs (Table 7) of Wistar rats treated with the ASE extract. GSH levels increased in the PMF while MDA level was high in both liver PMF and kidney homogenates. The observed significant increases in the antioxidant enzymes and other parameters are indicative of the potential of ASE to induce the expression of antioxidant enzymes and synthesis of GSH in response to oxidative stress signified by the elevated level of MDA in both the kidney homogenate and liver PMF (Table 7, 8).

In this study, the histopathology of the liver revealed that concentration-dependent localized degeneration of hepatic microarchitecture, characterized by slight necrosis in the perivenular area to a distinct but non-patterned mild and eventually severe necrosis at the perivenular and lobular areas, which were attributable to the 28-day oral administration of 50, 100 and 150 mg/kg of ASE stem bark extract, respectively (Fig. 1). This gradual morphological damage confirms the dose-response-related results of body weight, ALT and ALP levels, and antioxidant parameters. These data vary from those reported by Okoye *et al.* (44), who reported that a 400 mg/kg dose of root bark extract of ASE caused degeneration and necrosis in the liver. The differences in the composition of bioactive components of the stem bark and the root bark may account for this discrepancy. Furthermore, this finding lends credence to the results of SDH activity and the depletion of the antioxidant system in the liver, which confirms the liver toxicity of the 150 mg/kg dose of the ASE extract. In contrast, there was no evidence of toxicity to the kidneys in this study, in terms of biochemical constituents, antioxidant status, and kidney cell morphology. Thus, the finding implied that the kidneys could tolerate the dose and clearance was not affected, which provides supportive evidence for the relative kidney weight assessments (32).

The findings from this study demonstrate that ASE stem bark extract induced oxidative damage to the liver microarchitecture and the chain of electron transfer in the mitochondria with prolonged ingestion. However, the extract had little or no toxic effects on the kidneys. Therefore, it is recommended that consumption of ASE should be reduced to the barest minimum and awareness should be created among the communities that consume any part of this plant.

## ACKNOWLEDGMENTS

The authors appreciate the technical assistance of Mr S. Adenekan and other technical staff of Department of Biochemistry, College of Medicine, University of Lagos.

## CONFLICT OF INTEREST

The authors declare that there is no conflict of interest.

Received March 19, 2018; Revised June 29, 2018; Accepted July 20, 2018

## REFERENCES

- Okigbo, R., Anuagasi, C. and Amadi, J. (2009) Advances in selected medicinal and aromatic plants indigenous to Africa. *J. Med. Plants Res.*, **2**, 86-95.
- Abebe, D., Debella, A. and Urga, K. (2003) Medicinal plants and other useful plants of Ethiopia. EHNRI, Addis Ababa, Ethiopia, p. 5.
- Nwafor, S. (2004) Investigation of the antiulcer properties of the methanolic leaf fraction of *Cissampelos mucronata*. *AJST*, **5**, 109-114.
- Steenkamp, P.A., Harding, N.M., van Heerden, F.R. and van Wyk, B.E. (2006) Identification of atractyloside by LC-ESI-MS in alleged herbal poisonings. *Forensic Sci. Int.*, **163**, 81-92.
- Moghadamtousi, S., Fadaeinasab, M., Nikzad, S., Mohan, G., Ali, H. and Kadir, H. (2015) *Annona muricata* (Annonaceae): a review of its traditional uses, isolated acetogenins and biological activities. *Int. J. Mol. Sci.*, **16**, 15625-15658.
- Mustapha, A. (2013) *Annona senegalensis* persoon: a multipurpose shrub, its phytotherapeutic, phytopharmacological and phytomedicinal uses. *Int. J. Sci. Tech.*, **2**, 862-865.
- Janick, J. and Paul, R.E. (2008) The encyclopedia of fruits and nuts. CABI, Oxfordshire, UK, pp. 47-60.
- GRIN (2008) *Annona senegalensis* information, Taxonomy for plants, USDA, ARS, National Genetic Resources Program, National Germplasm Resources Laboratory, Beltsville, Maryland.
- Adzu, B., Abubakar, M.S., Izebe, K.S., Akumka, D.D. and Gamaniel, K.S. (2005) Effect of *Annona senegalensis* root bark extracts on *Najan igracotlis* venom in rats. *J. Ethnopharmacol.*, **96**, 507-513.
- Apak, L. and Olila, D. (2006) The *in vitro* antibacterial activity of *Annona senegalensis Securidacalongi pendiculata* and *Steganotaenia araliacea*-Ugandan medicinal plants. *Afr. Health Sci.*, **6**, 31-35.
- Suleiman, M.M., Dzenda, T. and Sani, C.A. (2008) Antidiarrhoeal activity of the methanol stem-bark extract of *Annona senegalensis* Pers. (Annonaceae) *J. Ethnopharmacol.*, **16**, 125-130.
- Ezugwu, C.O. and Odoh, U.E. (2003) Anticonvulsant activity of the root extract of *Annona senegalensis*. *J. Trop. Med. Plants*, **4**, 51-55.
- Adzu, B., Amos, S., Adamu, M. and Gamaniel, K. (2003) Anti-nociceptive and anti-inflammatory effects of the methanol extract of *Annona senegalensis* root bark. *J. Nat. Res.*, **3**, 63-67.
- Odoh, U.E., Ezugwu, C.O. and Ajali, U. (2004) Preliminary investigation of the analgesic activity of the chloroform root extract of *Annona senegalensis* L. *J. Pharm. Allied Sci.*, **2**, 169-172.
- Samie, A., Obi, C.L., Bessong, P.O. and Namrita, L. (2005) Activity profiles of fourteen selected medicinal plants from Rural Venda communities in South Africa against fifteen clinical bacterial species. *Afr. J. Biotechnol.*, **4**, 1443-1451.
- Atawodi, S.E., Ameh, D.A., Ibrahim, S., Andrew, J.N., Nze-libe, C. and Onyike, E.O. (2003) Indigenous knowledge system for treatment of trypanosomiasis in Kaduna State of Nigeria. *J. Ethnopharmacol.*, **79**, 279-282.
- Ogbadoyi, E.O., Abdulganiy, A.O., Adama, T.Z. and Okogun, J.I. (2007) *In vivo* trypanocidal activity of *Annona senegalensis* Pers. leaf extract against *Trypanosoma brucei*. *J. Ethnopharmacol.*, **112**, 85-89.
- Igwe, A.C. and Onabanjo, A.O. (1989) Chemotherapeutic effects of *Annona senegalensis* in *Trypanosoma brucei*. *Ann. Trop. Med. Parasitol.*, **83**, 527-534.
- Graham, J.G., Quinn, M.L., Fabricant, D.S. and Farnsworth, N.R. (2000) Plants used against cancer-an extension of the work of Jonathan Hartwell. *J. Ethnopharmacol.*, **73**, 343-377.
- Abubakar, M.S., Musa, A.M., Ahmed, A. and Hussaini, I.M. (2007) The perception and practice of traditional medicine in the treatment of cancers and inflammations by the Hausa and Fulani tribes of Northern Nigeria. *J. Ethnopharmacol.*, **111**, 625-629.
- Ajaiyeoba, E., Falade, M., Ogbale, O., Okpako, L. and Akinboye, D. (2006) Antimalarial and cytotoxic properties of *Annona senegalensis* extract. *Afr. J. Trad. CAM*, **3**, 137-141.
- Okoye, T.C. and Akah, P.A. (2010) Anticonvulsant and sedative effects of root bark extract and fractions of *Annona senegalensis*. *Inventi Impact Ethnopharmacol.*, **1**, 100-104.
- Okoli, C.O., Onyeto, C.A., Akpa, B.P., Ezike, A.C., Akah, P.A. and Okoye, T.C. (2010) Neuropharmacological evaluation of *Annona senegalensis* leaves. *Afr. J. Biotechnol.*, **9**, 8435-8444.
- Ajiboye, T.O., Yakubu, M.T., Salau, A.K., Oladiji, A.T., Akanji, M.A., Okogun, J.I. (2010) Antioxidant and drug detoxification potential of aqueous extracts of *Annona senegalensis* leaves in carbon tetrachloride induced hepatocellular damage. *Pharmaceut. Biol.*, **48**, 1361-1370.
- National Research Council: Custard Apples (*Annona* Species) (2008) In *Lost Crops Of Africa Vol. III: Crops*, Nat Acad Press, Washington, D.C., pp. 244-246.
- Dambata, S. and Aliyu, B. (2011) A survey of major ethnomedicinal plants of Kano North, Nig, their knowledge and uses by traditional healers. *Bayero J. Pure Applied Sci.*, **4**, 28- 34.
- Jada, M., Usman, W. and Olabisi, A. (2015) Crude flavonoids isolated from the stem bark of *Annona senegalensis* have antimicrobial activity. *J. Adv. Biol. Biotech.*, **2**, 24-29.
- Chalchat, J., Garry, R., Menut, C., Lamaty, G., Malhuret, R. and Chopineau, J. (1997) Correlation between chemical composition and antimicrobial activity. VI. Activity of some African essential oils. *J. Ess. Oil Res.*, **9**, 67-75.
- Khallouki, F., Younous, C., Soulimani, R. and Bessiere, J. (2002) Chemical composition of the essential oils of *Annona senegalensis* cuneata L. and *Annona senegalensis* Pers. Stem barks. *Flavour Fragrance J.*, **17**, 398-400.
- Okhale, S.E., Akpan, E., Fatokun, O.T., Esievo, K.B. and Kunle, O.F. (2016) *Annona senegalensis* Persoon (Annonaceae): a review of its ethnomedicinal uses, biological activities and phytochemicals. *J. Pharmacog. Phytochem.*, **5**, 211-219.

31. Lorke, D. (1983) A new approach to practical acute toxicity testing. *Arch. Toxicol.*, **54**, 272-289.
32. Nurul, S.A.Y., Hazilawati, H., Mohd, R.S., Noordin, M.M. and Norhaizan, M.E. (2018) Sub-acute oral toxicity assessment of ethanol extracts of *Mariposa christia* vesperticonis leaves in male Sprague Dawley rats. *Toxicol. Res.*, **34**, 85-95.
33. Johnson, D. and Lardy, H.A. (1967) Isolation of liver or kidney mitochondria. *Methods Enzymol.*, **10**, 94-96.
34. King, T.E. (1967) Preparation of succinate dehydrogenase and reconstitution of succinate oxidase. *Methods Enzymol.*, **10**, 322-331.
35. Chen, P.S., Toribara, T.Y. and Warner, H. (1956) Microdetermination of phosphorus. *Analyt. Chem.*, **28**, 1756-1758.
36. Lowry, O.H., Rosenbrough, N.J., Farr, A.L. and Randall, R.J. (1951) Protein measurement with Folin phenol reagent. *J. Biol. Chem.*, **193**, 265-275.
37. Misra, H.P. and Fridovich, I. (1972) The role of superoxide anion in the autoxidation of epinephrine and a simple assay for superoxide dismutase. *J. Biol. Chem.*, **247**, 3170-3175.
38. Geller, B.L. and Winge, D.R. (1983) A method for distinguishing Cu, Zn-and Mn-containing superoxide dismutases. *Anal. Biochem.*, **128**, 86-92.
39. Sedlak, J. and Lindsay, R.H. (1968) Estimation of total protein - bound and non-protein sulfhydryl groups in tissue with Ellman's reagent. *Anal. Biochem.*, **25**, 192-205.
40. Jollow, D.J., Mitchell, J.R., Zampaglione, N. and Gillette, J.R. (1974) Bromobenzene induced liver necrosis: protective role of glutathione and evidence for 3,4-bromobenzene oxide as the hepatotoxic metabolite. *Pharmacology*, **11**, 151-169.
41. Sinha, K.A. (1971) Colorimetric assay of catalase. *Anal. Biochem.*, **47**, 389-394.
42. Buege, J.A. and Aust, S.D. (1978) Microsomal lipid peroxidation. *Methods Enzymol.*, **52**, 302-310.
43. Rosidah, Y.M.F., Sadikun, A., Ahmad, M., Akowuah, G.A. and Asmawi, M.Z. (2009) Toxicology evaluation of standardized methanol extract of *Gynura procumbens*. *J. Ethnopharmacol.*, **123**, 244-249.
44. Graça, C., Freitas, C.S., Baggio, C.H., Dalsenter, P.R. and Marques, M.C. (2007) Mikania laevigata syrup does not induce side effects on reproductive system of male Wistar rats. *J. Ethnopharmacol.*, **111**, 29-32.
45. Saha, P., Mazumber, U.K., Halder, P.K., Islam, A. and Kumar, S.R.B. (2011) Evaluation of acute and subchronic toxicity of *Legenaria siceraria* aerial part. *Int. J. Pharm. Sci. Res.*, **2**, 1507-1512.
46. Okoye, T.C., Akah, P.A., Ezike, A.C., Okoye, M.O., Onyeto, C.A., Ndukwu, F., Ohaegbulam, E. and Ikele, L. (2012) Evaluation of the acute and sub-acute toxicity of *Annona senegalensis* root bark extracts. *Asian Pac. J. Trop. Med.*, **5**, 277-282.
47. Hilaly, J., Israih, H. and Lyoussi, B. (2004) Acute and chronic toxicological studies of *Ajugaiva* in experimental animals. *J. Ethnopharmacol.*, **91**, 43-50.
48. Porwal, M., Khan, N.A. and Maheshwar, K.K. (2017) Evaluation of acute and sub-acute oral toxicity by ethanolic extracts of *Marsdenia tenacissima* leaves in experimental rats. *Sci. Pharm.*, **85**, E29.
49. Nandy, S. and Datta, R. (2012) Acute and subacute toxicity studies of methanolic leaves extract of *Pterospermum acerifolium* L wild in rodents. *Int. J. Pharm. Life Sci.*, **3**, 1519-1529.
50. Raza, M., Al-Shabanah, O.A., El-Hadiyah, T.M. and Al-Majed, A.A. (2002) Effect of prolonged vigabatrin treatment on hematological and biochemical parameters in plasma, liver and kidney of Swiss albino mice. *Sci. Pharm.*, **70**, 135-145.
51. Carol, S.A. (1995) Acute, Sub-Chronic and Chronic Toxicology. CSR Handbook of Toxicology (Michael, J.D. and Manfred, A.H. Ed.). CSR Press Inc, Boca Raton, FL, pp. 51-104.
52. Amresh, G.R., Singh, P.N. and Rao, C.V. (2008) Toxicological screening of traditional medicine Laghupatha (*Cissampelos pareira*) in experimental animals. *J. Ethnopharmacol.*, **116**, 454-460.
53. Mohamed, E.A.S., Lim, C.P., Ebrika, O.S., Asmawi, M.Z., Sadikun, A. and Yam, M.F. (2011) Toxicity evaluation of a standardised 50% ethanol extract of *Orthosiphonstamineus*. *J. Ethnopharmacol.*, **133**, 358-363.
54. Dybing, E., Doe, J., Groten, J., Kleiner, J. and O'Brien, J. (2002) Hazard characterization of chemicals in food and diet: dose response, mechanism and extrapolation issues. *Food Chem. Toxicol.*, **42**, 237-282.
55. Senthil, K.R., PonMozhi, M., Viswanathan, P. and Nalini N. (2003) Activity of *Cassia auriculata* leaf extract in rats with alcoholic liver injury. *J. Nutr. Biochem.*, **14**, 452-458.
56. Costa-Silva, J.H., Lima, C.R. and Silva, E.J.R. (2008) Acute and sub-acute toxicity of the *Carapa guianensis* Aublet (Meliaceae) seed oil. *J. Ethnopharmacol.*, **116**, 495-500.
57. Adebayo, A.H., Abolaji, A.O., Opata, T.K. and Adegbenro, I.K. (2010) Effects of ethanolic leaf extracts of *Chrysophyllum albidum* G. on biochemical and haematological parameters of albino Wistar rats. *Afr. J. Biotechnol.*, **19**, 2145-2150.
58. Adebisi, O.E. and Abatan, O.M. (2013) Phytochemical and acute toxicity of ethanolic extract of *Enantia chlorantha* (oliv) stem bark in albino rats. *Interdiscip. Toxicol.*, **16**, 145-151.
59. Moody, J.O., Ogundipe, O.D., Akang, E.U. and Agbedana, E.O. (2007) Toxicological studies on the purified protoberberine alkaloidal fraction of *Enantia chlorantha* Oliv (Annonaceae). *Afr. J. Med. Med. Sci.*, **36**, 317-323.
60. Bello, I., Bakkouri, A.S., Tabana, Y.M., Al-Hindi, B., Al-Mansoub, M.A., Mahmud, R. and Asmawi, M.Z. (2016) Acute and sub-acute toxicity evaluation of the methanolic extract of *Alstonia scholaris* stem bark. *Med. Sci.*, **4**, 1-14.
61. Ackrell, B.A.C., Johnson, M.K., Gunsalus, R.P. and Cecchin, G. (1992) Structure and function of succinate dehydrogenase and fumarate reductase in Chemistry and Biochemistry of Flavoproteins (vol. III) (Muller, F. Ed.). CRC Press, Boca Raton, FL. pp. 229-297.
62. Rustin, P., Munnich, A. and Roetig, A. (2002) Succinate dehydrogenase and human diseases: new insights into a well-known enzyme. *Eur. J. Hum. Genet.*, **10**, 289-291.
63. Ohtsuka, T., Nishijima, M. and Akamatsu, Y. (1993) A somatic cell mutant defective in phosphatidyl glycerophosphate synthase with impaired phosphatidyl glycerol and cardiolipin biosynthesis. *J. Biol. Chem.*, **268**, 2908-2913.

64. Chicco, A.J. and Sparagna, G.C. (2007) Role of cardiolipin alterations in mitochondrial dysfunction and disease. *Am. J. Physiol. Cell Physiol.*, **292**, C33-C44.
65. Joshi, A.S., Zhou, J., Gohil, V.M., Chen, S. and Greenberg, M.L. (2009) Cellular functions of cardiolipin in yeast. *Biochim. Biophys. Acta.*, **1793**, 212-218.
66. Adisa, R.A. and Sulaimon, L.A. (2017) Assessment of liver antioxidant status and mitochondrial membrane composition of *Plasmodium berghei* -infected mice treated with selected antimalarials. *Acta Biochimica Polonica*, **64**, 1-7.
67. Abbassy, M.A. and Mossa, A.H. (2012) Haemato-biochemical effects of formulated and technical cypermethrin and deltamethrin insecticides in male rat. *J. Pharmacol. Toxicol.*, **7**, 312-321.
68. Persson, T., Popescu, B.O. and Minguéz, A.C. (2014) Oxidative stress in Alzheimer's disease: why did antioxidant therapy fail? *Oxid. Med. Cell. Longev.*, **2014**, 427318.
69. Tomlin, C.D. (1994) *The E-Pesticide Manual* (10th ed), The British Crop Protection Council, UK.
70. Ashar, W.M.P. and Muthu, M.H.S. (2012) Fenvalerate induced hepatotoxicity and its amelioration by quercetin. *Int. J. Pharm. Tech. Res.*, **4**, 1391-1400.
71. Halliwell, B. and Gutteridge, J.M. (1989) *Free Radicals in Biology and Medicine*, Clarendon Press, Oxford.