

## Case report

## Retinoblastoma presenting as pseudohypopyon and preserved visual acuity

Andrea L. Blitzer<sup>a</sup>, Sidney A. Schechet<sup>b</sup>, Hassan A. Shah<sup>a</sup>, Michael P. Blair<sup>a,c,\*</sup><sup>a</sup> Department of Ophthalmology and Visual Science, University of Chicago, Chicago, IL, USA<sup>b</sup> Elman Retina Group, Baltimore, MD, USA<sup>c</sup> Retina Consultants, Ltd, Des Plaines, IL, USA

## ARTICLE INFO

## Keywords:

Retinoblastoma  
Pseudohypopyon  
Enucleation  
Histopathology  
Anterior segment tumor

## ABSTRACT

**Purpose:** To describe a Case of retinoblastoma that presented subtly as a pseudohypopyon in a child with preserved visual acuity.**Observations:** A 3-year-old male was referred for concern of hypopyon in the left eye. Initial examination revealed 20/30 vision, a pseudohypopyon, and a large white mass on fundoscopy. Examination under anesthesia revealed extensive retinoblastoma with vitreous seeds and anterior chamber involvement. Enucleation was performed and histology demonstrated retinoblastoma with tumor cells found within the ciliary body, iris, iridocorneal angle, and Schlemm canal. Based on the high-risk histopathology findings, adjuvant chemotherapy was performed.**Conclusions and importance:** Retinoblastoma is the most common primary intraocular malignancy in children. Though the classic presentation is leukocoria and/or strabismus, it can present in a variety of ways. Physicians should be aware that retinoblastoma, even severe forms, can present subtly with pseudohypopyon and preserved vision. Adjuvant chemotherapy for anterior segment involvement remains controversial.

## 1. Introduction

Retinoblastoma is the most common primary intraocular malignancy of childhood. Leukocoria is the most common presenting sign and is seen in the majority of cases (56%), followed by strabismus (24%).<sup>1</sup> Retinoblastoma may present with a diverse range of signs and symptoms. Specifically, retinoblastoma can masquerade as uveitis or infection. Diagnosis of retinoblastoma is difficult in patients who present atypically. Here, we present a child with excellent vision who presented with a pseudohypopyon. Multimodal imaging revealed extensive unilateral retinoblastoma. The patient underwent enucleation and adjuvant systemic chemotherapy based on high-risk features on histopathology.

## 2. Case presentation

A 3-year-old boy was referred by an outside ophthalmologist who diagnosed a “hypopyon” in the left eye after the boy’s grandmother noted a “white spot” in his eye. He was a healthy child with an unremarkable, full-term birth history, and there were no significant diseases in the family. This very cooperative patient denied any vision changes or symptoms, including photophobia, and a comprehensive review of systems was negative, including a lack of fever, chills, fatigue, weight loss,

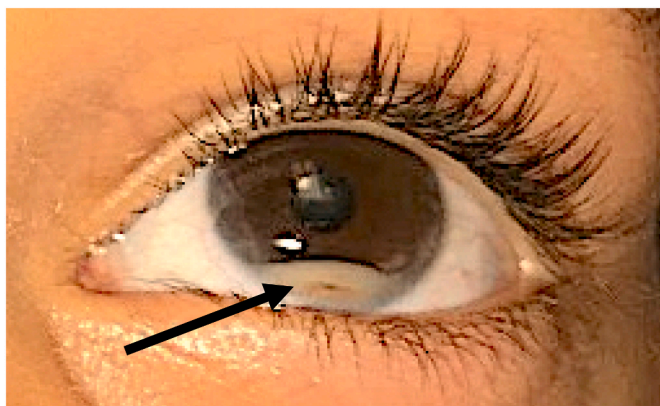
joint pain, and rash. Uncorrected Lea visual acuity was 20/20 OD and 20/30 OS. Intraocular pressure by iCare tonometry was 17 OD and 24 OS. Pupils and eye movements were within normal limits OU. The conjunctiva was without hyperemia in both eyes. Slit lamp examination of the left eye revealed a 2 mm pseudohypopyon in the anterior chamber with layered red cells within it (Fig. 1) as well as punctate white lesions on the left iris. No circulating cells or flare was present in the anterior chamber and no keratoprecipitates were present. There were clumps of white cells in the vitreous, and on fundoscopic exam superonasally there was a large, white mass with tortuous feeder-vessels and subretinal exudation (Fig. 2A). Examination of the right eye was unremarkable.

Initial exam raised concern for likely retinoblastoma. The patient was urgently taken for an exam under anesthesia, where fluorescein angiography demonstrated prominent feeder and drainage vessels, retinal vascular dilatation and telangiectasias, late vascular leakage, terminal vascular bulbs with extensive subretinal exudation, and prominent iris neovascularization with leakage (Fig. 2B and C). B-scan ultrasonography of the left eye showed a large 6 × 8mm superonasal retinal mass with calcifications (Fig. 3). The right eye was confirmed to be unremarkable. An MRI of the brain and orbits did not show any extraocular extension of the tumor or any intracranial lesions.

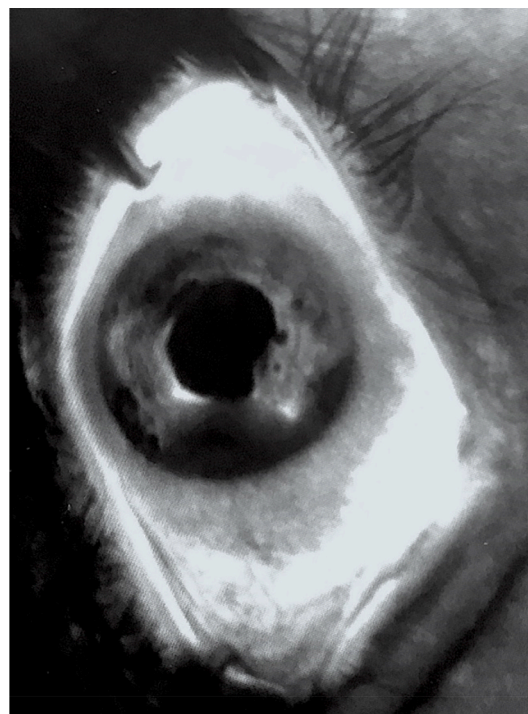
This multimodal imaging confirmed retinoblastoma, Group E (cT3c),

\* Corresponding author. Department of Ophthalmology and Visual Science, University of Chicago, Chicago, IL, USA.

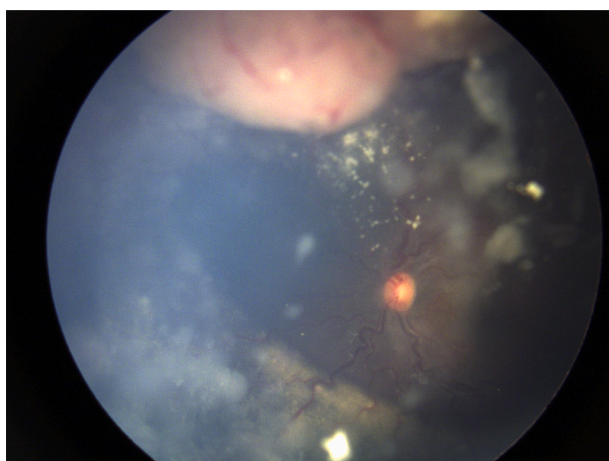
E-mail address: [Michaelblairmd@gmail.com](mailto:Michaelblairmd@gmail.com) (M.P. Blair).



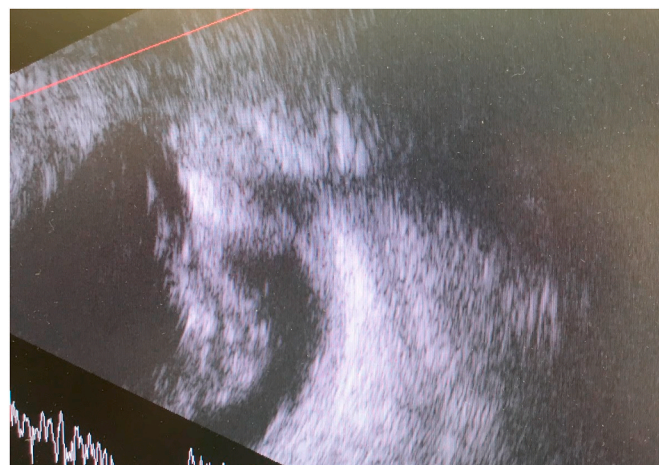
**Fig. 1.** External photograph of the left eye at initial presentation with a 2mm pseudohypopyon in the anterior chamber. A streak of blood is seen (arrow) within the pseudohypopyon.



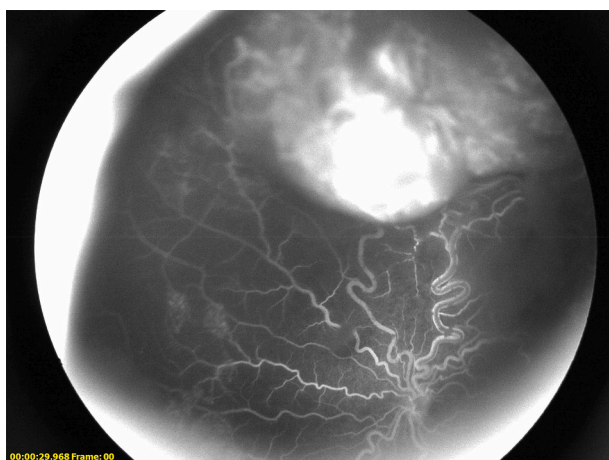
**Fig. 2C.** Fluorescein angiogram of the iris. Hyperfluorescence is present diffusely from most of the iris and more profuse leakage is present at the iris margin. Note blockage inferiorly from the tumor mass.



**Fig. 2A.** Fundus photography during exam under anesthesia showed a large white vascular mass with tortuous feeder vessels, subretinal exudation, and vitreous seeding.



**Fig. 3.** B-scan showing a large 6 × 8mm mass with shadowing from calcifications.

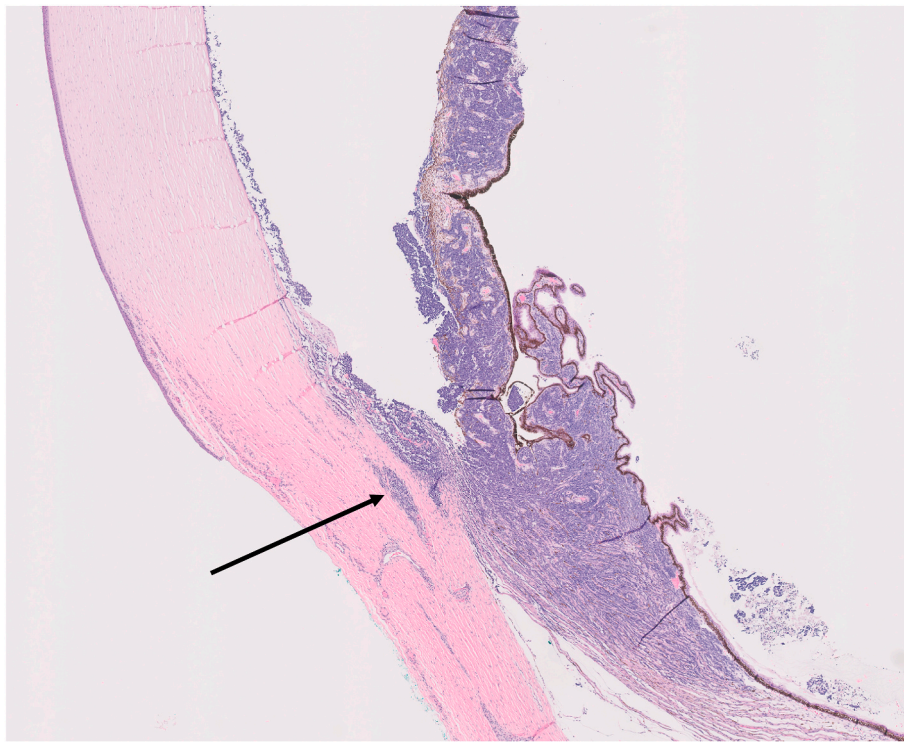


**Fig. 2B.** Fluorescein angiography showing tortuous feeder vessels and telangiectasias.

with infiltration of the anterior segment. After a fully informed discussion of the findings, prognosis, and treatment options, including systemic chemotherapy, intra-arterial chemotherapy, likely with intracameral chemotherapy, and enucleation, the family opted to pursue

primary enucleation.

Histopathology of the enucleated eye revealed extensive tumor in both posterior and anterior segments including infiltration into the ciliary body, iris, and iridocorneal angle (pT2b). Tumor cells were identified within Schlemm canal with concern for possible extraocular extension through the aqueous outflow system (Fig. 4). Given massive ciliary body involvement and involvement of outflow structures the eye was considered best categorized as high risk. Options regarding continued surveillance versus adjuvant chemotherapy was undertaken with the family and oncology service. They opted for chemotherapy and 6 cycles of vincristine, etoposide and carboplatin were administered. Genetic testing was negative, as were the ocular examinations of all family members. Surveillance of the right eye is ongoing and is still unremarkable.



**Fig. 4.** Hematoxylin-eosin (H&E) staining of the enucleated eye revealed tumor infiltration (blue cells) into Schlemm canal (arrow), iris, and ciliary body. (For interpretation of the references to colour in this figure legend, the reader is referred to the Web version of this article.)

### 3. Discussion

Retinoblastoma is the most common primary intraocular malignancy in children. Atypical presentations may masquerade as other ocular conditions and postpone the diagnosis of retinoblastoma. Here we present an unusual Case of retinoblastoma with anterior segment involvement in a child with excellent vision.

The most common presenting sign of retinoblastoma is leukocoria, followed by strabismus.<sup>1</sup> In very rare instances, it can present as a pseudohypopyon when tumor cells accumulate in the anterior chamber. Retinoblastoma can be mistaken initially as uveitis or endophthalmitis when there is anterior segment involvement and vitreous seeding.<sup>2-5</sup> The lack of the usual signs of iritis, including photophobia, conjunctival hyperemia, white blood cells and flare in the anterior chamber and keratoprecipitates can help distinguish these entities.

Despite recent breakthroughs in the treatment of intraocular retinoblastoma, retinoblastoma with anterior segment involvement continues to portend a very poor visual prognosis with exceedingly low rates of globe salvage. Although intra-arterial chemotherapy (IAC) can be an effective primary therapy, and is particularly useful for improving ocular survival of Group D eyes, the efficacy is limited in Group E eyes, particularly with diffuse seeding.<sup>6-9</sup> Tumor control in Group E eyes has been improved significantly with the combination of IAC and adjuvant intravitreal chemotherapy; however rates of globe salvage remain low and nearly half of all eyes undergo secondary enucleation.<sup>10</sup> Orbital metastasis<sup>11</sup> and even death have been observed following sole IAC therapy in Group E tumors after apparent tumor regression.<sup>12</sup>

Data regarding the treatment of anterior chamber involvement (ASI) remains limited. A report by Pavlidou described failure of anterior segment seeding to respond to IAC.<sup>13</sup> A report by Shields et al. described treatment of RB limited to the anterior chamber, without vitreous involvement, with systemic chemotherapy in three eyes with radiation in two of those eyes.<sup>14</sup> Another report by Munier et al. described globe salvage in 6/11 eyes treated with intracameral chemotherapy for anterior segment seeding despite aggressive primary treatment.<sup>15</sup>

Nonetheless, enucleation remains a conservative option, particularly in a unilateral Case with negative genetic testing.

Classically, high-risk features have included massive (>3mm) choroidal involvement and tumor invasion into the post-laminar optic nerve,<sup>16</sup> though rarely tumor can also spread through the trabecular meshwork and direct scleral extension.<sup>17,18</sup>

The role of adjuvant systemic chemotherapy after enucleation in eyes with ASI is somewhat controversial. Although Honavar et al. did report metastasis in a patient with ASI alone,<sup>19</sup> this has not been found to be a consistent risk factor. In a retrospective review, Khelifaoui reported anterior chamber seeds to be a risk factor for metastasis, but this did not hold in multivariate analysis.<sup>20</sup> Sreelakshmi et al. found higher mortality among patients with ASI and other high-risk factors than those with high-risk characteristics alone, but ASI alone did not appear to be a risk factor for extraocular involvement.<sup>21</sup> Baroni et al. did not find ASI to be a separate risk factor, but the number of patients with ASI without other risk factors was relatively small.<sup>22</sup>

Relative contribution of involvement of different anterior segment tissues with regards to extraocular spread is uncertain since generally ASI has not been parsed by specific tissue in the literature. It may be that massive ciliary body involvement may be similar to choroidal involvement as they are both uveal tissue and adjacent to sclera.

In the present Case, tumor cells found within the ciliary body, iris, trabecular meshwork and Schlemm canal raised concern for metastasis through the aqueous outflow system and prompted treatment with adjuvant systemic chemotherapy.

### 4. Conclusion

In summary, we present a Case of an atypical presentation of retinoblastoma in a patient with excellent vision. When the anterior segment and vitreous contain fine seeds, the clinical scenario can be mistaken for uveitis or endophthalmitis. Adjuvant chemotherapy for ASI remains controversial.

## Patient consent

Written consent was obtained from the patient's guardian for use of imaging and data in the publication of this Case report.

## Disclosures

None.

## Funding sources

No funding or grant support.

## Authorship

All listed authors meet the ICMJE criteria.

We attest that all authors contributed significantly to the creation of this manuscript, each having fulfilled criteria as established by the ICMJE.

## Intellectual property

We confirm that we have given due consideration to the protection of intellectual property associated with this work and that there are no impediments to publication, including the timing of publication, with respect to intellectual property. In so doing we confirm that we have followed the regulations of our institutions concerning intellectual property.

## Research ethics

We further confirm that any aspect of the work covered in this manuscript that has involved human patients has been conducted with the ethical approval of all relevant bodies and that such approvals are acknowledged within the manuscript.

## Contact with the editorial office

We understand that this Corresponding Author is the sole contact for the Editorial process (including EVISE and direct communications with the office). He/she is responsible for communicating with the other authors about progress, submissions of revisions and final approval of proofs.

We confirm that the email address shown below is accessible by the Corresponding Author, is the address to which Corresponding Author's EVISE account is linked, and has been configured to accept email from the editorial office of American Journal of Ophthalmology Case Reports:

## Declaration of competing interest

We wish to confirm that there are no known conflicts of interest associated with this publication and there has been no significant financial support for this work that could have influenced its outcome.

## Acknowledgments

None.

## References

- Abramson DH, Frank CM, Susman M, Whalen MP, Dunkel LJ, Boyd NW. Presenting signs of retinoblastoma. *J Pediatr*. 1998;132(3 Pt 1):505–508.
- Haik BG, Dunleavy SA, Cooke C, et al. Retinoblastoma with anterior chamber extension. *Ophthalmology*. 1987;94(4):367–370.
- Shields JA, Shields CL, Eagle RC, Blair CJ. Spontaneous pseudohypopyon secondary to diffuse infiltrating retinoblastoma. *Arch Ophthalmol*. 1988 Sep;106(9):1301–1302.
- Materin MA, Shields CL, Shields JA, Eagle Jr RC. Diffuse infiltrating retinoblastoma simulating uveitis in a 7-year-old boy. *Arch Ophthalmol*. 2000 Mar;118(3):442–443.
- Shields CL, Ghassemi F, Tuncer S, Thangappan A, Shields JA. Clinical spectrum of diffuse infiltrating retinoblastoma in 34 consecutive eyes. *Ophthalmology*. 2008 Dec;115(12):2253–2258.
- Shields CL, Mashayekhi A, Au AK, et al. The International Classification of Retinoblastoma predicts chemoreduction success. *Ophthalmology*. 2006;113(12):2276–2280.
- Shields CL, Fulco EM, Arias JD, et al. Retinoblastoma frontiers with intravenous, intra-arterial, periocular, and intravitreal chemotherapy. *Eye*. 2013;27(2):253–264.
- Shields CL, Manjandavida FP, Lally SE, et al. Intra-arterial chemotherapy for retinoblastoma in 70 eyes: outcomes based on the international classification of retinoblastoma. *Ophthalmology*. 2014;121(7):1453–1460.
- Chen Q, Zhang B, Dong Y, et al. Comparison between intravenous chemotherapy and intra-arterial chemotherapy for retinoblastoma: a meta-analysis. *BMC Canc*. 2018;18(1):486.
- Dalvin LA, Kumari M, Essuman VA, et al. Primary intra-arterial chemotherapy for retinoblastoma in the intravitreal chemotherapy era: five years of experience. *Ocul Oncol Pathol*. 2019;5(2):139–146.
- Mathew AA, Sachdev N, Staffieri SE, Mckenzie JD, Elder JE. Superselective intra-arterial chemotherapy for advanced retinoblastoma complicated by metastatic disease. *J AAPOS*. 2015;19(1):72–74.
- Ong SJ, Chao AN, Wong HF, Liou KL, Kao LY. Selective ophthalmic arterial injection of melphalan for intraocular retinoblastoma: a 4-year review. *Jpn J Ophthalmol*. 2015;59(2):109–117.
- Pavlidou E, Burris C, Thaug C, et al. Anterior segment seeding in eyes with retinoblastoma failing to respond to intraophthalmic artery chemotherapy. *JAMA Ophthalmol*. 2015;133(12):1455–1458.
- Shields CL, Lally SE, Manjandavida FP, Leahey AM, Shields JA. Diffuse anterior retinoblastoma with globe salvage and visual preservation in 3 consecutive cases. *Ophthalmology*. 2016;123(2):378–384.
- Munier FL, Moulin A, Gaillard M-C, et al. Intracameral chemotherapy for globe salvage in retinoblastoma with secondary anterior chamber invasion. *Ophthalmology*. 2018;125(4):615–617.
- Chévez-Barrios P, Eagle RC, Krailo M, et al. Study of unilateral retinoblastoma with and without histopathologic high-risk features and the role of adjuvant chemotherapy: a children's oncology Group study. *J Clin Oncol*. 2019;37(31):2883–2891.
- Kramer TR, Watanabe T, Miller J, Ober RR. Unilateral sporadic retinoblastoma presenting as acute angle closure glaucoma with intraocular inflammation. *Ophthalmic Pract*. 1999;17(1):20–25.
- Alkatan HM, Alqahtani FS, Maktabi AM. Enucleated globes with advanced retinoblastoma: correlation of histopathological features and reclassification of tumors according to the 8th edition of the American Joint Committee on Cancer (AJCC). *Int Ophthalmol*. 2020 Jul;40(7):1739–1747.
- Honavar SG, Singh AD, Shields CL, et al. Postenucleation adjuvant therapy in high-risk retinoblastoma. *Arch Ophthalmol*. 2002;120(7):923–931.
- Khelfaoui F, Validire P, Auperin A, et al. Histopathologic risk factors in retinoblastoma: a retrospective study of 172 patients treated in a single institution. *Cancer*. 1996;77(6):1206–1213.
- Sreelakshmi KV, Chandra A, Krishnakumar S, Natarajan V, Khetan V. Anterior chamber invasion in retinoblastoma: not an indication for adjuvant chemotherapy. *Invest Ophthalmol Vis Sci*. 2017;58(11):4654–4661.
- Baroni LV, Sampor C, Fandiño A, et al. Anterior segment invasion in retinoblastoma: is it a risk factor for extraocular relapse? *J Pediatr Hematol Oncol*. 2014;36(8):e509–512.