



Case Report

Proton beam therapy for a giant hepatic hemangioma: A case report and literature review



Shosei Shimizu^a, Masashi Mizumoto^{a,*}, Toshiyuki Okumura^a, Yinuo Li^b, Keiichirou Baba^a, Motohiro Murakami^a, Toshiki Ishida^a, Masatoshi Nakamura^a, Yuichi Hiroshima^a, Takashi Iizumi^a, Takashi Saito^a, Haruko Numajiri^a, Kei Nakai^a, Masaharu Hata^c, Hideyuki Sakurai^a

^a Department of Radiation Oncology, Proton Medical Research Center, University of Tsukuba Hospital, Tsukuba, Ibaraki, Japan

^b Department of Radiation Oncology, Graduate School of Comprehensive Human Sciences, University of Tsukuba, Tsukuba, Ibaraki, Japan

^c Department of Radiation Oncology, Yokohama City University Graduate School of Medicine, Yokohama, Kanagawa, Japan

ARTICLE INFO

Article history:

Received 6 July 2020

Revised 27 January 2021

Accepted 30 January 2021

Available online 3 February 2021

Keywords:

Radiotherapy

Proton beam therapy

Hemangioma

Liver

Secondary cancer

ABSTRACT

Background: Hepatic hemangiomas are benign tumors with a favorable prognosis, but giant hepatic hemangiomas can cause abdominal symptoms and are indicated for treatment. Most cases are treated with surgery, but radiotherapy has also been used. However, to date, there have been no reports of proton beam therapy for a hepatic hemangioma.

Case presentation: A 46-year-old woman had a tumor of 80 × 80 mm in the left medial lobe of the liver, which was diagnosed as a giant hemangioma based on the contrast pattern. Therapy was required for a giant hepatic hemangioma with symptoms, but the patient refused blood transfusion due to religious reasons, which made surgical resection difficult. Therefore, she was referred to our hospital for proton beam therapy. At her first visit, liver function was Child-Pugh A (5 points) and there was no elevation of tumor markers. Proton beam therapy of 28.6 Gy (RBE) given in 13 fractions was performed without interruption. The only observed acute radiation toxicity was Grade 1 dermatitis. One year after proton beam therapy, the hemangioma had significantly decreased, and a complete response has been maintained for 15 years based on ultrasound and MRI.

Conclusion: This case is the first reported use of proton beam therapy for a hepatic hemangioma. The outcome suggests that this treatment may be effective for a giant liver hemangioma.

© 2021 The Author(s). Published by Elsevier B.V. on behalf of European Society for Radiotherapy and Oncology. This is an open access article under the CC BY-NC-ND license (<http://creativecommons.org/licenses/by-nc-nd/4.0/>).

1. Background

Hepatic hemangiomas are the most common benign tumors of the liver and are reported to account for 73% of benign liver tumors. Among all liver tumors, hemangiomas are the second most common after metastatic liver tumors [1–4]. A hemangioma is generally small, asymptomatic, undetectable and may be found at autopsy [5–7]. In recent years, the frequency of detection of hepatic hemangiomas has increased due to more use of imaging such as ultrasound, computed tomography (CT), magnetic resonance imaging (MRI), positron emission tomography–CT (PET-CT), and angiography [6–10]. Although hepatic hemangiomas are benign, some of these tumors (<40%) may increase in size [11–13]. Lesions

larger than 4 cm in diameter are referred to as giant hemangiomas [14].

The recommended management of a hemangioma after discovery is monitoring by follow-up of changes of size. Hemangiomas rarely cause intraperitoneal hemorrhage due to spontaneous rupture, but careful follow-up is necessary for tumors larger than 5 cm, and especially for giant hemangiomas larger than 10 cm, as the risk of rupture is higher than that for smaller tumors. Clinical symptoms such as abdominal pain, a rapid increase of the tumor diameter, bleeding due to spontaneous or traumatic rupture, and blood coagulation abnormalities may occur, and such cases require treatment. Surgery is commonly performed, but there are a few reports of use of hepatic artery embolization or radiotherapy [15]. Herein, we describe the first case of use of proton beam therapy for a giant hemangioma.

* Corresponding author at: Department of Radiation Oncology, University of Tsukuba, 1-1-1 Tennoudai, Tsukuba, Ibaraki 305-8575, Japan.

E-mail address: mizumoto@pmrc.tsukuba.ac.jp (M. Mizumoto).

2. Case report

The patient was a 46-year-old woman with no liver function abnormalities in whom a medical examination 3 years earlier had revealed increases of hepatobiliary enzymes (AST 62 IU/L, ALT 68 IU/L, ALP 458 IU/L and γ -GTP 195 IU/L) and detection of a liver mass on abdominal ultrasound. Abdominal CT revealed a tumor of 80 × 80 mm in the left medial lobe of the liver, which was diagnosed as a giant hemangioma based on the contrast pattern (Fig. 2). Similarly, MRI showed a typical image of a hepatic hemangioma with a clear border. The homogenous lesion, which was hypointense on T1-weighted images and hyperintense on T2-weighted images, presented with a “cotton-wool” pattern. In addition, dilatation of the peripheral bile duct, and compression of the bile duct and blood vessels were observed. A physical examination revealed a flat and soft abdomen and tenderness of the right rib.

Therapy for the giant hepatic hemangioma was considered to be required due to the symptoms. However, the patient was unable to undergo a blood transfusion for religious reasons, making surgical resection difficult. Therefore, she was referred to our hospital for proton beam therapy. At her first visit, liver function was Child-Pugh A (Alb: 4.5 g/dl, T-Bil: 1.1 mg/dl, PT%: 103%, no hepatic encephalopathy, no abdominal dropsy) and there was no elevation of tumor markers. We proceeded proton beam therapy. Acute radiation toxicity was observed as Grade 1 dermatitis only.

The patient refused follow-up by CT imaging, so we basically follow up with ultrasound examination. Tumor size was gradually decreased 50 × 50 mm diameter one year after proton beam therapy, 44 × 33 mm after 1 year and half, 40 × 26 mm after 2 years, 36 × 26 mm after 3 years, respectively. Follow up by the ultrasound examination once a year was continued and the tumor was slightly decreased. The hemangioma had decreased in size by ultrasound. 11 years later, T2-weighted MRI image showed a low signal area which had reduced to 29 × 15 mm and the size was maintained (Fig. 3). It was difficult to be recognized by ultrasound. And there was no deformation of liver. Except for the atrophy of the irradiated area of the tumor, the rest of the liver did not deform and remained intact. In addition, there were no increase of hepatobiliary enzymes in a blood test and no symptoms in an abdominal examination. PS was 0 and the patient was healthy. Changes in blood chemistry are shown in Table 1.

3. Proton beam therapy

Before treatment planning for hepatocellular carcinoma (HCC) or intrahepatic cholangiocarcinoma, patients typically have a metal fiducial marker (an iridium seed of 0.8 mm in diameter

and 2 mm in length) implanted near the tumor to aid in positioning. Patient set-up is performed as follows, using respiratory synchronization and a 5-mm margin for respiratory motion: the laser is applied to the body prior to treatment, the patient's position is adjusted based on a body mark on the skin, and orthogonal fluoroscopy is then used to match the bone structure, with reference to the DRR prior to treatment. Online correction is performed and then final adjustments are used around the position of the fiducial marker. Additionally, a respiration sensor and 3D tumor motion are used. The terminal stage is then acquired using an imaging system, and irradiation with the proton beam is performed only at this stage. By using this system, the error is <5 mm [16].

In a case of HCC, the GTV is irradiated with a margin of about 10 mm and an additional leaf margin of 5–10 mm to cover micro-filtration of the tumor. However, the present case was a benign tumor and no margin was added to the GTV. Also, the patient refused to have a metal fiducial marker implanted, so a total leaf margin of 10 mm was added while using respiratory synchronization to cover the setup error. For HCC, the gastrointestinal tract is normally avoided as much as possible after 40–50 Gy (RBE) to maximize the non-irradiated area of the liver. However, since the total dose for hemangioma is low, at risk organs were not a concern in the present case. To minimize the risk of secondary cancers, proton therapy was started with 28.6 Gy (RBE) in one field from a 320° direction in 13 fractions (Fig. 1) and was completed without interruption.

4. Discussion

There are no reports of hepatic hemangiomas becoming malignant [6,14], and asymptomatic cases only require general follow-up once every 6 months to 1 year [6]. Indications for treatment include pain, persistent increase in size, effects on surrounding organs, rupture, and complication of Kasabach-Merritt syndrome [12]. Surgery is the first choice for symptomatic hepatic hemangiomas [10,14,15], and other options include arterial embolization and radiofrequency ablation [12,15]. If these treatments are difficult due to the size, number, site, or general condition, radiotherapy may be an option. However, information is limited [10]. Searching in PubMed for articles with “Radiotherapy, Hemangiomas” as the keywords in the past 30 years, there are only three reports about treatment results of radiotherapy for hepatic hemangiomas.

Radiotherapy is not recommended as the first treatment for hepatic hemangiomas because it can cause radiation hepatitis and secondary cancer [14,15]. Gaspar et al. reported radiotherapy for 7 cases of symptomatic inoperable hepatic hemangiomas. The

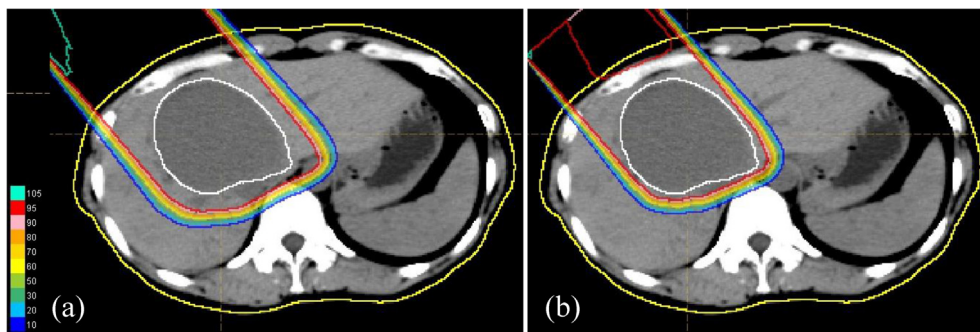


Fig. 1. Dose-distribution chart for proton beam therapy, showing isodose curves representing 100% to 10% of the prescribed dose at 10% intervals. Normal liver outside the blue line was not irradiated. The treatment plan was changed after ten rounds to gradually reduce the treatment margin. (a) 0–22 Gy (RBE)/10 Fr. (b) 24.2–28.6 Gy (RBE)/11–13 Fr. (For interpretation of the references to color in this figure legend, the reader is referred to the web version of this article.)

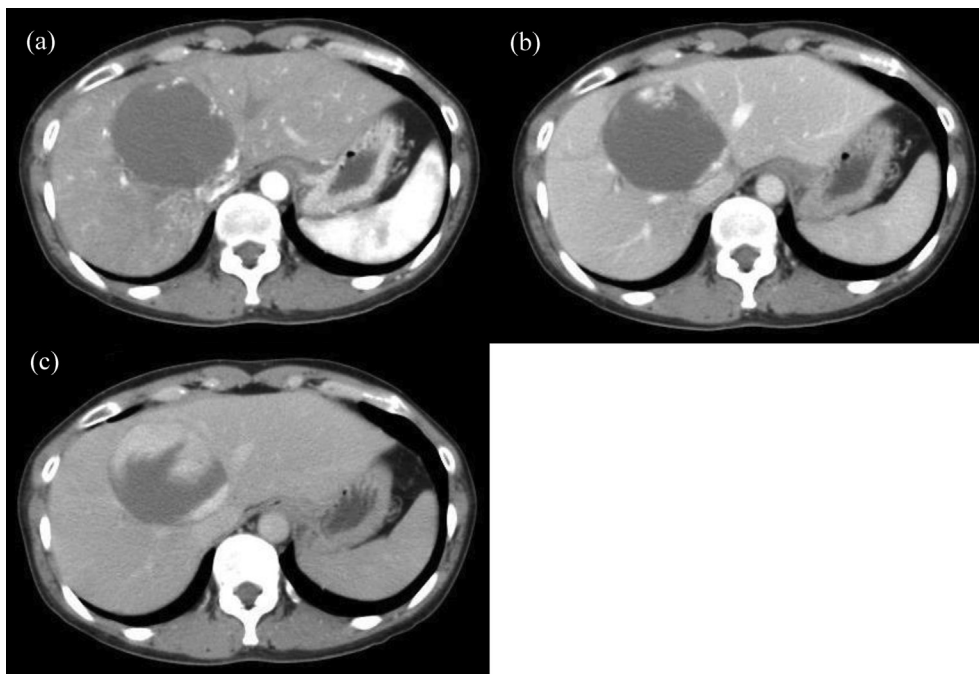


Fig. 2. CT showed a giant hepatic hemangioma in the left medial lobe before proton beam therapy. (a) Hepatoarterial phase (b) Portal venous phase (c) Equilibrium phase.

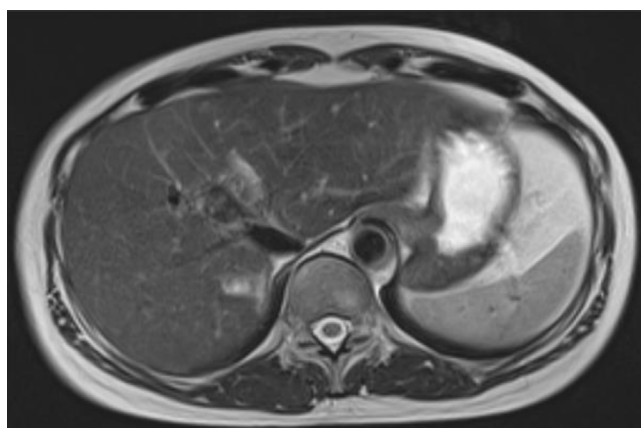


Fig. 3. T2-weighted MRI showed that the size of the giant hepatic hemangioma had reduced to 29 × 15 mm and maintained for 15 years after proton beam therapy.

total dose at the isocenter calculated according to ICRU recommendations varied from 15 to 30 Gy given in 15–22 fractions. The observation period was 40–67 months, and all 7 cases showed improvement of symptoms [10]. At the time of final follow-up, there were 3 cases with abdominal symptoms and one with abnormal liver function. Biswal et al. treated 4 patients aged 42–55 years

with 30 Gy given in 15 fractions and obtained reduction and relief from symptoms during an observation period of 12–36 months [15]. Lee et al. used 3D-CRT of 30 Gy given in 15 fractions in a 79-year-old patient and found that reduction of size was maintained after 15 months of follow-up [17]. Adverse events of Grade 1 (elevation of AST, ALT) occurred in these treatments, but there were no severe late effects. However, in longer-term follow-up, Moore et al. and Okazaki et al. found emergence of secondary HCC 20 years after treatment of hepatic hemangiomas [18,19], and Weshler et al. reported one case of squamous cell carcinoma of the renal pelvis 20 years after right hemi-abdominal irradiation for a cavernous hemangioma of the liver [20].

Sanford et al. reported that proton therapy was associated with significantly fewer post-irradiation liver function exacerbations compared to X-ray therapy. In addition, the incidence of radiation hepatitis was significantly higher in patients with sub-average liver doses higher than the median dose of 21.6 Gy, indicating that minimizing this dose is clinically meaningful [21]. In our case, even though the patient had a benign liver tumor, the total dose was 28.6 Gy, suggesting that radiation exposure to the normal liver should have been reduced. Taddei et al. compared the DVH of irradiation for HCC using a dose distribution chart, and showed that proton therapy lowered the dose to the normal liver compared to X-ray therapy [22]. These results suggest that proton therapy not only minimizes the effect on liver function, but may also reduce the risk of second cancers.

Table 1
Changes in hepatobiliary enzymes before and after PBT.

	Before PBT	At the end of PBT	1 year after PBT	1.5 years after PBT	2 years after PBT	3 years after PBT
AST (U/l)	27	48	29	27	27	26
ALT (U/l)	33	51	29	25	22	18
LDH (U/l)	158	162	147	158	153	162
ALP (U/l)	362	405	275	218	191	277
γ-GTP (U/l)	162	179	73	51	32	22
CHE (U/l)	287	272	277	265	299	275
T-Bil (mg/dl)	1.1	0.7	0.6	0.6	0.8	0.5
Alb (g/dl)	4.5	4.6	4.0	4.2	4.2	4.2

There have been no reports of use of proton beam therapy for hepatic hemangiomas. However, this therapy is likely to be safe for liver hemangiomas because, in our experience, proton beam therapy achieves good local control for other liver tumors without causing severe hepatic damage [23–25]. Hemangiomas require lower doses (20–30 Gy) and smaller margins (about 0–5 mm) compared to malignant liver tumors (≥ 70 Gy, ≥ 10 mm), which suggests that toxicity effects after proton beam therapy for hemangiomas are likely to be mild. Proton beam therapy may significantly reduce the risk of secondary cancer [26–28], which is important because hepatic hemangiomas are benign tumors that occur in young people, and the long-term prognosis after treatment is important. Proton beam therapy for hemangiomas may reduce risks of subsequent hepatic failure and secondary cancer.

Searching in PubMed for articles with “Surgery, Hemangiomas” as the keywords in the past 15 years, there are only five reports about treatment results of surgery for hepatic hemangiomas. Wang et al. reported the laparoscopic surgery of 44 cases of hepatic hemangioma and reported that the median hemorrhage volume was 335 ml and the blood transfusion rate was 9.1% [29]. Wahab et al. operated in 144 patients with giant hepatic hemangioma (median diameter of 10 (5–31) cm) from January 2000 to April 2017. 92 cases were enucleated and hepatectomy was performed in 52 cases [30]. The hemorrhage volume was 400 (50–10,000) ml in the median value of hepatic hemangioma >10 cm (300 pairs 575 ml, $P = 0.007$), and the blood transfusion was 18.1% in less than 10 cm, 51.4% at 10 cm or more. Liu et al. reported that they performed surgery on 141 cases (>20 cm, 36 cases, >10 cm but <20 cm, 105 cases) of huge hemangiomas over 10 cm [31]. And the mean value of hemorrhage was 838.4 ± 998.4 ml, and blood transfusion was 31.2%. In the report of Yang et al., forty-one patients underwent hepatectomy and 53 underwent laparoscopic hepatectomy [32]. The tumor diameter was 8.32 ± 2.49 cm, 7.95 ± 2.01 cm, respectively. Although there was no description of the blood transfusion, the average bleeding quantity was 437.81 ml and 361.69 ml, respectively. Hu et al. reported 19, 13, and 25 cases of robotic hemi-hepatectomy, hemi-hepatectomy, and open hemi-hepatectomy, respectively [33]. Mean volume of the tumor was 553.2 ± 122.3 cm³, 556.2 ± 0.2178 cm³, 667.5 ± 202.6 cm³, respectively. And blood transfusion was 26.3%, 30.8% and 32%, respectively.

Searching in PubMed for articles with the keyword “RFA, Hemangiomas” over the past 15 years, there are only five reports about treatment results of RFA for hepatic hemangiomas. The search resulted in 4 case series and 1 case report [34–38]. The success rate of hemangioma treatment with RFA was around 71–86.5% [34,35]. Hemoglobinuria, renal failure, pleural effusion and hyperbilirubinemia were reported as toxicities by RFA for hemangioma. Risk of blood transfusion looks lower compared to surgery, but the risk of bleeding cannot be reduced to zero. Although, surgery and RFA are common treatment strategy for hemangioma. The risk of bleeding and blood transfusion is inevitable. So the patient that surgery or RFA is difficult (complications, elderly, refuse blood transfusion, etc.) may be a good indication for proton beam therapy.

5. Conclusion

This case is the first reported use of proton beam therapy for a hepatic hemangioma. The successful long-term outcome indicates that this therapy may be useful for a giant liver hemangioma.

Financial disclosure

All authors have no financial relationships associated with the content of the manuscript.

Availability of data and materials

Please contact the corresponding author for data requests.

Ethics approval and consent to participate

The patients signed a consent form prior to initiation of treatment and collection of data.

Declaration of Competing Interest

The authors declare that they have no known competing financial interests or personal relationships that could have appeared to influence the work reported in this paper.

References

- [1] Ishak KG, Rabin L. Benign tumors of the liver. *Med Clin North Am* 1975;59:995–1013.
- [2] Yang Z, Tan H, Liu X, Sun Y. Extremely giant liver hemangioma (50 cm) with Kasabach-Merritt syndrome. *J Gastrointest Surg* 2017;21:1748–9.
- [3] Reddy KR, Kligerman S, Levi J, Livingstone A, Molina E, Franceschi D, et al. Benign and solid tumors of the liver: relationship to sex, age, size of tumors, and outcome. *Am Surg* 2001;67:173–8.
- [4] Hasan HY, Hinshaw JL, Borman EJ, Gegios A, Levenson G, Winslow ER. Assessing normal growth of hepatic hemangiomas during long-term follow-up. *JAMA Surg* 2014;149:1266–71.
- [5] Bioulac-Sage P, Laumonier H, Laurent C, Blanc J, Balabaud C. Benign and malignant vascular tumors of the liver in adults. *Semin Liver Dis* 2008;28:302–14.
- [6] Bajenaru N et al. Hepatic hemangioma – review. *J Med Life* 2015;8(special issue):4–11.
- [7] Okano H et al. Natural course of cavernous hepatic hemangioma. *Oncol Rep* 2001;8(2):411–4.
- [8] Mungovan JA, Cronan JJ, Vacarro J. Hepatic cavernous hemangiomas: lack of enlargement over time. *Radiology* 1994;191(1):111–3.
- [9] Takagi H et al. Diagnosis and management of cavernous hemangioma of the liver. *Semin Surg Oncol* 1985;1(1):12–22.
- [10] Gaspar L, Mascarenhas F, da Costa MS, et al. Radiation therapy in the unresectable cavernous hemangioma of the liver. *Radiother Oncol* 1993;29:45–50.
- [11] Reading NG, Forbes A, Nunnerley HB, Williams R. Hepatic haemangioma: a critical review of diagnosis and management. *Q J Med* 1988;67(253):431–45.
- [12] Leon M, Chavez L, Surani S. Hepatic hemangioma: what internists need to know. *World J Gastroenterol* 2020;26(1):11–20.
- [13] Corigliano N, Mercantini P, Amodio PM, et al. Hemoperitoneum from a spontaneous rupture of a giant hemangioma of the liver: report of a case. *Surg Today* 2003;33:459–63.
- [14] Biswal BM, Sandhu M, Lal P, Bal CS. Role of radiotherapy in cavernous hemangioma liver. *Indian J Gastroenterol* 1995;14(3):95–8.
- [15] Toro A, Mahfouz AE, Ardiri A, et al. What is changing in indications and treatment of hepatic hemangiomas. A review. *Ann Hepatol* 2014;13(4):327–39.
- [16] Oshiro Y, Okumura T, Ishida M, et al. Displacement of hepatic tumor at time of exposure in end-expiratory-triggered-pulse proton therapy. *Radiother Oncol* 2011;99(2):124–30.
- [17] Lee HL et al. CT and MRI findings correlate with the time-course of unresectable cavernous haemangioma of the liver after fractionated radiotherapy. *Br J Radiol* 2012;85(1011):e49–52.
- [18] Moore TA et al. Hepatoma occurring two decades after hepatic irradiation. *Gastroenterology* 1976;71(1):128–32.
- [19] Okazaki N, Yoshino M, Yoshida T, Ohno T, Kitagawa T. Radiotherapy of hemangioma cavernosum of the liver. *Gastroenterology* 1977;73(2):353–6.
- [20] Weshler Z, Sulkes A, Kopolovic J. Squamous cell carcinoma of the renal pelvis as a late complication of hepatic irradiation: a case report. *J Surg Oncol* 1983;22(2):84–6.
- [21] Sanford Nina N, Pursley Jennifer, et al. Protons versus photons for unresectable hepatocellular carcinoma: liver decompensation and overall survival. *Int J Radiat Oncol Biol Phys* 2019;105(1):64–72. *Phys Med Biol.* 2010 December 7; 55(23): 7055–7065..
- [22] Taddei Phillip J, Howell Rebecca M, et al. Risk of second malignant neoplasm following proton versus intensity-modulated photon radiotherapies for hepatocellular carcinoma.
- [23] Mizumoto M, Okumura T, Hashimoto T, et al. Proton beam therapy for hepatocellular carcinoma: a comparison of three treatment protocols. *Int J Radiat Oncol Biol Phys* 2011;81(4):1039–45.
- [24] Mizumoto M, Okumura T, Hashimoto T, et al. Evaluation of liver function after proton beam therapy for hepatocellular carcinoma. *Int J Radiat Oncol Biol Phys* 2012;82(3):e529–35.

- [25] Shosei S, Toshiyuki O, Yoshiko O, et al. Clinical outcomes of previously untreated patients with unresectable intrahepatic cholangiocarcinoma following proton beam therapy. *Radiat Oncol* 2019;14(1):241.
- [26] Sethi RV, Shih HA, Yeap BY, et al. Second nonocular tumors among survivors of retinoblastoma treated with contemporary photon and proton radiotherapy. *Cancer* 2014;120(1):126–33.
- [27] Lautenschlaeger S, Iancu G, Flatten V, et al. Advantage of proton-radiotherapy for pediatric patients and adolescents with Hodgkin's disease. *Radiat Oncol* 2019;14(1):157.
- [28] Tamura M, Sakurai H, Mizumoto M. Lifetime attributable risk of radiation-induced secondary cancer from proton beam therapy compared with that of intensity-modulated X-ray therapy in randomly sampled pediatric cancer patients. *J Radiat Res* 2017;58(3):363–71.
- [29] Wang Y, Ji W, et al. Laparoscopic liver resection and enucleation of liver hemangioma with selective hepatic vascular occlusion: technique and indications. *J Laparoendosc Adv Surg Tech A* 2017;27(9):944–50.
- [30] Wahab MA, Nakeeb NE, et al. Surgical management of giant hepatic hemangioma: single center's experience with 144 patients. *J Gastrointest Surg* 2018;22(5):849–58.
- [31] Liu X, Yang Z, et al. Characteristics and operative treatment of extremely giant liver hemangioma >20 cm. *Surgery* 2017;161(6):1514–24.
- [32] Yan C, Li B, et al. Laparoscopic hepatectomy is superior to open procedures for hepatic hemangioma. *Hepatobiliary Pancreat Dis Int* 2020. S1499-3872(20)30198-3.
- [33] Hu M, Chen K, et al. Robotic, laparoscopic or open hemihepatectomy for giant liver haemangiomas over 10 cm in diameter. *BMC Surg* 2020;20(1):93.
- [34] Qu C, Liu H, et al. Percutaneous ultrasound-guided 'three-step' radiofrequency ablation for giant hepatic hemangioma (5–15 cm): a safe and effective new technique. *Int J Hyperthermia* 2020;37(1):212–9.
- [35] Zou H, Yan J, et al. The new technology of enhanced radiofrequency ablation is safe and effective for treating giant hepatic hemangioma. *Zhonghua Gan Zang Bing Za Zhi* 2012;20(4):261–5.
- [36] Yang X, Liu J, et al. Heme is involved in the systemic inflammatory response following radiofrequency ablation of hepatic hemangiomas. *Eur J Gastroenterol Hepatol* 2020;32(9):1200–6.
- [37] Park SY, Tak WY. Symptomatic-enlarging hepatic hemangiomas are effectively treated by percutaneous ultrasonography-guided radiofrequency ablation. *J Hepatol* 2011;54(3):559–65.
- [38] van Tilborg AAJM, Dresselaars DH, et al. RF ablation of giant hemangiomas inducing acute renal failure: a report of two cases. *Cardiovasc Intervent Radiol* 2016;39(11):1644–8.