

Analysis of prostate cancer localization toward improved diagnostic accuracy of transperineal prostate biopsy

Yoshiro Sakamoto^{1,2}, Kaori Fukaya¹, Masaki Haraoka¹, Kosuke Kitamura¹, Yoichiro Toyonaga¹, Michio Tanaka¹, Shigeo Horie²

¹Department of Urology, Juntendo University Nerima Hospital, Tokyo, Japan

²Department of Urology, Juntendo University Graduate School of Medicine, Tokyo, Japan

Purpose: Delineating the precise localization of prostate cancer is important in improving the diagnostic accuracy of prostate biopsy.

Methods: In Juntendo University Nerima Hospital, initial 12-core or repeat 16-core biopsies were performed using a transrectal ultrasound guided transperineal prostate biopsy method. We step-sectioned prostates from radical prostatectomy specimens at 5-mm intervals from the urethra to the urinary bladder and designated five regions: the (1) Apex, (2) Apex-Mid, (3) Mid, (4) Mid-Base, and (5) Base. We then mapped prostate cancer localization on eight zones around the urethra for each of those regions.

Results: Prostate cancer was detected in 93 cases of 121 cases (76.9%) in the Apex, in 115 cases (95.0%) in the Apex-Mid, in 101 cases (83.5%) in the Mid, in 71 cases (58.7%) in the Mid-Base, and in 23 cases (19.0%) in the Base. In 99.2% of all cases, prostate cancers were detected from the Apex to Mid regions. For this reason, transperineal prostate biopsies have routinely been prioritized in the Apex, Apex-Mid, and Mid regions, while the Base region of the prostate was considered to be of lesser importance. Our analyses of prostate cancer localization revealed a higher rate of cancer in the posterior portion of the Apex, antero-medial and postero-medial portion of the Apex-Mid and antero-medial and postero-lateral portion of the Mid. The transperineal prostate biopsies in our institute performed had a sensitivity of 70.9%, a specificity of 96.6%, a positive predictive value (PPV) of 92.2% and a negative predictive value (NPV) of 85.5%.

Conclusions: The concordance of prostate cancer between prostatectomy specimens and biopsies is comparatively favorable. According to our study, the diagnostic accuracy of transperineal prostate biopsy can be improved in our institute by including the anterior portion of the Apex-Mid and Mid regions in the 12-core biopsy or 16-core biopsy, such that a 4-core biopsy of the anterior portion is included.

Keywords: Needle biopsy, Prostatectomy, Prostate neoplasms

INTRODUCTION

Systematic transrectal biopsy was first introduced by Hodge et al. [1] in 1989, with numerous modifications and adjustments to the procedure subsequently suggested [2,3]. Recently, 10- to 12-core extended prostate biopsies have superseded the sextant biopsy, with greater than 12-core reportedly failing to show any significant increase in cancer detection

rate [4,5]. McNeal et al. [6] reported that 68% of all prostate cancers which they detected was localized in the peripheral zone (PZ), 24% in the transition zone (TZ), and 8% in the central zone. The localization of prostate cancer is known to be different in Japanese patients than in those from Western countries, with a greater tendency for detection in the Apex region in Japan [7-10]. We undertook the current study to improve the diagnostic efficiency of transperineal prostate bi-

Corresponding author: Yoshiro Sakamoto

Department of Urology, Juntendo University Nerima Hospital, 3-1-10 Takanodai, Nerima-ku, Tokyo 177-8521, Japan

E-mail: miandyo@juntendo.ac.jp / Tel: +81-3-5923-3111 / Fax: +81-3-5923-3217

Submitted: 23 April 2014 / Accepted after revision: 17 June 2014

Copyright © 2014 Asian Pacific Prostate Society (APPS)

This is an Open Access article distributed under the terms of the Creative Commons Attribution Non-Commercial License (<http://creativecommons.org/licenses/by-nc/3.0/>) which permits unrestricted non-commercial use, distribution, and reproduction in any medium, provided the original work is properly cited.

<http://p-international.org/>
pISSN: 2287-8882 • eISSN: 2287-903X

opsies performed in Juntendo University Nerima Hospital by analyzing specimens from radical prostatectomies in order to determine the precise localization of prostate cancer.

MATERIALS AND METHODS

1. Materials

We analyzed radical prostatectomy specimens of 121 patients from Juntendo University Nerima Hospital in the period from April 2007 to December 2012. All patients underwent open radical prostatectomy and had preoperative clinical staging of cT2 or under, while none underwent pretreatment such as transurethral resection of the prostate or neoadjuvant hormonal therapy. The patients ranged from 53 to 78 years old, with an average and median age of 67.6 and 68 years, respectively. PSA level at the time of diagnosis ranged from 1.2–32.5 ng/mL, with an average of 8.9 ng/mL and a median level of 7.9 ng/mL. The preoperative clinical stage was cT1 in 37 patients and cT2 in 84 patients. Gleason score (GS) of prostate biopsies were as follows: GS ≤ 6, 41 cases (35.7%); GS = 7, 46 cases (40.0%); GS ≥ 8, 28 cases (24.3%). GS of prostatectomies were as follows: GS ≤ 6, 31 cases (27.0%); GS = 7, 62 cases (53.9%); GS ≥ 8, 22 cases (19.1%). The pathological stages were as follows: pT2a, 27 cases (22.3%); pT2b, 1 case (0.8%); pT2c, 58 cases (48.0%); pT3a, 28 cases (23.1%); and pT3b, 7 cases (5.8%).

2. Methods

The specimens from radical prostatectomy were fixed in formalin, after which sections were step-sectioned at 5-mm intervals. As shown in Fig. 1, the prostate was divided into five regions from the Apex of the urethra to the Base of the urinary bladder, centered around the Mid region, with designations as follows: A, Apex; A-M, Apex-Mid; M, Mid; M-B, Mid-Base; and B, Base. Each region was then divided into eight zones around the urethra, with each region further designated as: E, antero-lateral; F, antero-medial; G, postero-lateral; and H, postero-medial. The transperineal prostate biopsies were performed utilizing ultrasonography equipment (Toshiba Medical Systems Co., Otawara, Japan), using a 7.0-MHz biplane transrectal probe (PVL-715RT) and a BARD MAGNUM (C.R. Bard Inc., Covington, GA, USA) biopsy needle with 22-mm penetration length. The probe was equipped with an adapter (UAGL-001AHA Toshiba Medical Systems Co.) for the biopsy needle running parallel to the probe. In Japanese patients with prostate cancer, the cancer has been reported to localize at a higher frequency in the Apex as compared to patients from Western countries [8,9]. Therefore, we inserted the biopsy needle transperineally, penetrating the prostate capsule, and

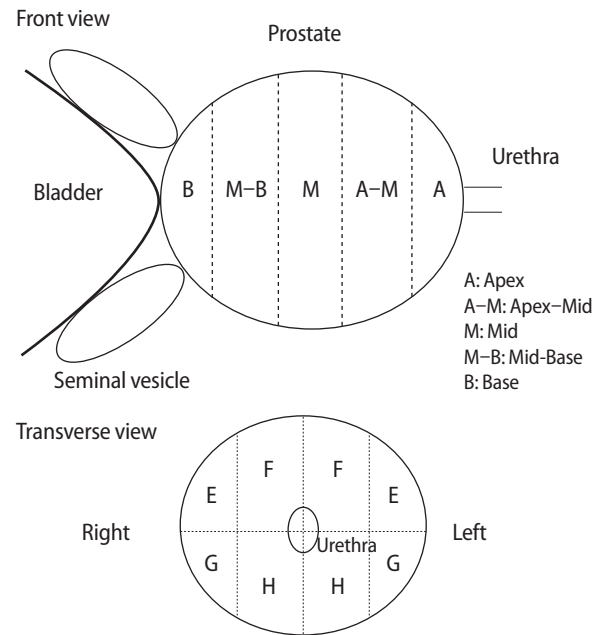


Fig. 1. Five regions from the Apex to the Base and eight zones around the urethra with each region. E, antero-lateral; F, antero-medial; G, postero-lateral; and H, postero-medial.

performing biopsies in the Apex, Apex-Mid, and Mid regions (Fig. 2). Fig. 3 shows the methods of 12-core transperineal biopsies in our institute. Eight-core biopsy samples are taken from the PZ in ①–④, ⑦–⑩ and 4-core biopsy samples are taken from TZ in ⑤, ⑥, ⑪, and ⑫. Repeat biopsies included a supplementary 4 cores in the anterior portion (⑬–⑯) for a total of 16 cores. Although the size and shape of each prostate gland differs from one patient to another, a three-dimensional (transverse, lateral, and front) view of a transperineal prostate biopsy suggests that it is difficult to get samples from the far-lateral region of the Apex in PZ (① and ⑦) and the samples of ① and ② are taken from the Apex-Mid, Mid, and Mid-Base regions. Samples of ②, ③, ⑤, ⑧, ⑨, and ⑪ are taken from a portion of the Apex to the Mid-Base regions, while those of ④, ⑥, ⑩, and ⑫ are taken from the Apex to the Mid regions. Samples of the anterior portion including ⑬, ⑭, ⑮, and ⑯ are taken from the Apex to the Mid regions, with slightly upward inclination of the ultrasound probe and biopsy needle to avoid penetrating the pubic bones. For this reason, we conclude that when the prostate is enlarged, we would be unable to get biopsy specimens from the Base region in our institute. Fig. 4 shows the mapping of cancer locations and biopsy sites in each patient. A total 1,348 cores from biopsies from 110 patients were mapped onto each region and the concordance of prostate cancer in specimens obtained from prostatectomy and biopsy were used in the calculation of sensitivity, specificity, PPV, and NPV.

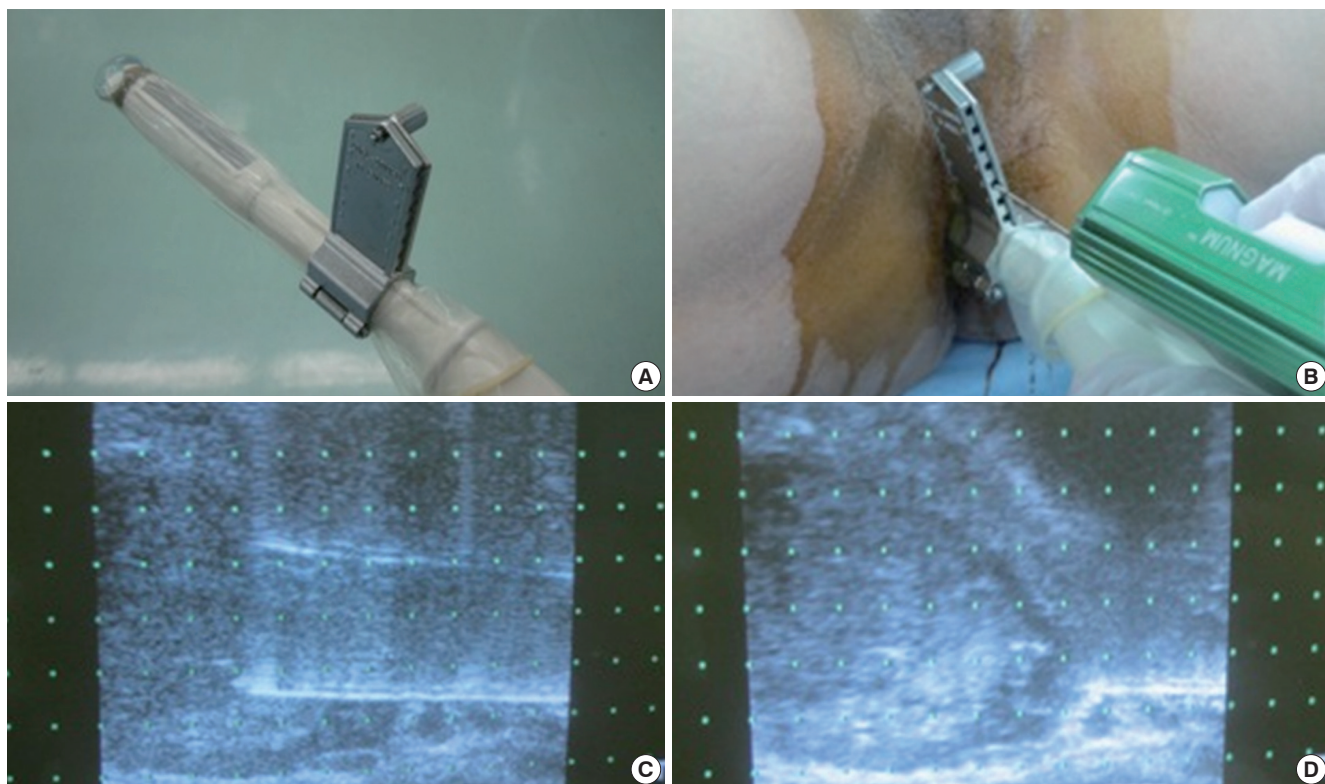


Fig. 2. (A) Ultrasound probe and adapter, (B-D) transperineal prostate biopsy.

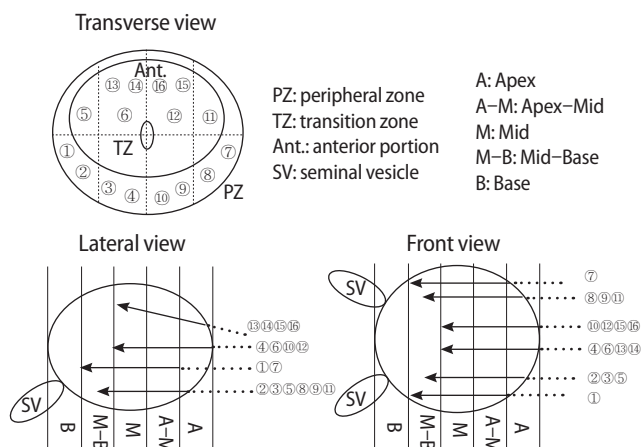


Fig. 3. Transperineal prostate biopsy: transverse view, lateral view, and front view.

RESULTS

As shown in Fig. 4, a total of 121 prostate cancer specimens were each divided into 5 regions for cancer mapping. Out of the 121 cases, 93 cases (76.9%) were found to be localized in the Apex, 115 cases (95.0%) in the Apex-Mid, 101 cases (83.5%) in the Mid, 71 cases (58.7%) in the Mid-Base, and 23 cases (19.0%) in the Base. Ninety-nine point two percent of all cancer cases were detected in the Apex and Apex-Mid re-

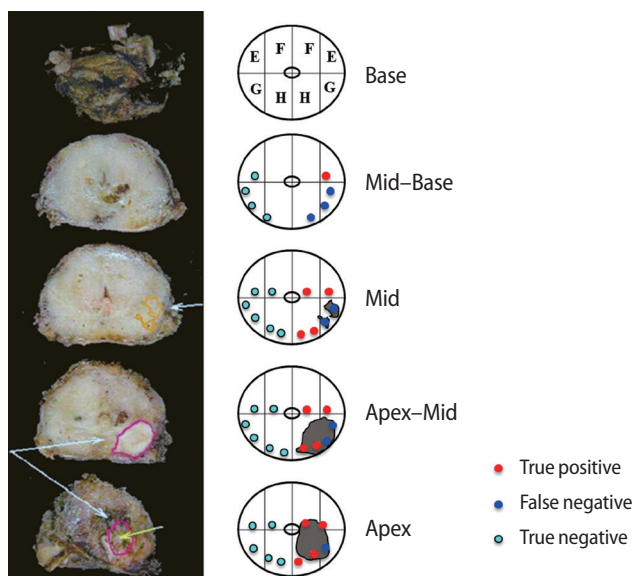


Fig. 4. Transverse view: prostate cancer localization and transperineal prostate biopsy.






gions, 95.5% was detected in the Apex-Mid and Mid regions, and 84.3% was detected in the Mid and Mid-Base regions (Table 1). The frequency of cases where the cancer was detected only in one region was low. Prostate cancer in the Apex alone was detected only in 4 cases (3.3%), there were 6 cases (5.0%) detected in the Apex-Mid region alone, and there were

Table 1. Prostate cancer localization in the Apex, Apex–Mid, Mid, Mid–Base, and Base out of the 121 cases


Region	No. of cases of prostate cancer positive (%)
Apex	93 (76.9)
Apex–Mid	115 (95.0)
Mid	101 (83.5)
Mid–Base	71 (58.7)
Base	23 (19.0)

Ninety-nine point two percent of all cancer cases were detected in the Apex and Apex–Mid regions, 95.5% was detected in the Apex–Mid and Mid regions, and 84.3% was detected in the Mid and Mid–Base regions.

Table 2. The proportion of cancer localization in each region

Region	Frequency of prostate cancer cases (%)				
	E	F	G	H	
Apex	15.6	22.1	45.9	41.0	
Apex–Mid	30.0	52.0	38.1	42.2	
Mid	31.6	45.9	41.8	37.3	
Mid–Base	18.9	27.0	18.0	20.1	
Base	3.7	8.6	4.1	7.8	

Right



Left

no cases where cancer was detected in the Mid, Mid–Base, or Base alone. In 16 cases (13.2%), cancer was detected in all regions from the Apex to the Base.

The frequency of prostate cancer cases in the eight zones in E, F, G, and H is shown in Table 2. In the Apex samples, the frequency of cancer in the posterior area of G and H regions was high at 45.9% and 41.0%, respectively. In Apex–Mid samples, the frequency was also high at 52.0% in the antero-medial area designated as F, while slightly lower frequencies of 30%–40% occurred in regions E, G, and H. In Mid sample, cancer was detected fairly uniformly throughout, but was especially frequent in the antero-medial portion F (45.9%) and the postero-lateral portion G (41.8%). In the Mid–Base, cancer was detected in the antero-medial portion F in 27.0% of cases; cancer was detected in 20% of cases or less elsewhere. In the Base, the frequency of cancer occurrence was low and constituted less than 10% of regions in which cancer was detected at all.

The concordance of prostate cancer in prostatectomy specimens and biopsy sites was analyzed and the resultant sensitivity, specificity, PPV, and NPV are as follows. Three hun-

Table 3. Concordance of prostate cancer in prostatectomy specimen and biopsy

	Prostate cancer (+)	Prostate cancer (–)	Total
Biopsy (+)	344 ^{a)}	29 ^{b)}	373
Biopsy (–)	141 ^{c)}	834 ^{d)}	975
Total	485	863	1,348

Sensitivity (=TP/[TP+FN]), 70.9%; specificity (=TN/[FP+TN]), 96.6%; positive predictive value (=TP/[TP+FP]), 92.2%; negative predictive value (=TN/[TN+FN]), 85.5%.

^{a)}True positive (TP). ^{b)}False positive (FP). ^{c)}False negative (FN). ^{d)}True negative (TN).

dred and seventy-three biopsy cores were positive out of a total of 1,348 cores, and negative in the remaining 975 cores. There were 65 cases in which one to three cores were positive (59.1%), 35 cases in which four to six cores were positive (31.8%), and 10 cases in which seven to twelve cores were positive (9.1%). In our institute, the transperineal prostate biopsy resulted in 29 cores showing false positive results (2.2%), and 141 cores showing false negative results (10.5%), giving rise to a sensitivity of 70.9% and a specificity of 96.6%. The PPV was 92.2%, while the NPV was 85.5% (Table 3). The average prostate volume was 37.0 mL and median volume was 32.8 mL, which were calculated based on 76 cases. We did not find a relationship between prostate volume and accuracy of prostate biopsy.

DISCUSSION

A disparity of prostate cancer localization in radical prostatectomy is recognized between Japanese patients and those of Western countries. Iremashvili et al. [7] reported a 65.4% cancer detection rate in the Apex, a 56.6% detection rate in the Mid, and a 46.3% detection rate in the Base. Ishii et al. [8] reported that at Baylor University and Memorial Sloan Kettering Cancer Center, cancer was detected at the highest rate in the Mid at 58%, followed by the Apex at 36%, and lastly in the Base at 6%. In this study, Apex carcinomas showed a lower tendency for extracapsular extension than Mid or Base carcinomas (27% vs. 43% and 52%, respectively), as well as lower tendencies for seminal vesicle involvement (5% vs. 13% and 20%, respectively). In contrast, Takashima et al. [9] and Sazuka et al. [10] reported that a high proportion of prostate cancers in Japan was detected in the Apex (82.3% and 85%, respectively) that was comparable with the detection rates in the Mid (85.5% and 77%, respectively), and lowest in the Base (48.4% and 22%, respectively). Takahashi et al. [11] reported a higher incidence of cancer in Japan than in the United States in the TZ zone, in which the induration was not palpable by

digital rectal examination. Analysis in our institute based on the five regions yielded a cancer detection rate of 76.9% in the Apex, 95% in the Apex-Mid, 83.5% in the Mid, 58.7% in the Mid-Base, and 19% in the Base. Ninety-nine point two percent of all cancer cases were detected in the Apex and Apex-Mid regions, 95.5% was detected in the Apex-Mid and Mid regions, and 84.3% was detected in the Mid and Mid-Base regions (Table 1). Our analysis, like that of others in Japan, found a high incidence of prostate cancer that could be detected in the Apex. We also found that prostate cancer was generally not limited to only one of the five regions, with detection rates in the Apex or Apex-Mid region alone being under 5%, and no case having cancer detected in the Mid, Mid-Base or Base region alone. Although all patients had pre-operative disease staging of T2 or under, cancer was detected in all 5 regions in 16 patients (13.2%).

Table 2 shows the proportion of cancer localization in each region. In the Apex, cancer most often localized to the posterior portion, while in the Apex-Mid, localization tended to be high in the antero-medial portion. In the Mid, cancer localization tended to be highly frequent in the antero-medial and postero-lateral portions. In the Mid-Base, cancer localization tended to the antero-medial portion, with 20% or less detection elsewhere. Cancer showed low frequency in the Base, with a detection rate of 10% or lower in all areas.

In most institutions in United State, transrectal prostate biopsies are performed, whereas transperineal prostate biopsies are performed at some institutes in Japan and Europe. Kakehi et al. [12] conducted a nationwide survey in Japan, reporting that 76% of biopsies were transrectal, 23% were transperineal, and 1% involved a combined method, with the frequency of complications of biopsies such as fever and sepsis reported as significantly lower in the transperineal biopsies. Emiliozzi et al. [13] conducted 6-core transperineal and 6-core transrectal biopsies on 107 patients, with prostate cancer detected in 43 patients (40%); the transperineal approach yielded 38% (41/107) detection, whereas the transrectal approach yielded 32% (34/107), resulting in a higher detection rate with the transperineal approach. However, as there was no information on the biopsy site, this report could not discriminate between the accuracy of prostate biopsies using the transrectal and transperineal approaches. Of interest to note, despite the report of a high detection rate of cancer in the Apex in Japan by Sazuka et al. [10], transrectal prostate biopsies often result in a false negative for cancer in the Apex, with transperineal prostate biopsy or other precise imaging being reportedly required for detection.

The current study sought to improve the diagnostic accura-

cy of transperineal prostate biopsy by comparing specimens taken from radical prostatectomies and prostate biopsies. In our method, we utilize an 18-G biopsy needle with BARD MAGNUM reusable core biopsy instrument of 22-mm-long tissue core that is guided by transrectal ultrasound (TRUS). Therefore, a tissue collection spanning all regions from Apex to Base cannot normally be achieved with a single biopsy, excluding cases with a small prostate gland. In consideration of studies reporting a high rate of cancer detection in the Apex in Japan [9,10], we have performed transperineal prostate biopsies primarily in the Apex, Apex-Mid, and Mid regions by inserting the biopsy needle transperineally to penetrate the prostate membrane (Fig. 2). As the cancer is rarely detected in the Base region alone, we considered it unnecessary to perform additional biopsies in the Mid-Base to the Base regions at an initial or routine transperineal prostate biopsy for the purpose of improving cancer detection rates. However, it is necessary to perform a repeat biopsy of the Mid-Base, Base and seminal vesicle for a pathological investigation of seminal vesicle involvement. Schulte et al. [14] reported that the concordance rate of prostatectomy specimens and needle biopsy specimens in a 12-core or more extended biopsies using a template resulted in a PPV of 97.3% in the right lobe and 96.7% in the left lobe, with a lower rate in NPV of 24.7% in the right lobe and 31.3% in the left. Huo et al. [15] reported the overall sensitivity of 48% and specificity of 84.1% in a systematic template guided transperineal biopsy and greatest accuracy in the postero-lateral zone. Sensitivity was 59.9%, with the lowest being reported in the anterior apex (38.8%) and lateral zone (41.2%). Rogatsch et al. [16] reported a PPV of 71.1%, a NPV of 75.5%, and a sensitivity of 44.5%, with a positive apical margin and apical tumor involvement at the Apex difficult to estimate through biopsy. Sazuka et al. [10] performed 14-core transrectal prostate biopsies of a 17-mm-long tissue. They performed 12-core biopsies from the PZ and the remaining 2 cores from the TZ. In radical prostatectomy specimens, they detected cancer in the Apex (85%), Middle (75%), Base (22%), and TZ (22%); when they further examined anterior vs. posterior portions in each region, however, they detected cancer at rates of 77%, 53%, 13%, and 16%, respectively, in the anterior, and at 49%, 51%, 13%, and 11%, respectively, in the posterior, with localization in the anterior apex (77%) showing the highest frequency. Analysis of the concordance between radical prostatectomy specimens and the transrectal prostate biopsies revealed 51% true positive, 49% false negative, 17% false positive, and 83% true negative results. The analysis in our institute revealed a false positive in 29 cores (2.2%), a false negative in 141 cores (10.5%), 70.9%

sensitivity, and 96.6% specificity, with a 92.2% PPV and 85.5% NPV, showing comparatively favorable results. There were 65 cases in which one to three cores were positive (59.1%), 35 cases in which four to six cores were positive (31.8%), and 10 cases in which seven to twelve cores were positive (9.1%). These results suggest that the prostate cancers were fairly wide spread in our specimens, although the actual tumor volume could not be calculated. We consider that these facts make some contributions to the diagnostic accuracy of prostate biopsy.

As shown in Fig. 4, initial transperineal prostate biopsies in our institute were performed at 12 sites (①–⑫); repeat biopsies were performed at an additional 2 sites bilaterally of the anterior portion (a 16-core biopsy in total), in consideration of the fact that cancer often localizes in the anterior portion. Transperineal prostate biopsies require a three-dimensional consideration of the prostate. The tissue collection site will vary depending on the method used to insert the biopsy needle. In order to use a probe adapter, we inserted the needle to run parallel with the probe. As the shape and size of the prostate gland varies from person to person, each patient must be considered individually; since accessing the far lateral PZ (① and ⑦) through the Apex region is difficult, we performed tissue collection primarily in the Apex–Mid, Mid and Mid–Base regions. Tissue collections for ②, ③, ⑤, ⑧, ⑨, and ⑩ were performed from part of the Apex through part of the Mid–Base, for ④, ⑥, ⑩, and ⑫ from the Apex through the Mid, and for the anterior portions of ⑬, ⑭, ⑮, and ⑯ from the Apex through the Mid, with the tip of the ultrasound probe tilted upward to avoid penetrating the pubis. In contrast, the Apex is accessible from almost any point when tissue collection is performed similar to a radial or shotgun style biopsy method from the perineum. However, due to the difficulty of this technique, we do not utilize this method. In Japan, most prostate cancer cases are localized in the Apex, Apex–Mid, and Mid, hence when a biopsy needle with a 22-mm-long is utilized, a tissue collection around the region of the prostate membrane facilitates sampling of the Apex, Apex–Mid, and Mid.

Table 2 illustrates the sites showing the greatest predilection for cancer in each region, and these are comparable to biopsy sites from our institute shown in ②–④ and ⑧–⑩. In the Apex, these are the posterior G (45.9%) and H (41.0%). In the Apex–Mid region, cancer was often localized in antero-medial F (52.0%), corresponding to ⑥, ⑫, ⑬, ⑭, ⑮, and ⑯. H showed a slightly lower rate at 42.2%, corresponding to ③, ④, ⑨, and ⑩. Cancer localization was fairly uniform in the Mid, clustering somewhat in the antero-medial F (45.9%), which corresponds to ⑥, ⑫, ⑬, ⑭, ⑮, and ⑯, the and postero-

lateral G (41.8%), corresponding to ①, ②, ⑦, and ⑧.

Analysis of prostate cancer localization shows that, to increase the diagnostic accuracy of the transperineal biopsies, these biopsies: (1) should be performed in the Apex, Apex–Mid, and Mid; (2) need not include the Base when performed routinely; (3) should include the antero-medial area when performed in the Apex; (4) should include the antero-medial and postero-lateral areas when performed in the Apex–Mid; and (5) should include the antero-medial and postero-lateral areas in the Mid, as these areas tend to correlate with a higher detection rate of cancer.

There is no statistically significant difference between the cancer detection rate of transrectal and transperineal prostate biopsies, but in the sextant biopsies there is an improvement of cancer detection rate to add biopsy sites corresponding to the anterior apical region [17] and lateral region [18]. Takenaka et al. [19] performed a prospective comparison of 6- and 12-core transperineal prostate biopsies and reported a statistically significant difference, with the 12-core biopsies yielding a higher cancer detection rate. Merrick et al. [20] performed transperineal template-guided saturation biopsies on 24 sites. Cancer was most often detected in the ventral area of the Apex, but no statistically significant difference was reported. Transperineal prostate biopsy performed on 12 or more cores is usually performed with alternative forms of anesthesia other than local anesthesia. In our institute 12-core transperineal prostate biopsies are carried out under general anesthesia except for advanced cases. We have safely performed approximately 900 transperineal prostate biopsies, without fever, septicemia, or other complications among the patients. According to our study, the diagnostic accuracy of transperineal prostate biopsy can be improved in our institute by including the anterior portion of the Apex–Mid and Mid regions in the 12-core biopsy or 16-core biopsy, such that a 4-core biopsy of the anterior portion is included.

CONFLICT OF INTEREST

No potential conflict of interest relevant to this article was reported.

REFERENCES

1. Hodge KK, McNeal JE, Terris MK, Stamey TA. Random systematic versus directed ultrasound guided transrectal core biopsies of the prostate. *J Urol* 1989;142:71-4.
2. Satoh T, Matsumoto K, Fujita T, Tabata K, Okusa H, Tsuboi T, et al. Cancer core distribution in patients diagnosed by ex-

- tended transperineal prostate biopsy. *Urology* 2005;66:114-8.
3. Scattoni V, Maccagnano C, Zanni G, Angiolilli D, Raber M, Roscigno M, et al. Is extended and saturation biopsy necessary? *Int J Urol* 2010;17:432-47.
 4. Presti JC Jr. Prostate biopsy strategies. *Nat Clin Pract Urol* 2007;4:505-11.
 5. Eichler K, Hempel S, Wilby J, Myers L, Bachmann LM, Kleijnen J. Diagnostic value of systematic biopsy methods in the investigation of prostate cancer: a systematic review. *J Urol* 2006;175:1605-12.
 6. McNeal JE, Redwine EA, Freiha FS, Stamey TA. Zonal distribution of prostatic adenocarcinoma. Correlation with histologic pattern and direction of spread. *Am J Surg Pathol* 1988; 12:897-906.
 7. Iremashvili V, Pelaez L, Jorda M, Manoharan M, Arianayagam M, Rosenberg DL, et al. Prostate sampling by 12-core biopsy: comparison of the biopsy results with tumor location in prostatectomy specimens. *Urology* 2012;79:37-42.
 8. Ishii J, Ohori M, Scardino P, Tsuboi T, Slawin K, Wheeler T. Significance of the craniocaudal distribution of cancer in radical prostatectomy specimens. *Int J Urol* 2007;14:817-21.
 9. Takashima R, Egawa S, Kuwano S, Baba S. Anterior distribution of Stage T1c nonpalpable tumors in radical prostatectomy specimens. *Urology* 2002;59:692-7.
 10. Sazuka T, Imamoto T, Namekawa T, Utsumi T, Yanagisawa M, Kawamura K, et al. Analysis of preoperative detection for apex prostate cancer by transrectal biopsy. *Prostate Cancer* 2013;2013:705865.
 11. Takahashi H, Epstein JI, Wakui S, Yamamoto T, Furusato B, Zhang M. Differences in prostate cancer grade, stage, and location in radical prostatectomy specimens from United States and Japan. *Prostate* 2014;74:321-5.
 12. Kakehi Y, Naito S; Japanese Urological Association. Compliance rates of ultrasound-guided prostate biopsy: a nationwide survey in Japan. *Int J Urol* 2008;15:319-21.
 13. Emiliozzi P, Corsetti A, Tassi B, Federico G, Martini M, Pansadoro V. Best approach for prostate cancer detection: a prospective study on transperineal versus transrectal six-core prostate biopsy. *Urology* 2003;61:961-6.
 14. Schulte RT, Wood DP, Daignault S, Shah RB, Wei JT. Utility of extended pattern prostate biopsies for tumor localization: pathologic correlations after radical prostatectomy. *Cancer* 2008;113:1559-65.
 15. Huo AS, Hossack T, Symons JL, PeBenito R, Delprado WJ, Brenner P, et al. Accuracy of primary systematic template guided transperineal biopsy of the prostate for locating prostate cancer: a comparison with radical prostatectomy specimens. *J Urol* 2012;187:2044-9.
 16. Rogatsch H, Horninger W, Volgger H, Bartsch G, Mikuz G, Mairinger T. Radical prostatectomy: the value of preoperative, individually labeled apical biopsies. *J Urol* 2000;164(3 Pt 1):754-7.
 17. Wright JL, Ellis WJ. Improved prostate cancer detection with anterior apical prostate biopsies. *Urol Oncol* 2006;24:492-5.
 18. Shigemura K, Arakawa S, Yamanaka K, Kataoka N, Yui K, Fujisawa M. Significance of lateral biopsy specimens during transrectal ultrasound-guided prostate biopsies in Japanese men. *Int J Urol* 2007;14:935-8.
 19. Takenaka A, Hara R, Hyodo Y, Ishimura T, Sakai Y, Fujioka H, et al. Transperineal extended biopsy improves the clinically significant prostate cancer detection rate: a comparative study of 6 and 12 biopsy cores. *Int J Urol* 2006;13:10-4.
 20. Merrick GS, Gutman S, Andreini H, Taubenslag W, Lindert DL, Curtis R, et al. Prostate cancer distribution in patients diagnosed by transperineal template-guided saturation biopsy. *Eur Urol* 2007;52:715-23.