



Arthroscopic Harvesting of Autologous Bone Graft for Use as a Mesenchymal Stem Cell Carrier in Anterior Cruciate Ligament Reconstruction

Angelica Marie van Gogh, B.S., Xingguang Li, M.Arch, Gun Min Youn, B.A., Alyssa Alvarez, B.A., Sophia Yin, B.S., Moyukh O. Chakrabarti, M.B.B.S., Patrick J. McGahan, M.D., and James L. Chen, M.D., M.P.H.

Abstract: Anterior cruciate ligament (ACL) tears are detrimental to knee stability and normal function. Although the standard of treatment is an ACL reconstruction, technical improvements are sought to enhance clinical outcomes due to the appreciable failure rate. The use of autologous biologic substances as carriers of stem cells are desirable because of their multipotent properties. Traditionally, the collection of autologous bone grafts is through an open incision of the iliac crest, which causes substantial morbidity to the patient. This Technical Note describes an arthroscopic, minimally invasive collection method of autologous tibial and femoral bone graft to use in backfilling the tunnels during an ACL reconstruction to improve graft incorporation and clinical outcomes.

Up to 200,000 anterior cruciate ligament reconstructions (ACLRs) are performed each year in the United States, with failure rates as high as 20%.¹⁻⁴ Factors of anterior cruciate ligament (ACL) graft failure include traumatic events, inadequate surgical technique, and poor graft integration.¹⁻³ Improper tunnel placement and ACL graft tensioning are common technical errors.¹ Furthermore, biological or mechanical effects can provoke unsuccessful graft integration.²

Graft-to-bone healing is a critical aspect of successful ACLRs. Several studies have focused on improving this process through the use of growth factors and

biomaterials.⁵⁻⁸ Mesenchymal stem cells (MSCs) are self-renewing, multipotent cells found in bone marrow and periosteum.⁹ MSCs possess potential for orthopaedic applications due to their ability to differentiate into bone, cartilage, muscle, tendon, ligament, and fat.⁹ The presented technique uses bone fragments dislodged during femoral and tibial tunnel reaming as the source of bone autograft as an MSC carrier in an ACLR to facilitate tendon–bone healing and graft incorporation.

Surgical Technique

Patient Positioning

The patient is positioned supine on the operating table with a lateral post. Perioperative antibiotics and a peripheral nerve block are administered. General anesthesia is induced. The bony prominences are padded and a tourniquet is applied to the proximal thigh. The lower extremity is prepped and draped in the usual sterile fashion.

Arthroscopic Portal Placement

A standard anterolateral portal is created using a #11 blade and dilated with a blunt trocar. A diagnostic arthroscopy is performed. A standard anteromedial portal is created under needle localization.

Autologous Bone Graft Collection (With Video Illustration)

A non-aggressive shaver and electrocautery are used to debride the femoral and tibial footprints along with

From Advanced Orthopaedics and Sports Medicine, San Francisco, California, U.S.A.

The authors report the following potential conflict of interest or source of funding: J.L.C. is an educational consultant for Arthrex and receives compensation for medical educational lectures and instruction only. Full ICMJE author disclosure forms are available for this article online, as supplementary material.

This investigation was performed at Advanced Orthopaedics and Sports Medicine, San Francisco, CA.

Received July 12, 2019; accepted August 27, 2019.

Address correspondence to Angelica Marie van Gogh, B.S., Advanced Orthopaedics and Sports Medicine, 450 Sutter St., Suite 400, San Francisco, CA 94108. E-mail: avangog1@berkeley.edu

© 2019 by the Arthroscopy Association of North America. Published by Elsevier. This is an open access article under the CC BY-NC-ND license (<http://creativecommons.org/licenses/by-nc-nd/4.0/>).

2212-6287/19888

<https://doi.org/10.1016/j.eats.2019.08.018>

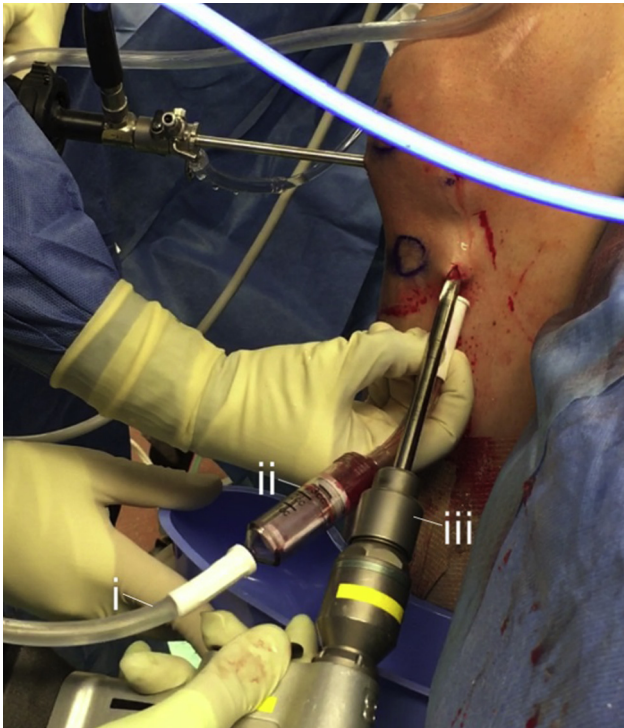


Fig 1. Operative imaging of reaming the femoral tunnel through the anterior tibial incision of the right knee and autologous femoral bone graft collection with GraftNet Autologous Tissue Collector attached to suction. (i) Suction; (ii) GraftNet Autologous Tissue Collector; and (iii) reamer.

residual graft fibers. A 55° tibial guide is inserted into the anteromedial portal and positioned posterior to the anterior horn of the lateral meniscus. An incision over the anterior tibia is created with a #15 blade and dilated. A Beath pin is fired through the tibial guide. A GraftNet Autologous Tissue Collector (Arthrex, Naples, FL) is attached to suction tubing. The tibial tunnel is barrel reamed over the Beath pin while suction is used to collect bone fragments (Fig 1, Video 1). The Achilles allograft is trimmed corresponding to tibial tunnel diameter, whipstitched, loaded onto an ACL TightRope (Arthrex), and tensioned. A corresponding over-the-top guide is inserted into the anteromedial portal and positioned in the intercondylar notch. The knee is hyperflexed. A Beath pin is fired bicortically through the femur and the condylar width is measured. The femoral socket is barrel reamed over the Beath pin. Then the bone fragments are collected with the GraftNet device (Arthrex) attached to the shaver suction (Fig 2, Video 1).

Bone Graft Preparation

A total of 5 mL of blood is drawn from the patient. The collected bone fragments are placed into a specimen cup (Fig 3A, Video 1). Each bone graft is prepared by mixing half the collected bone fragments with 2 mL

of blood (Fig 3B, Video 1). The bone graft is loaded into the BioXpress Graft Delivery device (Arthrex) (Fig 4, Video 1).

ACL With Achilles Allograft and Femoral Tunnel Backfilling

A 0-Vicryl suture is attached to the end of the Beath pin, passed through the femoral tunnel, and clamped. The BioXpress device is used to backfill the femoral tunnel with the prepared bone autograft (Fig 5, Video 1). The 0-Vicryl suture is unclamped and a suture grasper is used to pass the looped end of the suture through the tibial tunnel. The TightRope and graft are loaded onto the 0-Vicryl and passed using the suture. The TightRope button is flipped firmly against the lateral femoral cortex. Mini C-arm radiographs are taken to confirm button placement. The graft is fixed into the femoral tunnel by tensioning the white tension sutures of the TightRope. The knee is cycled 20 times to remove graft creep.

Tibial Tunnel Backfilling

The knee is repositioned into near-full extension. The tibial tunnel trajectory is confirmed with a nitinol wire. After dilation, a biocomposite fast thread interference screw is screwed into the tibial tunnel while a posterior drawer is applied to the knee (Video 1). The BioXpress

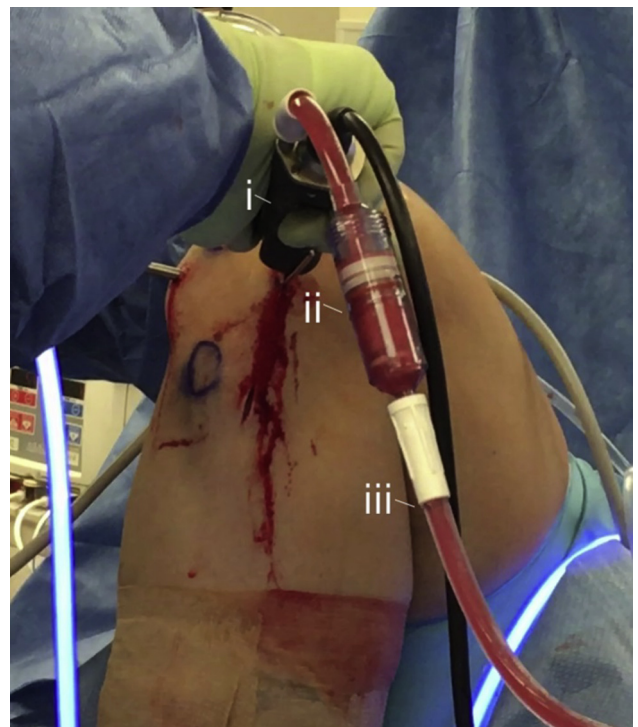


Fig 2. Operative imaging of autologous tibial bone graft collection with GraftNet Autologous Tissue Collector attached to the suction of the shaver. The shaver is inserted into the anteromedial portal of the right knee. (i) Shaver; (ii) GraftNet Autologous Tissue Collector; and (iii) suction.

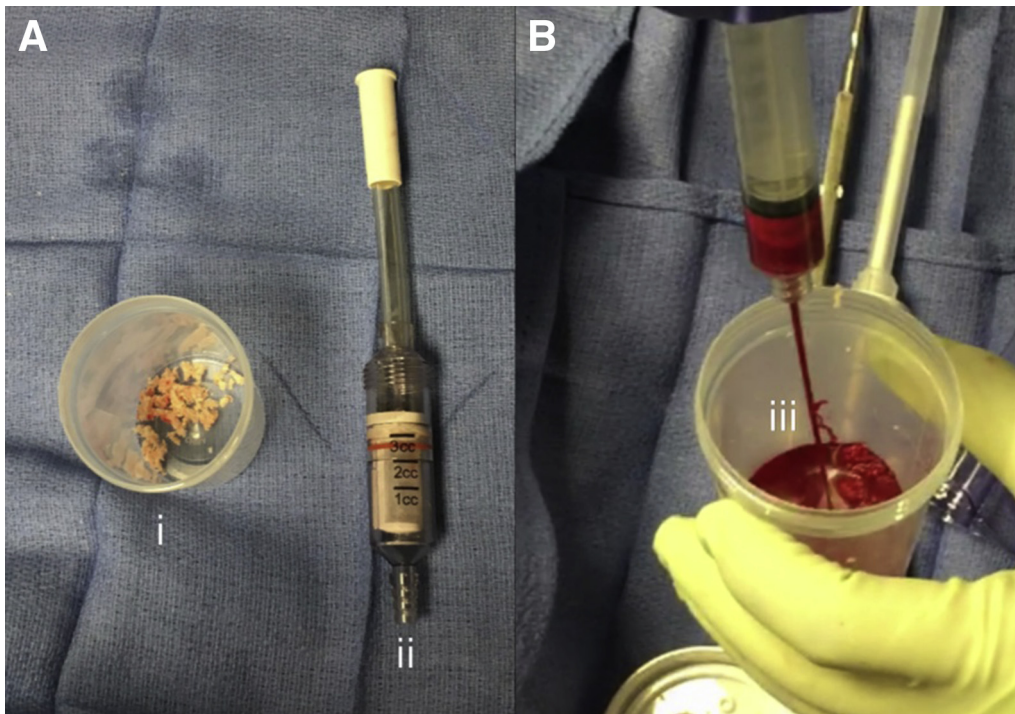


Fig 3. (A) Image of (i) collected autologous bone fragments and (ii) GraftNet Autologous Tissue Collector. (B) Image of (iii) autologous bone fragments mixed with autologous blood.

device is used to deliver the prepared bone autograft into and over the interference screw (Fig 6, Video 1).

The arthroscope is reinserted into the knee joint and the white sutures are re-tensioned. The graft integrity is tested with a probe. A tibial tug test is performed on the sutures exiting the tibial tunnel. Excess graft and sutures are removed. The incision site is irrigated and excess fluid is suctioned. The incisions are closed and dressed in the standard fashion.

Postoperative Care

The patient is placed in a knee extension brace locked in full extension. Patients are encouraged to achieve 90° flexion by their first postoperative visit. Formal physical therapy begins after the first postoperative visit.

Discussion

ACLRs are corrective procedures for ACL tears and are among the most common orthopaedic surgeries performed.¹ However, their failure rate motivates a pursuit for improvement.¹⁻³ Poor graft integration prompts scar tissue development and inferior mechanical properties.¹⁰ Moreover, enhancing primary ACL reconstructions will help reduce the frequency of revision ACL procedures that have inferior outcomes.¹¹ Therefore, improving the speed and

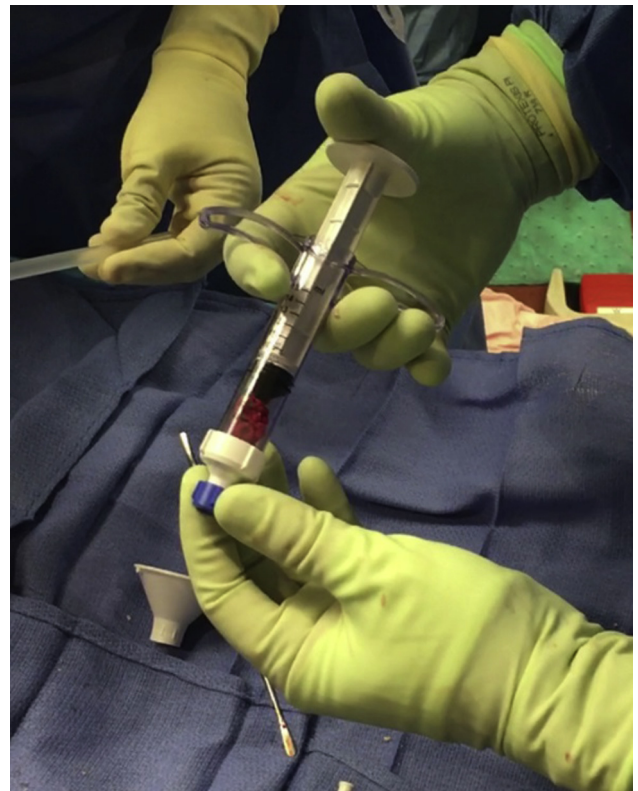


Fig 4. Image of BioXpress Graft Delivery device loaded with autologous bone graft.

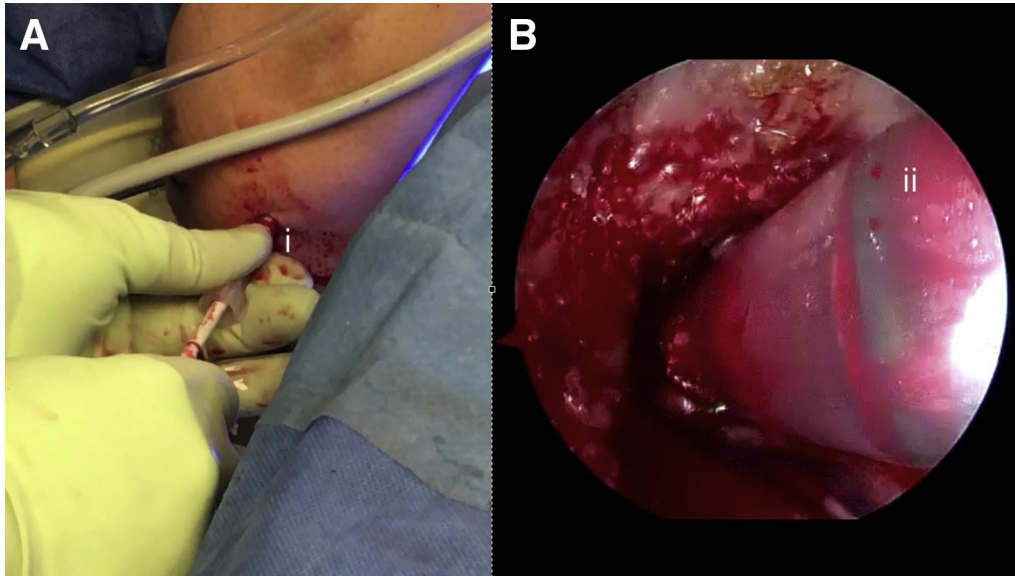


Fig 5. (A) Operative image of autologous bone grafting of the femoral tunnel through the anteromedial portal of the right knee. (I) BioXpress Graft Delivery cannula and plunger. (B) Arthroscopic view of autologous bone grafting of the femoral tunnel through the anteromedial portal of the right knee. (ii) BioXpress cannula in the femoral tunnel.

quality of graft integration would improve overall clinical outcomes.⁵

Several studies have analyzed the effects of MSCs on promoting tendon-to-bone healing.⁵⁻⁸ MSCs are multipotent, self-renewing cells derived from various tissues, including bone.^{6,12} Their osteogenic abilities show promise in bone, muscle, and ligament regeneration applications.¹² According to Setiawati et al.,⁵ MSCs improve angiogenesis and osteogenesis of the graft within the tunnel. Both Setiawati et al.⁵ and Lim et al.⁷ used MSCs in rabbit ACLRs that resulted in biomechanically superior ACLRs with more native ACL chondral entheses compared with controls. Although promising, the efficacy of MSCs *in vivo* remains inconclusive, as there are studies that show no improvement upon MSC treatment.⁸ Various growth factors, such as transforming growth factor- β (TGF- β), are also present in bones.^{13,14} A study examining the injection of upregulating TGF- β MSCs into osseous tunnels during rabbit ACLRs found tighter entheses, reduced scar tissue, sealed bone tunnels, and greater quantities of cell types indicative of healing compared with controls.⁶ Moreover, they found that overexpression of TGF- β promoted greater maximum load, rigidity, new bone formation, and mineral density—which are integral to achieving robust graft fixation.⁶

The proposed ACL technique uses an autologous bone graft prepared from bone fragments generated during typical femoral and tibial tunnel reaming as an MSC carrier. Harvesting the bone graft in this manner for ACLRs combats harvesting complications that arise from the more common iliac crest bone grafts (Table 1).^{15,16} Comparative studies report reduced donor morbidity, more plentiful MSCs and growth

factors, and greater levels of gene expression corresponding to vascular, skeletal, and hematopoietic tissues in bone grafts derived from similar techniques

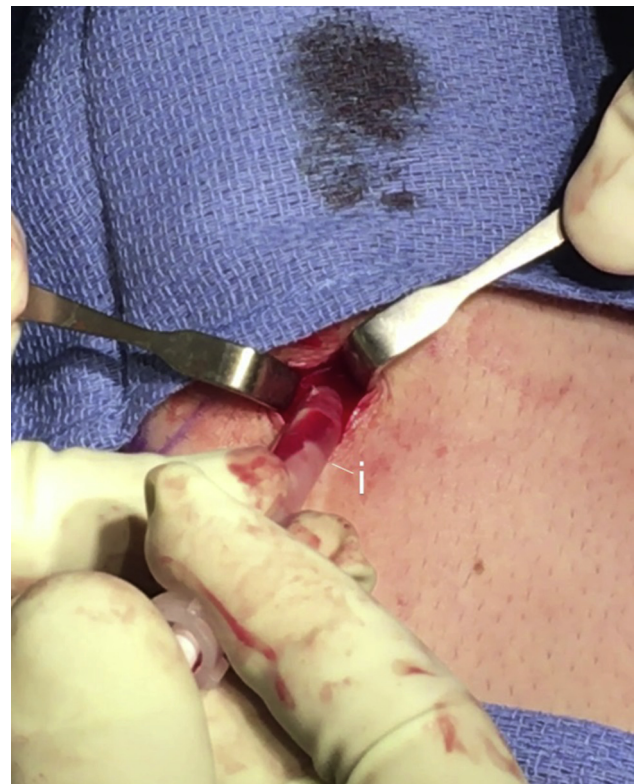

Fig 6. Operative image of autologous bone grafting into the fast thread interference screw in the tibial tunnel through the anterior incision of the right tibia. (i) BioXpress Graft Delivery cannula and plunger.

Table 1. Advantages and Disadvantages to Autologous Iliac Crest Bone Grafts¹⁶

Advantages	Disadvantages
<ul style="list-style-type: none"> • Autografts possess mesenchymal stem cells and growth factors • Autografts possess osteoconductive, osteoinductive, and osteogenic properties • Expedite graft-to-host integration with better quality and lower failure rates compared with allografts • No risk of allogeneic disease 	<ul style="list-style-type: none"> • Prolonged operation time • Increased risk of donor-site morbidity • Increased risk of infection • Limited graft quantity

Table 2. Advantages and Disadvantages of Backfilling Anterior Cruciate Ligament Reconstruction Tunnels With Autologous Bone Graft Derived From the Femoral and Tibial Tunnels

Advantages	Disadvantages
<ul style="list-style-type: none"> • May improve anterior cruciate ligament graft-to-host integration • Bone autograft poses no risk of allogeneic disease • Concurrent bone collection during reaming minimizes donor site morbidity, operation time, and risk of infection associated with iliac crest bone grafts 	<ul style="list-style-type: none"> • Longer operating time than typical anterior cruciate ligament reconstruction due to additional bone grafting procedure • Increased risk of infection due to extended operating time • Greater financial burden

Table 3. Pearls and Pitfalls to Backfilling Anterior Cruciate Ligament Reconstruction Tunnels With Autologous Bone Graft Derived From the Femoral and Tibial Tunnels

Pearls	Pitfalls
<ul style="list-style-type: none"> • Pass the button through the femoral socket before backfilling with bone graft, then secure the anterior cruciate ligament graft by dunking it into the femoral socket. • Take care when transferring bone autograft from the GraftNet device to the specimen cup to prevent bone autograft spillage. • Place the suction directly below the reamer to collect tibial fragments. 	<ul style="list-style-type: none"> • Backfilling the femoral tunnel with autologous bone graft before passing the TightRope button may obstruct passage of the TightRope and anterior cruciate ligament graft. • Excess fluid in the knee or a high blood-to-graft ratio during bone autograft preparation can lead to graft leakage from the femoral tunnel.

when compared to iliac crest bone grafts harvesting.^{15,16} The addition of backfilling tunnels with bone autograft to traditional ACLR methods is performed to improve ACL graft integration and overall healing and rehabilitation. Disadvantages (Table 2) include prolonged operative time, increased risk of infection, and other biological complications without definitive benefits.¹⁶ Further research is needed to better understand the realistic potential of bone grafting effects in ACLRs as many studies are limited to animal models and short-term analyses. However, this Technical Note establishes a proof of technique concept that can be incorporated by operators into their own ACLR and revision procedures if so desired. Pearls and pitfalls are listed in Table 3.

References

1. Wilde J, Bedi A, Altchek DW. Revision anterior cruciate ligament reconstruction. *Sports Health* 2014;6:504-508.
2. Grote S, Helfen T, Mück F, Regauer M, Prall W. Femoral marrow cavity bone harvesting used for arthroscopic refilling of misplaced or enlarged bone tunnels in revision ACL surgery: An arthroscopically supported technique with antegrade intramedullary bone harvesting by a reamer-irrigator-aspirator (RIA) system. *Knee Surg Sports Traumatol Arthrosc* 2015;23:808-815.
3. Prall W, Kusmenkov T, Fürmetz J, et al. Outcomes of revision anterior cruciate ligament reconstruction secondary to reamer-irrigator-aspirator harvested bone grafting. *Injury* 2019;50:467-475.
4. Lynch T, Parker R, Patel R, Andrish J, Spindler K. The impact of the Multicenter Orthopaedic Outcomes Network (MOON) research on anterior cruciate ligament reconstruction and orthopaedic practice. *J Am Acad Orthop Surg* 2015;23:154-163.
5. Setiawati R, Utomo D, Rantam F, Ifran N, Budhiparama N. Early graft tunnel healing after anterior cruciate ligament reconstruction with intratunnel injection of bone marrow mesenchymal stem cells and vascular endothelial growth factor. *Orthop J Sports Med* 2017;5:1-8.
6. Wang R, Xu B, Xu H. Up-regulation of TGF- β promotes tendon-to-bone healing after anterior cruciate ligament reconstruction using bone marrow-derived mesenchymal stem cells through TGF- β /MAPK signaling pathway in a New Zealand white rabbit model. *Cell Physiol Biochem* 2017;41:213-226.
7. Lim J, Hui J, Li L, Thambyah A, Goh J, Lee E. Enhancement of tendon graft osteointegration using mesenchymal stem cells in a rabbit model of anterior cruciate ligament reconstruction. *Arthroscopy* 2004;20:e899-e910.
8. Kanazawa T, Soejima T, Noguchi K, et al. Tendon-to-bone healing using autologous bone marrow-derived

- mesenchymal stem cells in ACL reconstruction without a tibial bone tunnel—a histological study. *Muscles Ligaments Tendons J* 2014;4:201-206.
9. Lee E, Hui J. The potential of stem cells in orthopaedic surgery. *J Bone Joint Surg Br* 2006;88-B:841-851.
 10. Song F, Jiang D, Wang T, et al. Mechanical loading improves tendon-bone healing in a rabbit anterior cruciate ligament reconstruction model by promoting proliferation and matrix formation of mesenchymal stem cells and tendon cells. *Cell Physiol Biochem* 2017;41:875-889.
 11. Chen JL, Allen CR, Stephens TE, et al. MARS Group. Differences in mechanisms of failure, intraoperative findings, and surgical characteristics between single- and multiple- revision ACL reconstructions. *Am J Sports Med* 2013;41:1571-1578.
 12. Hofer H, Tuan R. Secreted trophic factors of mesenchymal stem cells support neurovascular and musculoskeletal therapies. *Stem Cell Res Ther* 2016;7:e1-e14.
 13. Di Matteo B, Loibl M, Andriolo L, et al. Biologic agents for anterior cruciate ligament healing: A systematic review. *World J Orthop* 2016;7:592-603.
 14. Wu M, Chen G, Li Y. TGF- β and BMP signaling in osteoblast, skeletal development, and bone formation, homeostasis and disease. *Bone Res* 2016;4:e16009.
 15. Dimitriou R, Mataliotakis G, Angoules A, Kanakaris N, Giannoudis P. Complications following autologous bone graft harvesting from the iliac crest and using the RIA: A systematic review. *Injury* 2011;42:S3-S15.
 16. Wang W, Yeung K. Bone grafts and biomaterials substitutes for bone defect repair: A review. *Bioactive Mater* 2017;2:224-247.