

Available online at www.sciencedirect.com

ScienceDirect

journal homepage: www.elsevier.com/locate/ihj

Case Report

Absent right coronary artery: A case of single coronary artery or congenital ostial atresia?



Mohit D. Gupta^{a,*}, M.P. Girish^a, Vickram Vignesh^b, Poonam Narang^c,
Vijay Trehan^d, Sanjay Tyagi^d

^a Associate Professor of Cardiology, Department of Cardiology, GB Pant Institute of Postgraduate Medical Education and Research, New Delhi, India

^b Senior Resident Cardiology, Department of Cardiology, GB Pant Institute of Postgraduate Medical Education and Research, New Delhi, India

^c Professor of Radiology, Department of Cardiology, GB Pant Institute of Postgraduate Medical Education and Research, New Delhi, India

^d Professor of Cardiology, Department of Cardiology, GB Pant Institute of Postgraduate Medical Education and Research, New Delhi, India

ARTICLE INFO

Article history:

Received 9 August 2015

Accepted 25 November 2015

Available online 23 December 2015

Keywords:

Coronary artery anomaly

Intercoronary communication

Coronary artery atresia

Single coronary artery

ABSTRACT

Atresia of the right coronary artery ostium is a rare anatomic variant of the coronary circulation. It is often difficult to differentiate from single coronary artery. Its presence unassociated with any other anomaly has never been described in an adult individual. We report this unusual anomaly and discuss its anatomical and pathophysiological significance and possible ways to differentiate from single coronary artery.

© 2015 Cardiological Society of India. Published by Elsevier B.V. All rights reserved.

1. Introduction

Coronary artery anomalies have been identified in 0.6–1.5% of coronary angiograms.¹ Among the coronary artery anomalies, the least frequently observed is coronary artery ostial atresia (COSA)² and single coronary arteries. While the atresia of the left coronary artery ostium is a rare anatomic variant of the coronary circulation, atresia of the right coronary

artery ostium is exceedingly rare and its existence unassociated with any anomaly has not been reported in adults till date.² We report congenital ostial atresia of right coronary artery (RCA). The left circumflex artery (LCx) through an unusual intercoronary communication continued in the right atrioventricular groove (AV groove) as the RCA. The possibility of this being a single coronary artery is also discussed. Such a course has never been reported in the literature.

* Corresponding author.

E-mail address: drmohitgupta@yahoo.com (M.D. Gupta).

<http://dx.doi.org/10.1016/j.ihj.2015.11.038>

0019-4832/© 2015 Cardiological Society of India. Published by Elsevier B.V. All rights reserved.

2. Case

A 62-year-old male patient, with no conventional coronary risk factors, presented with chest pain of atypical nature for the past 20 days. Clinical examination did not reveal any significant findings. Electrocardiogram was normal. Two-dimensional echocardiogram showed normal global left ventricular ejection fraction with no regional wall motion abnormality. The patient also had osteoarthritis involving both the knees, rendering him unable to perform an exercise treadmill test. After taking informed consent, the patient was subjected to diagnostic coronary angiography. Selective angiogram of left coronary artery (LCA) revealed normal left anterior descending (LAD) artery and LCx. The distal LCx was continuing in the right AV groove as the RCA in its usual course (Fig. 1 and Video 1). Selective angiogram of the RCA did not reveal any evidence of stump of the RCA. The LCx continued in left AV groove to the right AV groove as normal caliber RCA through intercoronary communication (also called as coronary cascade) (Fig. 1). To further ascertain the same, simultaneous angiogram of left and right coronary system was done which clearly revealed ostial atresia of RCA and filling of RCA from LCA through intercoronary communication (Fig. 2 and Video 2). Further, CT coronary angiography of the patient was done to confirm this unusual coronary anatomy. The origin of RCA could not be demonstrated from the right sinus. Instead it was filling retrogradely from the LCA via intercoronary communication (Fig. 3). Such COSA of RCA in an adult has never been described earlier.

Supplementary Videos 1 and 2 related to this article can be found, in the online version, at [doi:10.1016/j.ihj.2015.11.038](https://doi.org/10.1016/j.ihj.2015.11.038).

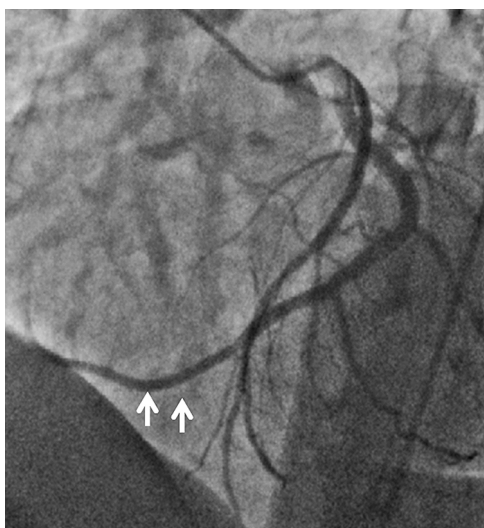


Fig. 1 – Coronary angiogram of left coronary artery in LAO – cranial view showing normal left anterior descending artery and Left circumflex artery. Also evident is retrograde opacification of right coronary artery from intercoronary communication (white arrows).

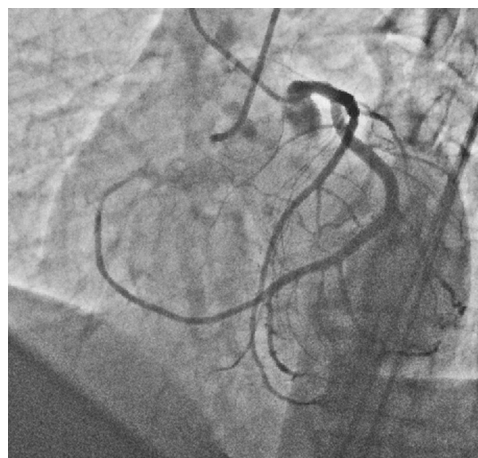


Fig. 2 – Simultaneous coronary angiogram of RCA and LCA in LAO – cranial view showing ostial atresia of RCA and opacification of RCA by intercoronary communication from left circumflex artery running in AV groove.

3. Discussion

Among all cases of anomalous origin and distribution of the coronary arteries, isolated congenital ostial atresia (COSA) of a coronary artery is extremely rare and seldom reported.³ Further, COSA of RCA is extremely rare and its presence in absence of any associated abnormality has never been reported.³ Only one case of right COSA associated with congenital pulmonic valve disease has been reported till date.² There are two fundamental features that are common in all different forms of COSA: first the defect is congenital, although progression in prenatal and postnatal life can occur.³ Second, the developmental defect causes ostial or proximal coronary obstruction. Distinguishing congenital atresia of the ostium from acquired ostial stenosis/atresia is also important. Few features are suggestive of congenital presence of COSA. Most important is the presence of only 1–2 full diameter connecting collateral vessels (without narrowing at the junction of the two vessels).³ In the present case also, RCA was filling retrogradely through intercoronary communication/full diameter collateral vessel from LCx continuing in the left AV groove toward the RCA. On the contrary, in postnatally acquired collateral vessels, often dense network of channels are expected that often enlarge progressively after birth.³ Further, absence of typical clinical angina and lack of evidence of myocardial scarring is highly suggestive of COSA. Absence of ostial stump on CT coronary angiography is also suggestive of R-COSA. Several acquired causes of coronary ostial and proximal stenosis must be ruled out in an adult patients. These include atherosclerosis, syphilis, Kawasaki, and takayasu arteritis.^{3,4} None of these were evident in our patient.

Congenital atresia of the RCA should be considered different from RCA arising from single coronary trunk,⁵ even though the LCA supplies circulation in both conditions. This is because in the prior condition, RCA circulation is completely dependent on LCA patency.³ In the present case, RCA was filling retrogradely almost up to its proximal part by LCx

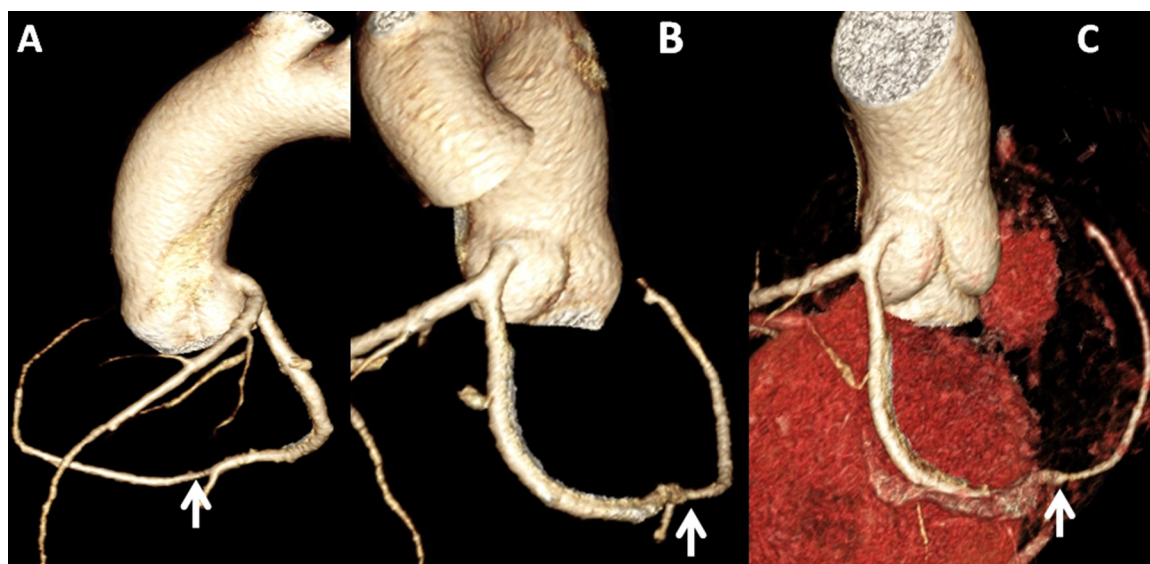


Fig. 3 – Coronary CT projections in different views (subtracted and un-subtracted images) showing ostial atresia of RCA and retrograde filling of RCA from left circumflex artery through coronary cascade.

continuing in the right AV groove. However, on CT coronary angiography, ostial stump of the RCA was not visualized. Lipton et al. have suggested that in congenital ostial atresia or hypoplasia, a small stump may be detected⁶ though this may not always be the case. Possibility of this being a case of single coronary artery (RCA arising from LCx: Lipton L1 type) cannot be denied. Single coronary artery with origin of RCA from LCx has been reported to have an incidence of 0–0.035%.⁷ It is interesting to note that three major collateral pathways at the cono-truncal level provide circulation between the right and left coronary systems in all congenital or acquired forms of one-sided coronary artery occlusion. These pathways are usually used as basis for different classifications.⁵ These include the pre-conal ring, also known as Vieussens' arterial ring, comprising of right pulmonary conus branches arising from the RCA or the aorta and left conus branches arising from the left main or proximal LAD arteries. The retroconal anastomotic ring forms connections from the right and left coronaries through collaterals, which traverse in the inter-arterial space behind the MPA but anterior to the ascending aorta. The retroaortic anastomotic ring, also known as the Kugel atrial anastomotic network, communicates with the proximal right and left coronary systems together or individually with a distal coronary system through the interatrial septum.⁵ The present case probably falls in the retroaortic anastomotic ring, but it is noteworthy that the RCA was filling mainly from the terminal LCx. Such a communication is often known as coronary cascade or intercoronary communication.

Analyzing all angiographic views and CT coronary angiogram together, the present case may be an extremely rare ostial atresia of RCA filling retrogradely from LCx through coronary cascade or an equally uncommon case of single

coronary artery with LCx continuing as the RCA in its usual anatomic position.

Conflicts of interest

The authors have none to declare.

REFERENCES

1. Musiania A, Cernigliarob C, Sansab M, Masellia D, De Gasperisa C. Left main coronary artery atresia: literature review and therapeutical considerations. *Eur J Cardiothorac Surg.* 1997;11:505–514.
2. Saremi F, Goodman G, Wilcox A, Salibian R, Vorobiof G. Coronary artery ostial atresia: diagnosis of conotruncal anastomotic collateral rings using CT angiography. *JACC Cardiovasc Imaging.* 2011;4:1320–1323. <http://dx.doi.org/10.1016/j.jcmg.2011.09.018>.
3. Angelini P. Congenital coronary artery ostial disease: a spectrum of anatomic variants with different pathophysiologies and prognoses. *Tex Heart Inst J.* 2012;39:55–59.
4. Kumar GV, Agarwal NB, Javali S, Patwardhan AM. Takayasu's arteritis with ostial and left main coronary stenosis. *Tex Heart Inst J.* 2007;34:470–474.
5. Lipton MJ, Barry WH, Obrez I, Silverman JF, Wexler L. Isolated single coronary artery: diagnosis, angiographic classification, and clinical significance. *Radiology.* 1979;130:39–47.
6. Lipton LJ, Barry WH, Obrez E, et al. Isolated single coronary artery: diagnosis, angiographic classification and clinical significance. *Radiology.* 1979;130:39–47.
7. Yamanaka O, Hobbs R. Coronary artery anomalies in 126,595 patients undergoing coronary arteriography. *Catheter Cardiovasc Diagn.* 1990;21:28–40.