

Medial Patella Femoral Ligament Reconstruction With Periosteal Tunnels and Suture Fixation



Jefferson Brand, M.D., Richard Hardy, Ed.D., A.T.C., and
Paul Westerberg, M.A., A.T.C., O.T.C.

Abstract: Lateral patellar dislocations can damage the medial patella femoral ligament. Nonoperative care is preferred but some tears may require a surgical intervention. Patella fractures are considered a risk factor after surgery. The technique described in this Technical Note avoids any bone tunnel drilling, which may eliminate the possibility of a patella fracture. The surgical procedure uses periosteal fibro-osseous tunnels to a double-limbed gracilis graft to reconstruct the upper and lower borders as conventionally used for medial patella femoral ligament reconstruction. Once the graft is tensioned, it is sutured to the periosteal fibro-osseous tunnel with 2 sutures on the medial side and at least 1 suture on the lateral side of each periosteal fibro-osseous sleeve. Each of the 2 periosteal fibro-osseous tunnels has 3 to 4 sutures securing the graft. After surgery, the patients complete 5 phases of rehabilitation to reduce swelling and to regain their strength and range of motion.

Patella dislocations comprise approximately 2% to 3% of all knee injuries. On dislocation, a pop is often felt and swelling of the knee ensues.¹ Damage may occur to the articular cartilage of the lateral femoral condyle and medial patella, medial patella femoral ligament (MPFL), and vastus lateralis oblique muscle.² MPFL injuries typically occur with lateral patellar dislocations because this ligament contributes approximately 60% of the medial restraining force.³ When the MPFL is injured, nonoperative care is the choice of treatment.⁴ However, patellofemoral pain complicated by recurrent instability is a complication to nonoperative treatment.⁵ MPFL reconstruction that addresses only ligamentous factors has led to sufficient clinical results and low redislocation rates.⁶ Unfortunately, patella fractures have been reported in the literature as a complication after MPFL surgery. As our

technique avoids any bone tunnel or drilling, it may eliminate the possibility of patella fracture after MPFL reconstruction. The purpose of this Technical Note is to present an MPFL reconstruction technique with suture fixation in periosteal tunnels for patella fixation.

Surgical Technique

Preoperative Evaluation

The preoperative examination requires insight concerning the history of the patient's initial injury, episodes of

From Department of Orthopedics and Sports Medicine, Heartland Orthopedic Specialists, Alexandria, Minnesota, U.S.A.

The author reports the following potential conflicts of interest or sources of funding: J.B. is Deputy Editor for Journal of Arthroscopy. Full ICMJE author disclosure forms are available for this article online, as [supplementary material](#).

Received March 28, 2017; accepted July 14, 2017.

Address correspondence to Richard Hardy, Ed.D., A.T.C., Douglas County Hospital, 111 17th Ave E Ste 101, Alexandria, MN 56308, U.S.A. E-mail: rhardy@heartlandorthopedics.com

© 2017 by the Arthroscopy Association of North America. Published by Elsevier. This is an open access article under the CC BY-NC-ND license (<http://creativecommons.org/licenses/by-nc-nd/4.0/>).

2212-6287/17419

<http://dx.doi.org/10.1016/j.eats.2017.07.019>

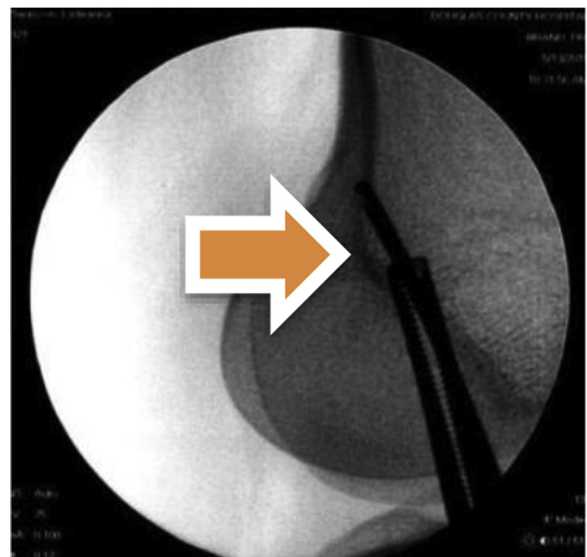


Fig 1. Guide pin is marked with a clamp.

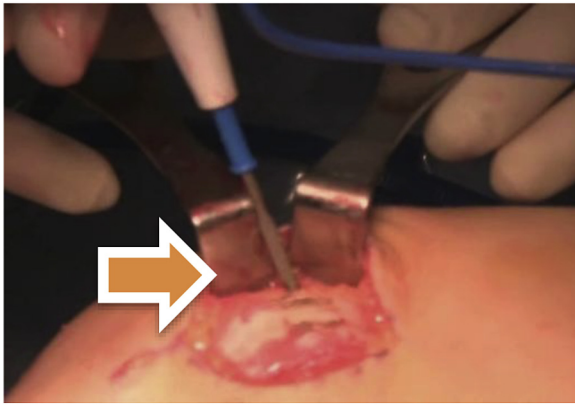


Fig 2. Patella periosteal tunnels are created.

dislocations or subluxations, and generalized ligamentous laxity. Instances of instability should be noted along with their physical activity level. Clinical examination includes analysis of patella tracking, manual tilts to identify alignment and apprehension, and patella displacement along with identifying any factors that alter the patellofemoral joint mechanics. Attention should be directed to a J sign, because it may portend high-grade trochlear dysplasia. Ligamentous laxity can be assessed with a Beighton scale. Bony injuries are ruled out by radiographs, and magnetic resonance imaging (MRI) identifies chondral and soft tissue injuries. Frequently, MPFL injury is identified with MRI. Femoral lesions are reported to be more common, whereas patellar avulsions may be more easily visualized with MRI. A bone bruise on the lateral extra-articular trochlea is pathognomonic and confirms the patellar dislocation. Patellar instability is confirmed by diagnostic knee arthroscopy.

Patient Setup

Under general anesthesia, the patient is placed in a supine position on the arthroscopy table. The nonoperative leg is positioned lower than the operative knee. The operative

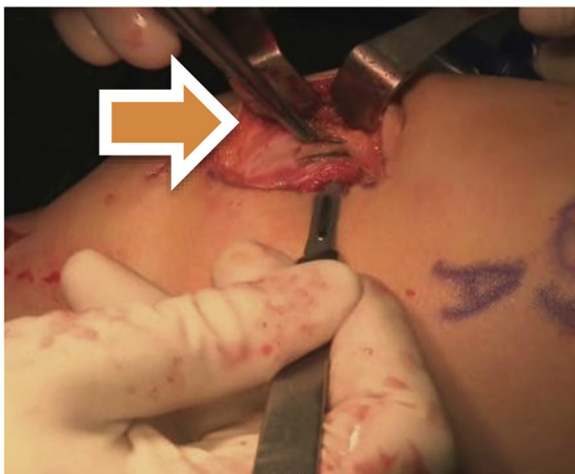

Fig 3. The tunnels are undermined with a No. 15 blade.

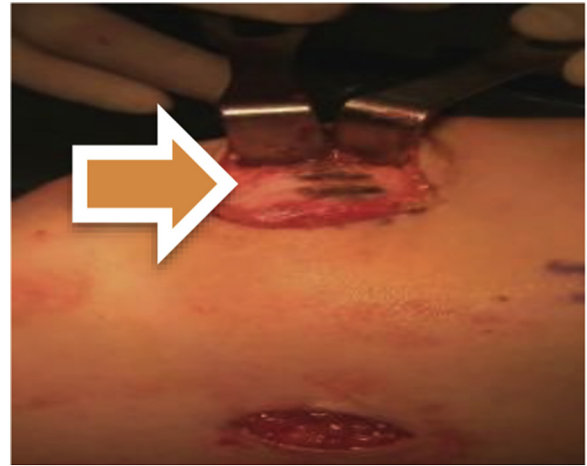

Fig 4. First completed tunnel at the junction of the proximal 1/3 and middle 1/3 of the patella.

knee is placed at 90° flexion. The intended incision points are marked over the medial femoral condyle and medial border of the patella.

Performing the MPFL Reconstruction Procedure

The operative technique is outlined in [Video 1](#). To harvest the gracilis, a 5- to 7.5-cm incision is made over the pes anserinus insertion point. Using a tendon stripper (Arthrex, Naples, FL), the gracilis is exposed and released. The gracilis is then doubled to reach a minimum length of 10 cm. The normal MPFL is approximately 4 cm long.

The femoral tunnel is created at Schottle's point that is the fluoroscopic location of the femoral origin of the MPFL. According to Schottle et al.,⁷ Schottle's point can be located 1 mm anterior to the posterior cortex extension line, 2.5 mm distal to the posterior origin of the medial femoral condyle, and proximal to the level of the posterior point of the Blumensaat line. The guide pin is marked with a clamp at the bone surface ([Fig 1](#)). Patellar periosteal fibro-osseous tunnels are created with a series of incisions in the periosteum ([Fig 2](#)). The periosteal tunnels are undermined with a No. 15 blade

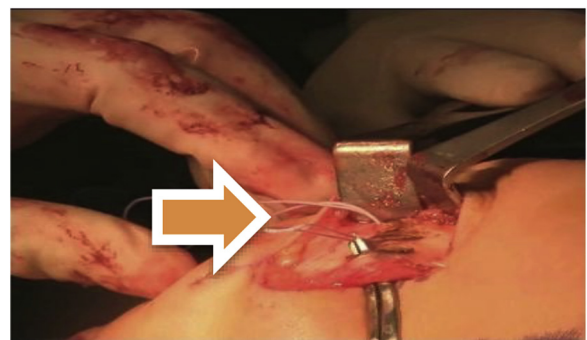


Fig 5. Suture passed "Under, Over, Under" to allow graft passage later in the procedure.

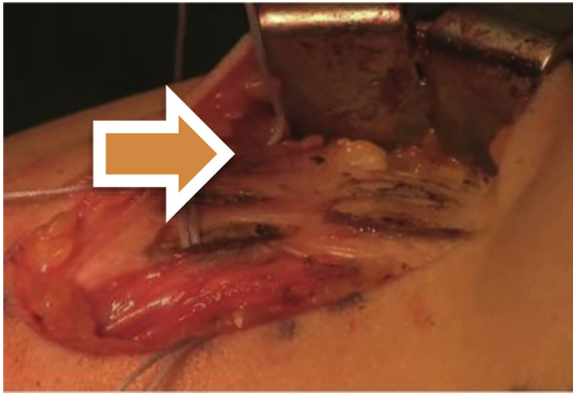


Fig 6. The second periosteal tunnel is created at the junction of the patella and quadriceps tendon.

and expanded with a clamp (Fig 3). The first periosteal tunnel fibro-osseous is created at the junction of the proximal third and middle third of the patella and can be confirmed with a metal clamp with fluoroscopy (Fig 4). The suture is passed through the periosteal fibro-osseous tunnel for graft passage (Fig 5). A second periosteal fibro-osseous tunnel is created at the junction of the patella and the quadriceps tendon (Fig 6). Each tunnel has 2 individual sleeves that the graft passes under. In between the 2 sleeves the graft passes over the periosteum (Fig 7). Manual pressure allows the patella to be reduced symmetrically in the trochlea. The shuttle sutures are passed between layer 2 and layer 1 (Fig 8).

The graft is inserted into the femoral tunnel and secured with an interference biocomposite tenodesis screw (Arthrex) (Fig 9). The 2 limbs are separated, and passed under layer 2 and through the periosteal tunnels into the individual periosteal sleeves with the 2 shuttle sutures (Fig 10). The 2 graft limbs reconstruct both the

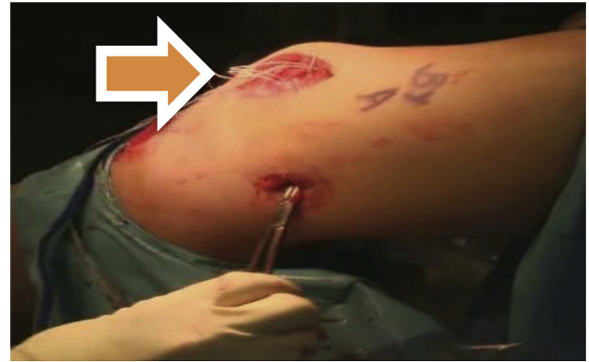

Fig 8. The sutures are passed between layer 2 and layer 1.

upper and lower margin of the MPFL. Occasionally, the sleeves need to be dilated with a clamp or No. 15 blade. Manual pressure is applied to the lateral border of the patella to reduce it in the trochlea with the knee flexed approximately 30°. Each graft limb is secured on each of the 2 periosteal sleeves with 2 No. 2 FiberWire sutures (Arthrex) in a figure-of-8 fashion for a total of 4 sutures on each graft limb (Fig 11). We use a suture on each side of the 2 sleeves for each graft limb (Fig 12). Frequently, we assess patellar position after the first suture is tied and after the first graft limb is secured to ensure good patella seating in the trochlea. The distal limb is secured first. Patella position is confirmed arthroscopically to ensure that the median ridge, lateral facet, and medial facet are appropriately aligned. The proximal graft limb is secured in a similar fashion to the distal limb. With periosteal and suture fixation, there are no drill holes in the patella, as fractures have been reported with suture anchors. Arthroscopic views through the anterolateral portal confirm that the patella seated symmetrically in the trochlea. To this point, there have been minimal complaints of the suture knots over the anterior aspect of the patella.

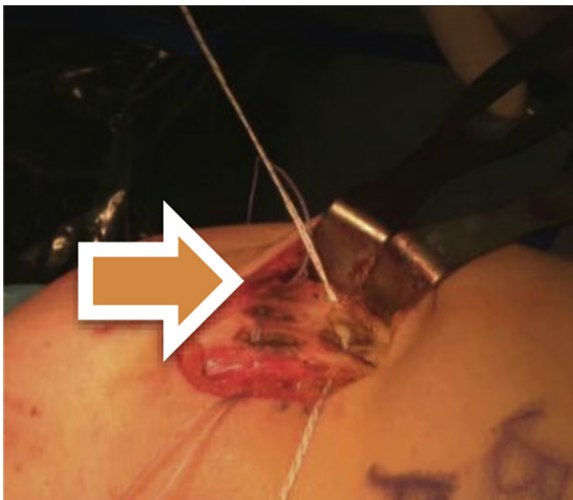

Fig 7. Suture passed "Under, Over, Under" in the second tunnel as well.

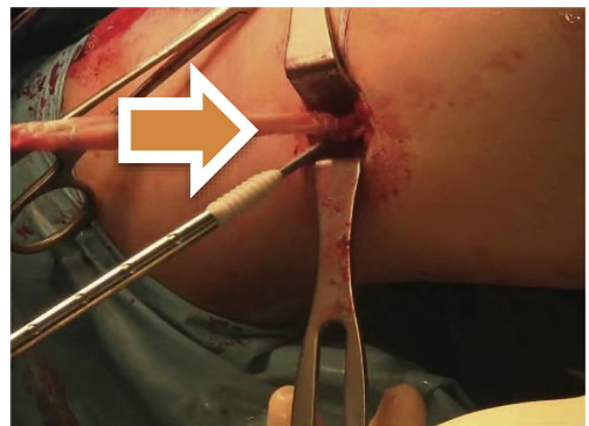


Fig 9. The graft is placed in the femoral tunnel, and secured with an interference biocomposite screw.

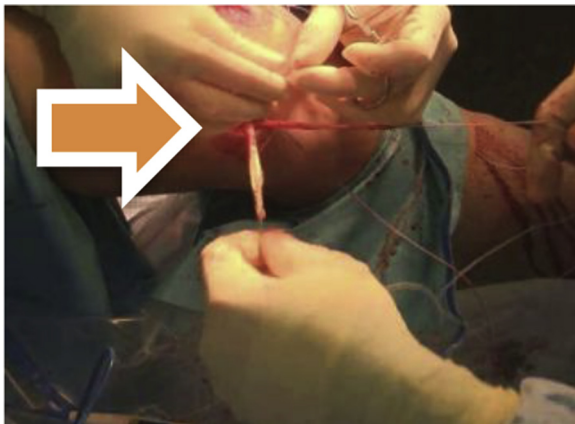


Fig 10. The 2 limbs of the graft are separated before being passed under layer 2.

Postoperative Care

The patient is placed in a long hinged rehabilitation brace locked for ambulation and sleeping during the first 4 weeks. The patient can weight bear as tolerated using crutches. Goals of the immediate postop phase (days 1-7) are to diminish swelling/inflammation, diminish post-operative pain, and initiate voluntary quadriceps control. Active knee extension is prohibited. The acute phase (weeks 2-4) goals are to control swelling and pain, promote healing, and improve quadriceps strength. The brace may be unlocked to 90° for sitting and the patient is transitioned to a patellar stabilizing brace at 4 weeks. The patient may discontinue crutches as gait is normalized. The subacute phase (weeks 5-8) is geared toward improvements of muscular strength and endurance control that is focused on the extension mechanism. The criteria to progress to the strengthening phase (weeks 9-16) are that range of motion is at least 0° to 115°, absence of swelling/inflammation, and voluntary control of quadriceps muscle group. The goal of the strengthening phase is the gradual improvement of muscular strength using functional activities/drills. The final phase is focused on the return to activity. With proper range of motion and strengthening exercises, the patient typically returns to full activity approximately 4 to 6 months after surgery.

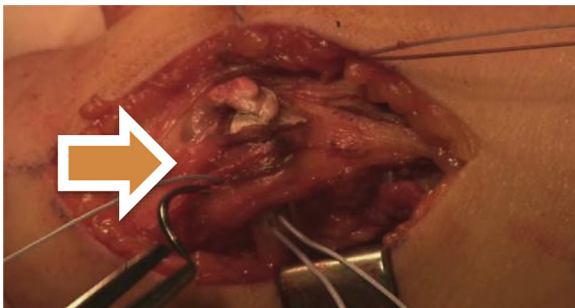


Fig 11. Each graft limb is secured on each of the 2 periosteal tunnels with 2 No. 2 sutures in a figure-of-8 fashion.

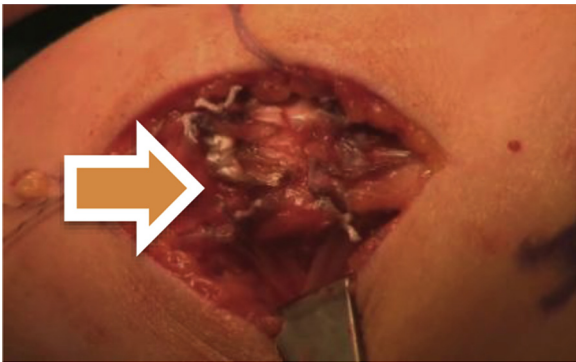


Fig 12. A total of 4 sutures on each graft limb are used.

Discussion

Acute patella dislocations are the primary reason for tears of the MPFL. Fortunately, reconstruction of the MPFL is a successful treatment option for MPFL tears.⁸ Fractures of the patella may arise from MPFL surgery. Shah et al.⁹ reported 4 patients who endured patella fractures where the surgical procedure used transpatellar tunnels. Similarly, Parikh et al.¹⁰ found 6 patellar fractures in which 5 were transverse patellar fractures that were through patellar tunnels. Drill holes made within the patella have been identified as a risk factor for patella fractures.¹¹ Techniques have been developed to avoid patella drilling to lessen the likelihood of patellar fractures.¹² But patella fracture has been reported even after suture anchor fixation, although the authors did ascribe the complication to surgical error.¹³ The gracilis tendon is stronger than the native MPFL making it a viable tendon to harvest for reconstructive surgery. Use of this tendon reduces the likelihood of stress fractures due to the drill holes being smaller in comparison with a semitendinosus graft.¹⁴ Furthermore, patella stability remains normal and knee function improves after gracilis tendon autograft.¹⁵ Deie et al.¹⁶ reported the use of periosteal fibro-osseous tunnels for securing a single gracilis tendon. We have adapted this technique of periosteal fibro-

Table 1. Advantages and Disadvantages of the Proposed MPFL Technique

Advantages	Disadvantages
No bone tunnels or suture anchors on the patella	Suture fixation is not as strong biomechanically as interference fixation
Reduced risk of patella fracture	
Applicable to a more proximal fixation point on the quadriceps tendon	
Low recurrence rate in our experience	
Sutures on the patella well tolerated	

MPFL, medial patella femoral ligament.

Table 2. Technique Pearls

Technique Pearls	
Difficulty creating fibro-osseous periosteal sleeves	Vertical incisions with a No. 15 blade Dissect the sleeve off of the dorsal aspect of the patella with a No. 15 blade
Passing graft through the sleeve is difficult	Trim the tips of the graft to make them more rounded Enlarge the fibro-osseous periosteal sleeves with a small hemostat clamp

osseous tunnels to a double-limbed gracilis graft to reconstruct the upper and lower borders as conventionally used for MPFL reconstruction. Once the graft is tensioned, it is sutured to the periosteal fibro-osseous tunnel with 2 sutures on the medial side and at least 1 suture on the lateral side of each periosteal fibro-osseous sleeve. Each of the 2 periosteal fibro-osseous tunnels has 3 to 4 sutures securing the graft. Although the biomechanics of MPFL femoral fixation are being clarified, suture anchor fixation is comparable with interference screw fixation, although not as strong as the converging tunnel technique.¹⁷ Suture fixation is comparable with suture anchor fixation as the suture is the weak link in suture anchor fixation.¹⁸ Our technique is yet to be compared with more commonly described techniques, but present evidence suggests that our technique with multiple high tensile strength sutures may be weaker than interference fixation. The native MPFL is neither strong nor stiff, and multiple high tensile suture fixation along with postoperative immobilization may be adequate strength and stiffness for the MPFL reconstruction. Our patients have had few recurrent patella dislocations and no patella fractures during the 2.5 years that we have used this technique. The sutures have been well tolerated on the dorsal patella. None have been removed. Table 1 outlines advantages and disadvantages of this technique. Table 2 outlines the technique pearls.

Some authors believe that the proximal portion of the MPFL attaches onto the quadriceps expansion onto the patella.¹⁹ This technique can be modified to weave the proximal limb through the quadriceps expansion and fix with suture as we have described. A fixation to the quadriceps tendon would reconstruct the medial quadriceps tendon-femoral ligament.²⁰

In conclusion, the described technique has avoided patella fracture as a complication and is flexible as to its fixation point on the patella.

References

1. Panagopoulos A, Van Niekerk L, Triantafillopoulos IK. MPFL reconstruction for recurrent patella dislocation: A new surgical technique and review of the literature. *Int J Sports Med* 2008;29:359-365.
2. Elias DA, White LM, Fithian DC. Acute lateral patellar dislocation at MR imaging: Injury patterns of medial patellar soft-tissue restraints and osteochondral injuries of the inferomedial patella. *Radiology* 2002;225:736-743.
3. Desio SM, Burks RT, Bachus KN. Soft tissue restraints to lateral patellar translation in the human knee. *Am J Sports Med* 1998;26:59-65.
4. Buchner M, Baudendistel B, Sabo D, Schmitt H. Acute traumatic primary patellar dislocation: Long-term results comparing conservative and surgical treatment. *Clin J Sports Med* 2005;15:62-66.
5. Hing CB, Smith TO, Donell S, Song F. Surgical versus nonsurgical interventions for treating patellar dislocation. *Cochrane Database Syst Rev* 2011;11:CD0081066.
6. Wagner D, Pfalzer F, Hingelbaum S, Huth J, Mauch F, Bauer G. The influence of risk factors on clinical outcomes following anatomical medial patellofemoral ligament (MPFL) reconstruction using the gracilis tendon. *Knee Surg Sports Traumatol Arthrosc* 2013;21:318-324.
7. Schottle PB, Schmeling A, Rosenstiel N, Weiler A. Radiographic landmarks for femoral tunnel placement in medial patellofemoral ligament reconstruction. *Am J Sports Med* 2007;35:801-804.
8. Li J, Li Y, Wei J, Wang J, Gao S, Shen Y. A simple technique for reconstruction of medial patellofemoral ligament with bone-fascia tunnel fixation at the medial margin of the patella: A 6-year-minimum follow-up study. *J Orthop Surg Res* 2014;9:66.
9. Shah JN, Howard S, Flanigan DC, Brophy RH, Carey J, Lattermann C. A systematic review of complications and failures associated with medial patellofemoral ligament reconstruction for recurrent patellar dislocation. *Am J Sports Med* 2012;40:1916-1923.
10. Parikh SN, Nathan ST, Wall EJ, Eismann EA. Complications of medial patellofemoral ligament reconstruction in young patients. *Am J Sports Med* 2013;41:1030-1038.
11. Bowers AL, Stein BES. Complications of patellar stabilization surgery. *Oper Tech Sports Med* 2010;18:123-128.
12. Schottle P, Fucentese S, Romero J. Clinical and radiological outcome of medial patellofemoral ligament reconstruction with a semitendinosus autograft for patella instability. *Knee Surg Sports Traumatol Arthrosc* 2005;13:516-521.
13. Dhinsa BS, Bhamra JS, James C, Dunnet W, Zahn H. Patella fracture after medial patellofemoral ligament reconstruction using suture anchors. *Knee* 2013;20:605-608.
14. Thaunat M, Erasmus PJ. Recurrent patellar dislocation after medial patellofemoral ligament reconstruction. *Knee Surg Sports Traumatol Arthrosc* 2008;16:40-43.
15. Enderlein D, Nielsen T, Christiansen SE, Fauno P, Lind M. Clinical outcome after reconstruction of the medial patellofemoral ligament in patients with recurrent patella instability. *Knee Surg Sports Traumatol Arthrosc* 2014;22:2458-2464.
16. Deie M, Ochi M, Sumen Y, Yasumoto M, Kobayashi K, Kimura H. Reconstruction of the medial patellofemoral ligament for the treatment of habitual or recurrent dislocation of the patella in children. *J Bone Joint* 2003;85:887-890.
17. Russo F, Doan J, Chase DC, Farnsworth CL, Pennock AT. Medial patellofemoral ligament reconstruction: Fixation technique biomechanics. *J Knee Surg* 2016;29:303-309.
18. Russ SD, Tompkins M, Nuckley D, Macalena J. Biomechanical comparison of patellar fixation techniques in

- medial patellofemoral ligament reconstruction. *Am J Sports Med* 2015;43:195-199.
19. Tanaka MJ. Variability in the patellar attachment of the medial patellofemoral ligament. *Arthroscopy* 2016;32:1667-1670.
 20. Fulkerson JP, Edgar C. Medial quadriceps tendon-femoral ligament: Surgical anatomy and reconstruction technique to prevent patella instability. *Arthrosc Tech* 2013;2:e125-e128.