



ELSEVIER

Available online at [www.sciencedirect.com](http://www.sciencedirect.com)

## Infection Prevention in Practice

journal homepage: [www.elsevier.com/locate/ijip](http://www.elsevier.com/locate/ijip)

## Case Report

# Expect the unexpected – Implications for next phase of COVID-19 response

Sarah Clifford<sup>a,\*</sup>, Muge Cevik<sup>a,b</sup>, Robyn Campbell<sup>a</sup>, Dàire O'Shea<sup>a</sup>,  
Rebecca Sutherland<sup>a</sup>

<sup>a</sup> NHS Lothian Infection Service, Regional Infectious Diseases Unit, Western General Hospital, Edinburgh, UK

<sup>b</sup> Division of Infection and Global Health Research, School of Medicine, University of St Andrews, St Andrews, UK

## ARTICLE INFO

**Article history:**

Received 24 May 2020

Accepted 11 January 2021

Available online 2 February 2021

**Key words:**

COVID-19

Coronavirus

nCoV

SARS-CoV-2

Novel coronavirus



## SUMMARY

A case report of a 66 year old male patient with COVID 19 who presented late in the clinical course and subsequently developed respiratory failure requiring intubation, after initially experiencing diarrhoea.

© 2021 The Authors. Published by Elsevier Ltd on behalf of The Healthcare Infection Society. This is an open access article under the CC BY-NC-ND license (<http://creativecommons.org/licenses/by-nc-nd/4.0/>).

## Introduction

Among those infected with Severe Acute Respiratory Syndrome Coronavirus-2 (SARS-CoV-2), 5 to 10% experience severe disease, only a small subset of these patients require intubation and mechanical ventilation [1]. In severe cases, SARS-CoV-2 elicits an excessive host immune response leading to extensive tissue damage similar to the manifestations observed with MERS and SARS [1–5]. While illness severity is predominantly associated with older age and underlying comorbidities [1,5],

in clinical practice it has proven challenging to predict an individual's disease course and the requirement for critical care support. Here we present a case whose initial manifestation was prolonged diarrhoea alone before presenting to hospital but persistent fever and new cough precipitated hospitalisation. Though appearing relatively well at first, progressive deterioration ensued with severe hypoxaemia requiring mechanical ventilation. The patient has provided written consent for the publication of this case report and the use of his radiological images.

## Case report

A 66-year-old male with a past medical history of type 2 diabetes mellitus, non-valvular atrial fibrillation and prostate

\* Corresponding author. Address: Ward 41 Regional Infectious Diseases Unit, Crewe Road South, Edinburgh EH4 2XU, UK. Telephone number: 0131 537 1000.

E-mail address: [sarah.clifford@nhslothian.scot.nhs.uk](mailto:sarah.clifford@nhslothian.scot.nhs.uk) (S. Clifford).

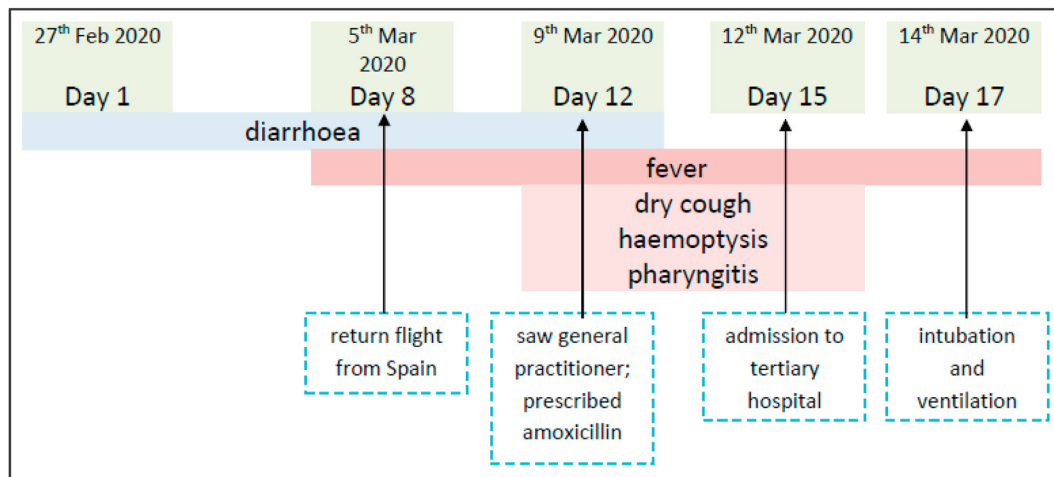


Figure 1. Disease course.

cancer (treated with brachytherapy two months prior to this admission) was admitted to a tertiary hospital with a seven-day history of fever, productive cough and haemoptysis. His regular medication included metformin, warfarin and tamsulosin. He was a current smoker and had smoked a pipe for over 20 years.

The patient had developed diarrhoea whilst on a business trip in Spain and became febrile on the day of his return flight to Scotland (Figure 1). He then presented to primary care with fever and cough three days prior to hospital admission and was prescribed oral amoxicillin for a possible lower respiratory tract infection.

On presentation to the hospital (Day 15 after the onset of diarrhoea, Figure 1), he appeared clinically well. His Clinical Frailty Score was 2 and BMI was 30. His temperature measured 37.8°C, respiration rate (RR) of 20 breaths per minute, with evidence of hypoxia (SpO<sub>2</sub> of 87% breathing room air). He was in atrial fibrillation with a blood pressure of 124/64 mmHg and ventricular rate of 120 beats per minute, confirmed on an electrocardiogram. He had fine crepitations in both lung bases. Neurological and abdominal examinations were unremarkable.

In addition to a lymphopenia of 0.59 10<sup>9</sup>/L, he also had a raised CRP of 109 mg/L (0–5). Minor interstitial opacification in both mid- and lower zones on a chest radiograph (CXR) suggested interstitial pneumonitis or fibrosis. A combined nasal and pharyngeal viral swab confirmed SARS-CoV-2 by rtPCR (real time polymerase chain reaction) with a Ct (Cycle threshold) value of 34.87. One stool sample was sent and was negative on routine culture and *C. difficile* toxin EIA (enzyme immuno-assay). Oral doxycycline was commenced.

The day following admission (day 16 post symptom onset) he developed respiratory distress with worsening tachypnoea (RR 30) and an increasing oxygen requirement. He was febrile (39.2°C) though maintained a blood pressure of 148/97mmHg. Within 36 hours of admission, despite reporting clinical improvement and comfortably mobilising in his room without breathlessness, his oxygen requirement rose from an FiO<sub>2</sub> of 0.24 to 0.6 via Venturi mask. This stepwise deterioration correlated with spikes of fever. A follow up CXR demonstrated worsening bilateral pulmonary infiltrates and consolidation compared to admission findings (Figure S1). His antibiotics were escalated from oral doxycycline to intravenous amoxicillin-clavulanic acid and he received approximately four hours of intravenous fluids at

200mls per hour, at which point he was reviewed by the intensive care team. With PaO<sub>2</sub>:FiO<sub>2</sub> of 137 mmHg he was transferred to the intensive care unit (ICU) for intubation and mechanical ventilation. During six days of ICU admission, he was administered an intravenous furosemide infusion to maintain a negative fluid balance of 500mls. He did not require any cardiac or renal support. After extubation, he required a further 8 days hospitalisation until his discharge home.

## Discussion

This case report highlights an unusual initial presentation of COVID-19 infection, which presented to hospital late (day 15 after the onset of diarrhoea) in the disease course. Whilst he presented to hospital with relatively mild symptoms, he rapidly deteriorated with progressive severe hypoxaemia requiring mechanical ventilation.

One of the prominent features observed in this case was the lack of correlation between the patient's presentation and the severity of hypoxemia. There have been reports of patients with COVID-19 having different 'types' of ARDS [12]. Patients who require ventilation have relatively preserved lung compliance but severely impaired gas exchange. They develop severe hypoxaemia without the proportional symptoms of respiratory distress. It is suggested that the apparent lack of distress, termed 'silent hypoxia', is a result of several factors including hypocapnic hypoxia, which does not tend to induce the same degree of respiratory distress [13]. This can result in patients being seemingly well up until a very severe and acute deterioration. This has implications for decisions regarding referral to intensive care within in the hospital, but can make assessments in the community very challenging.

While we continue to learn more about the disease course of COVID-19, according to the available literature, the average duration from symptom onset to clinical deterioration, is five to six days, and hospitalisation generally occurs around day seven or eight [1,5–7]. In contrast, this patient had a long course of illness prior to onset, symptoms initially dominated by diarrhoea alone followed by fever and cough. While approximately 40% of patients may have concurrent gastrointestinal manifestations related to SARS-CoV-2 [8], less than 10% of patients have diarrhoea as a presenting complaint without

respiratory symptoms or fever [8,9]. While an alternate pathogen responsible for diarrhoea cannot be fully excluded as gastrointestinal symptoms were resolving at the time of admission and only one stool sample was obtained for diagnostic purposes, there is evidence that SARS-CoV-2 can infect and replicate within the human gut enterocytes [9] and emerging evidence suggests that diarrhoea may be one of the under-recognised initial symptoms. Given that GI disturbance is not currently included in the UK government community testing criteria, there is a need to improve surveillance of symptoms to quantify the proportion of acute presentations with diarrhoea to acute care, and to include gastrointestinal disturbance in the case definition which requires a screen to be sent for COVID-19 testing.

Despite multiple risk factors that are associated with increased severity of illness such as older age, diabetes, cardiovascular disease and treated prostate cancer, this patient had a relatively mild course of illness prior to hospitalisation. Despite having 15 days of symptoms prior to hospital admission, upper respiratory tract sampling remained positive for SARS-CoV-2, and the patient deteriorated with respiratory failure at day 16 post symptom onset. This mirrors data from a systematic review of 79 studies demonstrating that patients continue to have detectable virus up to 83 days, although culturable virus was not identified beyond day 9 [10] s. Viral RNA shedding was shown to be longer in severe group and among those over the age of 60y [10,11].

Despite having a relatively high Ct value (on nasopharyngeal swab) indicating low viral load, this patient developed sudden respiratory failure within 36 hours. There is evidence suggesting discordance between rtPCR results for nasopharyngeal swabs versus sputum samples, in particular depending on when in course of the illness the sample was collected [10,14] Sputum samples were not obtained at the time of respiratory failure so it is not possible to know if there was ongoing viral replication in the lower airways. However, this could indicate, as has been previously suggested, that the lung injury and ARDS could be associated with an aberrant immune response [5,15]. This is supported by the increased levels of pro-inflammatory cytokines observed in cases with severe pneumonia, that is associated with abnormal respiratory signs, and increased ground glass opacities within the lungs [2,3].

This case emphasises the ongoing challenge posed in clinical management of patients with COVID-19. The risk of rapid disease progression in patients with underlying risk factors persists even when presenting late in the disease course with seemingly mild symptoms, especially lacking common severity indicators such as dyspnoea, respiratory distress and elevated CRP. It also highlights the importance of improving symptom surveillance to increase case detection in the UK for COVID-19 pandemic going forward.

## Authors contributions

SC, MC, RC drafted the first and subsequent versions of the manuscript, and all authors provided critical feedback and contributed to the manuscript.

## Financial support and sponsorship

None.

## Conflicts of interest

None.

## Appendix A. Supplementary data

Supplementary data to this article can be found online at <https://doi.org/10.1016/j.infpip.2021.100118>.

## References

- [1] Cevik M, Bamford CGG, Ho A. COVID-19 pandemic-a focused review for clinicians. *Clin Microbiol Infect* 2020;26:842–7.
- [2] Carsana L, Sonzogni A, Nasr A, Rossi R, Pellegrinelli A, Zerbi P, et al. Pulmonary post-mortem findings in a large series of COVID-19 cases from Northern Italy. *medRxiv* 2020. 2020.04.19.20054262.
- [3] Giamarellos-Bourboulis EJ, Netea MG, Rovina N, Akinosoglou K, Antoniadou A, Antonakos N, et al. Complex Immune Dysregulation in COVID-19 Patients with Severe Respiratory Failure. *Cell Host & Microbe* 2020;27(6):992–1000.
- [4] Wu C, Chen X, Cai Y, Xia Ja, Zhou X, Xu S, et al. Risk Factors Associated With Acute Respiratory Distress Syndrome and Death in Patients With Coronavirus Disease 2019 Pneumonia in Wuhan, China. *JAMA Internal Medicine* 2020;180(7):934–43.
- [5] Cevik M, Kuppalli K, Kindrachuk J, Peiris M. Virology, Transmission and Pathogenesis of SARS-CoV-2. *BMJ* 2020;371.
- [6] Wang D, Hu B, Hu C, Zhu F, Liu X, Zhang J, et al. Clinical Characteristics of 138 Hospitalized Patients With 2019 Novel Coronavirus-Infected Pneumonia in Wuhan, China. *JAMA* 2020;323(11):1061–9.
- [7] Zhou F, Yu T, Du R, Fan G, Liu Y, Liu Z, et al. Clinical course and risk factors for mortality of adult inpatients with COVID-19 in Wuhan, China: a retrospective cohort study. *Lancet* 2020;395(10229):1054–62.
- [8] Cholankeril G, Podboy A, Aivaliotis VI, Tarlow B, Pham EA, Spencer S, et al. High Prevalence of Concurrent Gastrointestinal Manifestations in Patients with SARS-CoV-2: Early Experience from California. *Gastroenterology* 2020;159(2):775–7.
- [9] Lamers MM, Beumer J, van der Vaart J, Knoop K, Puschhof J, Breugem TI, et al. SARS-CoV-2 productively infects human gut enterocytes. *Science* 2020;369(6499):50.
- [10] Cevik M, Tate M, Lloyd O, Maraolo AE, Schafers J, Ho A. SARS-CoV-2, SARS-CoV-1 and MERS-CoV viral load dynamics, duration of viral shedding and infectiousness: a living systematic review and meta-analysis. *medRxiv* 2020. 2020.07.25.20162107.
- [11] Zheng S, Fan J, Yu F, Feng B, Lou B, Zou Q, et al. Viral load dynamics and disease severity in patients infected with SARS-CoV-2 in Zhejiang province, China, January-March 2020: retrospective cohort study. *BMJ* 2020;369:m1443.
- [12] Marini JJ, Gattinoni L. Management of COVID-19 Respiratory Distress. *JAMA* 2020;323(22):2329–30.
- [13] Ottestad W, Søvik S. COVID-19 patients with respiratory failure: what can we learn from aviation medicine? *British Journal of Anaesthesia* 2020;125(3):e280–1.
- [14] Wolfel R, Corman VM, Guggemos W, Seilmaier M, Zange S, Muller MA, et al. Virological assessment of hospitalized patients with COVID-2019. *Nature* 2020;581(7809):465–9.
- [15] Blanco-Melo D, Nilsson-Payant BE, Liu W-C, Uhl S, Hoagland D, Møller R, et al. Imbalanced Host Response to SARS-CoV-2 Drives Development of COVID-19. *Cell* 2020;181(5):1036–45. e9.