

## Occurrence of multiple myeloma in the head and neck: a report of two cases

Ki-Uk Nam, Jaemyung Ahn, Jongrak Hong

*Department of Oral and Maxillofacial Surgery, Samsung Medical Center,  
Sungkyunkwan University School of Medicine, Seoul, Korea*

**Abstract** (J Korean Assoc Oral Maxillofac Surg 2013;39:139-143)

Multiple myeloma (MM) is a disease reported to account for 1% of all cancers and 10% of hematological malignant diseases. Unlike other malignant diseases that are transferred to the osseous tissues, MM does not show new bone formation, is associated with characteristic osteolytic lesions, and shows monoclonal protein (M-protein) on the immunohematological test, which is an important index in its diagnosis. Solitary lesions of MM are rare in the head and neck area, and, in most cases, MM of the head and neck area is related to systemic symptoms.

**Key words:** Multiple myeloma, Plasmacytoma, Plasma cell

[paper submitted 2013. 5. 9 / revised 2013. 6. 14 / accepted 2013. 6. 14]

### I. Introduction

Multiple myeloma (MM) mainly affects men, with those aged 65 years on the average affected. As for its systemic symptoms, anemia, hypercalcemia, renal failure, increased risk of infection, are the main clinical characteristics; for clinical symptoms at the head and neck area, pain on the affected bones, paresthesia, edema, tooth mobility, pathologic fracture of bones, etc., are observed.

We have experienced two cases of MM, which are not frequently observed at the head and neck area, and we report what we have investigated and analyzed in two MM patients who visited the Department of Oral and Maxillofacial Surgery at Samsung Medical Center (Seoul, Korea) to find out the diagnostic and therapeutic methodologies for MM.

### II. Cases Report

#### 1. Case 1

A 44-year-old female patient who had been diagnosed with MM at the bilateral humerus bones, bilateral pelvic bones, and bilateral femur bones as observed while receiving chemotherapy using vincristine doxorubicin, dexamethasone, hematopoietic stem cell transplantation (HSCT), etc., was referred to our department after masses were observed over the buccal gingiva on the left side of the maxillary anterior in May 2008.(Fig. 1. A) No specific features were observed from the panoramic view, but osteolytic features were noted at the relevant site based on a computed tomography (CT) scan in May 2008.(Fig. 1. B) M-protein was 1.07 g/dL, and there was an increase in the immunoglobulin G (IgG) count from the serum electrophoresis (2,235 mg/dL, normal range=700-1,600 mg/dL). There were no specific results from other hematological and physico-chemical tests. Reddish swellings were observed from the intraoral environment of the patient, and there were edemas - including teeth #22 and #23 - with smooth surfaces. Thus, based on the fact that the patient had been observed by the Department of Hematology and Oncology due to MM and an increase of M-protein, our department temporarily diagnosed the patient with an expression of MM at the head and neck area and carried out

---

#### **Jongrak Hong**

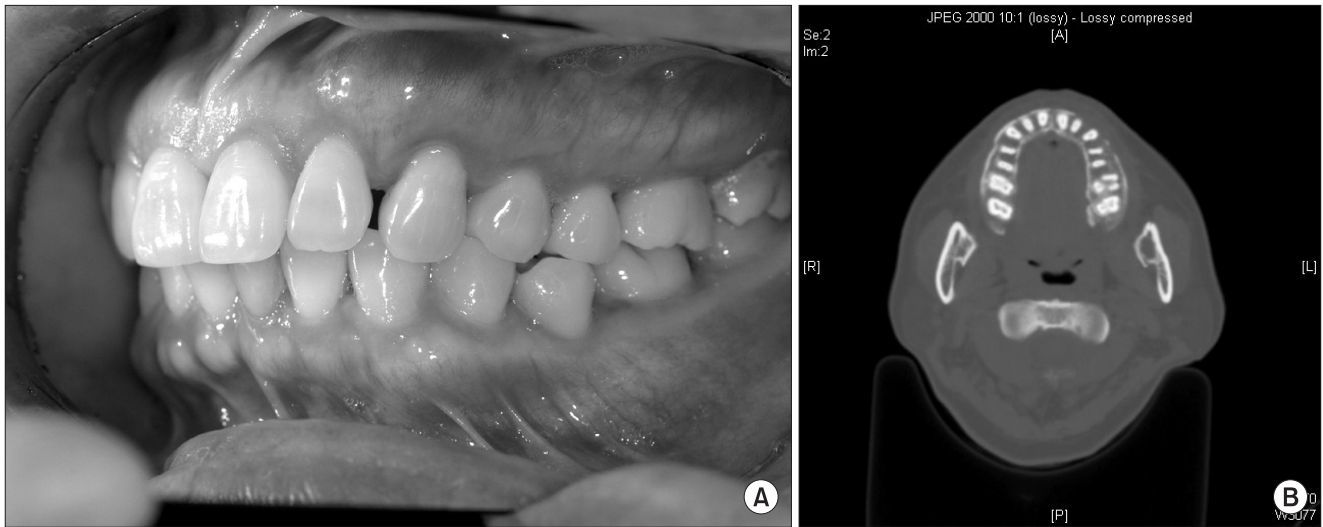*Department of Oral and Maxillofacial Surgery, Samsung Medical Center, Sungkyunkwan University School of Medicine, 50 Irwon-ro, Gangnam-gu, Seoul 135-710, Korea*

TEL: +82-2-3410-2420 FAX: +82-2-3410-0038

E-mail: hongjr@skku.edu

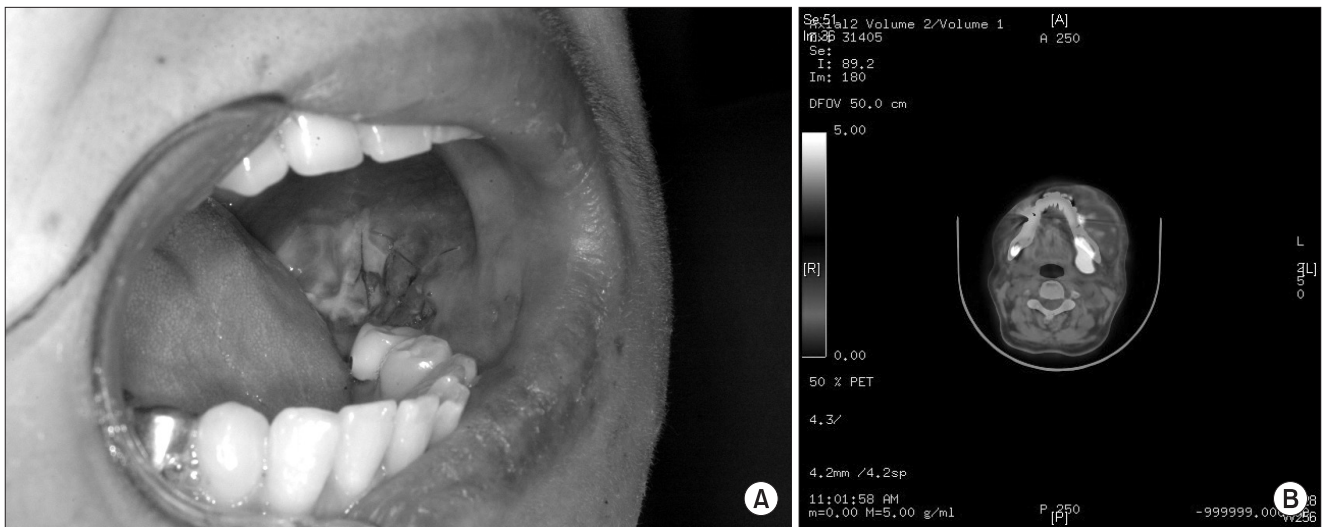© This is an open-access article distributed under the terms of the Creative Commons Attribution Non-Commercial License (<http://creativecommons.org/licenses/by-nc/3.0/>), which permits unrestricted non-commercial use, distribution, and reproduction in any medium, provided the original work is properly cited.

Copyright © 2013 The Korean Association of Oral and Maxillofacial Surgeons. All rights reserved.



**Fig. 1.** Figures of Case 1. A. Intraoral clinical photo. Reddish swelling was seen with the #22 and 23 teeth. B. Computed tomography image. The left maxilla cortical bone disappeared.

Ki-Uk Nam et al: Occurrence of multiple myeloma in the head and neck: a report of two cases. J Korean Assoc Oral Maxillofac Surg 2013



**Fig. 2.** Figures of Case 2. A. Pre-radiotherapy intraoral clinical photo. B. Pre-radiotherapy positron emission tomography image. Note the hot spots on the left side.

Ki-Uk Nam et al: Occurrence of multiple myeloma in the head and neck: a report of two cases. J Korean Assoc Oral Maxillofac Surg 2013

a biopsy of the relevant lesions under local anesthesia. The sample was sent to the Department of Pathology at Samsung Medical Center, and the tissue was reported to have aspects of monotonous plasmacytoid cell infiltration. Consequently, our department confirmed the expression of MM at the head and neck area. Though the aspects of osteolysis were observed to increase based on a follow-up CT scan in July 2008, healing of the gingival wounds at the sites of biopsy were shown, but the M-protein level was 1.6 g/dL, whereas the IgG level was 2,176 mg/dL. The Department of Hematology and Oncology then performed chemotherapy using thalidomide,

dexamethasone, velcade, etc. Note, however, that pancytopenia occurred in January 2009, and other malignant aspects had been observed, including plasma cell rate of more than 35% based on the hematological test performed in April 2009. The patient expired in July 2009.

## 2. Case 2

A 61-year-old female patient who had been diagnosed with MM at the skull and rib areas by the Department of Hematology and Oncology in May 2009 received HSCT in

January 2010. She was observed to be in a systemically stable state. In December 2010, she complained of edemas and pain in the left mandibular buccal gingiva and the buccal mucosa; thus, she was referred to our department. She had a history of extraction of the left lower first molar tooth due to pain and tooth mobility at the relevant sites 2 months before her visit to the Department of Oral and Maxillofacial Surgery. An edema in the left facial area was found during the first examination, and clinical symptoms such as spontaneous hemorrhage of blue-reddish color tones were observed.(Fig. 2. A) No specific features were noted in the panoramic view. There were no abnormal results except decrease of hemoglobin and hematocrit from the complete blood cell count test.(Table 1) Monoclonal gammopathy was observed with 5.29 g/dL when the M-protein level increased since June 2010, with the IgA level increasing considerably in the serum immunoglobulin counts (2,314 mg/dL, normal range=70-400 mg/dL). There were no osteolytic lesions in the mandible from the CT

**Table 1.** Results of complete blood cell count and chemistry of case 1 and 2

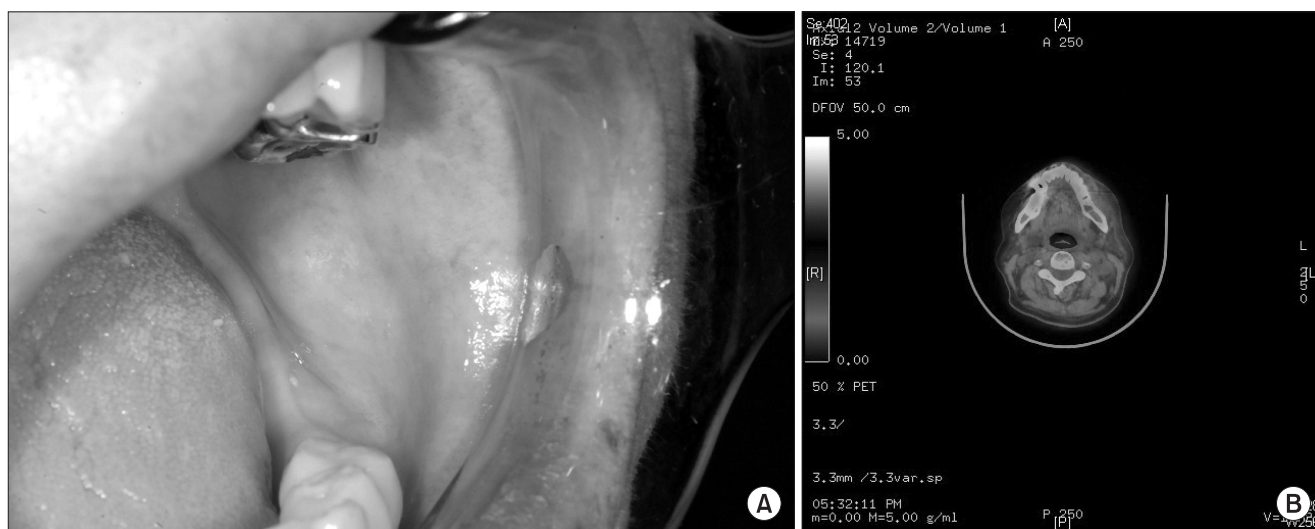
	Normal range	Case 1	Case 2
Hemoglobin (g/dL)	12-16	12.2	7.9
Hematocrit (%)	35-45	35.6	25.8
Platelet (/mm <sup>3</sup> )	150,000-450,000	125,000	164,000
Albumin (g/dL)	3.5-5.2	4.3	3.2
Globulin (g/dL)	2.0-3.5	3.3	6.6
Ca (g/dL)	8.4-10.2	8.9	9.2
Creatinine (g/dL)	0.7-1.3	0.6	0.8

Ki-Uk Nam et al: Occurrence of multiple myeloma in the head and neck: a report of two cases. *J Korean Assoc Oral Maxillofac Surg* 2013

scan. Since the patient had a history of existing MM, the test results seemed to be related to hematological diseases, and no changes in bones were observed from the CT scan; our department judged the existing MM to have been manifested into the oral soft tissue area and temporarily diagnosed the patient in detail with extramedullary plasmacytoma. Strong standardized uptake value (SUV) uptake (SUVmax=4.3) was found at the relevant site from a positron emission tomography-CT (PET-CT).(Fig. 2. B)

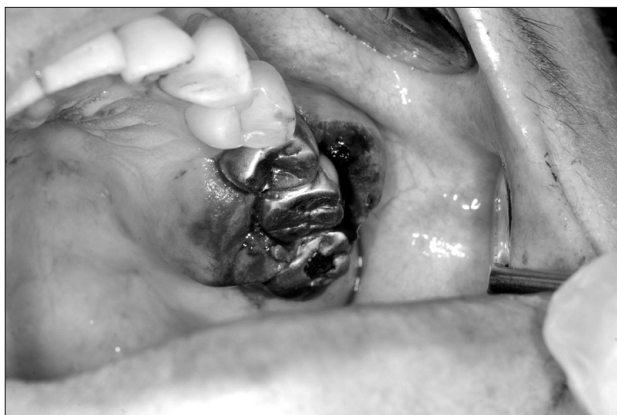Thus, our department carried out a biopsy, and tissue specimens were sent to the Department of Pathology at Samsung Medical Center. After the results of the biopsy determined the disease to be plasmacytoma, chemotherapy using lenalidomide, dexamethasone, and radiotherapy (25 Gy) were performed. Healing of the oral lesions was observed later(Fig. 3. A); some aspects of improvement, including decrease of IgA level, were found from the blood test carried out in March 2011 (740 mg/dL); the M-protein level also shifted to a constant decrease (1.9 g/ dL in March 2011), and there was no uptake observed from a follow-up PET-CT scan.(Fig. 3. B)

During the follow-up in August 2011, pain and edemas at the buccal gingiva of the left maxillary posterior teeth and palatal gingiva and pain, edemas, and spontaneous hemorrhage at the left mandibular lingual and buccal sites were found.(Fig. 4) Such was considered a recurrence of the existing lesions. In addition, osteolytic lesion with diameter of up to 1 cm and sclerotic rim was found in plain film and CT scans. Consequently, biopsy and radiotherapy were



**Fig. 3.** Figures of Case 2. A. Post-radiotherapy intraoral clinical photo. Healing mucosa was noted. B. Post-radiotherapy positron emission tomography scan. Hot spots disappeared.

Ki-Uk Nam et al: Occurrence of multiple myeloma in the head and neck: a report of two cases. *J Korean Assoc Oral Maxillofac Surg* 2013



**Fig. 4.** Figure of Case 2. Recurring multiple myeloma.  
*Ki-Uk Nam et al: Occurrence of multiple myeloma in the head and neck: a report of two cases. J Korean Assoc Oral Maxillofac Surg 2013*

performed again, with the patient hospitalized after consulting the Department of Hematology and Oncology for observation with chemotherapy (dexamethasone, thalidomide, cyclophosphamide, doxorubicin, cisplatin, and etoposide). Note, however, that cytopenia, azotemia, and pleural effusion of the lungs were observed due to development of the lesions; the patient was discharged in September 2011 due to the aggravation of general condition owing to the lesions.

### III. Discussion

As a disease showing plasma cell hyperplasia, MM can be classified into three stages based on the strengths of the activation of lesions. The first stage is monoclonal gammopathy of undetermined significance wherein M-protein is detected but no increase of plasma cells is observed in marrows and no clinical symptoms exist in relation to MM<sup>1</sup>. In the second stage, which is a more developed stage, smoldering multiple myeloma with increased M-protein and plasma cells is observed in the marrows, but no clinical symptoms exist. The third stage is classified as symptomatic multiple myeloma wherein the contractions are clinically identified and the spread of lesions is found over numerous organs<sup>2</sup>.(Table 2) Likewise, depending on the onset sites, MM can be divided into extramedullary plasmacytoma as a single lesion limited to soft tissues, solitary bone plasmacytoma occurring as a single lesion at the bone tissue, and the kind of MM occurring systemically over numerous organs. In general, solitary bone plasmacytoma occurring in a single bone is highly likely to develop into MM. Furthermore, Canger et al.<sup>3</sup> reported in 2007 that such shifts occurred over several months to several years. In contrast, in the case of the plasmacytoma occurring in soft

**Table 2.** Criteria for the diagnosis of multiple myeloma

<p>Symptomatic multiple myeloma (all are required)</p> <ol style="list-style-type: none"> <li>1) Clonal plasma cells present in the biopsy of bone marrow or plasmacytoma</li> <li>2) M-protein present in serum or urine</li> <li>3) Evidence of related organ or tissue impairment</li> </ol> <p>Asymptomatic (smoldering) myeloma</p> <ol style="list-style-type: none"> <li>1) Serum M-protein <math>\geq 3</math> g/dL and/or clonal plasma cells <math>\geq 10\%</math> of bone marrow</li> <li>2) No symptoms or evidence of related organ or tissue impairment</li> </ol> <p>Monoclonal gammopathy of undetermined significance</p> <ol style="list-style-type: none"> <li>1) Serum M-protein present, but <math>&lt;3</math> g/dL</li> <li>2) Bone marrow plasma cells <math>&lt;10\%</math> of aspirate and low level of infiltration on biopsy</li> <li>3) No symptoms or evidence of related organ or tissue impairment</li> </ol>
--

*Ki-Uk Nam et al: Occurrence of multiple myeloma in the head and neck: a report of two cases. J Korean Assoc Oral Maxillofac Surg 2013*

tissues, control of disease is reported to be possible with local excision and appropriate amount of irradiation. With respect to this, Tournier-Rangard et al.<sup>4</sup> reported that the amount of irradiation necessary for treatment was 45 Gy.

MM is a disease showing features of hyperplasia of plasma cells along with osteolytic lesions, anemia, hypercalcemia, renal failure, etc. The most affected sites include the vertebrae, skull, pelvic bone, ribs, humerus, and femur<sup>5</sup>. In the head and neck area, it occurs at the maxilla and mandible rather than skull sites but more frequently at the mandible than at the maxilla. In the mandible, it occurs more frequently at the posterior teeth including the body, angle, ascending ramus, etc<sup>6</sup>. In general, chemotherapy and HSCT are performed as treatment of MM<sup>2</sup>. Recently, however, prognosis has improved remarkably with the use of thalidomide, bortezomib, and lenalidomide. The reported mean residual life is 5 years or longer<sup>5</sup>; it is not the case in our hospital, and studies report that discussion is open with respect to the prognosis. It is difficult for an oral and maxillofacial surgeon to make a diagnosis from the first examination because many internal medicine approaches are necessary for the diagnosis of MM. There have only been a few cases wherein it occurs in the head and neck area, and we have rare cases of the first onset of this disease at the head and neck area<sup>7</sup>. This makes it difficult for oral surgeons to make a diagnosis. Table 2 shows the points that serve as references for the diagnosis of MM<sup>8</sup>. Though M-protein in serum is a clear criterion for the diagnosis, attention should be paid since M-protein is not detected in about 2% of all cases<sup>9</sup>.

The current two cases tended to be easy to diagnose because the oral symptom was expressed in patients with MM as the existing systemic disease; thus, the patients had existing internal medicine history. Note, however, that it is difficult for

an oral surgeon to confirm its diagnosis if the first symptom of MM occurs in the head and neck area. In the first case, a rare case was presented wherein the disease occurred at the maxilla anterior area. After the excision of the lesions, decrease of edemas and tooth mobility was observed since the lesions had been controlled with chemotherapy. Note, however, that progressive development of osteolysis at the mandible was seen from a follow-up CT scan.

In the second case, the existing MM had developed outside the bone marrow cavity. In such case, it shows more aggressive nature<sup>10</sup>. This case was also one wherein the lesions rapidly worsened one year after expression outside the bone marrow cavity. In the case of extra-marrow plasmacytoma, the first treatment is not surgery but radiotherapy, and the recommended dose in such case is 40-50 Gy<sup>11</sup>. A healing aspect was observed in this patient after 25 Gy irradiation to the relevant sites.

Usually, bone marrow biopsy is needed to evaluate the percentage of bone marrow occupied by plasma cells, and this percentage is used in the diagnostic criteria for myeloma. Immunohistochemistry can detect plasma cells that express immunoglobulin in the cytoplasm and occasionally on the cell surface; myeloma cells are typically CD56, CD38, and CD138 positive as well as CD19 and CD45 negative<sup>8</sup>. In two cases, the histopathologic samples showed fragments of soft tissue with marked plasma cell infiltrate. In an immunohistochemical staining study, the cells showed lambda light chain positive in the plasma cells. This phenotype showed a monoclonal population, indicative of a diagnosis of plasma cell tumor.

Surgery is not recommended when MM is found at the head and neck area since it is a systemic disease. It seems reasonable to treat patients systemically in terms of existing therapy after consulting the department of internal medicine. In the second case, we found the symptoms to have been mitigated by irradiation.

Though it rarely occurs in the head and neck area, MM is a disease that should be suspected for old patients who show a lot of osteoporotic lesions in the cortical bones and hematological abnormalities. In cases wherein MM

is suspected clinically, M-protein tests including serum electrophoresis, serum immunofixation, and serum free light chain should be performed. Though plain X-ray scan can be helpful in its diagnosis, PET-CT and magnetic resonance imaging scans enable more precise diagnosis. At the same time, clinical systemic symptoms (osteoclastic lesions, anemia, and renal failure) are observed. Thus, one should make a plan for systemic examination and treatment as well as treatment for the head and neck areas.

## References

1. Landgren O, Weiss BM. Patterns of monoclonal gammopathy of undetermined significance and multiple myeloma in various ethnic/racial groups: support for genetic factors in pathogenesis. *Leukemia* 2009;23:1691-7.
2. Stoopler ET, Vogl DT, Stadtmauer EA. Medical management update: multiple myeloma. *Oral Surg Oral Med Oral Pathol Oral Radiol Endod* 2007;103:599-609.
3. Canger EM, Celenk P, Alkan A, Günhan O. Mandibular involvement of solitary plasmacytoma: a case report. *Med Oral Patol Oral Cir Bucal* 2007;12:E7-9.
4. Tournier-Rangear L, Lapeyre M, Graff-Caillaud P, Nege A, Dolivet G, Toussaint B, et al. Radiotherapy for solitary extramedullary plasmacytoma in the head-and-neck region: A dose greater than 45 Gy to the target volume improves the local control. *Int J Radiat Oncol Biol Phys* 2006;64:1013-7.
5. Rajkumar SV. Treatment of multiple myeloma. *Nat Rev Clin Oncol* 2011;8:479-91.
6. Bruce KW, Royer RQ. Multiple myeloma occurring in the jaws; a study of 17 cases. *Oral Surg Oral Med Oral Pathol* 1953;6:729-44.
7. Baykul T, Aydin U, O Carroll MK. Unusual combination of presenting features in multiple myeloma. *Dentomaxillofac Radiol* 2004;33:413-9.
8. International Myeloma Working Group. Criteria for the classification of monoclonal gammopathies, multiple myeloma and related disorders: a report of the International Myeloma Working Group. *Br J Haematol* 2003;121:749-57.
9. Cesana C, Klersy C, Barbarano L, Nosari AM, Crugnola M, Pungolino E, et al. Prognostic factors for malignant transformation in monoclonal gammopathy of undetermined significance and smoldering multiple myeloma. *J Clin Oncol* 2002;20:1625-34.
10. Bergsagel PL, Kuehl WM. Molecular pathogenesis and a consequent classification of multiple myeloma. *J Clin Oncol* 2005; 23:6333-8.
11. Creach KM, Foote RL, Neben-Wittich MA, Kyle RA. Radiotherapy for extramedullary plasmacytoma of the head and neck. *Int J Radiat Oncol Biol Phys* 2009;73:789-94.