

## Case Report

# Hybrid Stabilization of Thoracic Spine Fractures with Sublaminar Bands and Transpedicular Screws: Description of a Surgical Alternative and Review of the Literature

**Marie-Therese Unterweger, Frank Kandziora, and Klaus J. Schnake**

*Center of Spinal Therapy, Schön Klinik Nürnberg Fürth, 90763 Fürth, Germany*

Correspondence should be addressed to Marie-Therese Unterweger; [m-th.unterweger@gmx.de](mailto:m-th.unterweger@gmx.de)

Received 21 July 2015; Accepted 7 October 2015

Academic Editor: Sigita Burneikiene

Copyright © 2015 Marie-Therese Unterweger et al. This is an open access article distributed under the Creative Commons Attribution License, which permits unrestricted use, distribution, and reproduction in any medium, provided the original work is properly cited.

Stabilization of unstable thoracic fractures with transpedicular screws is widely accepted. However, placement of transpedicular screws can cause complications, particularly in the thoracic spine with physiologically small pedicles. Hybrid stabilization, a combination of sublaminar bands and pedicle screws, might reduce the rate of misplaced screws and can be helpful in special anatomic circumstances, such as preexisting scoliosis and osteoporosis. We report about two patients suffering from unstable thoracic fractures, of T5 in one case and T3, T4, and T5 in the other case, with preexisting scoliosis and extremely small pedicles. Additionally, one patient had osteoporosis. Patients received hybrid stabilization with pedicle screws adjacent to the fractured vertebral bodies and sublaminar bands at the level above and below the pedicle screws. No complications occurred. Follow-up was 12 months with clinically uneventful postoperative courses. No signs of implant failure or loss of reduction could be detected. In patients with very small thoracic pedicles, scoliosis, and/or osteoporosis, hybrid stabilization with sublaminar bands and pedicle screws can be a viable alternative to long pedicle screw constructs.

## 1. Introduction

Indications for surgical interventions in thoracic fractures are neurological symptoms: feared neurological aggravation, unstable fractures, or unbearable pain with ongoing immobilization, respectively [1, 2].

Fractures of thoracic vertebrae are usually stabilized by an internal fixateur with transpedicular screws and rods. To achieve adequate biomechanical stability, long posterior constructs are recommended [2, 3]. Our treatment protocol includes stabilization of two vertebrae above the fractured one and two below with eight screws in total [1]. The screws are linked by two vertical rods and, if necessary, one cross link.

The anatomic specifics of the thoracic vertebrae often lead to problems in placing the pedicle screws. The pedicles are smaller [4] and formed differently [2]. Misplaced screws can lead to severe complications [5, 6].

The Universal Clamp System (Zimmer, Warsaw, USA) was developed as an advancement of the Luque Wiring [7]

where sublaminar wires were placed around the lamina. The sharp wires could easily cause injuries of the spinal cord resulting in neurological deficiencies [8–10]. The Universal Clamp (UC) System is based on the same idea but uses flexible bands made from polyethylene. After the positioning of the band, it is fixed in a clamp which is fastened to the vertical rod. The system is typically used in deformity surgery and has been occasionally used in fractures [11, 12].

In comparison to multisegmental transpedicular stabilization, a so-called “hybrid stabilization” with sublaminar clamps and only four transpedicular monoaxial pedicle screws has the advantage that less screws have to be placed in the thoracic spine. With the hybrid stabilization the two vertebrae adjacent to the fractured one, the one above and the one below, are treated with pedicle screws and the two vertebrae next to them, again one cranial and one caudal, are fixed by sublaminar clamps.

We report for the first time two cases of thoracic fractures treated with the above described hybrid stabilization.

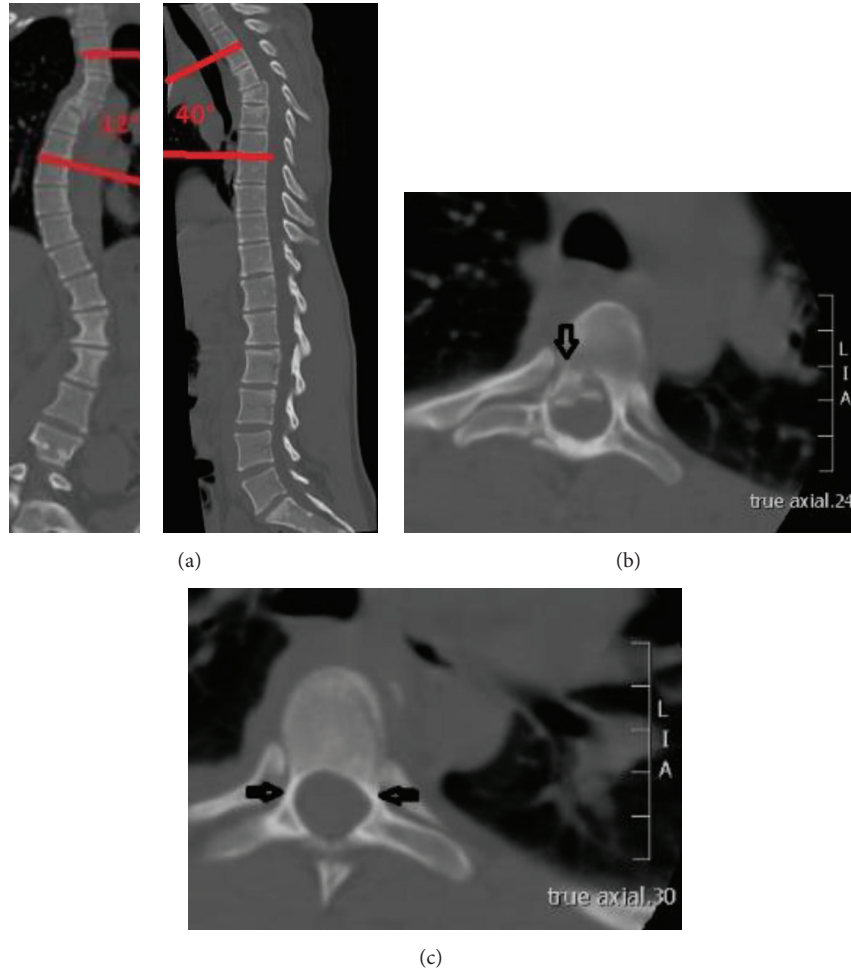


FIGURE 1: (a) CT scans showing the preexisting scoliosis and the fracture of T5. Cobb angle (T3–7): 12°, kyphosis angle (T3–7): 40°. (b) CT scan showing the fragment narrowing the spinal canal. (c) CT scan showing the small pedicles (blind on the right side, 2.5 mm on the left).

## 2. Patients and Methods

**2.1. Surgical Technique.** The sublaminar bands were used in combination with monoaxial (Medtronic, Minneapolis, USA) or polyaxial (Stryker, Kalamazoo, USA) pedicle screws of 5.5 mm diameter.

The vertebrae next to the fractured one were supplied with monoaxial or polyaxial transpedicular screws whereas the vertebrae next to these were fixed with sublaminar clamps.

First, the four necessary pedicle screws are set in a standard open technique under image intensifier control.

Then the vertebrae are prepared to pass the sublaminar bands. Therefore, the ligamentum flavum was partially removed. An arcuated dissector can help in checking the free space between the lamina and the dura. If the space is adequate, the sublaminar bands can be passed. First, the stiff part of the band is run in the clamp and then moved under the lamina from caudal to cranial. The band should always stay in contact to the lamina so the dura is not endangered. The surgeon has to verify that the band is flat against the lamina and that it is not twisted. Then the band is preassembled with

the clamp and is pushed into the rod. The rods have to be prepared and should be long enough so they can hold the clamps and the screws. Anatomical bending of the rods has to be done before fixing them to the implants. After preparing the rods, the clamps can be connected to them. The rods should now connect the screws and all the clamps. The pedicle screws are fixed to the rods before fixing the sublaminar bands. With this maneuver the first step of reduction of the fracture can be ensured. The final reduction is achieved by using the reposition tool. The bands are strained until the clamps are properly fixed to the laminae. When all implants are set in the desired position, the clamp screws of the UC System are fixed and the bands are shortened.

## 3. Case Reports

**3.1. Case 1.** An 18-year-old woman fell from a horse and sustained an unstable rotation-flexion-burst fracture of the 5th thoracic vertebra (C 2.2 according to AO-Magerl classification [13]; Figure 1(a)) with narrowing of the spinal canal (Figure 1(b)). The patient had a preexisting idiopathic adolescent scoliosis.

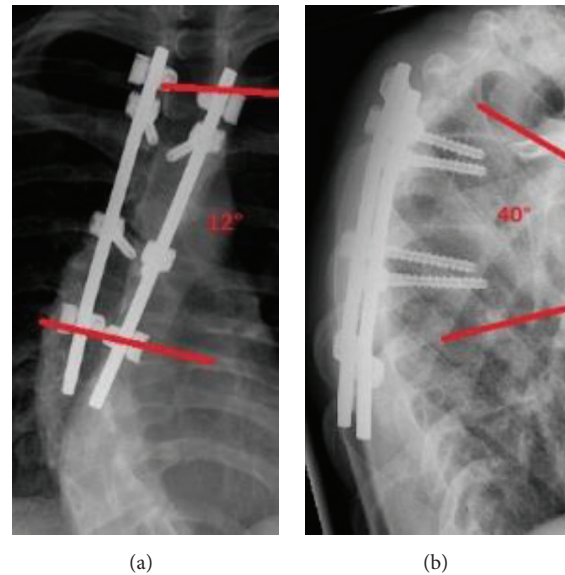


FIGURE 2: (a) Postoperative result in ap view with pedicle screws in T4 and T6 and UC System in T3 and T7 (12 months). Cobb angle (T3–7): 12°. (b) Postoperative result in lateral view (12 months). Kyphosis angle (T3–7): 40°.

She did not suffer from any neurological deficit.

Because of the instability and severe pain we decided to treat the patient surgically. We stabilized the thoracic spine from 3rd to 7th thoracic vertebra from posterior with pedicle screws and the sublaminar bands in the above described hybrid technique.

Since the patient had very small thoracic pedicles (Figure 1(c); 2.5 mm on the left side of the vertebra above the fractured one; on the right side the pedicles were blind, 1.6 mm in the vertebra below the fractured one), the only way to put the pedicle screws was parapedicular. The sublaminar bands were placed at the 3rd and 7th thoracic vertebra. Two rods were placed and fixed at the screws and the sublaminar clamps. A posterior fusion was added by using local bone graft together with demineralized bone matrix (DBM Pasty, Synthes, West Chester, USA) and tricalcium phosphate (chronOS, Synthes, West Chester, USA). No intraoperative complication occurred. The blood loss was 500 mL and the total operating time was 180 minutes.

The postoperative course was uneventful. The patient could be mobilized without orthosis. She could be discharged on the 10th postoperative day.

At final follow-up after 12 months (Figures 2(a) and 2(b)) patients did not suffer from any back pain.

**3.2. Case 2.** A 75-year-old woman fell in a bus and sustained a multisegmental injury with fractures of the 3rd, 4th, and 5th thoracic vertebra (Figures 3(a) and 3(b)). According to AO-Magerl classification [13], the fractures were classified as A3.1, B2.3, and A3.1, respectively. She also had an existing cervical-thoracic right-convex scoliosis and an osteoporosis.

The patient did not have any neurological deficit. The injury was treated surgically because of the instability and the deformation. Reduction and stabilization were performed from the 1st to the 7th thoracic vertebra. The surgery was

carried out one day after the accident. The 1st and 7th thoracic vertebrae were supplied by sublaminar bands whereas the 2nd and 6th thoracic vertebrae were supplied by polyaxial pedicle screws. A posterior fusion from T1 to T7 was initiated by demineralized bone matrix (DBM Pasty) and tricalcium phosphate (chronOS). No complication occurred. The blood loss was 550 mL and the total operation time was 280 minutes.

The postoperative course did not show any complicating events. The patient was mobilized without orthosis. She could be discharged to a geriatric rehabilitation clinic on the 12th postoperative day. When leaving the clinic she could walk with a walking frame by herself.

At final follow-up at 12 months (Figures 4(a) and 4(b)) patient was ambulatory and complained about moderate back pain (VAS 4).

#### 4. Discussion

The two cases illustrate the feasibility of the hybrid technique in thoracic fractures with difficult anatomical conditions. To the best of our knowledge, the used hybrid technique has not been published yet.

Gazzeri et al. [11] conducted a study with a different hybrid construct and stabilized thoracolumbar vertebrae with pedicle screws and UC System. Some patients suffered from a vertebral fracture, and the surgeons implanted screws in two to three segments underneath the fracture and sublaminar bands above the fractured vertebra. Our construct differs in the formation of the sublaminar bands and pedicle screws. The biomechanical characteristics of the implants are well distributed, so the stronger pedicle screws with a biomechanical failure strength of 1000 N [14] are adjacent to the fracture, potentially resulting in less loss of reduction.

Long constructs are widely recommended in thoracic fractures and have advantages over the short-segment stabilization concerning the biomechanical stability and loss of

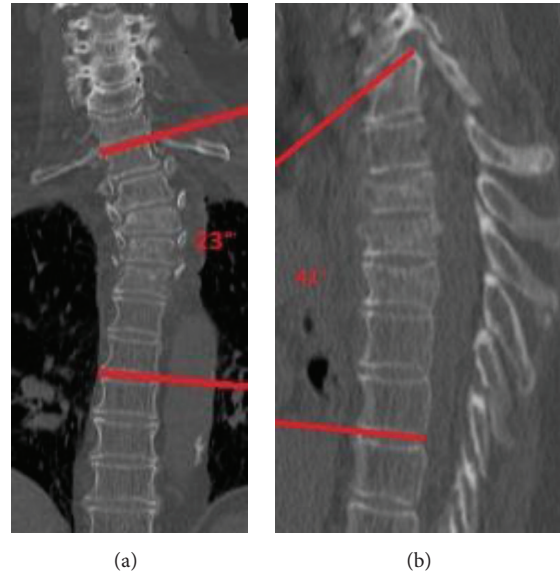


FIGURE 3: (a) CT scan showing the scoliosis and osteoporosis of the patient and the fractures in T3–T5. Cobb angle (T1–7): 23°. (b) CT scan in the sagittal profile. Kyphosis angle (T1–7): 41°.

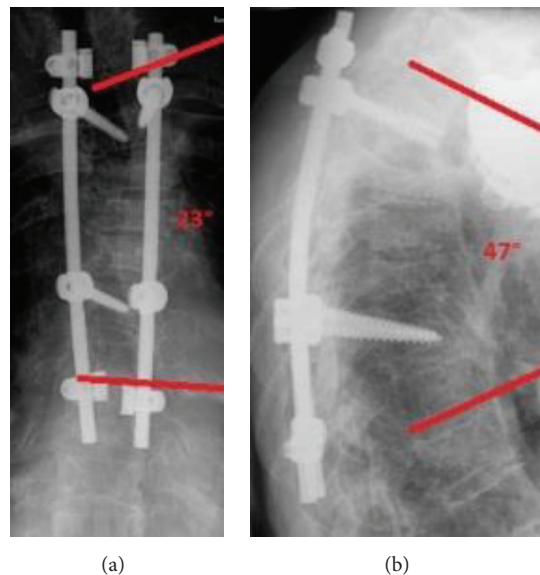


FIGURE 4: (a) Postoperative result with pedicle screws in T2 and T6 and UC System in T1 and T7 (12 months). Cobb angle (T1–7): 23°. (b) Postoperative result lateral (12 months). Kyphosis angle (T1–7): 47°.

correction [1, 2]. McLain [3] claimed that long-segment stabilization has different advantages when used in thoracic fractures. Beside others, the advantages of the long constructs are the multiple fixation points which distribute the forces necessary for the correction over a greater number of segments. So, the force on every point is reduced and the risk of pullout failure is minimized [3]. Disch et al. [15] studied the biomechanical stability of different types of stabilization after spondylectomy and showed that, in the thoracolumbar spine, the long-segment stabilization has a higher stiffness in all motion planes.

Placing thoracic screws in the thoracic vertebrae often is difficult because of the special anatomic features of the thoracic pedicles. The pedicles have smaller diameters compared to the rest of the thoracolumbar spine [16]. Typically, the smallest ones can be found in the 4th thoracic vertebra with an average of  $4.5 \pm 1.2$  mm [17]. If the screw has a bigger diameter than 80% of the pedicle, it can cause morphological changes of the pedicles [18]. This can result in pedicle fractures, breakout of the screws, and extension of the pedicle.

A burst fracture of the pedicle simplifies the screw breakout [14]. In weak bone especially, like in patients suffering

from osteoporosis, the risk of a breakout is higher than that in healthy bone [5, 19].

The consequences of the above-mentioned anatomical situation are frequently misplaced pedicle screws, mostly in the lateral direction because of the thinner pedicle wall on the lateral side [6, 20].

In the literature the frequency of misplaced thoracic screws is reported to be up to 40% [3, 21–23]. Misplaced screws can injure the dura or the spinal cord. They can also impinge the nerve root with associated neurological deficiencies. Other complications are the injury of organs, vessels, or nerves [5, 6, 24–28].

With the proposed hybrid stabilization, the risk of screw misplacement is lowered due to the simple fact that less screws have to be placed.

In special cases, the anatomy of the thoracic vertebrae can be even more challenging, for instance in deformed spines like scoliosis, osteoporosis, and deformation of the vertebrae, like in wedge-shaped vertebrae after a former fracture.

Patients who are suffering from a scoliosis have small pedicles on the concave side of the spine, especially on the apex and the main curve. Therefore, some authors suggest that the screw insertion on the apex of the curve should be avoided [14]. Pedicle diameters are declared between 2.5 and 4.0 mm [29–32]. Kotani et al. [33] reported a pedicle perforation in 11% of the observed patients with a scoliosis.

In our case the patient had a preexisting scoliosis with pedicle diameter less than 3 mm. Placing the sublaminar bands was therefore much easier and safer than inserting the pedicle screws.

Hybrid stabilization with pedicle screws and sublaminar bands might be beneficial in patients with osteoporosis. Chao et al. [19] showed in a biomechanical study that in patients with a  $T$ -score of  $-5.2$  the pull-out force amounts to  $144.3 \pm 92.1$  N. In comparison, in healthy bone, the pull-out force accounts for around 1000 N [5]. In osteoporotic spines, the posterior part with the lamina is stronger than the anterior parts [34]. So, the lamina should be an ideal part to fix an implant. The Universal Clamp System showed high failure loads of  $401 \pm 120$  N in fresh frozen human thoracic spines [35]. In our case number two, no postoperative implant failure occurred despite severe osteoporosis and long construct. No cement augmentation of the screws was necessary.

Another problem for the surgeon is the fact that it can be difficult to visualize bony thoracic structures with the image intensifier intraoperatively. When using sublaminar bands, no radiological control is necessary.

Also the use of sublaminar bands has some limitations. First, a decompression is necessary which carries the risk of dural tears or even damaging the cord. If a laminectomy is performed, no clamps can be fixed at this level. Finally, inserting the sublaminar band takes more time than placing a pedicle screw, at least in our hands. A slightly prolonged surgical time should be considered.

Limitations are the short follow-up time of one year and the missing CT scan after one year. So the fusion rate cannot be determined for sure.

## 5. Conclusion

In patients with a combination of an unstable fracture and difficult anatomic conditions the hybrid stabilization with sublaminar bands and pedicle screws is a reliable technique. Scoliosis, osteoporosis, or small pedicles are risk factors for pedicle screw failure. The use of sublaminar bands can help to avoid such complications.

## Conflict of Interests

All authors whose names are listed herein have no commercial interests in connection with this submitted paper.

## References

- [1] A. P. Verheyden, A. Hölzl, H. Ekkerlein et al., "Recommendations for the treatment of thoracolumbar and lumbar spine injuries," *Unfallchirurg*, vol. 114, no. 1, pp. 9–16, 2011.
- [2] J. J. Verlaan, C. H. Diekerhof, E. Buskens et al., "Surgical treatment of traumatic fractures of the thoracic and lumbar spine: a systematic review of the literature on techniques, complications, and outcome," *Spine*, vol. 29, no. 7, pp. 803–814, 2004.
- [3] R. F. McLain, "The biomechanics of long versus short fixation for thoracolumbar spine fractures," *Spine*, vol. 31, no. 11, pp. S70–S79, 2006.
- [4] O. Schwarzenbach, U. Berlemann, B. Jost et al., "Accuracy of computer-assisted pedicle screw placement: an in vivo computed tomography analysis," *Spine*, vol. 22, no. 4, pp. 452–458, 1997.
- [5] G. Li, G. Lv, P. Passias et al., "Complications associated with thoracic pedicle screws in spinal deformity," *European Spine Journal*, vol. 19, no. 9, pp. 1576–1584, 2010.
- [6] S. D. Gertzbein and S. E. Robbins, "Accuracy of pedicular screw placement in vivo," *Spine*, vol. 15, no. 1, pp. 11–14, 1990.
- [7] E. R. Luque, "Segmental spinal instrumentation for correction of scoliosis," *Clinical Orthopaedics and Related Research*, vol. 163, pp. 192–198, 1982.
- [8] B. A. Akbarnia, J. P. Fogarty, and K. R. Smith Jr., "New trends in surgical stabilization of thoraco-lumbar spinal fractures with emphasis for sublaminar wiring," *Paraplegia*, vol. 23, no. 1, pp. 27–33, 1985.
- [9] H. J. Forbes, P. W. Allen, C. S. Waller et al., "Spinal cord monitoring in scoliosis surgery. Experience with 1168 cases," *The Journal of Bone & Joint Surgery—British Volume*, vol. 73, no. 3, pp. 487–491, 1991.
- [10] C. E. Johnston II, L. T. Happel Jr., R. Norris, S. W. Burke, A. G. King, and J. M. Roberts, "Delayed paraplegia complicating sublaminar segmental spinal instrumentation," *The Journal of Bone & Joint Surgery—American Volume*, vol. 68, no. 4, pp. 556–563, 1986.
- [11] R. Gazzeri, A. Faiola, M. Galarza, and M. Tamorri, "Universal clamp system in thoracolumbar spinal fixation: technical note," *Acta Neurochirurgica*, vol. 151, no. 12, pp. 1673–1680, 2009.
- [12] J. Sales de Gauzy, J.-L. Jouve, B. Ilharberorde, B. Blondel, F. Accadbled, and K. Mazda, "Use of the universal clamp in adolescent idiopathic scoliosis," *European Spine Journal*, vol. 23, supplement 4, pp. S446–S451, 2014.
- [13] F. Magerl, M. Aebi, S. D. Gertzbein, J. Harms, and S. Nazarian, "A comprehensive classification of thoracic and lumbar injuries," *European Spine Journal*, vol. 3, no. 4, pp. 184–201, 1994.

- [14] D. C. George, M. H. Krag, C. C. Johnson, M. E. Van Hal, L. D. Haugh, and L. J. Grobler, "Hole preparation techniques for transpedicle screws. Effect on pull-out strength from human cadaveric vertebrae," *Spine*, vol. 16, no. 2, pp. 181–184, 1991.
- [15] A. C. Disch, A. Luzzati, I. Melcher, K. D. Schaser, F. Feraboli, and W. Schmoelz, "Three-dimensional stiffness in a thoracolumbar en-bloc spondylectomy model: a biomechanical in vitro study," *Clinical Biomechanics*, vol. 22, no. 9, pp. 957–964, 2007.
- [16] M. R. Zindrick, L. L. Wiltse, A. Doornik et al., "Analysis of the morphometric characteristics of the thoracic and lumbar pedicles," *Spine*, vol. 12, no. 2, pp. 160–166, 1987.
- [17] A. R. Vaccaro, S. J. Rizzolo, T. J. Allardyce et al., "Placement of pedicle screws in the thoracic spine. Part I: morphometric analysis of the thoracic vertebrae," *The Journal of Bone & Joint Surgery—American Volume*, vol. 77, no. 8, pp. 1193–1199, 1995.
- [18] G. R. Misenhimer, R. D. Peek, L. L. Wiltse, S. L. G. Rothman, and E. H. Widell Jr., "Anatomic analysis of pedicle cortical and cancellous diameter as related to screw size," *Spine*, vol. 14, no. 4, pp. 367–372, 1989.
- [19] K.-H. Chao, Y.-S. Lai, W.-C. Chen et al., "Biomechanical analysis of different types of pedicle screw augmentation: a cadaveric and synthetic bone sample study of instrumented vertebral specimens," *Medical Engineering and Physics*, vol. 35, no. 10, pp. 1506–1512, 2013.
- [20] U. R. Liljenqvist, H. F. H. Halm, and T. M. Link, "Pedicle screw instrumentation of the thoracic spine in idiopathic scoliosis," *Spine*, vol. 22, no. 19, pp. 2239–2245, 1997.
- [21] P. J. Belmont Jr., W. R. Klemme, A. Dhawan, and D. W. Polly Jr., "In vivo accuracy of thoracic pedicle screws," *Spine*, vol. 26, no. 21, pp. 2340–2346, 2001.
- [22] A. R. Vaccaro, S. J. Rizzolo, R. A. Balderston et al., "Placement of pedicle screws in the thoracic spine," *Journal of Bone and Joint Surgery A*, vol. 77, no. 8, pp. 1200–1206, 1995.
- [23] R. Xu, N. A. Ebraheim, Y. Ou, and R. A. Yeasting, "Anatomic considerations of pedicle screw placement in the thoracic spine: Roy-Camille technique versus open-lamina technique," *Spine*, vol. 23, no. 9, pp. 1065–1068, 1998.
- [24] S.-I. Suk, W.-J. Kim, S.-M. Lee, J.-H. Kim, and E.-R. Chung, "Thoracic pedicle screw fixation in spinal deformities: are they really safe?" *Spine*, vol. 26, no. 18, pp. 2049–2057, 2001.
- [25] M. Di Silvestre, P. Parisini, F. Lolli, and G. Bakaloudis, "Complications of thoracic pedicle screws in scoliosis treatment," *Spine*, vol. 32, no. 15, pp. 1655–1661, 2007.
- [26] R. L. De Saussure, "Vascular injury coincident to disc surgery," *Journal of Neurosurgery*, vol. 16, no. 2, pp. 222–229, 1995.
- [27] F. Oppel, A. J. Schramm, and M. Schirmer, "Results and complicated course after surgery for lumbar disc herniation," in *Lumbar Disc Adult Hydrocephalus*, vol. 4 of *Advances in Neurosurgery*, pp. 36–51, Springer, Berlin, Germany, 1977.
- [28] U. Wildförster, "Intraoperative complications in lumbar intervertebral disk operations. Cooperative study of the spinal study group of the German Society of Neurosurgery," *Neurochirurgia*, vol. 34, no. 2, pp. 53–56, 1991.
- [29] S. Parent, H. Labelle, W. Skalli, and J. de Guise, "Thoracic pedicle morphometry in vertebrae from scoliotic spines," *Spine*, vol. 29, no. 3, pp. 239–248, 2004.
- [30] U. R. Liljenqvist, T. Allkemper, L. Hackenberg, T. M. Link, J. Steinbeck, and H. F. H. Halm, "Analysis of vertebral morphology in idiopathic scoliosis with use of magnetic resonance imaging and multiplanar reconstruction," *The Journal of Bone and Joint Surgery A*, vol. 84, no. 3, pp. 359–368, 2002.
- [31] T. J. Gilbert Jr. and R. B. Winter, "Pedicle anatomy in a patient with severe early-onset scoliosis: can pedicle screws be safely inserted?" *Journal of Spinal Disorders and Techniques*, vol. 18, no. 4, pp. 360–363, 2005.
- [32] K. Takeshita, T. Maruyama, H. Chikuda et al., "Diameter, length, and direction of pedicle screws for scoliotic spine: analysis by multiplanar reconstruction of computed tomography," *Spine*, vol. 34, no. 8, pp. 798–803, 2009.
- [33] Y. Kotani, K. Abumi, M. Ito et al., "Accuracy analysis of pedicle screw placement in posterior scoliosis surgery: comparison between conventional fluoroscopic and computer-assisted technique," *Spine*, vol. 32, no. 14, pp. 1543–1550, 2007.
- [34] X. Banse, J. P. Devogelaer, E. Munting, C. Delloye, O. Cornu, and M. Grynepas, "Inhomogeneity of human vertebral cancellous bone: systematic density and structure patterns inside the vertebral body," *Bone*, vol. 28, no. 5, pp. 563–571, 2001.
- [35] M. Hongo, B. Ilharberorde, R. E. Gay et al., "Biomechanical evaluation of a new fixation device for the thoracic spine," *European Spine Journal*, vol. 18, no. 8, pp. 1213–1219, 2009.