

CASE REPORT

Unmasking of a significant left main stenosis in a patient with high left ventricular pressures

Marco G. Mennuni MD¹ | Martina Solli MD¹ | Vincenzo Galiffa MD¹ |
Giuseppe Patti MD^{1,2} 

¹Division of Cardiology, Interventional Cardiology, Maggiore della Carità Hospital, Novara, Italy

²Department of Translational Medicine, University of Eastern Piedmont, Novara, Italy

Correspondence

Giuseppe Patti, MD, Department of Translational Medicine, University of Eastern Piedmont, Novara, Italy, Maggiore della Carità Hospital, Via Solaroli 17, Novara (NO) 28100, Italy.

Email: giuseppe.patti@uniupo.it

Abstract

As identification of left main (LM) stenoses has prognostic and therapeutic relevance, a precise anatomic and/or functional characterization of angiographically intermediate LM stenoses, by using intravascular ultrasound (IVUS) and fractional flow reserve (FFR) respectively, is crucial (1). However, increased left ventricular (LV) pressures might affect FFR measurements (2). Here we describe the case of a patient with chronic coronary syndrome and severe LV dysfunction in whom coronary angiography revealed an intermediate LM stenosis and catheterization identified an increased LV end-diastolic pressure. FFR measurement showed disproportionately higher FFR values compared with the minimal luminal area assessed by IVUS. When cardiac output was artificially augmented by using Impella for assisting percutaneous coronary intervention, the value of FFR measurement turned out proportional to what expected for the degree of anatomical stenosis. This discrepancy between anatomic and functional measurement may be a sign of coronary autoregulation dysfunction and therefore could help to identify high-risk patients in whom the use of a mechanical support device is more beneficial during percutaneous revascularization.

KEYWORDS

ECMO/IABP/Tandem/Impella, fractional flow reserve (FFR), intravascular ultrasound, IVUS—Imaging, left main coronary disease (LM), left ventricular function (LVF), mechanical circulatory support (MCS)

1 | INTRODUCTION

A precise characterization of left main (LM) stenoses has prognostic and therapeutic relevance.¹ Beyond coronary angiography, in patients with intermediate LM stenosis Guidelines suggest to collect a more detailed anatomical information by intravascular ultrasound (IVUS) or to perform a physiologic measurement to guide the treatment.¹ This “physiologic approach” includes the evaluation of fractional flow

reserve (FFR), which is an index to identify coronary stenoses causing myocardial ischemia. FFR can be obtained by calculating the ratio of mean distal coronary pressure (Pd) measured by a pressure guidewire to mean aortic pressure (Pa) measured simultaneously by the guiding catheter. Notably, FFR use has been validated in populations with normal or slightly elevated left ventricular (LV) filling pressures. Thus, a cautious interpretation of FFR values is required in patients with LV dysfunction, where increased filling pressures might affect FFR

This is an open access article under the terms of the Creative Commons Attribution-NonCommercial License, which permits use, distribution and reproduction in any medium, provided the original work is properly cited and is not used for commercial purposes.

© 2022 The Authors. *Catheterization and Cardiovascular Interventions* published by Wiley Periodicals LLC.

measurements. Previous data demonstrated that LV end-diastolic pressure (LVEDP) was positively associated with FFR measures; this association was greater for FFR values <0.80 and at lower Pa.² To date, evidence on intra-individual variations of FFR measures based on changes of LV filling pressures in the single patient is scant.

1.1 | Case description

We here describe changes of LV, aortic, and coronary pressures and their effects on FFR measurement during the use of Impella CP device in a patient with LM stenosis and severe LV dysfunction. Impella CP is a percutaneous ventricular assistant device providing up to 4 L/min of flow, LV unloading and improved coronary perfusion. The effects of Impella-related changes in LV pressure on functional evaluation of coronary lesions were not previously reported. A 78 years old woman, with hypertension and diabetes mellitus, was admitted for chronic coronary syndrome and severe LV dysfunction. LV ejection fraction at echocardiography was 20% and invasive

LVEDP was 25 mmHg. Coronary angiography showed an intermediate LM stenosis (Figure 1A) with a FFR index of 0.83 (Pd = 67 mmHg, Pa = 81 mmHg) (Figure 1B). Conversely, IVUS imaging showed a significant LM plaque with a minimal luminal area of 4.7 mm² and 180° angle of a calcified arch (Figure 1C). Due to anatomical features of the lesion and concomitant LV dysfunction, we planned a percutaneous coronary intervention (PCI) assisted by Impella CP support. With Impella CP at maximal power (P8) we repeated LVEDP and FFR measurements, being 15 mmHg and 0.65 (Pd = 60 mmHg, Pa = 92 mmHg), respectively (Figure 1D). Then, we successfully performed coronary intravascular lithotripsy and stent implantation on LM stem (Figure 1E).

2 | DISCUSSION

This case demonstrates that an increased LVEDP underestimates the physiological assessment of LM coronary stenosis severity. This can be related to severe diastolic dysfunction resulting in impaired

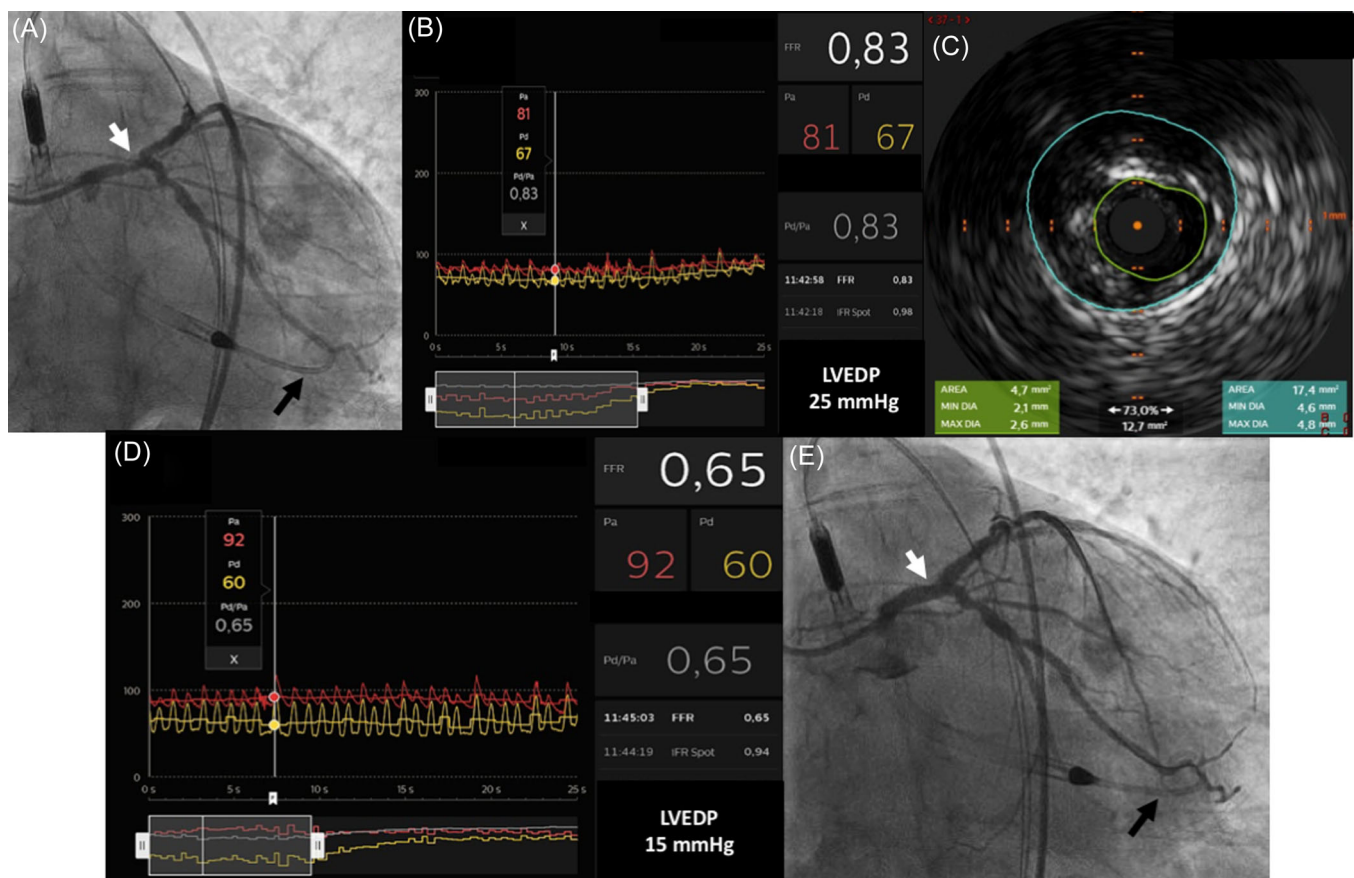


FIGURE 1 (A) Coronary angiography showing the distal LM stenosis (white arrow). Black arrow indicates the Impella CP device (Abimed) turned off in the left ventricle. (B) Functional measurement by pressure wire (OmniWire; Koninklijke Philips N.V.) without Impella CP support demonstrating a FFR index of 0.83 (with LVEDP 25 mmHg). (C) IVUS imaging (Eagle Eye Platinum; Philips Volcano) showing the LM plaque with 180° angle of a calcified arch and a minimal luminal area of 4.7 mm². (D) Functional measurement indicating a FFR index of 0.65 (with LVEDP 15 mmHg) under Impella CP support at maximal power. (E) Coronary angiography after LM stent implantation (white arrow). Black arrow indicates the Impella CP device in the left ventricle. FFR, fractional flow reserve; IVUS, intravascular ultrasound; LM, left main; LVEDP, left ventricular end-diastolic pressure. [Color figure can be viewed at wileyonlinelibrary.com]

coronary flow. A physiological coronary flow peak has been described in diastole, due to the dominance of a “suction wave” generated by coronary microcirculatory decompression.³ This wave is significantly reduced in patients with diastolic dysfunction.³ Furthermore, the vasodilatory capacity of coronary arterioles in patients with increased LVEDP, in our case being related to persisting, large myocardial ischemia and LV dysfunction, is reduced or exhausted at rest; thus, the vasodilatory effect of adenosine on microcirculatory resistance is limited. A similar condition has been described in patients with severe aortic stenosis, where LVEDP reduction by transcatheter aortic valve replacement leads to immediate recovery of coronary microcirculatory resistance and increased hyperemic flow velocity.⁴ In our patient, LV unloading and LVEDP decreasing by Impella, coupled with the device-related increase of aortic pressures and reduction of coronary pressures, restored the coronary autoregulation pathways, in particular improving the physiological diastolic “suction wave” and increasing coronary flow. This “unmasked” the functional severity of LM stenosis.

Previous data showed that anatomical and functional evaluation for LM disease are highly correlated in normal loading conditions.⁵ Notably, our case suggests to privilege the use of IVUS rather than FFR for LM assessment of patients with LV overload, given a higher sensitivity and the capability to provide potentially relevant anatomic information. However, the MLA cut-off value assessed by IVUS is a matter of debate. Furthermore, a mismatch between anatomical and physiological coronary severity, namely intermediate-to-severe stenoses associated with normal or near-normal FFR values, might represent a marker of dysfunctional autoregulation and help to select high-risk patients requiring a mechanical ventricular support during PCI. Notably, previous data demonstrated that the hemodynamic benefit of intra-aortic balloon pump (IABP) was maximal when coronary autoregulation was impaired (e.g., in presence of severe LV dysfunction).⁶ In this condition, IABP augments myocardial perfusion, mainly due to a diastolic forward compression wave caused by balloon inflation.⁶ Similarly, Impella support might be predominantly beneficial in patients with coronary autoregulation dysfunction. However, our data represent working hypotheses requiring future mechanistic studies.

3 | CONCLUSION

In patients with LM stenosis and high LV pressures, the discrepancy between anatomic and functional measurement may be a sign of coronary autoregulation dysfunction and therefore could help to identify high-risk patients in whom the use of a mechanical support device is more beneficial during percutaneous revascularization.

ACKNOWLEDGMENTS

We thank Dr. Leonardo Grisafi (Fellowship School in Cardiovascular diseases, University of Eastern Piedmont, Novara, Italy), for contributing to this case report. Open Access Funding provided by Università degli Studi del Piemonte Orientale Amedeo Avogadro within the CRUI-CARE Agreement.

CONFLICT OF INTEREST

G.P.: advisory board/speaker/consultant fees from Abbott, Astra Zeneca, Sanofi, Amgen, Menarini, Bayer, Pfizer, BMS, Daiichi Sankyo, PIAM, Malesci, Sigma Tau, Chiesi, MSD, Boehringer Ingelheim, Servier, Guidotti, Medtronic, Biosensors. M.M.: none. M.S.: none. V.G.: none.

DATA AVAILABILITY STATEMENT

The data that support the findings of this study are available from the corresponding author upon reasonable request.

ORCID

Giuseppe Patti  <http://orcid.org/0000-0002-5404-3968>

REFERENCES

1. Neumann FJ, Sousa-Uva M, Ahlsson A, et al. 2018 ESC/EACTS guidelines on myocardial revascularization. *Eur Heart J*. 2019;40(2): 87-165. doi:10.1093/eurheartj/ehy394
2. Leonardi RA, Townsend JC, Patel CA, et al. Left ventricular end-diastolic pressure affects measurement of fractional flow reserve. *Cardiovasc Revasc Med*. 2013;14(4):218-222. doi:10.1016/j.carrev.2013.06.001
3. Davies JE, Whinnett ZI, Francis DP, et al. Evidence of a dominant Backward-Propagating “suction” wave responsible for diastolic coronary filling in humans, attenuated in left ventricular hypertrophy. *Circulation*. 2006;113(14):1768-1778. doi:10.1161/CIRCULATIONAHA.105.603050
4. Aleksandric S, Banovic M, Beleslin B. Challenges in diagnosis and functional assessment of coronary artery disease in patients with severe aortic stenosis. *Front Cardiovasc Med*. 2022;9:849032.
5. D'Ascenzo F, Barbero U, Cerrato E, et al. Accuracy of intravascular ultrasound and optical coherence tomography in identifying functionally significant coronary stenosis according to vessel diameter: a meta-analysis of 2,581 patients and 2,807 lesions. *Am Heart J*. 2015;169(5):663-673. doi:10.1016/j.ahj.2015.01.013
6. De Silva K, Lumley M, Kailey B, et al. Coronary and microvascular physiology during intra-aortic balloon counterpulsation. *JACC Cardiovasc Interv*. 2014;7(6):631-640. doi:10.1016/j.jcin.2013.11.023

How to cite this article: Mennuni MG, Solli M, Galiffa V, Patti G. Unmasking of a significant left main stenosis in a patient with high left ventricular pressures. *Catheter Cardiovasc Interv*. 2022;100:216-218. doi:10.1002/ccd.30297