


ORIGINAL ARTICLE

Stripping versus ligation of vas deferens in microscopic denervation of spermatic cord in men with chronic orchialgia: A multicenter study

Adnan El-Achkar¹  | Muhammed Hammad²  | David Barham² | Chad A Service³ | Darshan Patel³ | Tung Chin Hsieh³ | Jesse Mills⁴ | Reza Kianian⁴ | Sriram Eleswarapu⁴ | Matthew Ziegelmann⁵ | Ryan Smith⁶ | Darren Bryk⁶ | Helen L Bernie⁷ | Melissa Egert⁷ | Omer Raheem⁸ | Kiarad Fendereski⁹ | Kelli Gross⁹ | Alex Pastuszak⁹ | James Hotaling⁹ | Faysal Yafi²

¹Department of Urology, American University of Beirut, Beirut, Lebanon

²Department of Urology, University of California Irvine, Orange, California, USA

³Department of Urology, University of California San Diego, San Diego, California, USA

⁴David Geffen School of Medicine, UCLA, Los Angeles, California, USA

⁵Department of Urology, Mayo Clinic, Rochester, Minnesota, USA

⁶Department of Urology, University of Virginia, Charlottesville, Virginia, USA

⁷Department of Urology, Indiana University, Indianapolis, Indiana, USA

⁸Department of Urology, University of Chicago, Chicago, Illinois, USA

⁹Department of Urology, University of Utah, Salt Lake City, Utah, USA

Correspondence

Faysal Yafi, Department of Urology, University of California, Irvine, CA, USA.

Email: fyafi@hs.uci.edu

Abstract

Background: Microdenervation of the spermatic cord (MSCD) is an effective treatment modality for men with intractable scrotal content pain. For patients not interested in preserving fertility, some centers advocate ligation of the vas during denervation, while others prefer stripping of the vas deferens to preserve the vasal artery, hence preserving vasculature to the testis and possibly decreasing post-operative congestion pain.

Objective: To compare outcomes of patients with chronic orchialgia, who underwent MSCD by either stripping or ligating the vas deferens.

Materials and methods: A retrospective chart review of 85 patients who underwent MSCD from 2017–2023 was performed. Patients' demographics including history of prior surgical procedures were recorded. Response to surgery was evaluated as either complete resolution of pain, partial resolution of pain, or no improvement in pain.

Results: Eighty-five patients underwent MSCD with a median (interquartile range, IQR) age of 36 (25.5–46.5) years and median duration of pain of 16 (6–31) months. Thirty-seven patients underwent stripping of vas, while 48 underwent ligation of vas during MSCD. Median follow up was 12 months. Twenty-one (43.5%) patients had prior inguinal scrotal surgery in the ligation group compared to 5 (13.5%) in the stripping group, $p = 0.003$. The etiology of pain was similar between the groups. The response to MSCD between the two groups was similar, 67.6% of patients who underwent stripping had complete resolution of pain versus 66.7% of those who had ligation ($p = 0.968$), with similar rates of post-operative complications (p -value = 0.132).

Conclusions: In men with intractable chronic scrotal content pain with no interest in preserving fertility, ligation, or stripping of the vas deferens yields similar

outcomes with regard to pain resolution. Both techniques are safe with no reports of any testicular atrophy.

KEYWORDS

chronic scrotal pain, ligation of vas, microscopic denervation of spermatic cord, surgical technique, treatment outcomes

1 | INTRODUCTION

Chronic orchialgia (scrotal content pain) is a distressing and poorly understood condition that significantly impacts patients' overall quality of life.^{1,2} It is marked by persistent or intermittent testicular discomfort lasting a minimum of 3 months, significantly impeding patient's daily activities.³ The discomfort may arise from any of the structures within the scrotal region, including the testicle, epididymis, para-testicular structures, and spermatic cord (Figure 1).⁴ Treatment poses challenges for both patients and clinicians due to the lack of clear treatment guidelines.⁵

Microscopic denervation of the spermatic cord (MSCD) has become the surgical intervention of choice in patients who fail conservative management (Figure 2).⁶ Since its description in 1978, the surgical technique of MSCD has not undergone any major changes.⁷ It entails the skeletonization of the spermatic cord preserving only the lymphat-

ics, testicular artery, and sometimes the vas deferens and its artery. In men who have not had a vasectomy and do not have an interest in fertility, the outer vasal sheath is stripped for 2 cm and 1 cm segment of vas is excised.⁵ MSCD has demonstrated effectiveness in alleviating chronic scrotal pain.⁸ Classically, the vasal sheath is stripped, while the vasal artery is preserved. In patients not interested in maintaining fertility, some urologists elect to ligate the vas deferens and its artery to ensure proper ligation of all perivasal tissue, which is a nerve dense region in the spermatic cord that plays a role in chronic orchialgia.^{9,10} While this technique might be easier and more appealing than stripping of the vas, some urologists have concerns over the risk of testicular atrophy and post vasectomy pain syndrome (PVPS) associated with ligation of vas. Currently, there is a lack of data in the literature that compares pain response of ligations versus stripping of vas deferens during MSCD. This is a multicenter retrospective study that sought to compare treatment outcomes associated with stripping or ligation of the vas deferens during MSCD.

2 | METHODS

We conducted a retrospective analysis involving seven US academic institutions. Data on 85 patients who had undergone MSCD from 2017–2023 as a therapeutic intervention for chronic scrotal pain was collected. We sorted patients into two distinct groups based on the surgical technique employed: the "stripping" group, comprising 37 individuals and the "ligation" group, comprising 48 individuals. Data on patient demographics, previous surgical history, duration of pain, MSCD technique, and perioperative complications were collected. The primary outcome was the pain response to surgery. The secondary outcomes were post-operative complications. Patients' responses to the treatment were categorized into three groups based on their pain outcomes. Those who experienced complete relief from pain and had no recurrence during follow-up were classified as having a "complete response." Conversely, patients with a "partial response" reported some improvement in pain symptoms but may still have occasional or intermittent pain recurrence. Despite these recurrences, patients subjectively described a reduction in overall pain compared to baseline. Lastly, patients who showed "no response" to treatment did not experience any improvement in pain symptoms, with their pain persisting at the same level or worsening over time, indicating no discernible benefit from the intervention. The response to the treatment was retrieved from the charts and had to have been recorded by the physician. No questionnaires nor

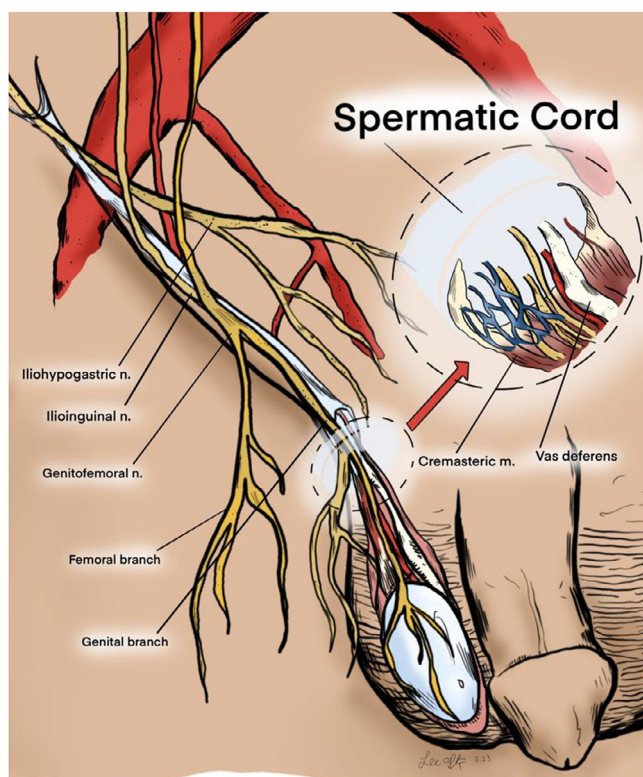


FIGURE 1 Complex innervation of the inguinoscrotal region. The spermatic cord is rich in nerves with close relationship to the vas deferens and vessels in the cord.

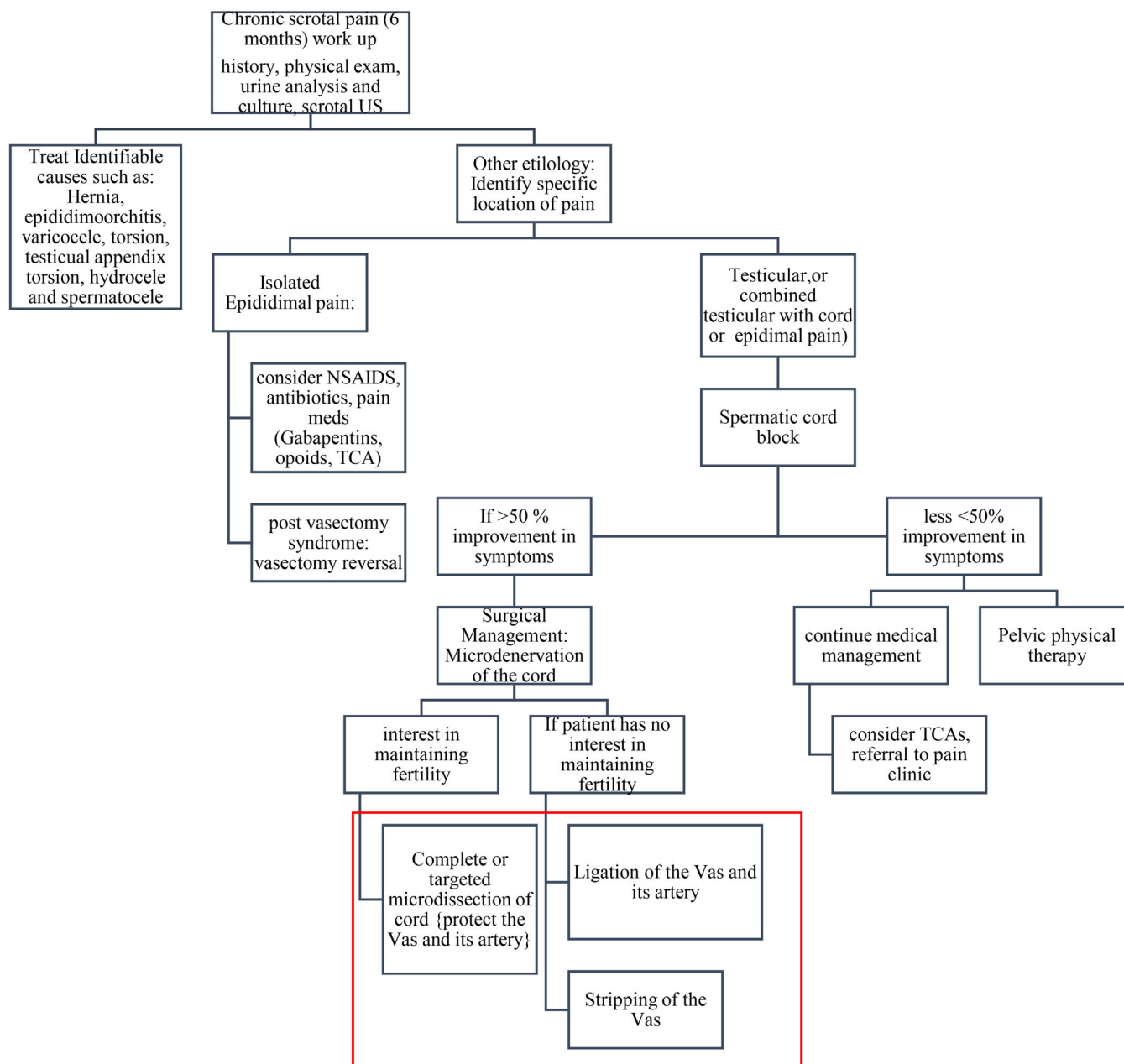


FIGURE 2 Chronic scrotal pain management algorithm. MSCD, Microscopic cord denervation; US, ultrasound; NSAIDS, non-steroidal anti-inflammatories; TCA, tricyclic antidepressants.

pain visual analog scales (VAS) were used systematically to assess the pain.

Eligible participants must have presented with localized pain in the testicle and this pain should not have an identifiable anatomical or pathologically identifiable cause. In addition, inclusion necessitated that patients had failed the conservative therapy. Only those who responded positively to a spermatic cord block (> 50% improvement of pain) and underwent full MSCD rather than targeted MSCD were considered.^{11,12} Furthermore, the ligation group included only individuals who expressed no interest in preserving fertility. A thorough clinical evaluation was done to rule out other etiologies of pain such as infectious or chronic epididymitis, infectious orchitis, varico-

cele, retractile testis, nerve entrapment post-inguinoscrotal surgery, chronic pelvic pain syndrome, and benign prostatic hyperplasia and associated lower urinary tract symptoms. Patients with a history of hernia or nerve entrapment related to mesh were excluded from the participation. Additionally, individuals who underwent a vasectomy prior to MSCD were also excluded.

Continuous variables were described with median, mean, and interquartile ranges (IQRs), whereas categorical variables were described with counts and percentages. For normally distributed continuous variables, independent *T*-test was used to test for significance, while for categorical variables the Chi-squared test was used to test for the significant association between independent (predictor) and

TABLE 1 Demographic, etiology of pain and outcomes of microscopic denervation of spermatic cord (MSCD) in patients undergoing MSCD with either stripping or ligation of vas deferens.

	Stripping (N = 37)	Ligation (N = 48)	p-value
Median age (IQR)	31 (24–45)	38 (29.5–49)	0.042*
Race			0.006*
White	20 (54%)	41 (85.4%)	
African American	4 (10.8%)	0	
Hispanic	7 (18.9%)	5 (10.4%)	
Asian	1 (2.7%)	0	
Mixed	5 (13.5%)	2 (4.2%)	
Patients with no children	30 (81.1%)	43 (89.6%)	0.661
Social Hx			0.678
Smoker	7 (19%)	7 (14.6%)	
Substance use	5 (13.5%)	7 (14.6%)	
Alcohol abuse	2 (5.4%)	6 (12.5%)	
Hx of inguinal scrotal surgery	5 (13.5%)	21 (43.8%)	0.003*
Median duration of pain	17 (8.5–26.5)	12 (5.0–36.0)	0.123
Sides of the pain			0.270
Unilateral	21 (73%)	33 (69%)	
Bilateral	10 (27%)	15 (31%)	
Not specified			
Possible etiology of pain			0.208
Idiopathic	27 (73%)	25 (52.1%)	
Trauma	3 (8%)	4 (8.3%)	
Post-inguinoscrotal surgery	4 (11%)	11 (22.9%)	
Post infection	3 (8%)	8 (16.7%)	
Microdissection			0.663
Unilateral	27 (73%)	37 (77%)	
Bilateral	10 (27%)	11 (23%)	
Response			0.968
Complete	25 (67.6%)	30 (66.7%)	
Partial	10 (27%)	13 (28.9%)	
No-response	2 (2%)	2 (4.4%)	
Post op complications (hematoma, infection, seroma, testicular atrophy, etc.)	1 (2.7%)	6 (14.2%)	0.132
Surgical site infection	1	1	
Hematoma	0	1	
Hydrocele	0	3	
Seroma	0	1	
Testicular atrophy	0	0	

Abbreviations: IQR, Interquartile range; Hx, history.

*p-value < 0.05.

dependent (outcome) variables. Two-sided statistical significance was set at p -value < 0.05 for all variables. All analyses were conducted using the statistical analysis software platform (IBM SPSS) for MAC version 28.0.0.0 (SPSS, Chicago, IL USA).

3 | RESULTS

A total 85 patients were included in this study. Thirty-seven patients (43.5%) underwent stripping, while 48 patients (56.5%) underwent ligation of the vas deferens. The median follow-up for both groups was 12 months. The ligation group was slightly older with a median age (IQR) of 38 years versus 31 years for the stripping group ($p = 0.042$). Also, the ligation group was more likely to have had a history of inguinal scrotal surgery (43.8% vs. 13.5% $p = 0.003$) (Table 1). Both groups had similar etiology of pain ($p = 0.208$). The response to treatment was similar between both groups: 67.6% of patients who underwent stripping had complete response to pain versus 66.7% of those who had ligation, $p = 0.968$. Post-operative complications were also similar ($p = 0.132$) with no reported post-operative testicular atrophy (Table 1).

4 | DISCUSSION

MSCD remains the treatment of choice for patients with chronic orchialgia who failed the conservative therapy.⁶ While some surgeons advocate transection of the vas deferens during MSCD to ensure ligation of the peri-vasal nerves, especially in patients those who are not interested in maintaining fertility, others strive to preserve the vas deferens and vasal artery in order to avoid congestion pain, post vasectomy syndrome, and testicular atrophy (Figure 2). Our study shows that both approaches offer similar pain control and similar perioperative complication rates (Table 1). At a median of 12-months follow-up, none of the patients developed PVSP and none had testicular atrophy.

Different anatomic studies highlighted the perivascular area as part of a trifecta of sites in the cord that are rich in nerves with Wallerian degeneration. The nerve distribution is around the vas, in the cremaster muscle fibers and in the posterior lipomatous/perivessel tissues.⁹ Another anatomic study noted a higher number of nociceptive nerves in patients with chronic orchialgia concentrated around the vas and in the spermatic fascia.¹⁰ The peri-vasal tissue and vasal sheath are harder to strip when attempting to maintain the artery. With similar complication rates and equal effectivity in relieving pain, ligation of the vas and its artery might decrease complexity of surgery, save operating room (OR) time, and ensure all nerves are ligated.

Anatomic studies have given us the opportunity to better target these nerves and potentially decrease risks of harm to other cord structures. Kavoussi et al. attempted to validate a targeted MSCD, where only areas previously mentioned are targeted.⁹ In their study, 43 men underwent targeted MSCD compared to 39 who underwent full MSCD. There was no significant difference in resolution of pain with targeted compared to traditional MSCD (69.8% vs. 66.7% $p = 0.88$). However, targeted MSCD had a shorter operative time (21 min vs. 53 min,

$P = 0.0001$).¹¹ In this study, all the patients underwent full MSCD. The targeted approach to MSCD is appealing given the decreased complexity of surgery and shorter operative time, but identifying which patients would benefit from limited MSCD is crucial to optimize the response rate to surgery. Anatomical studies have shown slight variation in distribution of nerves in the cord which might partially explain the suboptimal response (30% partial response or no response).^{9,10} Another limitation of the MSCD technique is our lack of ability to visualize nerves in vivo in real time intraoperatively, Ramasamy et al. focally ablated nerves in vivo using photon microscopy in rats.¹³ Potential advancement in this technology would help achieve an even more accurate, targeted, and less aggressive version of MSCD. More anatomical real time ablative studies are needed to better understand spermatic cord nerve anatomy and perform micro-targeted therapy.

Robotic assistance during microsurgery can provide surgeons many advantages including operative efficiency, elimination of tremor, enhanced vision, and imaging. Robotic-assisted targeted MSCD was described by Parekatill et al. in 2011 in 151 patients with a short median follow-up of 4 months. In this study, 85% of patients had significant decrease in pain score (defined as pain with no impact on quality of life), that is, score of less or equal to 50 on PIQ-6 (Quality Metric Inc., Lincoln, RI, USA) or $> 50\%$ reduction in pain.¹⁴ All our cases were done non-robotically under the microscope. Although the outcomes of robotic MSCD are comparable to microscopic, the use of robotic surgery for MSCD is associated with significantly higher costs, need for specialized equipment and robotic surgical training.

As previously mentioned, patient selection is crucial for outcomes of MSCD and some have attempted to identify potential predictors of failure of MSCD.^{12,15} Preoperatively patients with possible etiology of PVPS are the least likely to respond compared to those who have had inguinoscrotal surgery and those who had idiopathic chronic orchialgia.¹⁵ In our cohort, the possible etiology is similar between the two groups ($p = 0.208$), and we excluded PVPS patients. In addition, the selection criteria for MSCD should include only those who fail the medical treatment and who respond well to cord blocks.¹² Benson et al. had shown that the better the response to the block the higher the chance of pain relief post MSCD.¹² Also, the characteristic of the pain, whether it is intermittent or continuous, might be a predictor of failure to MSCD.¹⁴ Also, pelvic floor muscle spasm (PFMS) independently predicted MSCD failure (OR 3.95, $P = 0.02$) in another study.⁸ PFMS might induce referred scrotal pain and might be due to nociceptor active inflammatory cytokines at the level of pelvic floor not targeted by MSCD.^{8,16,17} Currently, the response rate to MSCD is still not ideal despite better selection of patient preoperatively, 67% only respond fully to MSCD and more than 30% of patients either have partial response or no response. In our study, 2%–4% of patients did not respond at all compared to 7%–15% in the Kavoussi study that did not exclude PVPS patients. This highlights the vital importance of preoperative patient selection.

Comprehensive counseling for men undergoing microscopic denervation of the cord with ligation of the vas deferens is important. It is crucial to inform these individuals about the potential implications for irreversible infertility, particularly in bilateral cases due to the

challenges associated with subinguinal reversal in such cases, as it may be technically complex and may not always result in successful restoration of fertility. Therefore, thorough counseling regarding the potential need for alternative fertility treatments such as testicular sperm extraction (TESE), in vitro fertilization (IVF), and intracytoplasmic sperm injection (ICSI) in instances, where reversal is not feasible or unsuccessful. Physicians should ensure that men are equipped with the necessary information to make informed decisions regarding their reproductive health and future family planning goals in light of the procedure's potential irreversible impact on fertility.

This study is not without limitation. First, this is a retrospective study which carries with it an inherent bias in patient selection. Given that this is a multicenter study, patient selection as well as response to cord block was not standardized. The dosage of anesthetics used for a cord block and the assessment of response is variable which might carry a selection bias across the cohort. While some studies relied on standardized pain questionnaires like the McGill pain questionnaire and visual analog scales to assess pain and surgical response, allowing for the detection of subtle improvements in pain scores, our approach to reporting pain response adopts a qualitative perspective.^{15,18} The retrospective nature of qualitative pain assessment may introduce biases, including patient recall bias and surgeon reporting bias. Additionally, pain experiences vary significantly among individuals due to factors such as pain tolerance, psychological state, and cultural background. Consequently, our pain assessment method may lack the sensitivity to discern subtle changes in pain intensity or quality. Nonetheless, our pain scale offers a clinically conservative and real-life measure of pain response to MSCD. Lastly, although the median follow up is short (12 months), our study has similar follow up to other studies in the literature, and likely long enough to ascertain changes in pain.^{11,15} All in all, our data on the number of patients that had completely responded to MSCD is in keep with literature.^{6,11,14}

5 | CONCLUSION

In patients with no interest in maintaining fertility, ligation or stripping of the vas deferens during microsurgical denervation of the cord for chronic orchialgia has similar pain outcomes and post-operative complication rates.

AUTHOR CONTRIBUTIONS

Conceptualization: Faysal Yafi, James Hotaling, David Barham, Chad A. Service, Darshan Patel, Tung Chin Hsieh, Jesse Mills, Reza Kianian, Helen L. Bernie, Ryan Smith, Sriram Eleswarapu, Matthew Ziegelmann. **Methodology:** Faysal Yafi, Adnan El-Achkar, Jesse Mills, Darshan Patel, Helen L. Bernie. **Data collection:** Muhammed Hammad, Darren Bryk, Melissa Egert, Omer Raheem, Kiarad Fendereski. **Formal analysis:** Adnan El-Achkar, Muhammed Hammad. **Manuscript preparation and editing:** Adnan El-Achkar, Muhammed Hammad, David Barham, Faysal Yafi. **Supervision:** Faysal Yafi.

ACKNOWLEDGMENTS

Yeonsoo Sara Lee for illustrations.

CONFLICT OF INTEREST STATEMENT

The authors declare no conflicts of interest.

DATA AVAILABILITY STATEMENT

The data that support the findings of this study are available from the corresponding author upon reasonable request.

ORCID

Adnan El-Achkar  <https://orcid.org/0000-0002-3656-4217>

Muhammed Hammad  <https://orcid.org/0000-0001-5396-1364>

REFERENCES

1. Wu C, Jarvi K. Chronic scrotal pain. *Curr Urol Rep*. 2018;19:59. doi:10.1007/s11934-018-0811-2
2. Moubasher A, Waqar M, Raison N, Brunckhorst O, Ahmed K. A review of the management of chronic scrotal pain. *Cureus*. 2020;12:e11979. doi:10.7759/cureus.11979
3. Davis BE, Noble MJ, Weigel JW, Foret JD, Mebust WK. Analysis and management of chronic testicular pain. *J Urol*. 1990;143:936-939. doi:10.1016/s0022-5347(17)40143-1
4. Levine L. Chronic orchialgia: evaluation and discussion of treatment options. *Ther Adv Urol*. 2010;2:209-214. doi:10.1177/1756287210390409
5. Tatem A, Kovac JR. Chronic scrotal pain and microsurgical spermatic cord denervation: tricks of the trade. *Transl Androl Urol*. 2017;6:S30-s36. doi:10.21037/tau.2017.05.17
6. Strom KH, Levine LA. Microsurgical denervation of the spermatic cord for chronic orchialgia: long-term results from a single center. *J Urol*. 2008;180:949-953. doi:10.1016/j.juro.2008.05.018
7. Devine CJ Jr, Schellhammer PF. The use of microsurgical denervation of the spermatic cord for orchialgia. *Trans Am Assoc Genitourin Surg*. 1978;70:149-151.
8. Murthy PB, Parekh NV, Vij SC, Shoskes DA. Microscopic spermatic cord denervation for chronic orchialgia/chronic scrotal content pain: operative outcomes and predictors of failure. *Transl Androl Urol*. 2020;9:1931-1936. doi:10.21037/tau-20-561
9. Parekattil SJ, Gudeloglu A, Brahmabhatt JV, Priola KB, Vieweg J, Allan RW. Trifecta nerve complex: potential anatomical basis for microsurgical denervation of the spermatic cord for chronic orchialgia. *J Urol*. 2013;190:265-270. doi:10.1016/j.juro.2013.01.045
10. Oka S, Shiraishi K, Matsuyama H. Microsurgical anatomy of the spermatic cord and spermatic fascia: distribution of lymphatics, and sensory and autonomic nerves. *J Urol*. 2016;195:1841-1847. doi:10.1016/j.juro.2015.11.041
11. Kavoussi PK. Validation of targeted microsurgical spermatic cord denervation: comparison of outcomes to traditional complete microsurgical spermatic cord denervation. *Asian J Androl*. 2019;21:319-323. doi:10.4103/aja.aja_87_18
12. Benson JS, Abern MR, Larsen S, Levine LA. Does a positive response to spermatic cord block predict response to microdenervation of the spermatic cord for chronic scrotal content pain? *J Sex Med*. 2013;10:876-882. doi:10.1111/j.1743-6109.2012.02937.x
13. Ramasamy R, Sterling J, Li PS, et al. Multiphoton imaging and laser ablation of rodent spermatic cord nerves: potential treatment for patients with chronic orchialgia. *J Urol*. 2012;187(2):733-738.

14. Parekattil SJ, Brahmabhatt JV. Robotic approaches for male infertility and chronic orchialgia microsurgery. *Curr Opin Urol*. 2011;21:493-499. doi:[10.1097/MOU.0b013e32834bb783](https://doi.org/10.1097/MOU.0b013e32834bb783)
15. Kavoussi PK, West BT, Machen GL. Preoperative predictors of failure of microsurgical spermatic cord denervation for men with chronic orchialgia. *Urology*. 2021;149:30-33. doi:[10.1016/j.urology.2020.11.030](https://doi.org/10.1016/j.urology.2020.11.030)
16. Shah JP, Danoff JV, Desai MJ, et al. Biochemicals associated with pain and inflammation are elevated in sites near to and remote from active myofascial trigger points. *Arch Phys Med Rehabil*. 2008;89:16-23. doi:[10.1016/j.apmr.2007.10.018](https://doi.org/10.1016/j.apmr.2007.10.018)
17. Moldwin RM, Fariello JY. Myofascial trigger points of the pelvic floor: associations with urological pain syndromes and treatment strategies including injection therapy. *Curr Urol Rep*. 2013;14:409-417. doi:[10.1007/s11934-013-0360-7](https://doi.org/10.1007/s11934-013-0360-7)
18. Shiraishi K, Tabara M, Matsuyama H. High inguinal microsurgical denervation of the spermatic cord for chronic scrotal content pain: a novel approach for adult and pediatric patients. *Urology*. 2019;131:144-149. doi:[10.1016/j.urology.2019.05.013](https://doi.org/10.1016/j.urology.2019.05.013)

How to cite this article: El-Achkar A, Hammad M, Barham D, et al. Stripping versus ligation of vas deferens in microscopic denervation of spermatic cord in men with chronic orchialgia: A multicenter study. *Andrology*. 2025;13:268-274. <https://doi.org/10.1111/andr.13650>