

Case report

Open Access

## Clinico-pathogenetic findings and management of chondrodystrophic myotonia (Schwartz-Jampel syndrome): a case report

Nicola C Ho\*<sup>1,2</sup>, Stacey Sandusky<sup>1</sup>, Victor Madike<sup>1</sup>, Clair A Francomano<sup>1</sup> and Marinos C Dalakas<sup>3</sup>

Address: <sup>1</sup>Human Genetics & Integrative Medicine Section, LG, NIA, National Institutes of Health, Baltimore, MD, USA, <sup>2</sup>Department of Pediatrics, Johns Hopkins Medical Institutions, Baltimore, MD, USA and <sup>3</sup>Neuromuscular Diseases Section, NINDS, National Institutes of Health, Bethesda, MD, USA

Email: Nicola C Ho\* - honi@grc.nia.nih.gov; Stacey Sandusky - sanduskyst@grc.nia.nih.gov; Victor Madike - madikevi@grc.nia.nih.gov; Clair A Francomano - francomano@grc.nia.nih.gov; Marinos C Dalakas - dalakasm@ninds.nih.gov

\* Corresponding author

Published: 02 July 2003

Received: 07 March 2003

BMC Neurology 2003, 3:3

Accepted: 02 July 2003

This article is available from: <http://www.biomedcentral.com/1471-2377/3/3>

© 2003 Ho et al; licensee BioMed Central Ltd. This is an Open Access article: verbatim copying and redistribution of this article are permitted in all media for any purpose, provided this notice is preserved along with the article's original URL.

### Abstract

**Background:** Chondrodystrophic myotonia or Schwartz-Jampel syndrome is a rare genetic disorder characterized by myotonia and skeletal dysplasia. It may be progressive in nature. Recently, the gene responsible for Schwartz-Jampel syndrome has been found and the defective protein it encodes leads to abnormal cartilage development and anomalous neuromuscular activity.

**Case Presentation:** We report the clinical findings and the management of an 8-year-old boy with this disorder. The molecular findings confirm that the patient is a compound heterozygote with a different splicing mutation in each *Perlecan* allele. This resulted in a significant reduction in the production of the encoded normal protein.

**Conclusion:** We discuss the multi-disciplinary management of Schwartz-Jampel syndrome that will facilitate optimal care and timely intervention of patients with this disorder.

### Background

In 1962, Oscar Schwartz and Robert Jampel jointly described a rare autosomal recessive disorder in a pair of siblings. The children had short stature, myotonia with paucity of facial expression, blepharophimosis, pectus carinatum, and contractures. [1] This disorder was also designated osteo-chondro-muscular dystrophy or chondrodystrophic myotonia, [2] and it was initially thought to be neurogenic in etiology. Recently, mutations in the gene *Perlecan* (*HSPG2*) encoding the protein heparan sulfate proteoglycan 2, have been found to be responsible for this condition. *Perlecan* resides in 1p34-p35.1. Its attendant defect leads to abnormal cartilage development and

anomalous neuromuscular activity, resulting in skeletal dysplasia and electrophysiologic signs of myotonia as seen in chondrodystrophic myotonia or Schwartz-Jampel syndrome (SJS). [3,4]

We report the case of an 8-year-old boy with SJS associated with *Perlecan* mutations. We discuss the clinical features, molecular findings, and management of this disorder.

### Case Presentation

An 8-year-old Caucasian boy presented with distinctive facial features, mild generalized muscle weakness and muscle stiffness. He was born to healthy, non-consan-

guineous parents. He started walking at the age of 16–18 months. His mother expressed concern about the unusual positioning of his legs and feet. At the age of 3 years, the patient was noted to have distinctive facies and skeletal abnormalities, which became increasingly apparent and progressive with time. There was no family history of neuromuscular disorders or skeletal dysplasias.

Because his main complaint was generalized muscle stiffness, he was prescribed carbamazepine 600 mg in the morning and 700 mg in the evening. Having a warm bath twice a day also help in alleviating his stiffness. Gradually, he experienced mild muscle weakness in his lower extremities resulting in inability to get up from the floor. He expressed difficulty in climbing stairs and running. One positive aspect was that his frequency of falls had reduced.

Physical examination revealed a boy with unusual facies and stiffness. His height was 122 cm (15<sup>th</sup> percentile), weight 25.3 kg (50<sup>th</sup>), and head circumference 54.3 cm (90<sup>th</sup>). He was normotensive. His distinctive facial features included blepharophimosis, low set ears with folded helices, a fixed facial expression due to tonic contraction of the facial muscles, pursed lips caused by contraction of the perioral muscles, and micrognathia (figure 1). He was mildly myopic. His palate was highly arched. He had a high-pitched voice and a drooling indistinct speech.

The patient had kyphosis of his cervical spine, pes planus of his feet, and valgus deformities of his ankles. Also noted was a tendon contracture of his left Achilles heel. He had diffuse muscular hypertrophy and stiffness but generalized myotonia was not evident. Strength testing revealed grade 5 muscle power (normal) throughout. Reflexes were difficult to elicit, especially in the lower extremities. He had a crouching stance and a stiff gait. When he walked, he would circumduct his right leg. Examination of his genitalia revealed small testes. His mental development was mildly delayed.

Skeletal survey showed kyphoscoliosis, bowing of long bones and abnormal capital femoral epiphyses. His blood differential and chemistry were normal, with the exception of creatine kinase, which was elevated at 896 I/U. The electromyogram showed occasional myotonic discharges. The muscle biopsy was unremarkable. The clinical diagnosis was SJS and the molecular analysis confirmed compound heterozygosity with different splice-site mutations in the two *Perlecan* alleles. These mutations result in significant reduction in the production of the wild-type (normal) protein encoded by *Perlecan* (figure 2).

The patient was placed on carbamazepine (Tegretol XR) 600 mg manè and 700 mg noctè for muscle stiffness and referred for physical therapy. His generalized muscle stiff-

ness showed symptomatic alleviation with carbamazepine treatment. His family was cautioned regarding life-threatening complications that may arise during anesthesia. Apart from neuromuscular assessments, he was also managed by routine evaluations in the orthopedic, ophthalmologic, and pediatric clinics.

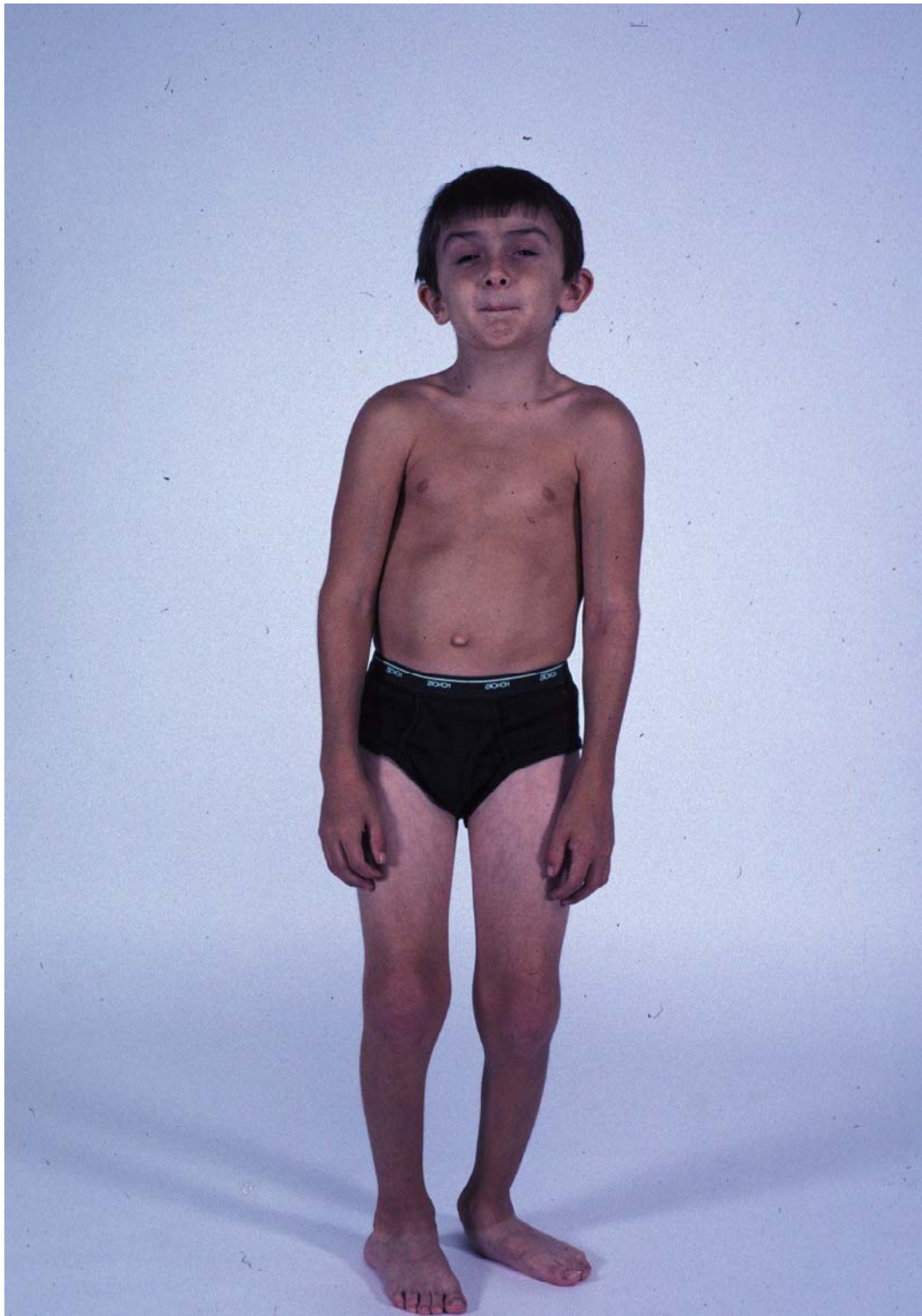## Discussion

Chondrodystrophic myotonia or Schwartz-Jampel syndrome (SJS) is a rare skeletal dysplasia often associated with clinical or electrophysiologic signs of myotonia. It may be progressive in nature. To date, there had been several reports on Middle Eastern families and South African kindreds, the prevalence of which may be accounted for by parental consanguinity in these regions. [5] The characteristic features include myotonia with a fixed or frozen facial expression, pursed lips, and a small mouth. The ocular manifestations are blepharophimosis, myopia and medial displacement of outer canthi. Patients have a waddling gait and frequently adopt a crouched stance because of joint stiffness. The skeletal findings are short stature, pectus carinatum, kyphoscoliosis, platyspondyly with coronal clefts in the vertebrae, metaphyseal and epiphyseal dysplasias, and joint contractures. Respiratory and feeding difficulties may occur shortly after birth. Mild mental retardation, which may be intrinsic to the syndrome or a result of the severity of physical limitations, has been said to be present in about 25% of cases. Muscle hypertrophy is evident in most patients. Malignant hyperthermia during anesthesia is a potentially lethal hazard. [5] In the prenatal period, polyhydramnios and absence of a stomach bubble, both indicative of a swallowing disorder, may be noted. [6] Contractures or short femurs may also be found on ultrasound. [6]

There is considerable clinical heterogeneity in the SJS phenotype. Giedion et al. (1997) proposed a useful clinicoradiological classification, characterizing the SJS phenotype into type 1A, which is associated with moderate bone dysplasia and is cognizant in childhood; type 1B, which shows more severe bone dysplasia and is recognizable at birth; and type 2, which has marked bowing of long bones and is manifested at birth. While types 1A and 1B are caused by mutations in *Perlecan* at 1p36.1, type 2 shows no linkage to the SJS locus on chromosome 1. [7] Type 2 is now identified as Stüve-Wiedemann syndrome, a genetically distinct, and highly lethal disorder. [4]

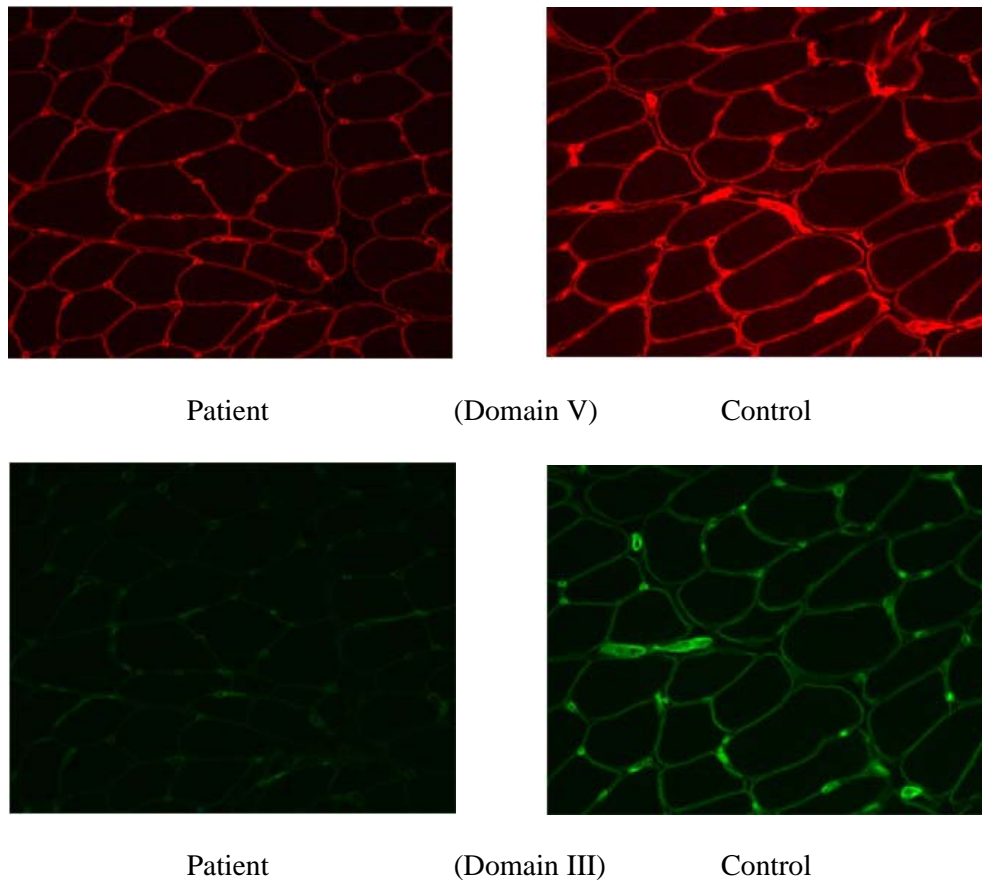
Creatine kinase and other muscle enzymes may be mildly or moderately elevated. [2,5] The electromyography shows persistent spontaneous activity that wanes at rest. Muscle biopsies show no distinguishable findings. [5]

*Perlecan* mutations characterized thus far in patients with SJS were missense mutations, splicing mutations with



**Figure 1**

The patient has blepharophimosis, pursed lips, low-set ears, and stiffness of facial expression. Note the bowing of the tibiae, valgus deformities of the ankles, and pes planus. Also note the muscle hypertrophy and mild chest deformity.

**Figure 2**

Immunostaining of perlecan with domain-specific anti-perlecan antibodies in muscle tissues from patient and from an unaffected control subject. Staining in muscle tissue of patient is significantly reduced.

exon skipping, and deletions.[3,4] In these patients, mutant Perlecan molecules or reduced amounts of wild-type Perlecan are secreted in the tissue matrix. Functional null mutations in the *Perlecan* were also found in individuals with dyssegmental dysplasia (Silverman-Handmaker type), a neonatal lethal skeletal dysplasia with exencephaly. Patients with this disorder demonstrated absence of Perlecan in the cartilage matrix. [8] It would seem that there is a spectrum of *Perlecan* disorders with SJS at the moderate severe area and the lethal Silverman-Handmaker syndrome at the most extreme end.

Muscle contraction is initiated at sites of nerve-muscle contact or neuromuscular junctions. Acetylcholinesterase degrades the neurotransmitter acetylcholine by hydrolyzing it at the synapse, thereby terminating neurotransmission. Peng et al. (1999) demonstrated that perlecan *in vitro* binds to acetylcholinesterase, and postulated that the perlecan-dystroglycan complex may function as an acceptor molecule for acetylcholinesterase at the neuromuscular junction. [9] Arikawa-Hirasawa et al. (2002) have shown that in perlecan-null mice, agrin and acetylcholine molecules were present at the neuromuscular junction but acetylcholinesterase was totally absent, indicating that

perlecan binds acetylcholinesterase and localizes it at the synapse. [10]

In our patient, the diminished amounts of normal perlecan found may result in reduced clustering of acetylcholinesterase at the neuromuscular junction. This culminates in a lower inhibition and therefore a higher concentration of acetylcholine, enhancing neuro-excitatory activity and probably generating myotonic discharges.

Currently, treatment for patients with SJS is primarily symptomatic, aimed at alleviating symptoms and preventing or managing complications. The management of contractures, bony deformities, and ambulatory issues will call for physical therapy, occupational therapy, orthopedic assessment and surgery. [2,5] Ophthalmologic correction of ptosis, myopia, and juvenile cataract, as well as repair of the narrowed palpebral fissures may be warranted to facilitate normal vision. [6] Elevation of the upper eyelid margin by levator aponeurosis surgery may improve facial appearance and self-image. Myotonia may respond to phenytoin, procainamide or carbamazepine. Treatment with carbamazepine, initiated in infancy, can produce marked resolution and continuous improvement of myotonia, blepharospasm and joint stiffness, resulting in lessening of the chest deformity and contractures. [11] The contractures are progressive until mid-adolescence but thereafter, usually become static. [5] The myotonia may improve spontaneously in later childhood.

Individuals with SJS should be cautioned regarding life-threatening complications that may arise during anesthesia. Micrognathia and jaw muscle rigidity may pose mechanical difficulties during intubation. Higher doses of muscle relaxants such as rocuronium may be required to facilitate tracheal intubation, probably because of the lowered degradation rate of acetylcholine. [12] Malignant hyperthermia during anesthesia is a potentially lethal complication. In view of the autosomal recessive mode of inheritance of this disorder, genetic counseling may be appropriate as the risk of recurrence is 25% or 1 in 4.

### Authors' contributions

NCH conceived of the study, carried out the clinical and participated in the molecular research and designed the study. SS and VM participated in research and design of the manuscript. CAF participated in the design and coordination and MCD participated in the clinical and molecular research and design of the study.

### Competing interests

None declared.

### List of abbreviations used

SJS - Schwartz-Jampel syndrome

### Acknowledgements

We gratefully acknowledge the family for their participation and their consent for the photographs to be used. We thank Drs. Arikawa-Hirasawa and Yamada for their assistance.

### References

- Schwartz O and Jampel RS: **Congenital blepharophimosis associated with a unique generalized myopathy** *Arch Ophthalmol* 1962, **68**:52-57.
- Pascuzzi RM: **Schwartz-Jampel Syndrome** *Semin Neurol* 1991, **11**:267-273.
- Nicole S, Davoine C-S, Topaloglu H, Cattolico L, Barral D, Beighton P, Ben Hamida C, Hammouda H, Cruaud C, White PS, Samson D, Urtizberea JA, Lehmann-Horn F, Weissenbach J, Hentati F and Fontaine B: **Perlecan, the major proteoglycan of basement membranes, is altered in patients with Schwartz-Jampel syndrome (chondrodystrophic myotonia)** *Nat Genet* 2000, **26**:480-483.
- Arikawa-Hirasawa E, Le AH, Nishino I, Nonaka I, Ho NC, Francomano CA, Govindraj P, Hassell JR, Devaney JM, Spranger J, Stevenson RE, Iannaccone S, Dalakas MC and Yamada Y: **Structural and functional mutations of the perlecan gene cause Schwartz-Jampel syndrome, with myotonic myopathy and chondrodysplasia** *Am J Hum Genet* 2002, **70**:1368-1375.
- Viljoen D and Beighton P: **Schwartz-Jampel syndrome (chondrodystrophic myotonia)** *J Med Genet* 1992, **29**:58-62.
- Farrell SA, Davidson RG and Thorp P: **Neonatal manifestations of Schwartz-Jampel syndrome** *Am J Med Genet* 1987, **27**:799-805.
- Giedion A, Boltshauser E, Briner J, Eich G, Exner G, Fendel H, Kaufmann L, Steinmann B, Spranger J and Superti-Furga A: **Heterogeneity in Schwartz-Jampel chondrodystrophic myotonia** *Eur J Pediatr* 1997, **156**:214-223.
- Arikawa-Hirasawa E, Wilcox WR and Yamada Y: **Dysegmental dysplasia, Silverman-Handmaker type is caused by functional null mutations of the perlecan gene** *Nat Genet* 2001, **27**:431-434.
- Peng HB, Xie H, Rossi SG and Rotundo RL: **Acetylcholinesterase clustering at the neuromuscular junction involves perlecan and dystroglycan** *J Cell Biol* 1999, **145**:911-921.
- Arikawa-Hirasawa E, Rossi SG, Rotundo RL and Yamada Y: **Absence of acetylcholinesterase at the neuromuscular junctions of perlecan-null mice** *Nat Neurosci* 2002, **5**:119-123.
- Squires LA and Prangley J: **Neonatal diagnosis of Schwartz-Jampel syndrome with dramatic response to carbamazepine** *Ped Neurol* 1996, **15**:172-174.
- Eikermann M, Bredendiek M, Schaper J, Hovel M and Peters J: **Resistance to rocuronium in a child with Schwartz-Jampel syndrome type IB** *Neuropediatrics* 2002, **33**:43-46.

### Pre-publication history

The pre-publication history for this paper can be accessed here:

<http://www.biomedcentral.com/1471-2377/3/3/prepub>