

➤ **Case Report** ◀

# Infrarenal Abdominal Aortic Pseudoaneurysm: Is It a Real Emergency?

Mafalda Massara, MD, PhD,<sup>1</sup> Roberto Prunella, MD,<sup>1</sup> Pasquale Gerardi, MD,<sup>1</sup> Antonio Lillo, MD,<sup>1</sup> Giovanni De Caridi, MD, PhD,<sup>2</sup> Raffaele Serra, MD, PhD,<sup>3</sup> Stefano Notarstefano, MD,<sup>1</sup> and Giovanni Impedovo, MD<sup>1</sup>

Abdominal aortic pseudoaneurysm is a rare but life-threatening condition that occurs due to penetrating or blunt trauma. Clinical manifestations are variable, and the time interval from the initial trauma to diagnosis is variable. A prompt diagnosis and an aggressive management approach are required to avoid catastrophic complications. Possible treatment options are open surgical repair, endovascular repair, pseudoaneurysmal sac thrombosis induction through direct thrombin injection, and coil embolization. Here, we present the case of a 75-year-old man affected by an infrarenal abdominal aortic pseudoaneurysm presenting with abdominal and lumbar pain for 3 days, who was successfully treated with an endograft.

**Keywords:** abdominal aortic pseudoaneurysm, blunt trauma, endovascular repair

## Introduction

Traumatic pseudoaneurysms of the abdominal aorta are rare and generally occur as a consequence of penetrating trauma, or more rarely blunt trauma, the latter accounting for only 1% of all abdominal aneurysms.<sup>1)</sup> The clinical presentation can considerably vary, with abdominal, chest, or lumbar pain; signs of compression of adjacent structures, such as the inferior caval vein, the visceral arteries or a vertebral erosion; gastrointestinal bleeding; sometimes with the rupture of the aneurysm, potentially leading to the patient's death. Prompt diagnosis and treatment are essential to avoid catastrophic complications.

Here, we report the case of a 75-year-old man affected by an infrarenal abdominal aortic pseudoaneurysm (AAP), presenting with abdominal and lumbar pain for 3 days, who was successfully treated with an endograft.

<sup>1</sup> Vascular Surgery Unit, SS, Annunziata Hospital, Taranto, Italy

<sup>2</sup> Vascular Surgery Unit, University of Messina, Messina, Italy

<sup>3</sup> Department of Surgical and Medical Science, University Magna Graecia of Catanzaro, Catanzaro, Italy

Received: May 19, 2017; Accepted: June 20, 2017  
Corresponding author: Mafalda Massara, MD, PhD. Vascular Surgery Unit, SS, Annunziata Hospital, Via P. Galluppi n.12, 89021 Cinquefrondi (RC), Italy  
Tel: +39-347-986948, Fax: +39-099-4585253  
E-mail: drmafaldamassara@gmail.com

## Case Report

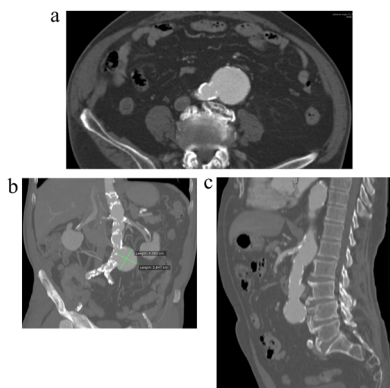
A 75-year-old man with a history of hypertension, dyslipidemia, smoke usage, chronic obstructive pulmonary disease, mild chronic renal failure (creatinine 1.78 mg/dl), and myocardial infarction was previously treated using percutaneous transluminal coronary angioplasty (PTCA), and was admitted to our Unit of Vascular Surgery. He complained of abdominal and lumbar pain for 3 days and was not responsive to medical therapy. He also reported a car accident 12 months before; however, the medical records for the hospitalization following the accident could not be obtained. Ultrasonography revealed a regular diameter of the abdominal aorta and the presence of a voluminous dilatation of the vessel on its left side below the renal arteries. His laboratory data were normal, without signs of infection.

An urgent computed tomography (CT) scan revealed the presence of a voluminous pseudoaneurysm (43×38 mm) arising from the left lateral wall of the infrarenal abdominal aorta, with a regular diameter of the aorta (antero-posterior (AP) diameter=18 mm), and diffused calcifications of the arterial wall (Figs. 1a and 1b). Another small pseudoaneurysm arising from the posterior aortic wall was also observed (Fig. 1c). No signs of active bleeding were present during the CT scan. The diameter of the proximal aortic neck was 18 mm; the diameter of the aortic bifurcation was 11 mm; the diameter of the iliac arteries was 5.6 mm on the right side and 6 mm on the left side in absence of tortuosity.

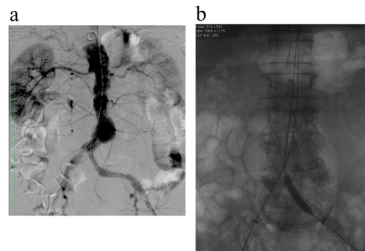
Our patient was considered to be at a high risk for undergoing open surgical repair because he presented with many comorbidities. Therefore, the surgeon opted for an endovascular treatment.

Under epidural anesthesia, the patient was submitted to the bilateral exposure of the common femoral arteries. Following the initial angiography, a predilatation of the left common iliac artery, which appeared larger than that of the right iliac artery at the CT scan, was essential before endoprosthesis deployment (Figs. 2a and 2b). Through the left side, an aortomoniliac endoprosthesis (23×140 mm) (Medtronic, Minneapolis, MN, USA) was deployed under the renal arteries; on the other side, a plug (16 mm) was positioned to occlude the right common iliac artery and to avoid

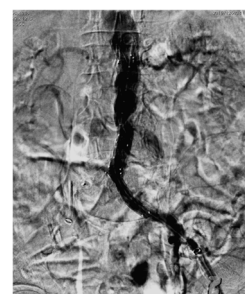




**Fig. 1** Preoperative CT scan showing a voluminous infrarenal abdominal aortic pseudoaneurysm in axial (a) and sagittal (b) plane (43x38mm) and a small pseudoaneurysm of the posterior abdominal aortic wall (c) in the lateral plane.



**Fig. 2** Intraoperative angiography showing the aortic pseudoaneurysm (a) and the left common iliac artery predilatation (b).



**Fig. 3** Final angiographic control showing aortomonoiliac endoprosthesis deployment with complete pseudoaneurysm exclusion, plug in the right common iliac artery, and absence of endoleak.

endoleaks. Intraoperative aortography revealed the regular deployment of the endograft and the complete exclusion of the two pseudoaneurysms, with no signs of endoleaks (Fig. 3). The surgery was completed through a femoro-femoral prosthetic bypass from the left to the right side.

The postoperative period was uneventful, and the patient was discharged on the fifth postoperative day on antiplatelet therapy. Our patient with mild chronic renal failure was followed-up by performing abdominal eco-color-duplex exams at 1, 3, 6, and 12 months.

## Discussion

AAP is a rare and severe complication of aortic injuries, occurring after a penetrating trauma or, more rarely, a blunt trauma, generally following traffic accidents.<sup>2)</sup>

The etiologic factors for AAP are infection, chronic inflammation, and trauma. Each of these factors causes the disruption in the arterial wall continuity. Sustained by arterial pressure, the blood dissects into the tissues surrounding the damaged vessel and forms a perfused sac that communicates with the arterial lumen. While in true aneurysms, all three layers of the arterial wall are intact, the AAP lacks a complete arterial wall and is generally contained by the media or adventitia.

Even though an AAP formation initially functions as a natural tamponade, thus saving the patient's life, AAPs are prone to symptoms and rupture at the later stage. The theoretical possibility of free rupture and the absence of natural history data demand an aggressive management approach.<sup>3)</sup>

In the current literature, the time interval from initial trauma to diagnosis of an AAP is extremely variable, ranging from days to years. The reason underlying this remains unknown; however, it can be hypothesized that high-velocity penetrating injuries, where a high force is applied to the tissue, can cause a

subclinical focal area injury of a vessel wall, which manifests at a later stage when healing by fibrosis occurs.

The clinical presentation can be variable and includes abdominal, back, or chest pain; presence of a palpable mass; visceral artery compression; upper gastrointestinal bleeding; inferior caval vein compression; and the acute occlusion of the abdominal aorta due to compression. The rupture of the AAP can also occur; spontaneous rupture has very high mortality rates.<sup>3)</sup>

Possible treatment options are open surgical repair, endovascular repair, pseudoaneurysmal sac thrombosis induction through direct thrombin injection,<sup>4)</sup> and coil embolization.<sup>5)</sup>

Open surgical repair consists of pseudoaneurysm resection and graft interposition<sup>4)</sup> or AAP resection and aortic repair through a lateral Dacron patch aortoplasty, as described by Pisters et al. in a child.<sup>6)</sup>

In 1997, Chase et al.<sup>1)</sup> have reported a case presenting with a traumatic pseudoaneurysm of the suprarenal abdominal aorta, epigastric pain, and obstructive jaundice. The patient was submitted to intraluminal patch aortoplasty with the resolution of the biliary obstruction.

Endovascular repair for the treatment of AAP has been reported through the application of stent grafts in two case reports and with a balloon-expandable bifurcated endoprosthesis in other cases.<sup>7-10)</sup>

In 1998, Bechara-Zamudio et al.<sup>8)</sup> have reported the case of a 22-year-old man presenting with upper gastrointestinal bleeding and massive intra-abdominal hemorrhage, with aortic and multiple intestinal perforations. He was submitted to aortic injury direct repair and multiple intestinal resections. The AAP, diagnosed through a CT scan, was resolved, recurring to a balloon-expandable bifurcated endoprosthesis.

Hinchliffe et al.<sup>9)</sup> have reported a case of ruptured AAP secondary to pancreatitis, which was successfully treated using an aortomonoiliac endograft. It allowed hemor-

rhage control in a potentially infected operative field, followed by elective pancreatic resection 6 months later.

More recently, Oner et al.<sup>10)</sup> have reported a case of post-traumatic AAP 8 months after being stabbed in the back and right flank. The pseudoaneurysm was close to the iliac bifurcation; the authors decided to deploy a bifurcated endovascular graft stent, the TriVascular Ovation endovascular stent and successfully resolved the case.

Few cases of alternative treatments different from open surgical repair or endovascular repair are reported in the literature.<sup>4,5)</sup>

Geckeis et al.<sup>4)</sup> have treated a 63-year-old man, who developed a large pseudoaneurysm in the abdominal aorta following surgical fenestration and patch aortoplasty for acute type B aortic dissection, with malperfusion syndrome. A transcatheter delivery of 1,500 thrombin units resulted in a complete thrombosis of the pseudoaneurysm sac.

Salsamendi et al.<sup>5)</sup> have resorted to endovascular coil embolization of a posterior aortic AAP, arising just superior to the origin of the renal arteries, and of a smaller broad-based right lateral juxta superior mesenteric artery AAP. In this case, the endovascular coil embolization was considered a good alternative approach for an AAP that cannot be treated by stent grafting or open surgical repair.

Our patient presented with sudden abdominal and lumbar pain by 3 days, which was non responsive to medical therapy. An urgent CT scan revealed a voluminous AAP and a small posterior AAP. The patient reported of having met a car accident 12 months before.

He was at a high risk for undergoing open surgical repair owing to his comorbidities; therefore, we opted for an endovascular treatment. The anatomic characteristics of the aorta, in particular, the small diameter of the aortic bifurcation (11mm), led the surgeon to opt for an aortomonoiliac stent graft accompanied by a femoro-femoral crossover bypass. The patient showed a complete resolution of his pathology.

Another endovascular option in the presence of a small diameter of the aortic carrefour is an AFX stent graft; however, this was excluded because the diameter of the iliac axis was very small, particularly on the right side.

Furthermore, embolization through coils was excluded since the CT scan revealed the presence of two AAPs, and the main AAP had a large diameter.

## Conclusion

AAP is a rare but severe disease, accompanied by variable clinical manifestations and symptoms. Patients with an incidental discovery of AAP and the absence of related symptoms can be submitted to strict follow-up. However, in presence of a large diameter of the AAP, with a consequent high risk of rupture and high mortality rate, or in the presence of a sudden appearance of abdominal or back acute

pain, the AAP should be considered as a genuine emergency.

In these cases an aggressive management approach is often required to avoid catastrophic complications.

## Disclosure Statement

The authors have no conflicts of interest.

## Author Contributions

Study conception: MM, SN, GI

Data collection: MM, RP, AL, RS

Analysis: MM, GD, RP, RS

Investigation: MM, PG

Writing: MM

Funding acquisition: none

Critical review and revision: all authors

Final approval of the article: all authors

Accountability for all aspects of the work: all authors

## References

- 1) Chase CW, Layman TS, Barker DE, et al. Traumatic abdominal aortic pseudoaneurysm causing biliary obstruction: a case report and review of the literature. *J Vasc Surg* 1997; **25**: 936-40.
- 2) Ishii H, Nakamura K, Nakamura E, et al. Aortic pseudoaneurysm due to simple vertebral compression fracture treated with conservative management. *Ann Vasc Dis* 2016; **9**: 349-51.
- 3) Li X, Zhao JC, Huang B, et al. Management of giant post-traumatic abdominal aortic pseudoaneurysm and aortic occlusion using a unique hybrid procedure combining transcatheter device closure and open surgical repair. *Ann Vasc Surg* 2014; **28**: 1322.e7-11.
- 4) Geckeis K, Eggebrecht H, Schmermund A, et al. Percutaneous repair of abdominal aortic pseudoaneurysm by catheter-based delivery of thrombin. *J Endovasc Ther* 2006; **13**: 264-8.
- 5) Salsamendi J, Pereira K, Rey J, et al. Endovascular coil embolization in the treatment of a rare case of post-traumatic abdominal aortic pseudoaneurysm: brief report and review of literature. *Ann Vasc Surg* 2016; **30**: 310.e1-8.
- 6) Pisters PW, Heslin MJ, Riles TS. Abdominal aortic pseudoaneurysm after blunt trauma. *J Vasc Surg* 1993; **18**: 307-9.
- 7) Ghazala CG, Green BR, Williams R, et al. Endovascular management of a penetrating abdominal aortic injury. *Ann Vasc Surg* 2014; **28**: 1790.e9-11.
- 8) Bechara-Zamudio L, Olive G, Barone H, et al. Traumatic abdominal aortic pseudoaneurysm treated with balloon-expandable bifurcated endoprosthesis. *J Vasc Surg* 1998; **28**: 345-8.
- 9) Hinchliffe RJ, Yung M, Hopkinson BR. Endovascular exclusion of a ruptured pseudoaneurysm of the infrarenal abdominal aorta secondary to pancreatitis. *J Endovasc Ther* 2002; **9**: 590-2.
- 10) Oner E, Erkanli K, Akturk IF, et al. Posttraumatic infrarenal abdominal aortic pseudoaneurysm treated with bifurcated endovascular graft stent. *Postepy Kardiol Interwencyjne* 2015; **11**: 146-9.