



REVIEW ARTICLE

**Forestier's disease and its implications in otolaryngology:
literature review** ☆, ☆☆

Janaina Oliveira Bentivi Pulcherio*, Cláudia Márcia Malafaia de Oliveira Velasco,
Rosane Siciliano Machado, Wallace Nascimento de Souza, Daniella Rossi de Menezes

Hospital Central da Polícia Militar do Estado do Rio de Janeiro, Rio de Janeiro, RJ, Brazil

Recebido em 12 de abril de 2013; aceito em 22 de setembro de 2013

KEYWORDS

Diffuse idiopathic skeletal hyperostosis;
Spine;
Spinal osteophytosis;
Deglutition disorders;
Otolaryngology

Abstract

Introduction: Forestier's disease affects the spinal column of primarily elderly men. It is not rare, but it is often undiagnosed and can lead to significant morbidity and mortality. When it affects the cervical spine, it can result in important otorhinolaryngological manifestations.

Objective: To analyze the pharyngeal and laryngeal symptoms of the Forestier's disease.

Methods: Literature review of the Web of Knowledge, PubMed, and SciELO databases and of the ten most frequently cited journals in the field of otorhinolaryngology. Additionally, a manual search was performed for publications in the reference lists of selected articles, mostly those of a historical nature.

Results: The etiology of the disease is still unclear. Symptoms of complications are more significant than the disease itself. Dysphagia is the most common cervical symptom and has several involved mechanisms. Other symptoms are sleep apnea, pharyngeal globus, coughing, dysphonia, dyspnea, otalgia, and medullary compression. The diagnosis is verified by appropriate radiological study. Treatment is based on a conservative strategy. Patients with refractory dysphagia and respiratory impairment can be surgically treated.

Conclusion: Forestier's disease should be suspected in elderly patients with the major symptoms of complications, which are common in otorhinolaryngology practice and when identified, a multidisciplinary approach should be instituted as soon as possible.

© 2014 Associação Brasileira de Otorrinolaringologia e Cirurgia Cérvico-Facial. Published by Elsevier Editora Ltda. All rights reserved.

PALAVRAS-CHAVE

Hiperostose esquelética difusa idiopática;
Coluna vertebral;
Osteofitose vertebral;
Transtornos de

Doença de Forestier e suas implicações otorrinolaringológicas: revisão de literatura

Resumo

Introdução: A Doença de Forestier afeta a coluna vertebral, preferencialmente em homens idosos. Não é rara, mas é frequentemente não reconhecida e pode levar a relevante morbimortalidade. Quando acomete a coluna cervical, pode gerar importantes manifestações otorrinolaringológicas.

Objetivo: Destacar os sintomas faringolaringeos da doença de Forestier.

☆Please cite this article as: Pulcherio JOB, Velasco CMMO, Machado RS, Souza WN, Menezes DR. Forestier's disease and its implications in otolaryngology: literature review. Braz J Otorhinolaryngol. 2014;80:161-6.

☆☆Study conducted at Hospital Central da Polícia Militar do Estado do Rio de Janeiro, Rio de Janeiro, RJ, Brazil.

* Corresponding author.

E-mail: janabentivi.ork@gmail.com (J.O.B. Pulcherio).

deglutição;
Otolaringologia

Método: Revisão da literatura nas bases de dados Web of Knowledge, PubMed e SciELO e entre os dez periódicos de maior número de citações na área de otorrinolaringologia e também busca manual por publicações nas listas de referências dos artigos selecionados, principalmente os de cunho histórico.

Resultados: A doença não tem etiologia clara. Os sintomas das complicações são mais exuberantes que os da doença propriamente dita. A disfagia é o sintoma cervical mais conhecido. Outros sintomas discutidos são a apneia do sono, globus faríngeo, tosse, disфония, dispneia, otalgia reflexa e sintomas medulares compressivos. O diagnóstico é efetuado com apropriado estudo radiológico. O tratamento é baseado em estratégia conservadora. Pacientes com disfagia refratária e comprometimento respiratório podem ser submetidos a tratamento cirúrgico.

Conclusão: A doença de Forestier deve ser suspeitada em pacientes idosos com os principais sintomas das complicações, os quais são comuns na prática otorrinolaringológica, para o início precoce de acompanhamento multidisciplinar.

© 2014 Associação Brasileira de Otorrinolaringologia e Cirurgia Cérvico-Facial. Publicado por Elsevier Editora Ltda. Todos os direitos reservados.

Introduction

Forestier's disease was first described by Forestier and Routhes-Querol in 1950.¹ In 1975, the acronym DISH (diffuse idiopathic skeletal hyperostosis) was introduced as a descriptive name for the disease.²

The criteria necessary for the diagnosis were identified by Resnick and Niwayama, and consist of: (1) calcification and ossification along the anterolateral paravertebral ligaments, contiguously involving at least four vertebral bodies with or without specific bony outgrowths projecting into the intervertebral spaces; (2) relative preservation of intervertebral disc height in the involved areas without signs of degeneration; and (3) absence of apophyseal ankylosis or erosion/sclerosis/sacroiliac fusion.³ Typically, osteophytes are identified in the anterior and lateral regions of the vertebral bodies.⁴

The first descriptions of the disease documented that the thoracic spine is most frequently affected, followed by the lumbar and cervical spines.¹⁻³ The disease mainly affects the right side of the thoracic spine, probably due to aortic pulsation delaying the calcification process.^{5,6}

It is a noninflammatory disease and mainly affects elderly men.¹ Although Forestier's disease is not rare, it is often undiagnosed.^{7,8} In the United States, it is estimated that its prevalence is 25% of men and 15% of women older than 50 years and 35% of men and 26% of women older than 80 years, showing a proportional increase with age according to the MrOS study.⁹

Forestier's disease or DISH is usually asymptomatic and therefore latent.^{1,5} However, it can lead to significant morbimortality.⁵ Osteophytes may develop and lead to extrinsic compression of local tissues. In the cervical region, it can generate otorhinolaryngological manifestations such as dysphagia, pharyngeal globus, dysphonia, and stridor.¹⁰

Dysphagia is the most frequently reported symptom among the complications of Forestier's disease and can occur in up to 28% of cases, and be directly related to the presence of cervical osteophytes.^{5,10} This symptom is usually progressive and more severe for solids than for liquids. Osteophytes originating from the level of the fifth and sixth

cervical vertebrae (C5 and C6) are most commonly implicated in causing dysphagia, followed by those from the C4 and C5 level.¹¹

Other symptoms have been described, such as cough, sore throat, foreign body sensation in the pharynx, and sleep apnea.^{4,10}

Due to the expected high prevalence, low diagnosis rates, and the frequent association of the disease with pharyngolaryngeal symptoms, this literature review aimed to emphasize the aspects pertaining to otorhinolaryngological practice.

Objective

To highlight the pharyngolaryngeal symptoms of Forestier's disease and alert otolaryngologists to the importance of confirmed diagnosis, early treatment, and prevention of severe complications of the disease based on descriptions in the literature.

Methods

The databases of Web of Knowledge, PubMed, and SciELO were searched in order to retrieve articles published between the years 1992-2012, in English or Portuguese, that contained the keywords "Forestier" and "hyperostosis"

The Web of Knowledge yielded 69 articles; PubMed, 41; and SciELO, 34 articles. Articles with no abstracts available for review, those considered irrelevant for the proposed subject of this study, and those written in other languages rather than English were excluded. Twenty-nine articles were selected from the first database, eight articles from the second, and no articles from the third one. Since four articles were common to the first two databases, a total of 33 articles were selected for this first stage of research.

Then, using the same inclusion criteria, a literature search was performed in the ten journals with the highest number of citations in the field of otolaryngology in 2011, according to the Journal Citation Reports®, contained in the

Web of Knowledge. This search yielded four additional references.

In the third phase, articles found through a manual search in the reference lists of the selected articles were added if considered relevant, especially those of historical nature, even if they were published before 1992.

Results

Cervical osteophytes are common findings in elderly patients, occurring in approximately one-third of individuals older than 60 years, and usually remain asymptomatic.^{12,13} The prevalence of Forestier's disease, however, is lower. Numbers vary according to the reference, ranging between 10% and 35% of male patients older than 70 years,¹⁴ with apparent propensity for Caucasians.¹⁵

The etiology of DISH remains unclear.^{1,15,16} Initially, trauma was suggested as the precipitating factor, although not present in all cases.⁵ The following were indicated as risk factors: excessive mechanical stress with or without obesity, dyslipidemia, hyperuricemia, hypertension, cardiovascular disease, hypervitaminosis A, prolonged therapy with isotretinoin, increased serum levels of insulin with or without diabetes mellitus, and other metabolic conditions concomitant with increased insulin-like growth factor type 1 or growth hormone that could stimulate osteoblast activity.^{4,15-19}

Some studies have shown familial association, with the presence of several leukocyte antigens related to this disease, as well as involvement of genes responsible for collagen synthesis.^{15,16,18} Possible vascular disorder as an etiology of the disease has been the subject of research.¹⁸

Although this disease affects the spine, few studies have assessed the association between DISH and back pain. Symptoms of the disease itself, when present, are stiffness of the spine, particularly in the thoracic region. These symptoms cause moderate discomfort, but are usually well tolerated by patients. Pain, when present, is primarily located in the cervical spine. Morning stiffness has also been described. Surprisingly, the MrOS study, comprising 298 patients, demonstrated that patients with DISH had lower prevalence of low back pain when compared with the control group, suggesting that the disease increased column "stability".⁹

Peripheral joints may also be affected in patients with DISH. The most frequently involved are the metacarpophalangeal joints, with findings of thickening/calcification of ligaments and enthesopathy.¹⁶

Symptoms of complications are more severe than those of the disease itself.⁴ Dysphagia is the best-known cervical symptom, occurring in approximately one-third of patients.^{12,17} Of these, there is worsening of symptoms with cervical extension and improvement with flexion in 14% to 16%.¹⁶

In some cases, there is no correlation between the size of osteophytes and severity of dysphagia, and this may correspond to the presence of underlying presbyphagia, contributing to this symptom. Other factors probably involved in these patients are disorders of mucosal sensitivity and changes in laryngeal mobility.^{4,5,20} It should be emphasized that dysphagia due to cervical involvement of DISH is a rare entity.

The mechanisms for dysphagia in DISH suggested in the literature include: 1) incomplete protection of the lower airways due to restricted epiglottis mobility; 2) incomplete glottal closure due to restricted vocal fold mobility; 3) restriction of the movement of elevation and anterior displacement of larynx; 4) neuropathy due to impairment of the recurrent laryngeal nerve; 5) mechanical obstruction of food bolus transportation in the posterior wall of the hypopharynx or esophagus; 6) inflammation and fibrosis of the esophageal wall secondary to irritation by osteophytes; and 7) periesophageal spasm due to pain.^{4,6,11-13,19,21} Fig. 1 shows a laryngoscopy image in a patient with Forestier's disease and complaint of dysphagia.

The first report of the association between DISH and sleep apnea was made by Hughes et al. in 1994.^{20,22} This symptom is uncommon, but it also was reported by Kawachi in a 75-year-old patient as the single complaint of the disease.¹⁹ Conversely, Ando et al. did not find such an association.²³

Patients may rarely have dyspnea, or even the need for an emergency airway.^{5,7,24} Dyspnea can be explained not only by the mechanical obstruction in the airways, but also by retrocricoid inflammation generated by osteophytes, which leads to reduction in glottal mobility. This mechanism also explains the presence of dysphonia and stridor.^{4,7,20,24,25} Osteophytes at the level of C2 and C3 vertebrae can generate higher risk for airway impairment in Forestier's disease.²⁶ There is also a report of difficult intubation in a patient with DISH²⁷ and cases of aspiration pneumonia.^{28,29}

Reflex otalgia can occur by reflex stimulation of the pharyngeal plexus through the glossopharyngeal and vagus nerves.^{5,10} Medullary compression symptoms occur when there is extension of calcification into the medullary canal or ossification of the posterior longitudinal ligament.^{5,30}

Maseiro et al. have suggested a classification for the degree of posterior pharyngeal wall compression.³¹ Compression is considered slight when the pharyngeal lumen reduction is less than 30%; moderate, when the reduction is between 30% and 50%; and severe when the reduction exceeds 50%.

The diagnosis of DISH cannot be established without adequate radiological evaluation. In many cases, the rationale for DISH is difficult, as there are generally pre-exis-

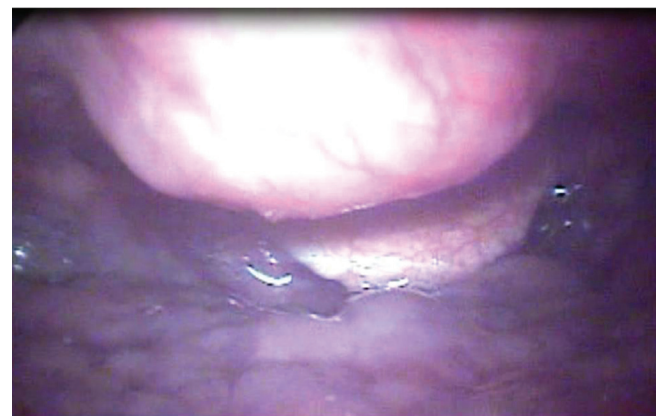

Figure 1 Video laryngoscopy image of a patient with Forestier's disease, showing submucosal bulging in hypopharynx, corresponding to prominent cervical osteophytes.

ting osteoarticular alterations in these elderly patients, to which hyperostosis is added.^{1,5} Although plain radiography of the spinal column (Figs. 2 and 3) sometimes is sufficient to identify diagnostic parameters, computed tomography (CT) and magnetic resonance imaging (MRI) of the spine are also useful and provide additional information, such as assessment of affected soft tissue and intramedullary involvement (Fig. 4).^{20,32}

With these modalities, the criteria established by Resnick and Niwayama must be utilized.³ In the cervical and lumbar regions, ligament ossification presents more discrete foci, in the form of early spurs whereas in the thoracic spine, the pattern is more linear or laminated.² Cervical changes are most common between C4 and C7 vertebrae. The bony outgrowths usually range from 1 to 2 mm, but can reach 30 mm. Over time, these bony growths gradually lengthen and extend, crossing the intervertebral space. They are most commonly observed at the lower margin of the vertebral bodies and grow inferiorly.^{2,5}

The differential diagnosis of DISH must include ankylosing spondylitis and spondylosis deformans, degenerative diseases of the intervertebral discs, and osteoarthritis.³ Acromegaly, fluorosis, pachydermoperiostosis, and hypertrophic

osteoarthropathy can mimic the symptoms and radiological signs of DISH, and are less common causes that should also be ruled out.^{3,5}

The differential diagnosis of patients with DISH and dysphagia is more extensive. the possibility of a malignancy should not be overlooked, even if there is radiological evi-

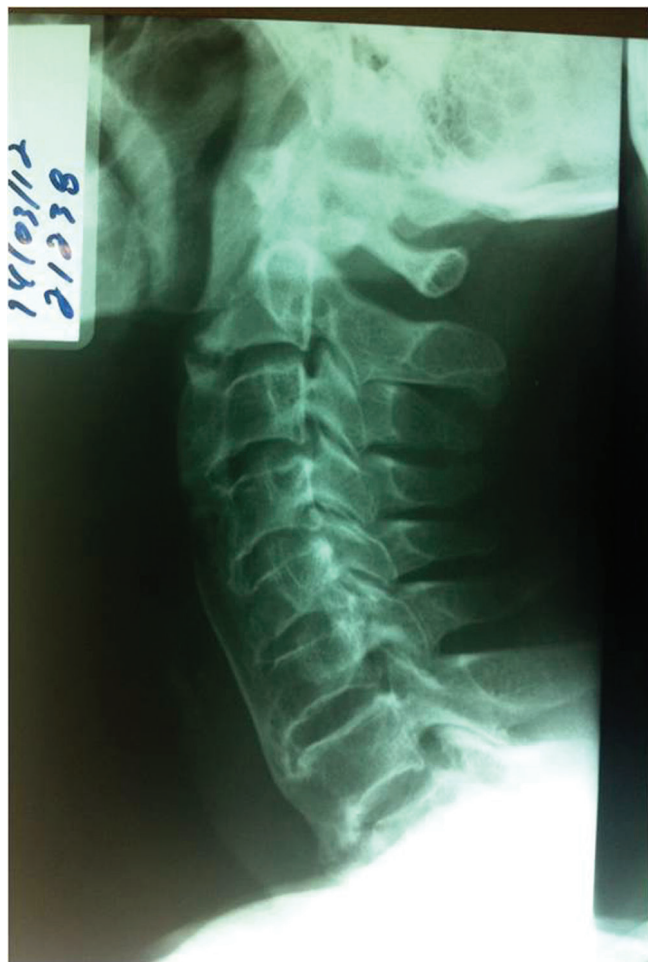

Figure 2 Plain profile X-ray of the cervical spine showing diffuse calcification in the anterior longitudinal ligament and calcification areas in the posterior longitudinal ligament.

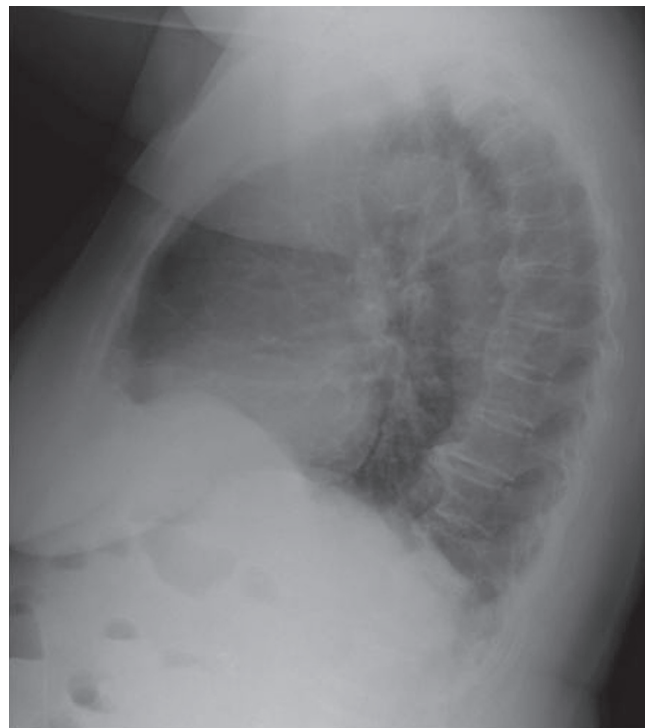


Figure 3 Profile chest X-ray showing diffuse calcification of the anterior longitudinal ligament with prominent formation of osteophytes in the thoracic spine.

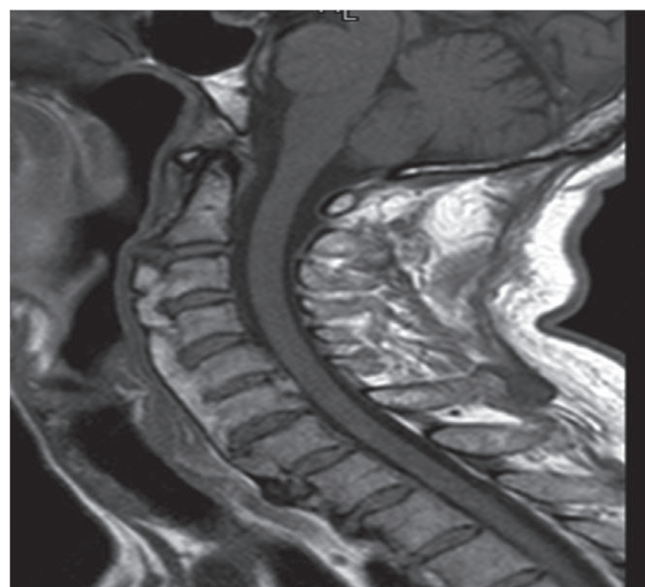


Figure 4 Magnetic resonance images of the cervical spine in T1 showing calcification of the anterior longitudinal ligament, with no involvement of nervous structures.

dence of osteophytes, especially if their small size does not seem to justify the symptoms.¹⁰ Tumors of the larynx, esophagus, lung, mediastinum, and spinal column should be investigated. Disorders of esophageal mobility, esophagitis, esophageal stricture, vascular abnormalities, Zenker's diverticulum, Plummer-Vinson syndrome, gastroesophageal reflux, globus hystericus, CVA, neurological disorders, dermatomyositis, and even isolated ventral cervical osteophytes are other causes of dysphagia that also should be investigated.^{4,10}

Elongation of the styloid process of the skull base or calcification of the stylohyoid ligament should be investigated in patients with complaints of dysphagia, throat pain, and foreign body sensation.^{5,33} Videofluoroscopy, upper digestive endoscopy, and deglutition videoendoscopy can be used in this differential diagnosis, in addition to the previously reported tests.^{13,32}

The treatment of DISH is based on a conservative multidisciplinary approach, with physical therapy and physical activities. Patients with deglutition disorders are advised to undergo dietary changes and deglutition therapies.^{6,12}

Muscle relaxants and anti-inflammatory drugs are recommended in the literature for symptomatic patients, especially in the early stages of the disease.^{4,7,8,10} Most patients with DISH initially show good response to treatment.²¹ Antireflux therapies may be used for patients with laryngeal edema.^{12,20}

Acupuncture and chiropractic therapies are popular among patients. Possible benefits of these practices include an improvement of spinal movement and pain relief; however, there is little information about their efficacy.⁶ It is noteworthy that the manipulation/mobilization of the spinal column of patients with DISH, even if performed by trained professionals, can have severe consequences. Hartel et al.³⁴ reported the case of a 65-year-old patient that suffered a cervical spine fracture after a physical therapy session and developed tetraplegia.³⁵

In patients with dysphagia refractory to medical treatment or those who are not candidates for surgical treatment, other nutritional strategies include enteral support, a temporary option, and gastrostomy.^{10,20}

Tracheotomy is indicated in patients with respiratory failure or before surgical procedures, when the larynx cannot be visualized.^{20,24} A continuous positive airway pressure (CPAP) device is indicated for patients with obstructive sleep apnea due to exuberant osteophytes.¹⁹

The recommended surgical treatment for DISH is a simple osteophyte excision (osteophylectomy). The indications for surgical treatment in the cervical region are mainly after cervical trauma, dysphagia refractory to conservative treatment, and airway impairment.^{7,10,12,26,30}

Complete resection of osteophytes cannot always be achieved. However, partial resection, or even resection of only the largest osteophytes, may result in clinical improvement. Some authors suggest resection in the initial phase of clinical symptoms.¹¹ The cervical surgical approaches can be anterolateral, posterolateral, or transoral.^{10,12,26}

The anterolateral approach to the cervical spine provides rapid and good exposure to the great vessels and the vagus nerve. The risks are injury to the recurrent laryngeal nerve, cerebrovascular accident, Horner's syndrome, and cervical instability. Although both the right

and the left sides offer good exposure, the left side is more commonly used, due to the more medial course of the recurrent laryngeal nerve.^{5,6,10} This access is preferred for lesions affecting the lower level of the cervical spine (C3 to C7).^{15,26}

The posterolateral access provides good exposure to the prevertebral space, but requires more retraction of the carotid sheath, and offers greater risk of injury to the sympathetic chain. It can best be employed in the C3-C6 approach.^{20,26}

The transoral or transpharyngeal approach has an esthetic advantage, as well as lower risk of affecting the great vessels, and the vagus and recurrent laryngeal nerves, compared to other approaches. It may be indicated to provide access to high cervical column lesions (C1-C2). However, the authors point out the transoral disadvantages of a more limited surgical field and the potential risk of fascia infection and osteomyelitis due to field contamination. Furthermore, it has been suggested that there is greater scarring and adhesions, with reduced mobility of the posterior pharynx.^{10,15,20,26,36}

DISH patients with dysphagia are at increased risk of recurrence after surgical resection of osteophytes. Some authors suggest that these patients must be followed-up for at least ten years. In a prospective study of six to 13 years performed by Miyamoto et al., all patients had radiological recurrence of resected osteophytes. In case of symptom recurrence, further interventions may be required.³⁷

Conclusion

Forestier's disease or DISH is not a rare disease, but it is often undiagnosed. This diagnostic hypothesis should be considered in elderly patients presenting with dysphagia, dysphonia, sleep apnea, cough, pharyngeal globus, or foreign body sensation in the throat, which are common symptoms in otolaryngology practice. The suspicion must lead to an investigation, which may begin with the simple, low-cost and widely available radiological examination, radiography of the cervical spine. Early diagnosis is important for the initiation of a multidisciplinary approach that will improve the patient's quality of life.

Conflicts of interest

The authors declare no conflicts of interest.

References

1. Forestier J, Rotes-Querol J. Senile ankylosing hyperostosis of the spine. *Ann Rheum Dis*. 1950;9:321-30.
2. Resnick D, Shaul SR, Robins JM. Diffuse idiopathic skeletal hyperostosis (DISH): Forestier's disease with extraespal manifestations. *Radiology*. 1975;115:513-24.
3. Resnick D, Niwayama G. Radiographic and pathologic features of spinal involvement in diffuse idiopathic skeletal hyperostosis (DISH). *Radiology*. 1976;119:559-68.
4. Seidler TO, Alvarez JC, Wonneberger K. Dysphagia caused by a ventral osteophytes of the cervical spine: clinical and radiographic findings. *Eur Arch Otorhinolaryngol*. 2009;266:285-91.

5. Ebo DG, Uytterhaegen PJ, Lagae PL, Mijnsbrugge AMV, Goffi J. Choking, sore throat with referred otalgia and dysphagia in a patient with diffuse idiopathic skeletal hyperostosis (DISH). *Acta Clin Belg.* 2005;60:98-101.
6. Goh PY, Dobson M, Iseli T, Maartens NF. Forestier's disease presenting with dysphagia and dysphonia. *J Clin Neurosc.* 2010;17:1336-8.
7. Marks B, Schober E, Swoboda H. Diffuse idiopathic skeletal hyperostosis causing obstructing laryngeal edema. *Eur Arch Otorhinolaryngol.* 1998;255:256-8.
8. Ozgocmen S, Kiris A, Kocakoc E, Ardicoglu O. Osteophyte-induced dysphagia: report of three cases. *Joint Bone Spine.* 2002;69:226-9.
9. Holton KF, Denard PJ, Yoo JU, Kado DM, Barrett-Connor E, Marshall LM. Diffuse idiopathic skeletal hyperostosis and its relation to back pain among older men: The MrOS Study. *Sem Arth Reum.* 2011;41:131-8.
10. Castellano DM, Sinacori JT, Karakla DW. Dysphagia in diffuse idiopathic skeletal hyperostosis (DISH). *Laryngoscope.* 2006;116:341-4.
11. Ido K, Hashitani M, Sakamoto A, Urushidani H. Surgical treatment for dysphagia caused by cervical hyperostosis: a report of three cases. *J Orthopaed Traumatol.* 2002;3:55-8.
12. Carlson ML, Archibald DJ, Graner DE, Kasperbauer JL. Surgical management of dysphagia and airway obstruction in patients with prominent ventral cervical osteophytes. *Dysphagia.* 2011;26:34-40.
13. Solaroglu I, Okutan O, Karakus M, Saygili B, Beskonakli E. Dysphagia due to diffuse idiopathic skeletal hyperostosis of the cervical spine. *Turkish Neurosurg.* 2008;18:409-11.
14. Presutti L, Alicandri-Ciufelli M, Piccinini A, Trebbi M, Marchioni D, Ghidini A, et al. Forestier disease: single-center surgical experience and brief literature review. *Ann Otol Rhinol Laryngol.* 2010;119:602-8.
15. Jeannon JP, Goldstein DP, Bachar G, Gentili F, Irish JC. Forestier disease causing dysphagia. *J Otolaryngol Head Neck Surg.* 2008;37:E11-4.
16. Akhtar S, O'Flynn PE, Kelly A, Valentine PMW. The management of dysphasia in skeletal hyperostosis. *J Laryngol Otol.* 2000;114:154-7.
17. Coaccioli S, Fatati G, Di Cato L, Marioli D, Patucchi E, Pizzuti C, et al. Diffuse idiopathic skeletal hyperostosis in diabetes mellitus, impaired glucose tolerance and obesity. *Panminerva Med.* 2000;42:247-51.
18. Sarzi-Puttini P, Atzeni F. New developments in our understanding of DISH (Diffuse Idiopathic Skeletal Hyperostosis). *Curr Opin Rheumatol.* 2004;16:287-92.
19. Kawachi E, Yamagata T, Tohda Y. A case of Forestier disease with obstructive sleep apnea syndrome. *Sleep Breath.* 2012;16:603-5.
20. Lecerf P, Malard O. How to diagnose and treat symptomatic anterior cervical osteophytes. *Eur Ann Otorhinolaryngol Head Neck Dis.* 2010;127:111-6.
21. Ho MP, Cheung WK, Tsang YM. Forestier's disease presenting as a retropharyngeal mass in an elderly with dysphagia. *Ann Acad Med Singapore.* 2010;39:943-4.
22. Hughes TAT, Wiles CM, Lawrie BW, Smith AP. Dysphagia and sleep apnoea associated with cervical osteophytes due to diffuse idiopathic skeletal hyperostosis (DISH). *J Neurol Neurosurg Psychiatr.* 1994;57:384.
23. Ando E, Ogawa T, Shigeta Y, Hirai S, Ikawa T, Ishikawa C, et al. A case of obstructive sleep apnoea with anterior cervical osteophytes. *J Oral Rehab.* 2009;36:776-80.
24. Karkas AA, Schmerber SA, Gay EP, Chahine KN, Righini CA. Respiratory distress and vocal cord immobilization caused by Forestier's disease. *Otolaryngol Head Neck Surg.* 2008;139:327-8.
25. Papakostas K, Thakar A, Nandapalan V, O'Sullivan G. An unusual case of stridor due to osteophytes of the cervical spine: (Forestier's disease). *J Laryngol Otol.* 1999;113:65-7.
26. Ozgursoy OB, Salassa JR, Reimer R, Wharen RE, Deen HG. Anterior cervical osteophyte dysphagia: manofluorographic and functional outcomes after surgery. *Head Neck.* 2010:588-93.
27. Palmer JHM, Ball DR. Awake tracheal intubation with the intubating laryngeal mask in a patient with diffuse idiopathic skeletal hyperostosis. *Anaesthesia.* 2000;55:70-8.
28. Masiero S, Ragona RM, Bottin R. An unusual cause of aspiration pneumonia. *Aging Clin Exp Res.* 2006;18:78-82.
29. Kos MP, Van Royen BJ, David EF, Mahieu HF. Anterior cervical osteophytes resulting in severe dysphagia and aspiration: two case reports and literature review. *J Laryngol Otol.* 2009;123:1169-73.
30. Mizuno J, Nakagawa H, Song J. Symptomatic ossification of the anterior longitudinal ligament with stenosis of the cervical spine - a report of seven cases. *J Bone Joint Surg.* 2005;87B:375-9.
31. Masiero S, Padoan E, Bazzi M. Dysphagia due to diffuse idiopathic skeletal hyperostosis: an analysis of five cases. *Rheumatol Int.* 2010;30:681-5.
32. Aydin E, Akdogan V, Akkuzu B, Kirbas I, Ozgirgin ON. Six cases of Forestier syndrome, a rare case of dysphagia. *Acta Otolaryngol.* 2006;126:775-8.
33. Karadag B, Cat H, Aksoy S, Ozulu B, Ozturk AO, Oguz S, et al. A geriatric patient with diffuse idiopathic skeletal hyperostosis. *World J Gastroenterol.* 2010;16:1673-5.
34. Sreedharan S, Li YH. Diffuse idiopathic skeletal hyperostosis with cervical spinal cord injury - a report of 3 cases and a literature review. *Ann Acad Med Singapore.* 2005;34:257-61.
35. Hartel MJ, Seidel U, Iselin L, Exadaktylos AK, Benneker LM. Partial tetraplegic syndrome as a complication of a mobilizing/manipulating procedure of the cervical spine in a man with Forestier's disease: a case report. *J Med Case Rep.* 2011;5:529.
36. Uppal S, Wheatley AH. Transpharyngeal approach for the treatment of dysphagia due to Forestier's disease. *J Laryngol Otol.* 1999;113:366-8.
37. Miyamoto K, Sugiyama S, Hosoe H, Iinuma N, Yasushi-Suzuki Y, Shimizu K. Postsurgical recurrence of osteophytes causing dysphagia in patients with diffuse idiopathic skeletal hyperostosis. *Eur Spine J.* 2009;18:1652-8.