

# Adjusting voltage criteria can unmask conducting channels in a patient with arrhythmogenic right ventricular cardiomyopathy and ventricular tachycardia



Prabhat Kumar, MBBS, J. Paul Mounsey, BMBCh, PhD, Eugene H. Chung, MD, FHRS

*From the Department of Medicine, Divisions of Cardiology and Cardiac Electrophysiology, University of North Carolina at Chapel Hill, Chapel Hill, North Carolina.*

## Introduction

Catheter ablation of ventricular tachycardia (VT) in patients with arrhythmogenic right ventricular cardiomyopathy (ARVC) is challenging.<sup>1–4</sup> A complex and predominantly epicardial substrate in the basal right ventricular free wall increases the risk of coronary injury during ablation.<sup>5</sup> The CARTO-UNIVU mapping system (Biosense Webster Inc, Diamond Bar, CA) permits detailed voltage mapping as well as overlaying of the 3-dimensional (3D) anatomic map on the coronary angiogram. We present an epicardial ablation case of a patient with ARVC in whom the CARTO-UNIVU system facilitated identification of the most critical targets for ablation and avoidance of coronary artery injury.

## Case report

A 67-year-old man had an episode of hemodynamically stable monomorphic VT requiring cardioversion and was diagnosed with ARVC. The 12-lead ECG recorded during that event is shown in [Figure 1A](#). He underwent dual-chamber implantable cardioverter-defibrillator implantation and was initiated on sotalol. Approximately 2.5 years later, he had an episode of VT with syncope while he was playing golf and received a shock from his implantable cardioverter-defibrillator. He was subsequently referred for electrophysiologic study and potential endocardial and epicardial catheter ablation.

**KEY WORDS** Arrhythmogenic right ventricular cardiomyopathy; Ventricular tachycardia; Epicardial; Substrate; Voltage; Three-dimensional mapping; CARTO-UNIVU mapping system

**ABBREVIATIONS** 3D = three-dimensional; ARVC = arrhythmogenic right ventricular cardiomyopathy; VT = ventricular tachycardia (*Heart Rhythm Case Reports* 2015;1:275–278)

Dr. Mounsey is a paid speaker and consultant to Boston Scientific and St. Jude Medical. Dr. Chung is a consultant to Biosense Webster Inc. **Address reprint requests and correspondence:** Dr. Eugene H. Chung, Division of Cardiology and Cardiac Electrophysiology, University of North Carolina at Chapel Hill, 160 Dental Circle, CB 7075, Chapel Hill, NC 27599. E-mail address: ehchung@med.unc.edu.

During the procedure, VT was induced with double ventricular extrastimuli from the right ventricular apex. The VT was hemodynamically unstable (cycle length 270 ms) but exactly matched the clinical VT recorded on the ECG from the first episode ([Figure 1A](#)). VT was terminated by synchronized direct current shock after failed overdrive pacing. The VT had a superior axis with positive QRS complexes in the lateral leads and negative complexes in the precordial leads ([Figure 1B](#)).

An endocardial 3D electroanatomic map during sinus rhythm was acquired using the Pentaray catheter and CARTO mapping system (Biosense Webster). The voltage map revealed a large scar (0.5–1.5 mV) in the inferior right ventricular free wall. Pace-mapping produced QRS morphologies moderately similar (9/12 match) to the VT. Multiple radiofrequency ablation lesions were placed with the ThermoCool SmartTouch ablation catheter (Biosense Webster) to transect the scar. Multiple areas of fractionated activity within the scarred area also were targeted. At this point, a slower (320 ms) and morphologically similar VT could be induced with double ventricular extrastimuli.

Pericardial access was obtained, and the ablation catheter was advanced into the pericardial space via a 45-cm Agilis (St. Jude Medical, Saint Paul, MN) steerable sheath. A 3D epicardial map acquired with voltage mapping demonstrated a similar but much larger area of scar than the endocardial map ([Figure 2A](#)). Pace-mapping from the epicardium did not yield any good pace-maps. Coronary angiography did not identify any major epicardial coronary artery in that area and was displayed along with the 3D map during ablation with the CARTO-UNIVU protocol. This integration allowed us to place lesions in the epicardial locations without the need for repeated coronary angiography ([Figure 3](#)). Multiple lesions were placed in the broad scar, but the VT still was easily inducible.

We then changed the voltage cutoff in the epicardial map down to 0.05 mV. This revealed discrete channels in the scar and multiple areas with late potentials ([Figure 2B](#)). Additional epicardial lesions placed along this region of channels rendered the VT noninducible, even with triple ventricular

## KEY TEACHING POINTS

- Catheter ablation of ventricular tachycardia in patients with arrhythmogenic right ventricular cardiomyopathy often requires a combined endocardial and epicardial approach.
- Adjustment of the voltage criteria can unmask potential channels by discriminating subtle areas of healthy tissue.
- CARTO-UNIVU integrates coronary angiography with 3-dimensional mapping to permit safer ablation on the epicardium.

extrastimuli. At 3-month follow-up the patient had not experienced any recurrent events.

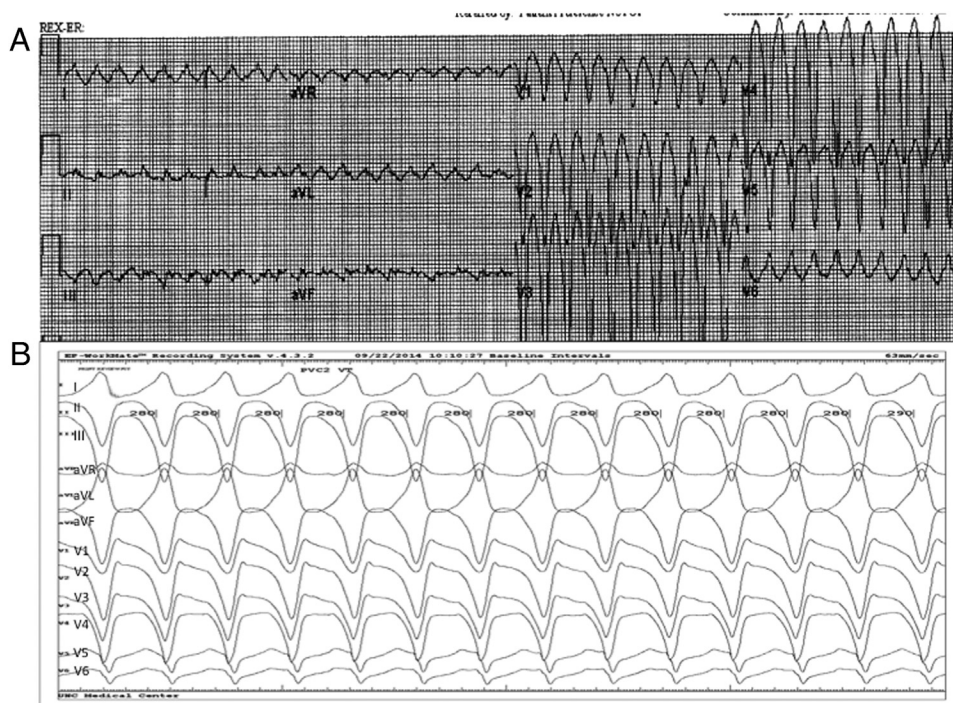
## Discussion

Our case highlights the roles of voltage mapping and CARTO-UNIVU in catheter ablation of VT. Use of CARTO-UNIVU image integration permits overlaying of coronary angiographic images on the 3D electroanatomic map and eliminates the need for repeated coronary angiography, especially when a large area of substrate modification on the epicardium is required.

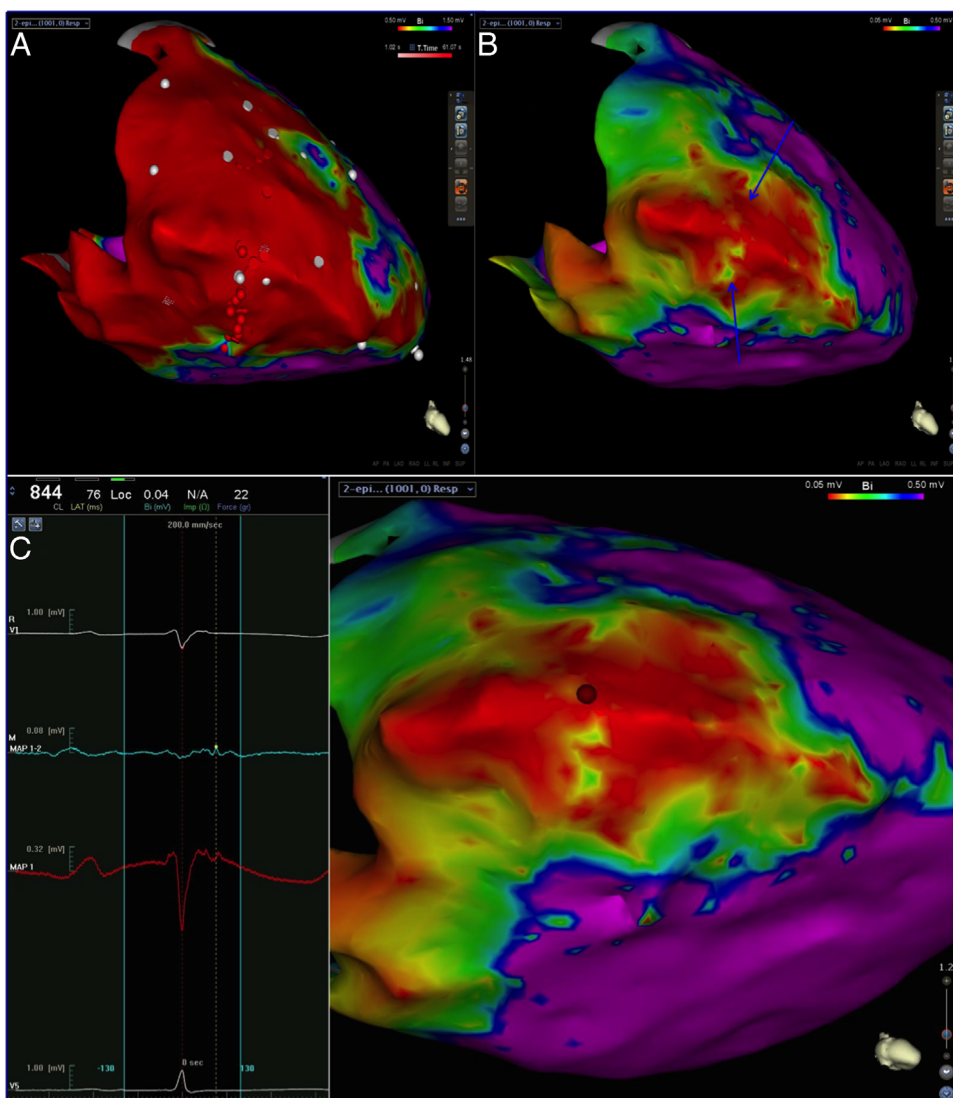
Our case also demonstrates the challenges in defining the substrate from the epicardial surface. Unipolar voltage mapping from the endocardium may be used for evaluation of epicardial scar.<sup>6-8</sup> However, traditional cutoffs may not suffice for mapping from the epicardial surface, especially in the context of ARVC.<sup>1,3</sup> In this patient, we attempted to recognize channels of relatively healthy tissue within the right ventricular free wall by selecting for voltage  $<0.5$  mV. Ablation of the channels unmasked by lowering the voltage cutoff was found to be an effective approach to ablating VT in this patient.

Catheter ablation is rarely associated with coronary artery injury. The areas requiring ablation in patients with ARVC often involve the base of the right ventricle, beneath the tricuspid valve annulus, and the right ventricular outflow tract.<sup>1</sup> These areas should be far from the right coronary artery, but coronary angiography is important to exclude unusual anatomy. Presentation of coronary injury can vary from immediate ECG changes to chest pain after discharge from the hospital.<sup>9</sup> We believe the CARTO-UNIVU system offers an important tool for avoiding coronary injury, especially during epicardial ablation.

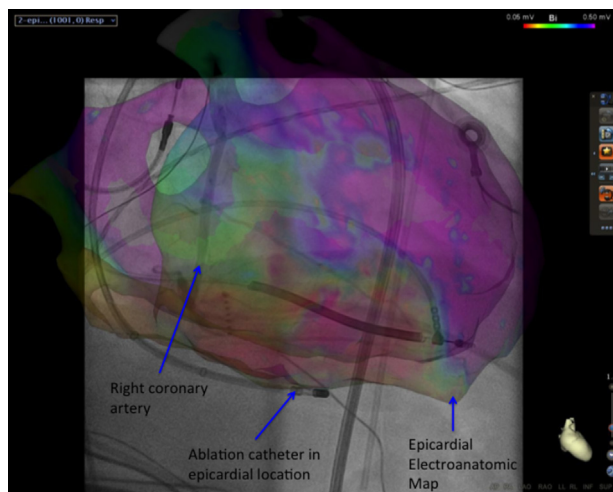
Adjustment of the voltage cutoff during epicardial substrate mapping for scar-related VT might be helpful in defining the potential VT circuits by unmasking channels of relatively healthy tissue in the middle of a dense scar. CARTO-UNIVU permits integration of coronary angiographic imaging with 3D electroanatomic maps to guide safe epicardial catheter ablation of VT.



**Figure 1** Electrocardiograms of clinical and induced ventricular tachycardia. **A:** Clinical ventricular tachycardia at initial presentation and diagnosis 2 years before ablation. Left bundle branch morphology and negative QRS complexes in the precordial leads suggest an apical inferior right ventricular exit. **B:** Induced ventricular tachycardia during the catheter ablation procedure showing similar axes and directions of the QRS complexes. However, QRS was negative in all precordial leads with no transition likely because of a difference in lead location between the 2 recordings.



**Figure 2** Epicardial voltage map during sinus rhythm showing extensive scarring of the right ventricular free wall. **A:** Voltage map with standard voltage threshold of 0.5 to 1.5 mV showing uniform extensive scarring of the right ventricular free wall. **B:** Unmasked channel of relatively higher voltage (blue arrows) after the voltage threshold was reduced to 0.05 to 0.5 mV. **C:** Unipolar and bipolar recordings from the epicardium with ablation catheter during sinus rhythm in the area of the channel (red tag) showing late potential.



**Figure 3** CARTO-UNIVU image showing electroanatomic voltage map in the right anterior oblique projection with overlaid coronary angiogram.

## References

1. Arbelo E, Josephson ME. Ablation of ventricular arrhythmias in arrhythmogenic right ventricular dysplasia. *J Cardiovasc Electrophysiol* 2010;21:473–486.
2. Arruda M, Armaganijan L, Fahmy T, Di Biase L, Patel D, Natale A. Catheter ablation of ventricular tachycardia in arrhythmogenic right ventricular dysplasia. *J Interv Card Electrophysiol* 2009;25:129–133.
3. Bai R, Di Biase L, Shivkumar K, et al. Ablation of ventricular arrhythmias in arrhythmogenic right ventricular dysplasia/cardiomyopathy: arrhythmia-free survival after endo-epicardial substrate based mapping and ablation. *Circ Arrhythm Electrophysiol* 2011;4:478–485.
4. Satomi K, Kurita T, Suyama K, Noda T, Okamura H, Otomo K, Shimizu W, Aihara N, Kamakura S. Catheter ablation of stable and unstable ventricular tachycardias in patients with arrhythmogenic right ventricular dysplasia. *J Cardiovasc Electrophysiol* 2006;17:469–476.
5. Sacher F, Roberts-Thomson K, Maury P, et al. Epicardial ventricular tachycardia ablation: a multicenter safety study. *J Am Coll Cardiol* 2010;55:2366–2372.
6. Polin GM, Haqqani H, Tzou W, Hutchinson MD, Garcia FC, Callans DJ, Zado ES, Marchlinski FE. Endocardial unipolar voltage mapping to identify epicardial substrate in arrhythmogenic right ventricular cardiomyopathy/dysplasia. *Heart Rhythm* 2011;8:76–83.
7. Spears DA, Suszko AM, Dalvi R, Crean AM, Ivanov J, Nanthakumar K, Downar E, Chauhan VS. Relationship of bipolar and unipolar electrogram voltage to scar transmural and composition derived by magnetic resonance imaging in patients with nonischemic cardiomyopathy undergoing VT ablation. *Heart Rhythm* 2012;9:1837–1846.
8. Hutchinson MD, Gerstenfeld EP, Desjardins B, et al. Endocardial unipolar voltage mapping to detect epicardial ventricular tachycardia substrate in patients with nonischemic left ventricular cardiomyopathy. *Circ Arrhythm Electrophysiol* 2011;4:49–55.
9. Roberts-Thomson KC, Steven D, Seiler J, Inada K, Koplan BA, Tedrow UB, Epstein LM, Stevenson WG. Coronary artery injury due to catheter ablation in adults: presentations and outcomes. *Circulation* 2009;120:1465–1473.