

## Case Report



# Desmoid Fibromatosis in the Multifidus Muscle Misdiagnosed as Intramuscular Schwannoma by Incisional Biopsy: A Case Report

Jae Hun Lee <sup>1</sup>, Sung Hwa Paeng <sup>1</sup>, Hwa Jin Cho <sup>2</sup>, Sung Tae Kim <sup>1</sup>, and Won Hee Lee <sup>1</sup>

<sup>1</sup>Department of Neurosurgery, Inje University Busan Paik Hospital, Busan, Korea

<sup>2</sup>Department of Pathology, Inje University Busan Paik Hospital, Busan, Korea



Received: May 26, 2021

Revised: Aug 15, 2021

Accepted: Aug 24, 2021

### Address of correspondence:

Sung Hwa Paeng

Department of Neurosurgery, Inje University Busan Paik Hospital, Inje Paik University, College of Medicine, 75 Bokji-ro, Busanjin-gu, Busan 47392, Korea.

E-mail: shpaeng@empas.com

Copyright © 2021 Korean Neurotraumatology Society

This is an Open Access article distributed under the terms of the Creative Commons Attribution Non-Commercial License (<https://creativecommons.org/licenses/by-nc/4.0/>) which permits unrestricted non-commercial use, distribution, and reproduction in any medium, provided the original work is properly cited.

### ORCID iDs

Jae Hun Lee

<https://orcid.org/0000-0001-8060-8937>

Sung Hwa Paeng

<https://orcid.org/0000-0002-8903-9117>

Hwa Jin Cho

<https://orcid.org/0000-0002-7613-1942>

Sung Tae Kim

<https://orcid.org/0000-0002-3737-3850>

Won Hee Lee

<https://orcid.org/0000-0002-3112-5354>

### Conflict of Interest

The authors have no financial conflicts of interest.

## ABSTRACT

Desmoid fibromatosis is a locally aggressive myofibroblastic neoplasm. In this study, we report a case of desmoid fibromatosis in the paraspinal muscle that was misdiagnosed as intramuscular schwannoma through incisional biopsy at another hospital. We performed total excision of the mass lesion with a clear margin. We found that for an accurate diagnosis, magnetic resonance imaging, incisional biopsy and excisional biopsy were required.

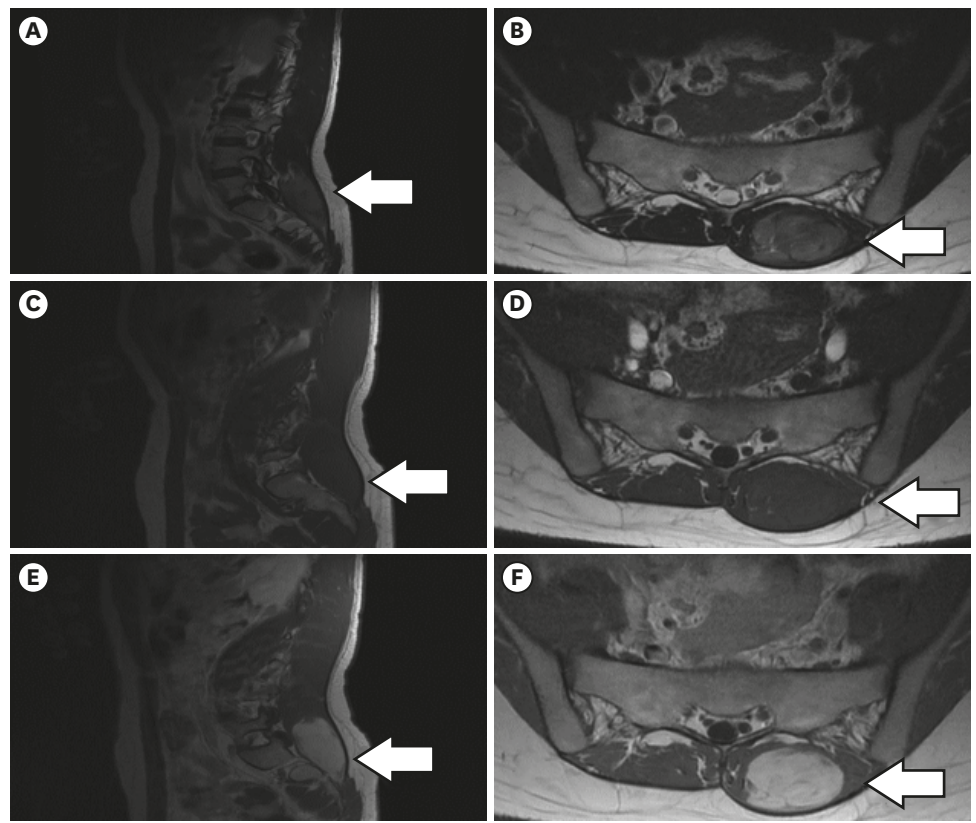
**Keywords:** Fibromatosis; Misdiagnosis; Biopsy

## INTRODUCTION

Desmoid fibromatosis is a locally aggressive myofibroblastic neoplasm. Approximately less than 4 patients per 1 million population are diagnosed with desmoid fibromatosis. Desmoid fibromatosis is commonly located in the extremities (30%–40%), abdominal cavity (15%), abdominal wall (20%), and chest wall (20%), but is rarely located in the head and neck, paraspinal region, or flank. Desmoid fibromatosis is well demarcated and shows iso-intensity by T2 weighted magnetic resonance imaging (MRI) and therefore is often confused with intramuscular schwannoma.<sup>5,6</sup> Because desmoid fibromatosis is mostly benign and grows slowly, differential diagnosis is often challenging due to other disease entities with similar clinical features. Neurological functions of patients are mostly saved because neural fiber involvement is not common. Here, we report a case study of desmoid fibromatosis in left multifidus muscle, which was misdiagnosed as schwannoma by pre-operative incisional biopsy.

## CASE REPORT

A 24-year-old woman was admitted to our department with pain in the right buttock and lower back. Incisional biopsy was performed at another hospital and a microscopic pathological report indicated intramuscular schwannoma. A non-tender palpable lump was identified at the left L5-S3 level. Neurologic sensory deficit or motor deficit was not detected. The laboratory data were within the normal limits. A 3.7×2.7×7.0 cm oval-shaped mass was identified on MRI at the left multifidus muscle. It had a well-defined margin with low signal



**FIGURE 1.** Magnetic resonance imaging scan show oval shaped paraspinal mass with iso-signal intensity and heterogeneity inside mass on T2-weighted sagittal (A) and axial (B) image. Low signal intensity on T1-weighted sagittal (C) and axial (D) image. Highly enhanced with well decarmated margin on gadolinium enhanced sagittal (E) and axial (F) image.

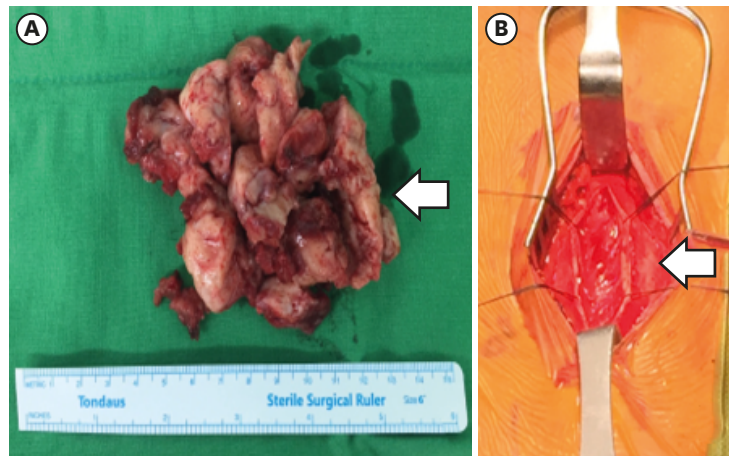
intensity on a T1 weighted image, intermediate signal intensity on a T2 weighted image, and a strong enhanced mass lesion was identified (**FIGURE 1**).

Under general anesthesia, we performed total mass excision and a biopsy was taken for pathologic confirmation. An 8.6 cm, well-encapsulated, soft mass was excised from the multifidus muscle (**FIGURE 2**). Histopathologic diagnosis identified the mass as desmoid fibromatosis (**FIGURE 3**). The patient was discharged without any neurologic defects after surgery.

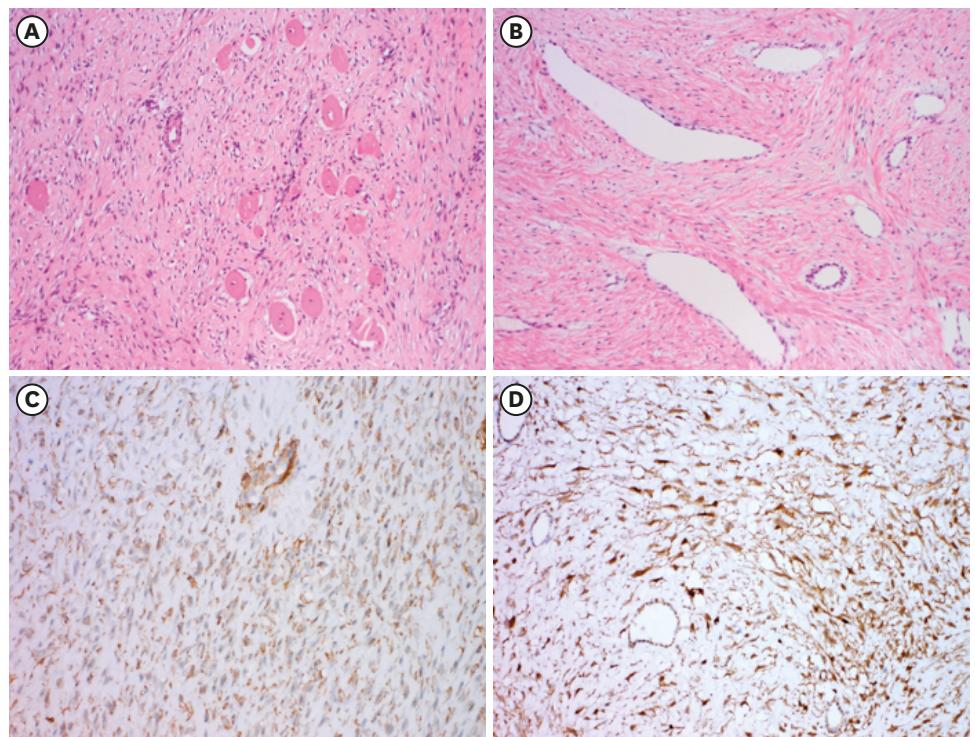
## DISCUSSION

Desmoid fibromatosis, a benign tumor that develops in musculoaponeurotic tissue, can affect any site in the body, but commonly develops in the extremities and abdomen. It usually localizes to a single area and lacks the probability of metastasis. It is classified as a locally aggressive tumor with a high probability of local recurrence, which is associated with extra-abdominal location, younger age, large tumor size, and certain mutation status.<sup>2)</sup>

Intramuscular desmoid tumor is uncommonly associated with neurologic symptoms including radiating pain, paresthesia, and motor deficit. In cases involving the psoas muscle, there is a possibility of femoral nerve compression. In our study, intramuscular desmoid fibromatosis developed at the left L5 to S3 multifidus muscle distant from any major nerve roots.



**FIGURE 2.** Surgical excision was done. (A, B) A 8×6×4 cm-sized, well encapsulated, soft mass was excised from the left multifidus muscle.



**FIGURE 3.** Microscopic findings of desmoid fibromatosis. (A) Fascicles of bland fibroblasts infiltrate into skeletal muscle. (B) Gaping thin-walled vessels are prominent with perivascular edema. Sweeping long fascicles are shown (A & B: hematoxylin and eosin stain). (C) Immunohistochemical staining of smooth muscle actin shows cytoplasmic positivity (smooth muscle actin). (D) Beta-catenin nuclear expression pattern is observed (beta-catenin) (A-D original magnifications: ×100).

Usually, MRI shows low signal intensity by T1-weighted images and intermediate signal intensity by T2-weighted images, and a well-enhanced and demarcated margin can be seen. The fibrotic portion of desmoid fibromatosis typically shows as a low signal by T2-weighted images. Prominent cellularity and myxoid lesion in desmoid fibromatosis are heterogeneous by T2-weighted images.<sup>8)</sup> Fascial tail sign indicates the presence of a linear border expanding from the lesion following the fascia and may be seen in up to 83% of desmoid fibromatosis

cases.<sup>3)</sup> This can be misdiagnosed as other soft tissue masses such as intramuscular schwannoma<sup>5,6)</sup> or a solitary fibrous tumor.

In our study, we observed microscopic features typical of desmoid fibromatosis. Infiltrative fascicles of long, bland fibroblasts were observed with remnants of skeletal muscle. Thin-walled blood vessels showed a gaping and focal staghorn appearance. Perivascular areas showed edematous changes. Nuclear atypia was mild and the mitotic count was less than 1 per 10 high-power views. Immunohistochemical staining for smooth muscle actin revealed the cytoplasm and nuclei, respectively. Ki-67 staining and the beta-catenin g index were low (up to 2%). No S-100 or CD34 staining was observed (**FIGURE 3**). To differentiate between schwannoma, S-100 and CD34 immunohistochemistry test is optimal as positive test result is present in schwannoma.

We report desmoid fibromatosis in the multifidus muscle mimicking intramuscular schwannoma. To prevent the misdiagnosis of desmoid fibromatosis, incisional biopsy as well as total excision after biopsy should be performed for patients with a paraspinal mass. A common reason for the misdiagnosis is insufficient biopsy tissues, lack of immunochemistry analysis tools, or human error.

Previous studies have reported paraspinal desmoid fibromatosis.<sup>1,4,7-9)</sup> Furlan et al.<sup>4)</sup> reported a patient with desmoid fibromatosis above the right quadratus lumborum. The patient was admitted with low back pain and received surgery.<sup>4)</sup> That report suggested radiotherapy, chemotherapy, and systemic therapy as further treatment modalities.<sup>4)</sup> Another study reported a tumor in the right subcutaneous fat.<sup>8)</sup> The incidence of local infiltration of the desmoid tumor is high, causing deformities. Therefore, the early detection and radical excision of the tumor is important for treatment planning. Also, regular outpatient follow-up and image taking is crucial for the evaluation of local recurrence.

## CONCLUSION

Paraspinal desmoid fibromatosis is a rare disease that can be misdiagnosed as other mass lesions by MRI. Desmoid fibromatosis should be considered on differential diagnosis to patients with paraspinal tumor.

## REFERENCES

1. Das Gupta TK, Brasfield RD, O'Hara J. Extra-abdominal desmoids: a clinicopathological study. *Ann Surg* 170:109-121, 1969  
[PUBMED](#) | [CROSSREF](#)
2. Dinauer PA, Brixey CJ, Moncur JT, Fanburg-Smith JC, Murphey MD. Pathologic and MR imaging features of benign fibrous soft-tissue tumors in adults. *Radiographics* 27:173-187, 2007  
[PUBMED](#) | [CROSSREF](#)
3. Fiore M, MacNeill A, Gronchi A, Colombo C. Desmoid-type fibromatosis: evolving treatment standards. *Surg Oncol Clin N Am* 25:803-826, 2016  
[PUBMED](#) | [CROSSREF](#)
4. Furlan JC, Valiante T, Dickson B, Kiehl TR. Paraspinal desmoid-type fibromatosis as a cause of low back pain. *Spine J* 13:1958-1959, 2013  
[PUBMED](#) | [CROSSREF](#)



5. Kim JH, Cho TG, Kim CH, Moon JG, Lee HK. Erector spinal muscular schwannoma of the dorsal ramus nerve: a case report. *Korean J Spine* 12:204-206, 2015  
[PUBMED](#) | [CROSSREF](#)
6. Kim YG, Kim TW, Kim MA, Park KH. Schwannoma in the dorsal paraspinal muscle: a case report. *Nerve* 6:93-95, 2020  
[CROSSREF](#)
7. Mubeen B, Majid S, Akhtar OS, Dar RA, Ashraf O. Paraspinal desmoid tumor in an 18 year old female. *J Orthop Traumatol Rehabil* 7:184-186, 2014  
[CROSSREF](#)
8. Nikolaou VS, Delis S, Giannakou N, Trainatopoulou C. Paraspinal desmoid tumor: a case report and a literature review. *Eur J Orthop Surg Traumatol* 18:525-529, 2008  
[CROSSREF](#)
9. Pignatti G, Barbanti-Bròdano G, Ferrari D, Gherlinzoni F, Bertoni F, Bacchini P, et al. Extraabdominal desmoid tumor. A study of 83 cases. *Clin Orthop Relat Res* 315:207-213, 2000  
[PUBMED](#) | [CROSSREF](#)