

# Case Report of *Aspergillus* Osteomyelitis of the Ribs in an Immunocompetent Patient

Shilpa Reynal D'sa, Suvir Singh, Sowmya Satyendra, Prasad Mathews

Department of Medicine, Christian Medical College and Hospital, Ida Scudder Road, Vellore, Tamil Nadu, India

## ABSTRACT

*Aspergillus* is a saprophytic fungus which is universally found in the environment. Most people breathe in the spores of *Aspergillus* every day without development of disease. It commonly affects immunocompromised hosts. There are only few reported cases in an immunocompetent host. It most commonly affects the respiratory system, causing superficial or invasive disease. It also affects the skin, brain and eye in severely immunocompromised patients. Aspergillosis of the bone is extremely rare. Amongst all the reported cases of invasive aspergillosis the incidence of osteomyelitis is less than three percent. In these cases commonly of the spine is reported. We present a case of *Aspergillus* osteomyelitis of the ribs in an immunocompetent host.

**Key words:** *Aspergillus*, Immunocompetent, Osteomyelitis, Ribs

## INTRODUCTION

*Aspergillus* is a ubiquitous saprophytic fungus universally found in nature. *Aspergillus* exists in two forms: spores and hyphae, with spores being the infective form. Most people breathe in *Aspergillus* spores daily without being affected. Of the 300 known species of *Aspergillus* only a few of them cause opportunistic infections.<sup>[1]</sup> The vast majority of disease is caused by *A. fumigatus*, followed by *A. flavus* and *A. niger*.

Invasive Aspergillosis (IA) is a disease generally seen in immunocompromised patients. It commonly affects the lungs, but can spread and invade other organs in the body. Population based studies suggest a rate of one to two cases of invasive aspergillosis per 100,000 people per year with the mortality increasing by 357% in the United States from 1980 to 1997.<sup>[2]</sup> This has been attributed to the increasing number and longer survival of immunocompromised patients with newer modalities of treatment.

## CASE REPORT

A 45-year-old lady presented with a history of right upper

abdominal pain for six months. The pain worsened on deep inspiration and on applying pressure over the chest wall. It had been progressively worsening in severity. She gave a history of loss of appetite and loss of weight of approximately five kilograms during this period. There was no history of cough, fever or trauma. She gave a history of diabetes mellitus for five years, which was adequately controlled with oral hypoglycemic agents.

On examination, she had tenderness over her right upper abdomen. She had no underlying organomegaly, bony tenderness or lung findings. Investigations were normal, except an elevated ESR and CRP. Imaging studies, including chest radiograph, abdomen ultrasound and a bone scan were inconclusive. She was asked to follow-up after two months.

She presented again after six months with increased pain over the right upper quadrant. On examination, she was found to have a tender swelling on the right ninth and tenth ribs, measuring 3 × 2 cm each. With a tender swelling, and elevated inflammatory markers, a diagnosis of Osteomyelitis involving the ribs was made, and she underwent a computed tomography (CT) scan to confirm the same.

CT of the chest and abdomen revealed a swelling over the lower end of the ninth and tenth ribs, associated with thickening of the underlying pleura, and necrosis of adjoining ribs and costochondral junctions. A screening

### Access this article online

Quick Response Code:



Website:  
[www.jgid.org](http://www.jgid.org)

DOI:  
10.4103/0974-777X.116875

**Address for correspondence:**

Dr. Shilpa Reynal D'sa, E-mail: [shilpa\\_dsa@yahoo.co.in](mailto:shilpa_dsa@yahoo.co.in)

ultrasound showed an 8cc collection with surrounding necrosis, which was aspirated under guidance. The histopathology report showed areas of necrosis on histology, with a lymphohistiocytic inflammatory infiltrate [Figure 1]. The aspirates were also sent for cultures, which grew *Aspergillus fumigatus* after two weeks of incubation [Figure 2]. This report was unexpected, as the patient did not have any traditional risk factors for *Aspergillosis*. She had diabetes mellitus, which was well controlled, without evidence of any complications.

She underwent surgical debridement, and was initiated on Voriconazole. She showed clinical improvement after the same

## DISCUSSION

*Aspergillus* is a fungus found universally in nature. It commonly causes disease in immunocompromised patients. This disease is well documented in solid organ recipients, involving over 30% patients with lung transplants, followed by chronic granulomatous disease and acute leukemias.<sup>[2]</sup>

The epidemiology of aspergillosis differs slightly in developing countries. In addition to the similar risk factors as in the western population, old tuberculous cavities, uncontrolled diabetes, intracranial surgery and cardiac device implantation are also found to increase the risk of *Aspergillus* infections.<sup>[3]</sup>

The spores of *Aspergillus* are unusually small compared to other fungi, which allows for easy inhalation.<sup>[1]</sup> Within 4-5 h of inhalation, the spores swell up, and within 12-14 h, germinate to form invasive hyphae. Cell mediated immunity

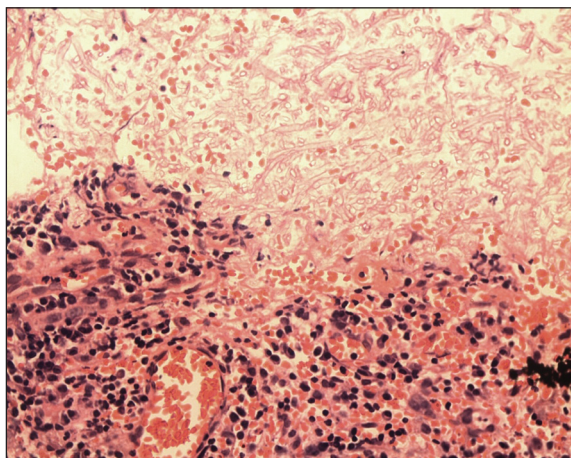
plays a vital role in defense against aspergillosis, with macrophages and NK cells being the first line of defense, followed by activation of NADPH oxidase and recruitment of T cells. The importance of NADPH is highlighted by the fact that patients with chronic granulomatous disease, who are unable to produce NADPH, have one of the highest incidences of *Aspergillus* infections. Pulmonary involvement is the commonest manifestation of aspergillosis, seen in 80-90% of patients.<sup>[4]</sup>

## Aspergillosis of the bone

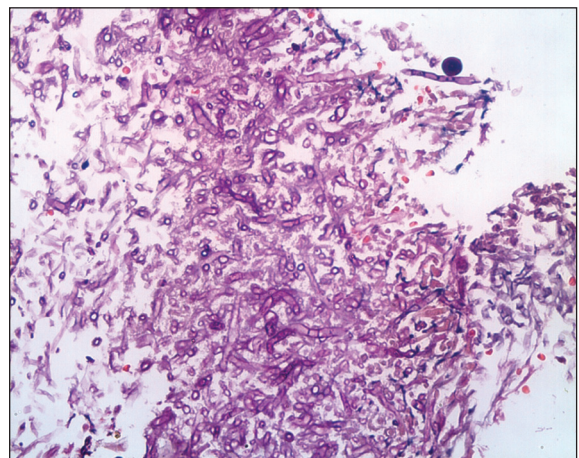
The most common cause of fungal osteomyelitis is *Candida*.<sup>[5]</sup> *Aspergillosis* of the bone is extremely rare and among cases of reported invasive aspergillosis the incidence of osteomyelitis is found to be lesser than three percent.<sup>[5]</sup> The osteomyelitis commonly involves the vertebral bodies and has been seen to mimic tuberculous osteomyelitis.<sup>[6]</sup>

Also more than 50% of the patients do not have fever. Osteomyelitis can occur by direct implantation (either traumatic or iatrogenic), hematogenous spread or by contiguity. There are very few case reports of *Aspergillus* osteomyelitis in an immunocompetent patient,<sup>[7]</sup> with most of the case reports showing involvement of the spine.

We came across only one case described in literature, where *Aspergillus* osteomyelitis of the rib and vertebral bodies was diagnosed in an immunocompetent IV drug user.<sup>[8]</sup> The presentation was remarkably similar to our patient's, with hypochondrial pain for more than four months and a localized swelling over the lower ribs. Diagnosis was proven by aspiration and culture of the localized collection. Treatment was with debridement and a prolonged course of antifungal therapy.<sup>[8]</sup>



**Figure 1:** The histopathology report of the necrotic bone showed dense inflammatory granulation tissue, necrotic bone and narrow branching septate fungal hyphae



**Figure 2:** PAS (Periodic acid-Schiff) stain of the necrotic bone showing branching septate fungal hyphae diagnostic of *Aspergillus fumigatus*

The natural history of such infections is to have a protracted course, with late diagnosis being the rule rather than the exception.<sup>[1]</sup> In a recent review of 106 patients with rib osteomyelitis, the mean duration to diagnosis of fungal osteomyelitis was 32 weeks.<sup>[1]</sup>

Our case highlights the increasing incidence of this previously rare disease, which is a reflection of an increase in the number of people living with immunosuppression. Thus, in a patient with osteomyelitis or soft tissue infections, culture and histopathological examination is very essential to avoid missing fungal infections. This is especially true in patients who are elderly, diabetics or otherwise debilitated.

To our knowledge this is the second case report of such a manifestation of *Aspergillus* osteomyelitis involving the ribs without pulmonary involvement, and the first such case in an immunocompetent host.

### CONCLUSION

It is important to consider the very rare possibility of a fungal osteomyelitis even in an immunocompetent patient. This is important in view of an ever increasing number of diabetic and elderly population. However, it is a diagnosis which can only be made with histopathology and culture reports.

### ACKNOWLEDGEMENT

Dr Anusha Kumari, Department of General pathology and  
Dr Ramya I, Department of Medicine, CMC Vellore.

### REFERENCES

1. Denning DW. Invasive aspergillosis in immunocompromised patients. *Curr Opin Infect Dis* 1994;7:456-62.
2. McNeil MM, Nash SL, Hajjeh RA. Trends in mortality due to invasive mycotic diseases in the United States, 1980-1997. *Clin Infect Dis* 2001;33:641-7
3. Arunaloke C, Chatterjee SS, Das A, Shivaprakash MR. Invasive aspergillosis in developing countries. *Med Mycol* 2011;49(Suppl 1):S35-47.
4. Segal BH. Aspergillosis. *N Engl J Med* 2009;360:1870-8.
5. Frazier DD, Campbell DR, Garvey TA, Wiesel S, Bohlman HH, Eismont FJ. Fungal infections of the spine: Report of eleven patients with long term follow-up. *J Bone Joint Surg Am* 2001;83:560-5.
6. Winterstein AR, Bohndrof K, Vollert K, Wagner T, Gnekow A, Roemer FW. Invasive aspergillosis osteomyelitis in children-a case report and review of literature. *Skeletal Radiol* 2010;39:827-31.
7. Ranjan R, Mishra S, Ranjan S. *Aspergillus* vertebral osteomyelitis in an immunocompetent person. *Neurol India* 2010;58:806-8.
8. Salloum A, Rao S, Havasi A, Miljkovic G, Amoateng-Adjepong Y. Correspondence. *Am J Med* 2004;116:208-9.

**How to cite this article:** D'sa SR, Singh S, Satyendra S, Mathews P. Case report of *Aspergillus* osteomyelitis of the ribs in an immunocompetent patient. *J Global Infect Dis* 2013;5:118-20.

**Source of Support:** Nil. **Conflict of Interest:** None declared.

#### Announcement

#### iPhone App



Download  
iPhone, iPad  
application

FREE

A free application to browse and search the journal's content is now available for iPhone/iPad. The application provides "Table of Contents" of the latest issues, which are stored on the device for future offline browsing. Internet connection is required to access the back issues and search facility. The application is Compatible with iPhone, iPod touch, and iPad and Requires iOS 3.1 or later. The application can be downloaded from <http://itunes.apple.com/us/app/medknow-journals/id458064375?ls=1&mt=8>. For suggestions and comments do write back to us.