

# Anti-programmed cell death protein 1-induced lichenoid changes of the nail unit: Histopathologic description



Claire van Damme, MD,<sup>a</sup> Vincent Sibaud, MD,<sup>b</sup> Josette André, MD,<sup>c</sup> Bertrand Richert, MD, PhD,<sup>c</sup> and Evelyne Berlingin, MD<sup>a</sup>  
Mons and Brussels, Belgium; and Toulouse, France

**Key words:** anti-PD-1; checkpoint inhibitor; histopathology; immunotherapy; lichenoid changes; lichen planus; lichen unguis; nail; nivolumab.

## INTRODUCTION

Tumor cells block our immune system and avoid being destroyed by inactivating T lymphocytes. Immunotherapy prevents this inactivation and allows the immune cells to fight tumor cells. The normal immunologic homeostasis is disturbed, and specific immune-related adverse events (irAEs) may develop: pneumonitis, hepatitis, colitis, endocrinopathies, and skin changes. The latter are one of the most frequent irAEs and occur in about 40% of the patients.<sup>1</sup> Maculopapular rashes (14%-40% of the patients) and pruritus (10%-30% of the patients) are mainly reported, but lichenoid (in about 7% of the patients), psoriasiform or eczematous eruptions, as well as alopecia, vitiligo (5%-11%), bullous pemphigoid (<1%), and sarcoid-like reactions have also been reported.<sup>1-3</sup>

Paradoxically, nail changes with immune checkpoint blockade have only been sporadically described in association with anti-programmed cell death protein 1 (anti-PD-1)/PD-L1 antibody therapy.<sup>4,5</sup> We report herein 2 cases of nail lichenoid changes, confirmed by histopathology, in 2 patients receiving the anti-PD-1 monoclonal antibody nivolumab.

## CASE REPORTS

### Case 1

A 68-year-old man with a pulmonary adenocarcinoma and liver, peritoneal, and bone metastases,

### Abbreviations used:

Anti-PD-1: Anti-programmed cell death protein 1  
irAEs: immune-related adverse events

received gemcitabine chemotherapy and then nivolumab alone (240 mg IV every 2 weeks). After 10 months of immunotherapy with nivolumab, he developed alterations on most fingernails presenting as an erythema of the lunula with a rapid progression to proximal or lateral onycholysis (Fig 1, A) and subsequent loss of 3 nails. There was neither subungual hyperkeratosis nor pterygium. Skin and mucous membranes were normal. A lateral longitudinal biopsy was performed on 1 fingernail. The alterations predominated in the distal matrix, where a hypertrophic acanthosis, the appearance of a stratum granulosum, and an orthokeratotic hyperkeratosis lifting up the nail plate were observed (Fig 2, A). A few apoptotic keratinocytes and a dense lichenoid mononuclear cell infiltrate in the upper dermis were also noticed. Periodic acid-Schiff–staining revealed neither fungal hyphae nor spores.

Immunotherapy was continued with the same regimen. Ultrapotent topical corticosteroids were applied under occlusion every night on the fingernails in addition to monthly intralesional injection of triamcinolone acetonide (10 mg/mL, 0.2 mL/nail). This treatment lasted 6 months until there was no

From the Dermatology Department, Ambroise Paré University Hospital Center<sup>a</sup>; Oncodermatology Department, Institut Claudius Regaud and Institut Universitaire du Cancer Toulouse Oncopole<sup>b</sup>; and Department of Dermatology, Saint-Pierre University Hospital, Université Libre de Bruxelles.<sup>c</sup>

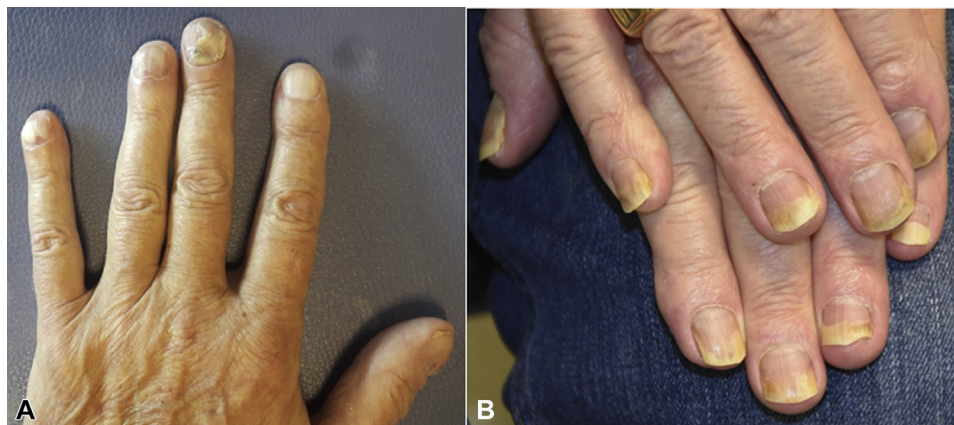
Funding sources: None.

Correspondence to: Claire van Damme, MD, CHU Ambroise Paré - Service de Dermatologie, Boulevard John Fitzgerald Kennedy, 2, B-7000 Mons, Belgium. E-mail: [claire.van.damme@ulb.be](mailto:claire.van.damme@ulb.be).

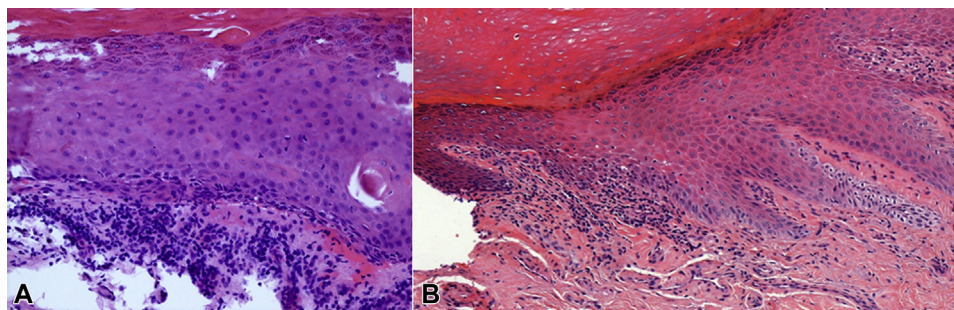
JAAD Case Reports 2021;10:110-2.  
2352-5126

© 2021 by the American Academy of Dermatology, Inc. Published by Elsevier, Inc. This is an open access article under the CC BY-NC-ND license (<http://creativecommons.org/licenses/by-nc-nd/4.0/>).

<https://doi.org/10.1016/j.jidcr.2021.02.016>



**Fig 1.** Clinical pictures of nail changes in 2 men with lung cancer treated with nivolumab. **A**, Patient 1, after 20 cycles of nivolumab. The fourth and fifth fingers presented a red lunula, and the first and third fingers presented onycholysis, thinning, and destruction of the nail plate. **B**, Patient 2, after 39 cycles of nivolumab. Diffuse distal onycholysis on all fingernails.



**Fig 2.** Histological pictures of nail changes in 2 men with lung cancer treated with nivolumab. Hematoxylin-eosin stain. Distal part of the matrix showing hypertrophic acanthosis, hypergranulosis, rare apoptotic keratinocytes, and a lichenoid infiltrate in the upper dermis. **A**, Patient 1. **B**, Patient 2.

longer any sign of lichen disease activity, with improvement of symptoms. At 1-year follow-up there was almost complete clearance despite continuation of nivolumab: all nails have grown back to normal except onychorrhexis for one fingernail and a distal fissure for another.

### Case 2

A patient in his seventies was addressed in the dermatology department for nail changes developing within the previous 2 months. The patient was managed for a squamous cell carcinoma of the lung [T3N2M0 according to the tumor, nodes, and metastases classification, 7th edition]. He was treated for 18 months with a 2-week regimen of nivolumab (240 mg, every cycle). He had no other medical history.

Diffuse distal onycholysis involving all fingernails was noted, with relative sparing of the toenails (Fig 1, B). Splinter subungual hemorrhages were visible on the nail plate of the right thumb. No clinical

hyperkeratosis or paronychia was noted. No cutaneous or mucosal lesions were visible.

A nail biopsy was performed on the right thumb, revealing a perivascular lympho-histiocytic infiltrate combined with a patchy lichenoid interface dermatitis and variable degrees of lymphocytic exocytosis, focal basal vacuolar changes, and apoptosis (Fig 2, B). Epidermal hyperkeratosis was also observed. Periodic acid-Schiff—staining did not show fungal hyphae or spores.

The patient was lost to follow-up.

### DISCUSSION

A considerable part of skin and/or nail irAEs are lichenoid or psoriasiform reactions. Anti-PD-1/PD-L1 especially but also anti-cytotoxic T-lymphocyte-associated protein 4 antibody therapies have been added to the evergrowing list of medication causing a lichenoid drug reaction.<sup>6</sup> It develops from day 1 up to more than 1 year after therapy initiation.<sup>2</sup> Immunotherapy causes lichenoid changes either by

itself through a generalized up-regulation of the immune system or by unmasking an immune response to a medication that was previously tolerated.<sup>2</sup> Regarding our 2 patients, nivolumab was suspected to be the cause of the lichenoid reaction as it was the only new medication.

A flare-up of a preexisting psoriasis that was quiescent before immunotherapy, or a *de novo* psoriasis may also occur. Dysregulation of the immune tolerance to some self-antigens or the unmasking of a psoriatic reaction in predisposed individuals due to augmented Th17 responses explain the development of psoriasiform reactions.<sup>7</sup> Immunotherapy-induced dermatological toxicity can clinically evoke psoriasis but be identified histologically as lichen planus. Indeed, the diffuse distal onycholysis affecting our second patient's nails suggested a psoriasiform condition; however, histology revealed lichenoid changes.

The histological presentation of anti-PD-1-associated lichenoid eruptions can be very similar to idiopathic lichen planus. The presence of parakeratosis, granular layer disruption, dyskeratotic cells present in the cornified or granular layers, periadnexal/perivascular inflammation, and eosinophils favor a lichenoid drug eruption.<sup>6</sup> Significantly more CD163<sup>+</sup> histiocytes, a marker of macrophages, are observed in biopsies from patients treated with immune checkpoint inhibitors.<sup>1</sup>

As of yet, no association between the tumor-justifying immunotherapy and the type of rash has been identified,<sup>8</sup> as dermatological toxicity has been described in patients treated with immunotherapy for several indications (lung cancer, melanoma, renal cell carcinoma). Of note, the occurrence of cutaneous irAEs might reflect a better therapeutic response in terms of progression-free survival.<sup>4</sup> It would be interesting to conduct further prospective studies on this topic, while paying attention to the nails in addition to the skin.

Prompt management of nail lichenoid changes with intralesional triamcinolone acetonide and/or oral retinoids without disruption of the life-saving anticancer treatment appears adequate. Acitretin (0.2-0.3 mg/kg/day) and alitretinoin (30 mg/day), which can improve the skin as well, are good options, and their doses can be tapered, once good control has been achieved.<sup>5,9</sup> Since nail growth takes longer than skin renewal (6 months to replace a fingernail and 12-18 months for a toenail), more time is required to evaluate the nail response to

treatment. Systemic corticosteroids should not be a first choice, especially when toxicity affects only a few nails. Their concomitant use with immune checkpoint inhibitors is not thought to worsen the clinical outcomes,<sup>10</sup> but more data are needed to confirm this. In severe cases, functional consequences, the patient's quality of life, and the importance of the anti-tumor response will be part of the discussion with oncologists and dermatologists to make a case-by-case decision.

The patients in this manuscript have given written informed consent to the publication of their case details. Thanks to Carole van Damme for reviewing the English.

#### Conflicts of interest

None disclosed.

#### REFERENCES

1. Lacouture M, Sibaud V. Toxic side effects of targeted therapies and immunotherapies affecting the skin, oral mucosa, hair, and nails. *Am J Clin Dermatol*. 2018;19(suppl1):31-39.
2. Shi VJ, Rodic N, Gettinger S, et al. Clinical and histologic features of lichenoid mucocutaneous eruptions due to anti-programmed cell death 1 and anti-programmed cell death ligand 1 immunotherapy. *JAMA Dermatol*. 2016;152(10):1128-1136.
3. Philips G, Wu J, Hellmann M, et al. Treatment outcomes of immune-related cutaneous adverse events. *J Clin Oncol*. 2019;37(30):2746-2758.
4. Sibaud V. Dermatologic reactions to immune checkpoint inhibitors: skin toxicities and immunotherapy. *Am J Clin Dermatol*. 2018;19(3):345-361.
5. Edwards C, Fearfield L. Nivolumab-induced lichenoid dermatitis occurring in a patient with metastatic melanoma successfully treated with alitretinoin. *Clin Exp Dermatol*. 2018;43(5):609-610.
6. Deschaine MA, Lehman JS. The interface reaction pattern in the skin: an integrated review of clinical and pathological features. *Hum Pathol*. 2019;91:86-113.
7. Elosua-González M, Pampín-Franco A, Mazzucchelli Esteban R, et al. A case of *de novo* palmoplantar psoriasis with psoriatic arthritis and autoimmune hypothyroidism after receiving nivolumab therapy. *Dermatol Online J*. 2017;23(8).
8. Coleman E, Ko C, Dai F, Tomayko MM, Kluger H, Leventhal JS. Inflammatory eruptions associated with immune checkpoint inhibitor therapy: a single-institution retrospective analysis with stratification of reactions by toxicity and implications for management. *J Am Acad Dermatol*. 2019;80(4):990-997.
9. Sahuquillo-Torralba A, Ballester-Sánchez R, Pujol-Marco C, Botella-Estrada R. Pembrolizumab: a new drug that can induce exacerbations of psoriasis. *Actas Dermosifiliogr*. 2016;107(3):264-266.
10. Garant A, Guilbault C, Ekmekjian T, Greenwald Z, Murgoi P, Vuong T. Concomitant use of corticosteroids and immune checkpoint inhibitors in patients with hematologic or solid neoplasms: a systematic review. *Crit Rev Oncol Hematol*. 2017;120:86-92.