



Published in final edited form as:

Gastroenterology. 2023 March ; 164(3): 484–491. doi:10.1053/j.gastro.2022.11.034.

AGA Clinical Practice Update on Diagnosis and Management of Acute Hepatic Porphyrrias: Expert Review

Bruce Wang¹, Herbert L. Bonkovsky², Joseph K. Lim³, Manisha Balwani⁴

¹Department of Medicine and Division of Gastroenterology, University of California San Francisco, San Francisco, California

²Section of Gastroenterology and Hepatology, Wake Forest University School of Medicine, Winston-Salem, North Carolina

³Section of Digestive Diseases and Yale Liver Center, Yale University School of Medicine, New Haven, Connecticut

⁴Departments of Genetics and Genomic Sciences, Icahn School of Medicine at Mount Sinai, New York, New York

Abstract

DESCRIPTION: The acute hepatic porphyrias (AHP) are rare, inborn errors of heme-metabolism and include acute intermittent porphyria, hereditary coproporphyria, variegate porphyria, and porphyria due to severe deficiency of 5-aminolevulinic acid dehydratase. Acute intermittent porphyria is the most common type of AHP, with an estimated prevalence of patients with symptoms of approximately 1 in 100,000. The major clinical presentation involves attacks of severe pain, usually abdominal and generalized, without peritoneal signs or abnormalities on cross-sectional imaging. Acute attacks occur mainly in women in their childbearing years. AHP should be considered in the evaluation of all patients, and especially women aged 15–50 years with recurrent severe abdominal pain not ascribable to common causes. The screening tests of choice include random urine porphobilinogen and δ -aminolevulinic acid corrected to creatinine. All patients with elevations in urinary porphobilinogen and/or δ -aminolevulinic acid should initially be presumed to have AHP. The cornerstones of management include discontinuation of porphyrinogenic drugs and chemicals, administration of oral or intravenous dextrose and intravenous hemin, and use of analgesics and antiemetics. Diagnosis of AHP type can be confirmed after initial treatment by genetic testing for pathogenic variants in *HMBS*, *CPOX*, *PPOX*, and *ALAD* genes. AHP is also associated with chronic symptoms and long-term risk of systemic arterial hypertension, chronic renal and liver disease, and hepatocellular carcinoma. Patients who have recurrent acute attacks (4 or more per year) should be considered for prophylactic therapy with intravenous hemin or subcutaneous givosiran. Liver transplantation is curative and reserved for patients with intractable symptoms who have failed other treatment options.

This is an open access article under the CC BY license (<http://creativecommons.org/licenses/by/4.0/>).

***Correspondence:** Address correspondence to: Bruce Wang, MD, Department of Medicine, Division of Gastroenterology, University of California San Francisco, 513 Parnassus Avenue, Health Science East 1427, San Francisco, California 94143-1346. bruce.wang@ucsf.edu.

METHODS: This expert review was commissioned and approved by the American Gastroenterological Association (AGA) Institute Clinical Practice Updates Committee (CPUC) and the AGA Governing Board to provide timely guidance on a topic of high clinical importance to the AGA membership, and underwent internal peer review by the CPUC and external peer review through standard procedures of *Gastroenterology*. These Best Practice Advice (BPA) statements were drawn from a review of the published literature and from expert opinion. Because systematic reviews were not performed, these BPA statements do not carry formal ratings of the quality of evidence or strength of the presented considerations.

Keywords

5-Aminolevulinic Acid; 5-Aminolevulinic Acid Synthase; Heme; Porphobilinogen; Porphyria; Porphyrins

Porphyrias are inherited disorders in the heme biosynthesis pathway. Heme is an essential molecule that carries out a wide array of functions necessary for aerobic life. It is synthesized through 8 enzymatic steps, and mutations that lead to partially defective activity in heme synthesis enzymes result in the 8 inherited porphyrias.^{1,2} Symptoms are due to the specific intermediates that accumulate before the defective enzymatic step. The acute hepatic porphyrias (AHPs) include acute intermittent porphyria (AIP), variegate porphyria (VP), hereditary coproporphyria (HCP), and 5-aminolevulinic acid dehydratase deficiency porphyria (ALAD) (Table 1). They present with acute neurovisceral symptoms due to abnormal accumulation of the porphyrin precursors δ -aminolevulinic acid (ALA) and porphobilinogen (PBG). Clinically, they present with severe acute abdominal pain, nausea, vomiting, constipation, muscle weakness, neuropathy, tachycardia, and hypertension. Four additional porphyrias present primarily with cutaneous symptoms and are not discussed in this review.

AIP, HCP, and VP are autosomal dominant disorders and ALAD porphyria is a very rare autosomal recessive disorder with fewer than a dozen reported cases in the world literature.^{3–6} Pathogenic variants in the hydroxymethylbilane synthase (HMBS), coproporphyrinogen oxidase, and protoporphyrinogen oxidase genes (referred to collectively as AHP pathogenic variants) result in at least a 50% reduction of the activity in the corresponding enzyme (Figure 1). Symptomatic AHPs are thought to affect approximately 1 in 100,000 patients; however, data from population-level genetic studies showed that the prevalence of pathogenic variants for AIP is between 1 in 1300 and 1 in 1785, much higher than previously believed.^{7,8} Diagnoses of AHPs are often missed, with a delay of more than 15 years from initial presentation. This suggests that the true prevalence of symptomatic AHPs may be higher. Recent advances in treatment have improved the outlook for patients with AHP. This review is designed to provide best practice advice on the diagnosis, treatment, and long-term management of patients with AHP. We have developed Best Practice Advice statements to address 12 key clinical issues.

Best Practice Advice 1: Women aged 15–50 years with unexplained, recurrent severe abdominal pain without a clear etiology after an initial workup should be considered for screening for an AHP.

Approximately 90% of patients with symptomatic AHP are women and attacks are rare before onset of menses or after menopause in these patients. Among symptomatic patients with AHP, >90% experience only 1 or a few acute attacks in their lifetimes. Attacks are often precipitated by inducing factors that increase heme production in the liver. An estimated 3%–5% of patients with symptomatic AHP experience frequent recurrent attacks, typically defined as 4 or more attacks per year. These attacks are often not associated with identifiable triggers, although some attacks during the luteal phase of the menstrual cycles are believed to be triggered by progesterone. In addition to the acute attack symptoms described, >50% of patients who experience recurrent attacks report chronic neurologic symptoms, and 35% have received a diagnosis of neuropathy.^{9,10} These patients have a markedly impaired quality of life^{11,12} and are at higher risk of long-term complications of AHP, including hepatocellular carcinoma (HCC)¹³ and chronic renal failure.^{14,15} ALA and PBG levels in patients experiencing recurrent attacks may be elevated at baseline between attacks.¹⁶ It remains unclear whether chronic symptoms are due to persistently elevated ALA or incomplete recovery from neurologic injury sustained during acute attacks.

Some individuals who carry an AHP pathogenic variant have elevated ALA and PBG but have never experienced acute attacks. This group of asymptomatic high excretors may be at increased risk for an induced acute attack, chronic renal or hepatic injury, and/or HCC relative to mutation carriers with normal ALA.^{17,18} Diagnosis of AHPs is frequently delayed, with an average of 15 years from onset of symptomatic AHP to diagnosis in the United States and Europe.¹⁹ Accordingly, AHP should be considered in any patient, especially any woman of childbearing age, who presents with unexplained recurrent, severe abdominal pain.

Best Practice Advice 2: Initial diagnosis of AHP should be made by biochemical testing measuring ALA, PBG, porphyrins, and creatinine in a random urine sample.

Diagnosis of symptomatic AHP requires biochemical testing. The hallmark of acute attacks is significantly elevated ALA and PBG in the urine or plasma. In all AHP except ALAD porphyria, PBG is elevated. During acute attacks, both ALA and PBG are elevated at least 5-fold the upper limit of normal. The levels are high enough that a random urine sample is sufficient and a 24-hour urine collection is not recommended. To adjust for differences in the degree of urinary concentration, ALA and PBG excretion should be normalized to that of creatinine. It is important to note that because ALA and PBG are porphyrin precursors, they are not included in tests of porphyrins, which typically measure porphyrins in urine or stool that have been separated and quantified by high-performance liquid chromatography with fluorescence detection. Urine porphyrins should not be used alone as a screening test for

AHP. Mild and nondiagnostic elevations in urinary porphyrins (secondary porphyrinurias) are often incorrectly interpreted as indicating AHP and lead to erroneous overdiagnosis.

Both ALA and PBG can be measured with high sensitivity and specificity.^{20–22} Unfortunately, these tests are performed at large reference laboratories only, and results often require 1–2 weeks to be reported. Rapid, qualitative urine PBG tests have been available since the 1950s (Hoesch or Watson-Schwartz test),²³ but their clinical use has been limited due to lack of use by most hospitals. Recently, a new rapid test for PBG was approved in the United States (Teco Diagnostics).

For most patients with AHP, those who experience only a few acute attacks in their lifetimes, testing for urine ALA, PBG, and creatinine is most useful during an acute attack. Unless the patient has been treated with intravenous hemin, testing for ALA and PBG can be performed days after the acute attack. Studies of patients with AIP found that ALA and PBG can remain elevated in urine for months to years after an acute attack.²⁴ However, ALA and PBG levels can fall quickly after an acute attack in patients with HCP or VP. When testing is performed in patients with sporadic AIP when they are asymptomatic, 15%–44% can have normal urine ALA and PBG values.^{25,26} The same, or even higher, percentages are likely true for HCP and VP. In these patients, confirmatory testing may require repeat testing during an acute attack.

In the small population of patients with AHP with recurrent acute attacks, urine ALA and PBG are typically elevated even at baseline between acute attacks.¹⁶ In patients who have frequent symptoms suggestive of acute attacks, normal ALA and PBG levels likely rule out AHP as the etiology of the symptoms.

Best Practice Advice 3: Genetic testing should be used to confirm the diagnosis of AHP in patients with positive biochemical testing.

Once the biochemical tests indicate AHP, confirmation of the specific type of AHP is usually established by genetic testing, with sequencing of the 4 genes *ALAD*, *HMBS*, *CPOX*, and *PPOX* leading to ALAD, AIP, HCP, and VP, respectively. When whole-gene sequencing is performed, 95%–99% of cases can be identified.²⁷ First-degree family members should be screened with genetic testing once the familial pathogenic variant has been identified in the patient with AHP to identify patients at risk for acute attacks. Those who are mutation carriers should be counseled.

Although genetic testing is the gold standard for confirmation of diagnosis, it is not recommended for initial screening. Most carriers of pathogenic variants in AHP genes do not experience symptomatic acute attacks in their lifetimes. The estimated phenotypic penetrance of symptomatic disease is approximately 1% of AIP gene carriers,⁸ with a penetrance of >20% in families with symptomatic patients.⁷ HCP and VP are reported to have lower penetrance than AIP.²⁸ Even among patients with a confirmed pathogenic variant, attribution of clinical symptoms often benefits from biochemical confirmation (Table 2).

Best Practice Advice 4: Acute attacks of AHP that are severe enough to require hospital admission should be treated with intravenous hemin, given daily, preferably into a high-flow central vein.

The currently approved treatment for acute attacks is intravenous hemin infusion,^{29–33} usually given once daily at a dose of 3–4 mg/kg body weight, typically for 4 days. Hemin rapidly down-regulates ALAS1 expression in the liver, thus ameliorating the continued overproduction and accumulation of ALA and PBG. Symptom relief depends on elimination of excess ALA and PBG and typically requires 48–72 hours, although recovery from neurologic symptoms can vary significantly. Timely initiation of hemin therapy results in normalization of ALA and PBG levels, symptom improvement, and decreased risk of long-term neurologic complications.

A random urine for ALA, PBG, and creatinine should be collected before the start of hemin treatment. Due to the lack of available rapid ALA or PBG tests, initiation of hemin can be made on empirical grounds in patients with confirmed AHP. Because of potential thrombophlebitis from hemin, it is best given into a high-flow central vein via a peripherally inserted central catheter or central port. In addition, heme bound to human serum albumin is preferred due to heme stabilization and less irritation to veins.³⁴

Best Practice Advice 5: In addition to intravenous hemin, management of acute attacks of AHP should include pain control, antiemetics, management of systemic arterial hypertension, tachycardia, and hyponatremia and hypomagnesemia, if present.

The primary goal of treatment during an acute attack is to decrease ALA production. Identifiable precipitating factors, such as medications that induce cytochrome P450s, should be stopped, as they can directly up-regulate ALAS1 messenger RNA. Severe pain and nausea should be treated aggressively with analgesics and antiemetics. Intravenous carbohydrate loading (approximately 300 g/d in adults) is commonly used during the early stages of acute attacks, as studies have shown that fasting induces expression of peroxisome proliferator-activated receptor γ coactivator 1- α , which induces expression of ALAS1.³⁵

Acute attacks can be associated with hyponatremia and hypomagnesemia due to a combination of hypovolemia and syndrome of inappropriate antidiuretic hormone secretion.^{36,37} Electrolytes should be monitored during acute attacks and hyponatremia corrected slowly if present.

In acute attacks that present with seizures, management should be approached with caution because many anticonvulsant medications, such as barbiturates, hydantoins, carbamazepine, and valproic acid, are contraindicated in AHP.³⁸ Magnesium sulfate, benzodiazepines, and levetiracetam appear to be safe options in the context of AHP.

Best Practice Advice 6: Patients should be counseled to avoid identifiable triggers that may precipitate acute attacks, such as alcohol and porphyrinogenic medications.

The low penetrance of AHPs indicates the likely presence of additional factors that are required for clinical symptoms, including precipitating factors and other poorly defined modifying genes and/or epigenetic factors.^{39,40} Sex hormones, in particular progesterone, are known to precipitate attacks. Other common precipitating factors include medications that induce cytochrome P450, acute illness or infection, physical or psychological stress, excess alcohol intake, tobacco use, and caloric deprivation. These factors induce hepatocyte ALAS1 messenger RNA and protein expression.^{35,41–43} All patients with AHP should be counseled to avoid identifiable triggers. Lists of safe and unsafe drugs are available online (<https://www.porphyrria.org/patient-resources/drug-safety-database-for-ahp/> and <http://www.drugs-porphyrria.org/>).

Best Practice Advice 7: Prophylactic heme therapy or givosiran, administered in an outpatient setting, should be considered in patients with recurrent attacks (4 or more per year).

Despite the improvement in management of acute attacks, treatment for patients with AHP with recurrent attacks remains challenging. Many patients are women who may experience menstrual cycle–associated attacks, which can be treated with hormonal suppression therapy, such as GnRH agonists, but with limited success.⁴⁴

Off-label use of prophylactic intravenous hemin infusion is common.^{1,45,46} Although hemin is effective at stopping acute attacks, its effectiveness in preventing recurrent attacks is less established. In addition, chronic hemin use is associated with several complications, including the need for indwelling central venous catheters, infections, and iron overload. Patients receiving prophylactic hemin therapy should be screened for iron overload (see Best Practice Advice statement 9).

Recently, a novel small interfering RNA–based therapy targeting ALAS1 was approved by the US Food and Drug Administration and European Medicines Agency for treatment of adults with AHP (United States) or person 12 years and older (European Union).^{47,48} Givosiran is an ALAS1-specific small interfering RNA covalently linked to N-acetyl galactosamine that is administered subcutaneously and taken up selectively by hepatocytes via the asialoglycoprotein receptor.⁴⁹ After uptake into hepatocytes, the small interfering RNA is processed by the cellular enzyme Dicer into approximately 20-bp-long single strands, which bind to ALAS1 messenger RNA and targets it for destruction, resulting in reduced translation of ALAS1 and decreased ALA production.⁵⁰ In a phase 3, randomized, double-blinded, placebo-controlled study of patients with AHP with recurrent attacks, monthly subcutaneous givosiran significantly lowered rates of acute attacks that correlated with lower urine ALA and PBG levels.^{47,51} A significant proportion of patients on givosiran were free of attacks.^{51,52} We suggest prescribing givosiran only for those patients with

recurrent acute attacks that are both biochemically and genetically confirmed. Due to limited safety data, givosiran should not be used in women who are pregnant or planning a pregnancy. Patients on givosiran should be screened and monitored for elevations in liver enzymes, serum blood urea nitrogen and creatinine, homocysteine, amylase, and lipase.⁵²

Best Practice Advice 8: Liver transplantation for AHP should be limited to patients with intractable symptoms and significantly decreased quality of life who are refractory to pharmacotherapy.

Liver transplantation has been successful in treating patients severely affected with AIP in reports from the United States and Europe.^{42,53,54} The primary rationale for the role of liver transplantation is that it corrects the HMBS deficiency in the liver of patients with AIP and restores normal PBG and ALA levels with resolution of clinical symptoms. Liver transplantation has been found to be curative in both the United States and Europe for patients with recurrent attacks refractory to treatment.^{42,55} Urinary ALA and PBG levels normalize after transplantation and some improvements in chronic symptoms, including peripheral neuropathy, have been reported.

In a recent report from Europe, retrospective data from the European Liver Transplant Registry were used to report on 38 liver transplant recipients (including 5 liver-kidney recipients) at centers across 12 countries in 2002–2019.⁵⁶ Liver transplantations were deemed curative in all cases, except 1 patient who received an auxiliary transplant, and overall were associated with elimination of AIP attacks and significant improvement in neurologic complications. The 1-year and 5-year overall survival rates were 92% and 82%, respectively, with poorer outcomes in patients with severe neuropathy and/or renal dysfunction at baseline. As AHPs are predominantly autosomal dominant with low penetrance, carriers of pathogenic variants may be asymptomatic. If living donor transplantation is considered, genetic testing should be used to screen related living donors, as HMBS pathogenic variants in asymptomatic living donors may result in poor post-transplantation outcomes.⁵⁷ Transplantation should ideally be performed in centers with experience with AHP, including preoperative management with hemin.

Best Practice Advice 9: Patients with AHP should be monitored annually for liver disease.

Liver enzymes can be elevated in approximately 13% of patients with AHP during acute attacks and in some patients without clinical symptoms.^{30,58} In the ENVISION clinical trial of patients with recurrent AHP attacks, baseline serum aminotransferase elevations were reported in 28% of patients.⁴⁷ Although chronic liver fibrosis and cirrhosis have been reported in patients with AHP, the cause of liver enzyme elevation and liver fibrosis is not well defined and, therefore, abnormal liver enzymes should prompt diagnostic investigation for alternative etiologies.⁵⁹ In some cases, a liver biopsy may help diagnose concomitant conditions, such as nonalcoholic steatohepatitis, iron overload, or other causes.⁶⁰

In addition, chronic hemin administration (9% iron by weight) can result in secondary iron overload with liver fibrosis. Liver enzymes should be monitored at least annually in AHP patients actively undergoing treatment. In patients receiving prophylactic hemin therapy at least monthly, ferritin and iron levels should be monitored every 3–6 months. In patients with ferritin levels >1000 ng/mL, therapeutic phlebotomy should be considered to reduce iron overload.⁶⁰ Serum alanine aminotransferase elevation >3× the upper limit of normal has been reported in patients treated with givosiran during the first 3–6 months of treatment and, therefore, clinicians should monitor liver enzymes monthly during this period.⁴⁷ If laboratory monitoring reveals normal findings, monitoring frequency may be decreased gradually to twice per year.

Best Practice Advice 10: Patients with AHP, regardless of the severity of symptoms, should undergo surveillance for HCC, beginning at age 50 years, with liver ultrasound every 6 months.

Patients with AHP experience an increased risk of HCC (and cholangiocarcinoma), with risk estimates ranging from 1.5% to 1.8% in studies from the United States and Europe.^{17,18,59,61–64} Most cases of HCC have been reported in patients with AIP, whereas risk estimates in patients with VP and HCP forms are unknown. A meta-analysis of HCC in AHP confirmed a significant female predominance (2.5 times higher than in male patients), and several studies have revealed that HCC may occur in the absence of liver fibrosis or cirrhosis.⁶⁴ Although HCC risk appears to be higher in clinically and biochemically active patients, it has also been reported in asymptomatic patients.⁶³ Most studies identified HCC in patients with AHP who are older than 50 years. The role of α -fetoprotein in HCC surveillance in AHP is unclear, as α -fetoprotein elevation is not routinely observed in patients with high tumor burden. However, based on the estimated HCC risk of >1.5% in patients with AHP, HCC surveillance should begin at age 50 years with liver ultrasound every 6 months.^{54,63}

Best Practice Advice 11: Patients with AHP on treatment should undergo surveillance for chronic kidney disease annually with serum creatinine and estimated glomerular filtration rate.

The risk of chronic kidney disease (CKD) and hypertension is increased in patients with AIP. In the longitudinal study of the US Porphyrrias Consortium, which enrolled symptomatic, asymptomatic, and latent carriers of AHP, CKD and hypertension were reported in 29% and 43% of patients, respectively.¹⁹ Systemic arterial hypertension is often seen during acute attacks and can result in chronic hypertension in some patients. In a report from France, porphyria-associated kidney disease (PAKD) occurred in up to 59% of the patients with symptomatic AIP, with an annual decline in the glomerular filtration rate of approximately 1 mL/min per 1.73 m², and among patients with PAKD, approximately 60% had concomitant hypertension.¹⁵ PAKD is postulated to occur due to ALA and PBG-mediated endoplasmic reticulum stress, apoptosis, and epithelial phenotypic changes in proximal tubular cells leading to renal injury.^{15,65} In addition, it has been reported that a

variant of the human peptide transporter 2 expressed by proximal tubular cells that mediate the reabsorption of ALA is an independent risk factor in developing PAKD.⁶⁶

In the EXPLORE prospective multinational natural history study of patients with recurrent AHP attacks, 68% experienced reduced estimated glomerular filtration rate (eGFR) during the study,¹⁰ and 28% met the criteria for stage 3a, 3b, or 4 CKD, based on eGFR levels. Importantly, therapeutic interventions, such as givosiran, may be associated with worsening eGFR and renal function in a subset of patients based on ENVISION clinical trial and real-world data.^{47,67}

Kidney transplantation is the treatment of choice for patients with end-stage renal disease secondary to AHP, as ALA and PBG levels can increase significantly between dialysis sessions.¹⁴ Immunosuppressive therapy post transplantation is generally well tolerated, and studies of kidney transplant recipients with AHP confirmed a significant improvement in clinical AHP symptoms, which is attributed to increased ALA and PBG clearance after transplantation.⁶⁸

Based on these studies, serum creatinine and eGFR should be monitored at least annually in patients with AHP and more frequently in patients on givosiran.⁶⁰ In addition, optimal control of systemic arterial hypertension is recommended to decrease additional risk factors for CKD.^{15,60}

Best Practice Advice 12: Patients should be counseled on the chronic and long-term complications of AHP, including neuropathy, CKD, hypertension, and HCC, and need for long-term monitoring.

The AHPs are chronic multisystem disorders that require ongoing monitoring and active management. Patients with recurrent attacks have a high chronic disease burden, including chronic nausea, fatigue, neuropathy, and kidney disease.^{10,19,60} In the EXPLORE natural history study, 65% of patients with recurrent attacks reported chronic symptoms, most commonly pain, fatigue, anxiety, and nausea, with 46% reporting daily symptoms.¹⁰ Quality of life is decreased considerably, with high rates of depression, anxiety, and insomnia.^{10,12} Although the disease burden in patients who are clinically asymptomatic with elevated levels of porphyrin precursors is not well defined, these patients may also experience an increased risk of CKD and HCC, and merit annual monitoring. Patients on chronic hemin or givosiran require close follow-up for adverse effects and treatment response.⁶⁰

In conclusion, AHPs are diseases due to inherited partial defects in enzyme of porphyrin and heme synthesis. They are not as rare as previously thought. Fortunately, most people with genetic defects never experience severe acute attacks or may experience only one or a few attacks throughout their lives. Acute attacks, however, do occur, especially in women aged approximately 15–50 years, and some of these women experience monthly symptoms during the luteal phase of their menstrual cycles. The key to early diagnosis is to consider the diagnosis, especially in patients with recurring severe abdominal pain not ascribable to other causes. The key diagnostic test is a spot urine for ALA, PBG, porphyrins, and creatinine. Treatment of acute attacks should be with intravenous hemin given by peripherally inserted

central catheter line or central port, 3–4 mg/kg body weight/d for 3–5 days. Givosiran should be considered in patients with biochemically and genetically documented AHP and with frequent attacks (4 or more per year). Long-term risks of AHPs include systemic arterial hypertension, chronic liver and renal diseases, and development of HCC, even in the absence of cirrhosis. Patients should have ongoing assessments for such potential complications.

Funding

The Porphyrias Consortium (U54DK083909) is part of Rare Diseases Clinical Research Network, an initiative of the Office of Rare Diseases Research, National Center for Advancing Translational Sciences (NCATS). This consortium is funded through collaboration between NCATS and National Institute of Diabetes and Digestive and Kidney Diseases.

Conflicts of interest

The authors disclose the following: Bruce Wang has received clinical trial support (to institution) from Alnylam and Mitsubishi-Tanabe, and honoraria for participation in advisory boards from Alnylam, Mitsubishi-Tanabe, and Disc Medicine. Herbert L. Bonkovsky has received clinical trial support (to institution) from Alnylam, Genkyotex, Gilead Sciences, and Intercept Pharma, Mitsubishi-Tanabe, and honoraria for participation in advisory boards from Alnylam, Disc Medicine, Eiger Biopharma, Mitsubishi-Tanabe, and Protagonist Therapeutics. Joseph K. Lim has received research support (to institution) from Allergan, Celgene, Genfit, Gilead, Intercept, Pfizer, and Viking. Manisha Balwani has received clinical trial support (to institution) from Alnylam and Mitsubishi-Tanabe and honoraria for participation in advisory boards from Alnylam, Mitsubishi-Tanabe, and Disc medicine.

Abbreviations used in this paper:

AHP	acute hepatic porphyria
AIP	acute intermittent porphyria
ALA	δ -aminolevulinic acid
ALAD	5-aminolevulinic acid dehydratase deficiency porphyria
CKD	chronic kidney disease
eGFR	estimated glomerular filtration rate
HCC	hepatocellular carcinoma
HCP	hereditary coproporphyrin
HMBS	hydroxymethylbilane synthase
PAKD	porphyria-associated kidney disease
PBG	porphobilinogen
VP	variegate porphyria

References

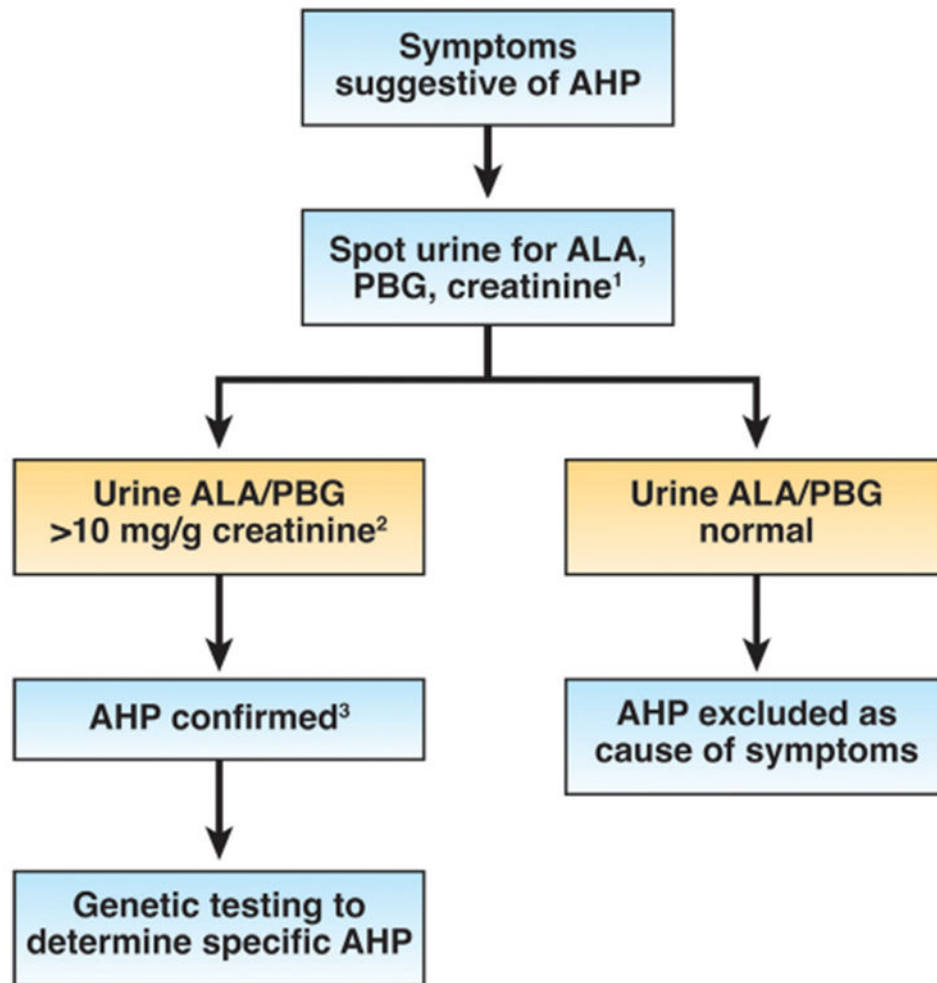
1. Bissell DM, Anderson KE, Bonkovsky HL. Porphyria. *N Engl J Med* 2017;377:862–872. [PubMed: 28854095]
2. Puy H, Gouya L, Deybach JC. Porphyrias. *Lancet* 2010;375(9718):924–937. [PubMed: 20226990]

3. Doss M, von Tieperman R, Schneider J, et al. New type of hepatic porphyria with porphobilinogen synthase defect and intermittent acute clinical manifestation. *Klin Wochenschr* 1979;57:1123–1127. [PubMed: 513604]
4. Doss MO, Stauch T, Gross U, et al. The third case of Doss porphyria (delta-amino-levulinic acid dehydratase deficiency) in Germany. *J Inherit Metab Dis* 2004;27:529–536. [PubMed: 15303011]
5. Thunell S, Holmberg L, Lundgren J. Aminolaevulinate dehydratase porphyria in infancy. A clinical and biochemical study. *J Clin Chem Clin Biochem* 1987;25:5–14. [PubMed: 3559484]
6. Akagi R, Kato N, Inoue R, et al. delta-Aminolevulinate dehydratase (ALAD) porphyria: the first case in North America with two novel ALAD mutations. *Mol Genet Metab* 2006;87:329–336. [PubMed: 16343966]
7. Lenglet H, Schmitt C, Grange T, et al. From a dominant to an oligogenic model of inheritance with environmental modifiers in acute intermittent porphyria. *Hum Mol Genet* 2018;27:1164–1173. [PubMed: 29360981]
8. Chen B, Solis-Villa C, Hakenberg J, et al. Acute intermittent porphyria: predicted pathogenicity of HMBS variants indicates extremely low penetrance of the autosomal dominant disease. *Hum Mutat* 2016;37:1215–1222. [PubMed: 27539938]
9. Wang B, Ventura P, Takase K-I, et al. Disease burden in patients with acute hepatic porphyria: experience from the phase 3 ENVISION study. *Orphanet J Rare Dis* 2022;17:327. [PubMed: 36028858]
10. Gouya L, Ventura P, Balwani M, et al. EXPLORE: a prospective, multinational, natural history study of patients with acute hepatic porphyria with recurrent attacks. *Hepatology* 2020;71:1546–1558. [PubMed: 31512765]
11. Simon A, Pompilus F, Querbes W, et al. Patient perspective on acute intermittent porphyria with frequent attacks: a disease with intermittent and chronic manifestations. *Patient* 2018;11:527–537. [PubMed: 29915990]
12. Naik H, Stoecker M, Sanderson SC, et al. Experiences and concerns of patients with recurrent attacks of acute hepatic porphyria: a qualitative study. *Mol Genet Metab* 2016;119:278–283. [PubMed: 27595545]
13. Peoc'h K, Manceau H, Karim Z, et al. Hepatocellular carcinoma in acute hepatic porphyrias: a Damocles sword. *Mol Genet Metab* 2019;128:236–241. [PubMed: 30413387]
14. Sardh E, Andersson DEH, Henrichson A, et al. Porphyrin precursors and porphyrins in three patients with acute intermittent porphyria and end-stage renal disease under different therapy regimes. *Cell Mol Biol (Noisy-le-grand)* 2009;55:66–71. [PubMed: 19268004]
15. Pallet N, Mami I, Schmitt C, et al. High prevalence of and potential mechanisms for chronic kidney disease in patients with acute intermittent porphyria. *Kidney Int* 2015;88:386–395. [PubMed: 25830761]
16. Sardh E, Harper P, Balwani M, et al. Phase 1 trial of an RNA interference therapy for acute intermittent porphyria. *N Engl J Med* 2019;380:549–558. [PubMed: 30726693]
17. Sardh E, Wahlin S, Björnstedt M, et al. High risk of primary liver cancer in a cohort of 179 patients with acute hepatic porphyria. *J Inherit Metab Dis* 2013;36:1063–1071. [PubMed: 23344888]
18. Andant C, Puy H, Bogard C, et al. Hepatocellular carcinoma in patients with acute hepatic porphyria: frequency of occurrence and related factors. *J Hepatol* 2000;32:933–939. [PubMed: 10898313]
19. Bonkovsky HL, Maddukuri VC, Yazici C, et al. Acute porphyrias in the USA: features of 108 subjects from porphyrias consortium. *Am J Med* 2014;127:1233–1241. [PubMed: 25016127]
20. Davis JR, Andelman SL. Urinary delta-aminolevulinic acid (ALA) levels in lead poisoning. I. A modified method for the rapid determination of urinary delta-aminolevulinic acid using disposable ion-exchange chromatography columns. *Arch Environ Health* 1967;15:53–59. [PubMed: 4951694]
21. Zhang J, Yasuda M, Desnick RJ, et al. A LC-MS/MS method for the specific, sensitive, and simultaneous quantification of 5-aminolevulinic acid and porphobilinogen. *J Chromatogr B Analyt Technol Biomed Life Sci* 2011;879:2389–2396.
22. Benton CM, Couchman L, Marsden JT, et al. Direct and simultaneous quantitation of 5-aminolaevulinic acid and porphobilinogen in human serum or plasma by hydrophilic interaction

- liquid chromatography-atmospheric pressure chemical ionization/tandem mass spectrometry. *Biomed Chromatogr* 2013;27:267–272. [PubMed: 23180457]
23. Pierach CA, Cardinal R, Bossenmaier I, et al. Comparison of the Hoesch and the Watson-Schwartz tests for urinary porphobilinogen. *Clin Chem* 1977;23:1666–1668. [PubMed: 890911]
 24. Marsden JT, Rees DC. Urinary excretion of porphyrins, porphobilinogen and delta-aminolaevulinic acid following an attack of acute intermittent porphyria. *J Clin Pathol* 2014;67:60–65. [PubMed: 23908454]
 25. Andersson C, Thunell S, Floderus Y, et al. Diagnosis of acute intermittent porphyria in northern Sweden: an evaluation of mutation analysis and biochemical methods. *J Intern Med* 1995;237:301–308. [PubMed: 7891051]
 26. Kauppinen R, Von und zu Fraunberg M. Molecular and biochemical studies of acute intermittent porphyria in 196 patients and their families. *Clin Chem* 2002;48:1891–1900. [PubMed: 12406973]
 27. Whatley SD, Mason NG, Woolf JR, et al. Diagnostic strategies for autosomal dominant acute porphyrias: retrospective analysis of 467 unrelated patients referred for mutational analysis of the HMBS, CPOX, or PPOX gene. *Clin Chem* 2009;55:1406–1414. [PubMed: 19460837]
 28. Hift RJ, Meissner PN. An analysis of 112 acute porphyric attacks in Cape Town, South Africa: evidence that acute intermittent porphyria and variegate porphyria differ in susceptibility and severity. *Medicine (Baltimore)* 2005;84:48–60. [PubMed: 15643299]
 29. Bissell DM. Treatment of acute hepatic porphyria with hematin. *J Hepatol* 1988;6:1–7. [PubMed: 3346530]
 30. Stein JA, Tschudy DP. Acute intermittent porphyria. A clinical and biochemical study of 46 patients. *Medicine (Baltimore)* 1970;49:1–16. [PubMed: 4907358]
 31. Bonkowsky HL, Tschudy DP, Collins A, et al. Repression of the overproduction of porphyrin precursors in acute intermittent porphyria by intravenous infusions of hematin. *Proc Natl Acad Sci U S A* 1971;68:2725–2729. [PubMed: 5288250]
 32. Lamon JM, Frykholm BC, Hess RA, et al. Hematin therapy for acute porphyria. *Medicine (Baltimore)* 1979;58:252–269. [PubMed: 449661]
 33. Watson CJ, Pierach CA, Bossenmaier I, et al. Postulated deficiency of hepatic heme and repair by hematin infusions in the “inducible” hepatic porphyrias. *Proc Natl Acad Sci U S A* 1977;74:2118–2120. [PubMed: 266732]
 34. Anderson KE, Bonkowsky HL, Bloomer JR, et al. Reconstitution of hematin for intravenous infusion. *Ann Intern Med* 2006;144:537–538. [PubMed: 16585674]
 35. Handschin C, Lin J, Rhee J, et al. Nutritional regulation of hepatic heme biosynthesis and porphyria through PGC-1 α . *Cell* 2005;122:505–515. [PubMed: 16122419]
 36. Eales L, Dowdle EG, Sweeney GD. The acute porphyric attack. I. The electrolyte disorder of the acute porphyric attack and the possible role of delta-aminolaevulinic acid. *S Afr Med J* 1971;89–97. [PubMed: 5150300]
 37. Meersseman W, Cassiman D, Goossens W, et al. An unusual cause of syndrome of inappropriate antidiuretic hormone secretion. *Acta Clin Belg* 2008;63:277–280. [PubMed: 19048708]
 38. Hahn M, Gildemeister OS, Krauss GL, et al. Effects of new anticonvulsant medications on porphyrin synthesis in cultured liver cells: potential implications for patients with acute porphyria. *Neurology* 1997;49:97–106. [PubMed: 9222176]
 39. Yasuda M, Lin G, Chen B, et al. Homozygous hydroxymethylbilane synthase knock-in mice provide pathogenic insights into the severe neurological impairments present in human homozygous dominant acute intermittent porphyria. *Hum Mol Genet* 2019;28:1755–1767. [PubMed: 30615115]
 40. Barreda-Sanchez M, Buendía-Martínez J, Glover-López G, et al. High penetrance of acute intermittent porphyria in a Spanish founder mutation population and CYP2D6 genotype as a susceptibility factor. *Orphanet J Rare Dis* 2019;14:59. [PubMed: 30808393]
 41. Yasuda M, Chen B, Desnick RJ. Recent advances on porphyria genetics: inheritance, penetrance & molecular heterogeneity, including new modifying/causative genes. *Mol Genet Metab* 2019;128:320–331. [PubMed: 30594473]

42. Yasuda M, Erwin AL, Liu LU, et al. Liver transplantation for acute intermittent porphyria: biochemical and pathologic studies of the explanted liver. *Mol Med* 2015;21:487–495. [PubMed: 26062020]
43. Schmitt C, Lenglet H, Yu A, et al. Recurrent attacks of acute hepatic porphyria: major role of the chronic inflammatory response in the liver. *J Intern Med* 2018;284:78–91. [PubMed: 29498764]
44. Schulenburg-Brand D, Gardiner T, Guppy S, et al. An audit of the use of gonadorelin analogues to prevent recurrent acute symptoms in patients with acute porphyria in the United Kingdom. *JIMD Rep* 2017;36:99–107. [PubMed: 28220410]
45. Kuo HC, Lin CN, Tang YF. Prophylactic heme arginate infusion for acute intermittent porphyria. *Front Pharmacol* 2021;12:712305. [PubMed: 34690757]
46. Yarra P, Faust D, Bennett M, et al. Benefits of prophylactic heme therapy in severe acute intermittent porphyria. *Mol Genet Metab Rep* 2019;19:100450. [PubMed: 30733921]
47. Balwani M, Sardh E, Ventura P, et al. Phase 3 trial of RNAi therapeutic givosiran for acute intermittent porphyria. *N Engl J Med* 2020;382:2289–2301. [PubMed: 32521132]
48. US Food and Drug Administration. FDA approves givosiran for acute hepatic porphyria. Updated November 20, 2019. Available at: <https://www.fda.gov/drugs/resources-information-approved-drugs/fda-approves-givosiran-acute-hepatic-porphyrin>. Accessed XXXX.
49. Chan A, Liebow A, Yasuda M, et al. Preclinical development of a subcutaneous ALAS1 RNAi therapeutic for treatment of hepatic porphyrias using circulating RNA quantification. *Mol Ther Nucleic Acids* 2015;4:e263. [PubMed: 26528940]
50. Majeed CN, Ma CD, Xiao T, et al. Spotlight on givosiran as a treatment option for adults with acute hepatic porphyria: design, development, and place in therapy. *Drug Des Devel Ther* 2022;16:1827–1845.
51. Ventura P, Bonkovsky HL, Gouya L, et al. Efficacy and safety of givosiran for acute hepatic porphyria: 24-month interim analysis of the randomized phase 3 ENVISION study. *Liver Int* 2022;42:161–172. [PubMed: 34717041]
52. Poli A, Schmitt C, Moulouel B, et al. Givosiran in acute intermittent porphyria: a personalized medicine approach. *Mol Genet Metab* 2022;135:206–214. [PubMed: 35058124]
53. Dowman JK, Gunson BK, Mirza DF, et al. Liver transplantation for acute intermittent porphyria is complicated by a high rate of hepatic artery thrombosis. *Liver Transpl* 2012;18:195–200. [PubMed: 21618697]
54. Singal AK, Parker C, Bowden C, et al. Liver transplantation in the management of porphyria. *Hepatology* 2014;60:1082–1089. [PubMed: 24700519]
55. Soonawalla ZF, Orug T, Badminton MN, et al. Liver transplantation as a cure for acute intermittent porphyria. *Lancet* 2004;363(9410):705–706. [PubMed: 15001330]
56. Lissing M, Nowak G, Adam R, et al. Liver transplantation for acute intermittent porphyria. *Liver Transpl* 2021;27:491–501. [PubMed: 33259654]
57. Al-Samkari H, Patel AA, Schiano TD, et al. Recurrence of acute intermittent porphyria after liver transplantation. *Ann Intern Med* 2019;170:904–905. [PubMed: 30716770]
58. Bylesjo I, Wikberg A, Andersson C. Clinical aspects of acute intermittent porphyria in northern Sweden: a population-based study. *Scand J Clin Lab Invest* 2009;69:612–618. [PubMed: 19401933]
59. Innala E, Andersson C. Screening for hepatocellular carcinoma in acute intermittent porphyria: a 15-year follow-up in northern Sweden. *J Intern Med* 2011;269:538–545. [PubMed: 21198994]
60. Balwani M, Wang B, Anderson KE, et al. Acute hepatic porphyrias: recommendations for evaluation and long-term management. *Hepatology* 2017;66:1314–1322. [PubMed: 28605040]
61. Andersson C, Bjersing L, Lithner F. The epidemiology of hepatocellular carcinoma in patients with acute intermittent porphyria. *J Intern Med* 1996;240:195–201. [PubMed: 8918510]
62. Saberi B, Naik H, Overbey JR, et al. Hepatocellular carcinoma in acute hepatic porphyrias: results from the longitudinal study of the U.S. Porphyrins Consortium. *Hepatology* 2021;73:1736–1746. [PubMed: 32681675]
63. Lissing M, Vassiliou D, Floderus Y, et al. Risk of primary liver cancer in acute hepatic porphyria patients: a matched cohort study of 1244 individuals. *J Intern Med* 2022;291:824–836. [PubMed: 35112415]

64. Baravelli CM, Sandberg S, Aarsand AK, et al. Acute hepatic porphyria and cancer risk: a nationwide cohort study. *J Intern Med* 2017;282:229–240. [PubMed: 28730628]
65. Pallet N, Karras A, Thervet E, et al. Porphyria and kidney diseases. *Clin Kidney J* 2018;11:191–197. [PubMed: 29644058]
66. Tchernitchko D, Tavernier Q, Lamoril J, et al. A variant of peptide transporter 2 predicts the severity of porphyria-associated kidney disease. *J Am Soc Nephrol* 2017;28:1924–1932. [PubMed: 28031405]
67. Lazareth H, Poli A, Bignon Y, et al. Renal function decline with small interfering RNA silencing aminolevulinic acid synthase 1 (ALAS1). *Kidney Int Rep* 2021;6:1904–1911. [PubMed: 34307985]
68. Lazareth H, Talbi N, Kamar N, et al. Kidney transplantation improves the clinical outcomes of acute intermittent porphyria. *Mol Genet Metab* 2020;131:259–266. [PubMed: 32893121]



¹Urine total porphyrins are not recommended as a screening test for AHP. Testing is most informative if done while patients are symptomatic.

²If only ALA is elevated, check lead level and urine organic acids to rule out lead poisoning and hereditary tyrosinemia.

³If clinically indicated, treatment for symptoms with hemin should be started promptly once AHP diagnosis is confirmed.

Figure 1.
Diagnostic workflow for AHP.

Table 1.

Summary of Acute Hepatic Porphyrrias

AHP type	Inheritance	Age at presentation	Gender predominance	Symptoms and signs
AIP	AD	15–50 y	F > M	Acute
HCP	AD	15–50 y	F > M	Acute, cutaneous
VP	AD	15–50 y	F > M	Acute, cutaneous
ALAD	AR	Childhood-adulthood	M > F	Acute

AD, autosomal dominant; AR, autosomal recessive; F, female; M, male.

Table 2.

Testing Recommendations for Acute Hepatic Porphyrrias

Diagnostic biochemical testing	Confirmatory testing	Annual Monitoring	Monitoring on hemin ^a	Monitoring on givosiran ^{a,b}
Random urine PBG, ALA, and creatinine ^c	Genetic testing by sequencing <i>ALAD</i> , <i>HMBS</i> , <i>CPOX</i> , and <i>PPOX</i>	Liver enzymes, creatinine and eGFR, liver ultrasound, and α -fetoprotein every 6 mo after age 50 y	Iron, ferritin	Comprehensive metabolic panel, plasma homocysteine urinalysis; urinary protein to creatinine ratio, B12/folate, amylase/lipase

^a Additional tests for patients receiving prophylactic hemin therapy or givosiran.

^b We recommend that the listed tests be performed before the start of givosiran and again just before each monthly injection of givosiran for 3 months. If the laboratory test results are stable and the drug is being well-tolerated, we recommend that laboratory monitoring be repeated once every 3 months for the next year and at least once every 6 months thereafter.

^c Sample should be normalized to creatinine, levels should be >5-fold the upper limit of normal for diagnosis. In 5-aminolevulinic acid dehydratase only ALA is elevated.