

Available online at www.sciencedirect.com

ScienceDirect

journal homepage: www.elsevier.com/locate/radcr

Case report

Direct percutaneous access to a mesenteric vein for antegrade embolization of esophageal varices: A case report [☆]

Yasuyuki Onishi, MD^{1,*}, Hironori Shimizu, MD¹, Shigeru Tsunoda, MD², Kazutaka Obama, MD², Yuji Nakamoto, MD¹

¹Department of Diagnostic Imaging and Nuclear Medicine, Kyoto University Graduate School of Medicine, Kyoto, Japan

²Department of Surgery, Kyoto University Graduate School of Medicine, Kyoto, Japan

ARTICLE INFO

Article history:

Received 1 June 2021

Accepted 7 June 2021

Keywords:

Embolization

Esophageal varices

Mesenteric access

ABSTRACT

A 79-year-old woman with a history of advanced gastric cancer and portal vein tumor thrombus, treated with surgery and chemoradiotherapy, presented with hematemesis due to esophageal variceal bleeding around the esophagojejunal anastomosis. Endoscopic treatment was unsuccessful. Due to portal vein occlusion, percutaneous transhepatic access was difficult. Thus, the middle colic vein, which was dilated due to portal vein occlusion, was percutaneously punctured, and antegrade embolization of a jejunal vein feeding the varices was performed using a microcatheter through a 4-F dilator placed as a sheath. After embolization, the sheath was removed, and ultrasound-guided compression of the puncture site was performed. No bleeding complication occurred. Therefore, direct percutaneous access to a mesenteric vein is a viable alternative to transhepatic access.

© 2021 The Authors. Published by Elsevier Inc. on behalf of University of Washington.

This is an open access article under the CC BY-NC-ND license

(<http://creativecommons.org/licenses/by-nc-nd/4.0/>)

Introduction

Accessing the portal venous system is the first step in various interventional radiology procedures, including preoperative portal vein embolization, thrombolysis and thrombectomy of the portal venous system, antegrade embolization of varices, and percutaneous islet cell transplantation [1–4]. Percutaneous transhepatic access to an intrahepatic portal vein branch is the most common way to access the portal venous

system. In rare cases, this approach is ineffective, and another approach is necessary. We report a case of antegrade coil embolization of esophageal varices by direct percutaneous access to the middle colic vein.

Case report

A 79-year-old woman underwent total gastrectomy with distal pancreatectomy and splenectomy for advanced gastric

[☆] Acknowledgements: None

* Corresponding author.

E-mail address: goforawalktoday@yahoo.co.jp (Y. Onishi).

<https://doi.org/10.1016/j.radcr.2021.06.018>

1930-0433/© 2021 The Authors. Published by Elsevier Inc. on behalf of University of Washington. This is an open access article under the CC BY-NC-ND license (<http://creativecommons.org/licenses/by-nc-nd/4.0/>)

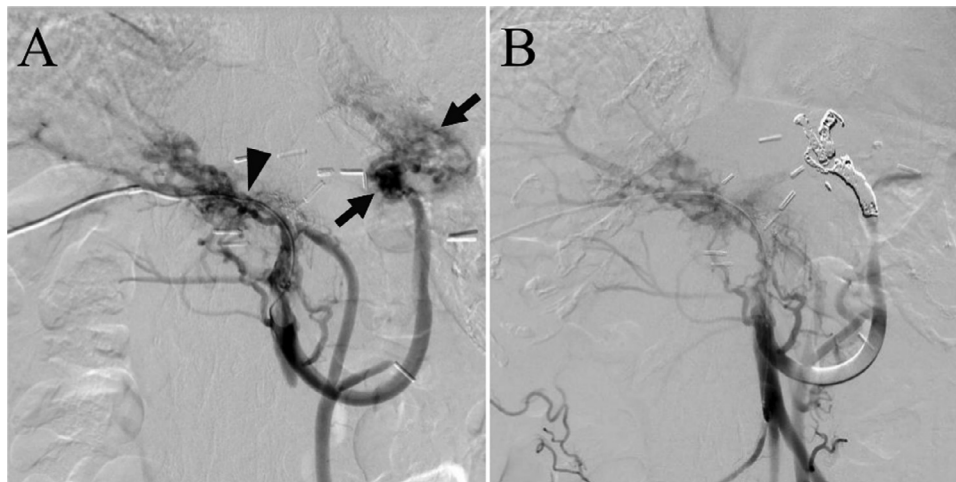


Fig. 1 – Angiography during previous percutaneous transhepatic variceal embolization. (A) Angiography from the superior mesenteric vein revealed esophageal varices (arrow) near the esophagojejunal anastomosis. The portal vein (arrowhead) is occluded, and a microcatheter was advanced to the superior mesenteric vein through a collateral vein around the portal vein. (B) Angiography from the superior mesenteric vein after coil embolization revealed no enhancement of the varices

cancer ten years ago. Portal vein tumor thrombus developed one year later, and was treated with radiation therapy and chemotherapy. Since then, gastric cancer has not recurred. Four years ago, she started experiencing recurrent episodes of hematemesis due to bleeding from the esophageal varices near the esophagojejunal anastomosis, which was treated by endoscopic hemostasis. Two years ago, endoscopic treatment failed to control the esophageal variceal bleeding. Based on the computed tomography (CT) findings, the varices were unsuitable for balloon-occluded retrograde transvenous obliteration. Thus, via percutaneous transhepatic access, a collateral vein around the occluded portal vein was inserted with difficulty using a microcatheter and a jejunal vein that fed the varices was embolized with microcoils (Fig. 1). Stent placement of the portal vein was discontinued due to the long occlusion and previous radiation exposure of the portal vein.

At this time, the patient presented with hematemesis for the first time in two years. During endoscopic hemostasis, massive hemorrhage from the esophageal varices near the anastomosis occurred, and hemostasis was achieved using a Sengstaken-Blakemore tube. Further endoscopic treatment was considered difficult, and percutaneous intervention was planned to prevent rebleeding from the varices. Her contrast-enhanced abdominal CT scan revealed that the middle colic vein was dilated, which was due to portal vein occlusion. It ran just below the peritoneum (Fig. 2). The vein was easily compressible because of its superficial course and adhesion caused by the previous surgery and radiation therapy (Fig. 3). Additionally, the intrahepatic portal vein branches were small due to portal vein occlusion. Therefore, we decided to access the middle colic vein. Under local anesthesia, the middle colic vein was punctured percutaneously using a 22-gauge coaxial needle (Fig. 4). The 0.018-inch wire in a micropuncture kit (Cook Medical, Bloomington, USA) was advanced, followed by placement of the 4-F coaxial dilator in the same kit into the middle colic vein as a sheath. Angiography of the previously embolized jejunal vein was ob-

tained using a microcatheter with a 2.2-F distal tip (Progreat β 3, Terumo, Tokyo, Japan), but the image was unclear due to rapid venous flow. The microcatheter was changed to a high-flow type microcatheter with a distal diameter of 2.85-F (Carry Leon high-flow; UTM, Nagoya, Japan). Angiography revealed recurrent esophageal varices (Fig. 5A). The jejunal vein was selected with the 2.2-F microcatheter, and embolization was performed with pushable microcoils. After embolization, angiography demonstrated no variceal enhancement (Fig. 5B). After removing the coaxial dilator, ultrasound-guided compression was applied to the puncture site for 10 minutes. Ultrasound showed no intra-abdominal hemorrhage, and the punctured vein was patent. There were no bleeding complications. Three weeks after the procedure, a moderate amount of ascites developed, which was managed conservatively. The patient has not experienced variceal bleeding for two months now.

Discussion

Access to the portal venous system is obtainable via several approaches, including percutaneous transhepatic access, ileocecal vein access with laparotomy, access through a transjugular intrahepatic portosystemic shunt (TIPS), percutaneous transsplenic access, and percutaneous paraumbilical vein access [5,6]. Direct percutaneous access to the portal venous system is another option. Few studies have described this technique [7-10]. Two studies have reported direct percutaneous access to the superior rectal vein for antegrade embolization of rectal varices [7, 8]. After embolization, N-butyl cyanoacrylate mixed with lipiodol was infused to prevent bleeding from the access site. One study reported the utility of direct superior or mesenteric access for portal vein recanalization and TIPS creation [9]. Hemostasis at the access site was not mentioned in this study. Another study reported a case of portal vein recanalization and TIPS creation

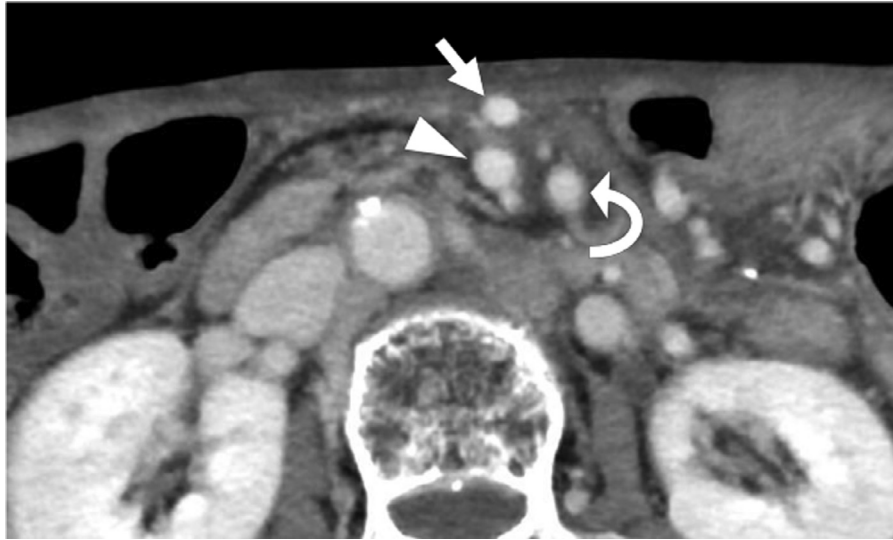


Fig. 2 – Contrast-enhanced computed tomography scan of the upper abdomen reveals that the middle colic vein (arrow) is dilated. The superior mesenteric vein (arrowhead) and the superior mesenteric artery (curved arrow) can also be appreciated in the scan

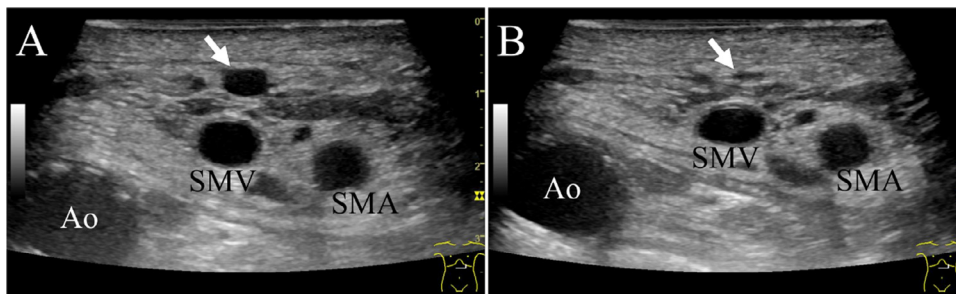


Fig. 3 – Abdominal ultrasound image of the middle colic vein. (A) Ultrasound reveals that the middle colic vein (arrow) is dilated and runs just below the peritoneum. (B) With the application of gentle compression using the ultrasound probe, the middle colic vein (arrow) is flattened. Ao; aorta, SMA; superior mesenteric artery, SMV; superior mesenteric vein

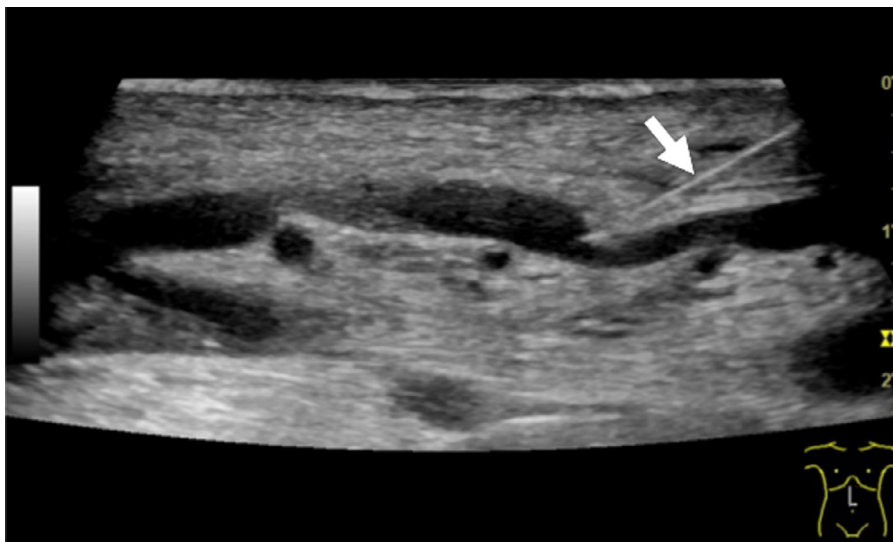

Fig. 4 – Direct percutaneous access to the middle colic vein. The ultrasound image reveals a 22-gauge needle (arrow) that hits the anterior wall of the middle colic vein

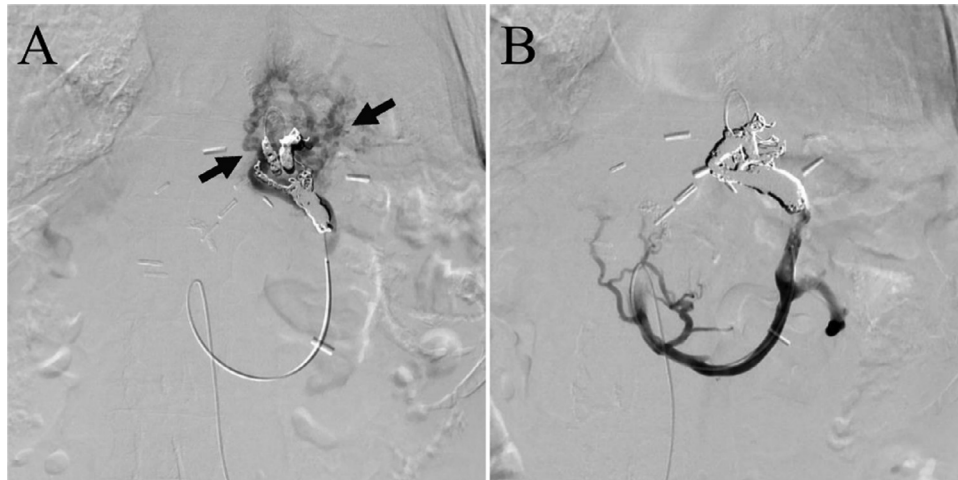


Fig. 5 – Angiography during variceal embolization via the direct percutaneous access through the middle colic vein. (A) Angiography of the previously embolized jejunal vein using a high-flow type microcatheter reveals recurrence of esophageal varices (arrows). (B) After additional coil embolization, the varices are no longer observed

using direct percutaneous access to a mesenteric vein [10]. After the procedure, a closure device was used at the access site to achieve hemostasis. In the present case, direct percutaneous access to the middle colic vein was used to embolize the esophageal varices. Intra-abdominal bleeding from the puncture site is a possible complication of direct percutaneous access to the portal venous system. In this case, a 4-F coaxial dilator was used as a sheath, and the mesenteric veins were evaluated by ultrasound to avoid intra-abdominal bleeding. The 4-F dilator is smaller than a 3-F vascular sheath but slightly larger than an 18-gauge sheathed needle, and a high-flow microcatheter can be advanced through the sheath, which is not feasible with an 18-gauge sheathed needle. In interventions using only microcatheters, the 4-F coaxial dilator is useful as a sheath to effectively reduce the size of the access site and decrease the risk of bleeding. We carefully evaluated the portomesenteric vein via ultrasound before the procedure and confirmed that the dilated middle colic vein was located just below the peritoneum and easily compressible. Manual compression after direct percutaneous mesenteric access is feasible when the vein is easily compressible on ultrasound and access is obtained with a small sheath.

In conclusion, the direct percutaneous approach to the mesenteric veins is a viable alternative approach in procedures involving easily compressible veins and a low-profile sheath.

Funding

This study was not supported by any funding.

Declarations of interest

None

Ethical approval

All procedures performed in studies involving human participants were in accordance with the ethical standards of the institutional and/or national research committee, and with the 1964 Helsinki declaration and its later amendments or comparable ethical standards. For this type of study, formal consent is not required.

Consent for publication

Consent for publication was obtained for the patient's data included in the study.

REFERENCES

- [1] Denys A, Bize P, Demartines N, Deschamps F, Baere De, Cardiovascular Tet al. Quality improvement for portal vein embolization. *Cardiovasc Intervent Radiol* 2010;33(3):452–6. doi:10.1007/s00270-009-9737-x.
- [2] Hidajat N, Stobbe H, Griesshaber V, Felix R, Schroder RJ. Imaging and radiological interventions of portal vein thrombosis. *Acta Radiol* 2005;46(4):336–43. doi:10.1080/02841850510021157.
- [3] Saad WE, Lippert A, Saad NE, Caldwell S. Ectopic varices: anatomical classification, hemodynamic classification, and hemodynamic-based management. *Tech Vasc Interv Radiol* 2013;16(2):158–75. doi:10.1053/j.tvir.2013.02.004.
- [4] Madoff DC, Gaba RC, Weber CN, Clark TW, Saad WE. Portal Venous Interventions: State of the Art. *Radiology* 2016;278(2):333–53. doi:10.1148/radiol.2015141858.
- [5] Chu HH, Kim HC, Jae HJ, Yi NJ, Lee KW, Suh KS, et al. Percutaneous transsplenic access to the portal vein for management of vascular complication in patients with chronic liver disease. *Cardiovasc Intervent Radiol* 2012;35(6):1388–95. doi:10.1007/s00270-011-0311-y.

- [6] Cho YJ, Kim HC, Kim YW, Hur S, Jae HJ, Chung JW. Percutaneous access via the recanalized paraumbilical vein for varix embolization in seven patients. *Korean J Radiol* 2014;15(5):630–6. doi:[10.3348/kjr.2014.15.5.630](https://doi.org/10.3348/kjr.2014.15.5.630).
- [7] Ono Y, Kariya S, Nakatani M, Yoshida R, Kono Y, Kan N, et al. Balloon-Occluded Antegrade Transvenous Sclerotherapy to Treat Rectal Varices: A Direct Puncture Approach to the Superior Rectal Vein Through the Greater Sciatic Foramen Under CT Fluoroscopy Guidance. *Cardiovasc Intervent Radiol* 2015;38(5):1320–4. doi:[10.1007/s00270-015-1174-4](https://doi.org/10.1007/s00270-015-1174-4).
- [8] Kariya S, Nakatani M, Maruyama T, Ono Y, Ueno Y, Shimizu H, et al. Sclerotherapy for Rectal Varices by a Small-Bore Needle Puncture Through the Greater Sciatic Foramen. *Cardiovasc Intervent Radiol* 2018;41(2):317–22. doi:[10.1007/s00270-017-1803-1](https://doi.org/10.1007/s00270-017-1803-1).
- [9] Entezari P, Riaz A, Thornburg B, Salem R. Percutaneous Ultrasound-Guided Superior and Inferior Mesenteric Vein Access for Portal Vein Recanalization-Transjugular Intrahepatic Portosystemic Shunt: A Case Series. *Cardiovasc Intervent Radiol* 2021;44(3):496–9. doi:[10.1007/s00270-020-02713-0](https://doi.org/10.1007/s00270-020-02713-0).
- [10] Farsad K, Zaman A. Percutaneous Transmesenteric Portal Vein Recanalization and Transjugular Direct Intrahepatic Portosystemic Shunt Creation for Chronic Portal Vein Occlusion. *J Vasc Interv Radiol* 2019;30(6):892–3. doi:[10.1016/j.jvir.2019.02.003](https://doi.org/10.1016/j.jvir.2019.02.003).