

Transcatheter Arterial Embolization Containing Donafenib Induces Anti-Angiogenesis and Tumoricidal CD8⁺ T-Cell Infiltration in Rabbit VX2 Liver Tumor

Qin Shi^{1,2,*}
Tongqiang Li^{1,2,*}
Songjiang Huang^{1,2,*}
Yaowei Bai^{1,2} 
Yingliang Wang^{1,2}
Jiacheng Liu^{1,2} 
Chen Zhou^{1,2}
Yang Chen^{1,2}
Bin Xiong^{1,2} 

¹Department of Radiology, Union Hospital, Tongji Medical College, Huazhong University of Science and Technology, Wuhan, 430022, People's Republic of China; ²Hubei Province Key Laboratory of Molecular Imaging, Wuhan, 430022, People's Republic of China

*These authors contributed equally to this work

Correspondence: Bin Xiong
Department of Radiology, Union Hospital, Tongji Medical College, Huazhong University of Science and Technology, Jiefang Avenue #1277, Wuhan, 430022, People's Republic of China
Email herr_xiong@126.com

Purpose: To evaluate the effect and immune response of transcatheter arterial embolization (TAE) combined with donafenib in rabbit VX2 liver tumor model.

Materials and Methods: Thirty-six New Zealand white rabbits with VX2 liver tumor were randomly divided into three groups. The LD group was treated with the emulsion of 0.5 mL lipiodol and 4 mg donafenib via hepatic arterial administration. The LE group was treated with the emulsion of 0.5 mL lipiodol and 4 mg epirubicin. The control group was treated with the equal volume of saline. Four rabbits were euthanized in each group on day 1, 3 and 7 after treatment. The tumor growth, histological markers associated with angiogenesis and immune response were assessed by imaging and histopathology. In addition, immune modulatory cytokines included interleukin (IL)-6, tumor necrosis factor (TNF)- α , interferon (IFN)- γ , and biochemical hepatorenal function were measured.

Results: Compared to other groups, LD group achieved lower tumor growth rate, fewer metastatic lesions, and higher tumor necrosis rate on day 7 after treatment. The percentage of CD31-positive area in the LD group was significantly lower than that in the LE group on day 3 and 7 after treatment. In addition, CD8⁺ lymphocytes infiltration was more pronounced in LD group than in LE group on day 7 after treatment, regardless of in the tumor or adjacent liver tissue. Serum cytokines including IL-6, TNF- α and IFN- γ were strongly upregulated in the LD group on day 1 after treatment. And there was no significant difference in the hepatorenal function between LD group and LE group after treatment.

Conclusion: The combination of TAE and angiogenesis inhibitor donafenib resulted in a potentiated tumoricidal effect, anti-angiogenesis and antitumour T cell response in rabbit VX2 liver tumor model. This may provide a potential basis for exploring the immune-related mechanisms of embolization in liver cancer.

Keywords: liver cancer, transcatheter arterial embolization, donafenib, tumor angiogenesis, immune response

Introduction

Transcatheter arterial embolization (TAE) or transcatheter arterial chemoembolization (TACE) is one of the most common treatments for unresectable hepatocellular carcinoma (HCC).^{1,2} The rationale is that the intra-arterial infusion of embolic agents combined with or without chemotherapy drugs will result in a strong ischaemic necrosis and cytotoxic effect targeted to the tumor.³ TACE, indeed, as a safe and effective local treatment method, has been quite a success in the past

decades. However, increasing evidences found that tumor ischemia and hypoxia after embolization can enhance the expression of angiogenesis related factors and chemoresistance of HCC.⁴⁻⁶ And some studies have shown that the combination of TAE and chemotherapy drugs seems to be unsatisfactory.^{7,8} Hence, inhibition of angiogenesis as an optional treatment is critical to combining with TAE for HCC.

Sorafenib, a first oral multiple-receptor tyrosine kinase inhibitor, is recommended as the first-line systemic therapy for advanced HCC.⁹ It can interrupt signaling pathways involved in angiogenesis and tumor cell proliferation. Although sorafenib has been used in clinical practice for more than a decade, the cost has still limited its accessibility in developing countries.^{10,11} Donafenib, developed by Zelgen Biopharmaceuticals, is a novel small molecular targeted drug by substituting a trideuteriomethyl group for a methyl on the sorafenib molecule.¹² The deuteration can improve the stability of drug, resulting in lengthened half-life or reduced clearance. Some clinical trials have demonstrated its safety, pharmacokinetics and efficacy in treating advanced solid tumors.^{13,14} It has also been confirmed that donafenib is superior to sorafenib in improving survival and favorable safety in first-line treatment of unresectable or metastatic HCC.¹⁵ Similar to sorafenib, donafenib has strong antiproliferative potency and antiangiogenic activity in multiple cancer cell lines. Though the both drugs achieve a survival benefit, they are prone to systemic adverse events after oral administration (e.g., hypertension, hand-foot skin reaction and diarrhea). Some patients are unable to tolerate treatment and even suspend.

Previous reports have indicated that the combination of embolic agents and angiogenesis inhibitors (e.g., sorafenib, apatinib and sunitinib) via arterial administration to the liver is effective.¹⁶⁻¹⁸ It can increase intratumoral drug concentration and reduce systemic toxicity. The aim of present study was to investigate the feasibility, safety and effects on angiogenesis and immune response after TAE combined with donafenib in rabbit VX2 liver tumor model.

Materials and Methods

Animal Model

Ethical approval for the study was obtained from the Animal Experiment Committee of the Institute for Huazhong University of Science and Technology. New Zealand white rabbits (male; weight, 2.0–2.5 kg) were

purchased from the Experimental Animal Center, and could free access to enough food and water. The VX2 carcinoma strain was bred in a hind limb of carrier rabbit. Under aseptic condition, a longitudinal incision was made in rabbit's abdominal white line to reveal the hepatic lobe. A single 1 mm³ VX2 tumor chip was implanted into the left lateral lobe and followed with gelatin sponge to prevent tumor from falling out or liver bleeding. And each recipient rabbit was given intramuscular injection of penicillin for three days. Two weeks after implantation, the tumor suitable for interventional therapy was measured by CT scan.

Interventional Therapy Procedure

Hepatic arteriography was performed in all groups of tumor-bearing rabbits under fluoroscopy guidance. Thirty-six tumor-bearing rabbits were randomly divided into three groups. The LD group received the emulsion of 0.5 mL lipiodol and 4 mg donafenib. The LE group received the emulsion of 0.5 mL lipiodol and 4 mg epirubicin. The control group received the equal volume of saline. The rabbit's femoral artery was dissected and catheterized after anesthesia. A 4-F Cobra catheter (Cook, Inc., Bloomington, Indiana) was inserted into the celiac artery, and a 2.7-F coaxial microcatheter (Terumo, Tokyo, Japan) was further used to select the hepatic artery for angiography to identify the tumor-feeding artery. According to the predetermined groups, the various treatment was administered slowly to avoid the occlusion of non-target vessels. We then used gelatin sponge particles for supplement till the complete embolization of tumor vessels. Finally, all catheters were removed, and all rabbits were intramuscularly injected with penicillin daily for three days.

CT Imaging Evaluation

A 320-slice spiral enhanced CT triple-phase scan (Aquilion One, Toshiba Co., Tokyo, Japan) was performed to measure the tumor size before and 7 days after treatment. The scanning parameters were set as follow: 80-kV tube voltage; 60-mA tube current; 2-mm slice thickness. The dynamic abdominal CT was initiated after a delay time of 10 sec, and the injection volume of contrast agent was 3 mL (rate at 1mL/sec). The obtained imaging data were processed by the Syngo Fastview image processing system. Tumor size, location and intrahepatic metastasis were recorded and analyzed by two senior radiologists. The tumor volume was calculated by formula: $V = a * b^2/2$ (a, long diameter; b, short diameter). And the tumor growth rate was calculated by

formula: $V_7/V_0 * 100\%$. Tumor response was characterized using modified Response Evaluation Criteria in Solid Tumors (mRECIST) criteria.¹⁹

Hematoxylin and Eosin Staining of Tissue Samples

According to a predetermined scheme, four rabbits were euthanized in each group on day 1, 3 and 7 after treatment. The VX2 tumor and adjacent liver tissue were harvested. The specimens were then fixed for more than 24 hours in 10% formalin solution. After dehydration with ethanol, the samples were embedded in paraffin, sectioned. One slide (4 μm) from paraffin section was stained with hematoxylin-eosin (H&E) for histopathologic analysis. The feature of each tissue slide was recorded and tumor necrosis rate was calculated using an established method.²⁰

Immunofluorescence of CD31

The prepared paraffin sections were first to deparaffinize and rehydrate. They were then immersed in EDTA antigen retrieval buffer (pH 8.0) and maintained at a sub-boiling temperature for several minutes. After incubation with primary antibody, the slides were incubated with anti-rabbit CD31 secondary antibody diluted 1:100 (DAKO, USA) and maintained at room temperature for 50 min in dark condition. Subsequently, the slides were incubated with DAPI solution for 10 min and spontaneous fluorescence quenching for 5 min at room temperature. DAPI glows blue by UV excitation wavelength 330–380 nm and emission wavelength 420 nm, and CY3 glows red by excitation wavelength 510–560 nm and emission wavelength 590 nm. The representative fluorescent images were collected under microscopy. Fluorescent quantitative analysis was performed by two observers using ImageJ software 1.8.0 (National Institutes of Health, USA). The percentage of CD31-positive area per 20 high power field was recorded and analyzed in each group.

Immunohistochemical Staining of CD8⁺ T Lymphocytes

The pretreatment steps of samples were mostly as above. Briefly, the slides were incubated with mouse anti-rabbit CD8⁺ T cells (1:100 dilution, NOVUS, USA). After DAB chromogenic reaction, nucleus counterstaining with hematoxylin stain solution and dehydration, the CD8 cells staining of tissue was visualized under a microscope. The nucleus of

hematoxylin stained is blue, and positive expression of DAB is brownish yellow. The images were taken from the VX2 tumor and adjacent liver tissue in each group. The number of CD8⁺ T cells was also counted at high magnifications (200 \times) using ImageJ software. To ensure the representativeness and reliability of data, more than five independent fields in each section were selected to observe the infiltration of lymphocytes.

Cytokine ELISA

Serum of rabbits collected on day 1, 3 and 7 after treatment (e.g., LD, LE and control), was used for cytokine analysis. Immune modulatory cytokines included interleukin (IL)-6, tumor necrosis factor (TNF)- α and interferon (IFN)- γ were measured using ELISA KITs (CUSABIO, Wuhan, China), according to the manufacturer's protocol. The ultimate samples were assessed at 450 nm in an Epoch plate reader (BioTek, USA).

Biochemical Hepatorenal Function Assessment

Blood samples for assessment of hepatorenal function were collected through marginal ear vessels of rabbits at 1 day, 3 days and 7 days after treatment. The biochemical tests included alanine transaminase (ALT), aspartate transaminase (AST), total bilirubin (TBIL) and creatinine (Cr).

Statistical Analysis

Statistical analysis was done with SPSS Statistics V.25.0 (SPSS Inc., Chicago, USA) and GraphPad Prism V.8.0 (GraphPad Software, La Jolla, USA) software packages. The data were described as mean value \pm standard deviation or absolute numbers (percentages). Independent *t* test or one-way ANOVA was used to analyze the variables between the groups. A *P* value < 0.05 was considered significant.

Results

Establishment of Rabbit VX2 Liver Tumor Model and Imaging Analysis

The operation, including the implantation of VX2 tumor and interventional therapy procedure, were performed successfully in all rabbits by the skillful interventional radiologists. Before operation, dynamic CT scanning showed that a spherical tumor with markedly marginal enhancement was embedded in the left lateral lobe of liver. The average tumor size was $1284.20 \pm$

218.02 mm³. Seven days after the operation, we found a well lipiodol deposition in the tumor both LD and LE group (Figure 1A). Even so, the result of tumor growth rate indicated the LD group was lower than LE group ($P < 0.05$) (Figure 1B). And further comparison of the number of intrahepatic metastases revealed that LD group was the lowest compared to other groups ($P < 0.05$) (Figure 1C).

Evaluation of Tumor Necrosis and Angiogenesis

Various degrees of tumor necrosis occurred in three groups on day 1, 3 and 7 after treatment (Figure 2). Tumor necrosis rate increased over time. One day after treatment, the tumor necrosis rate of LD group was similar to that of LE group (61.68% vs. 60.43%, $P = 0.707$). Similarly, there was no significant difference between LD and LE group 3 days after

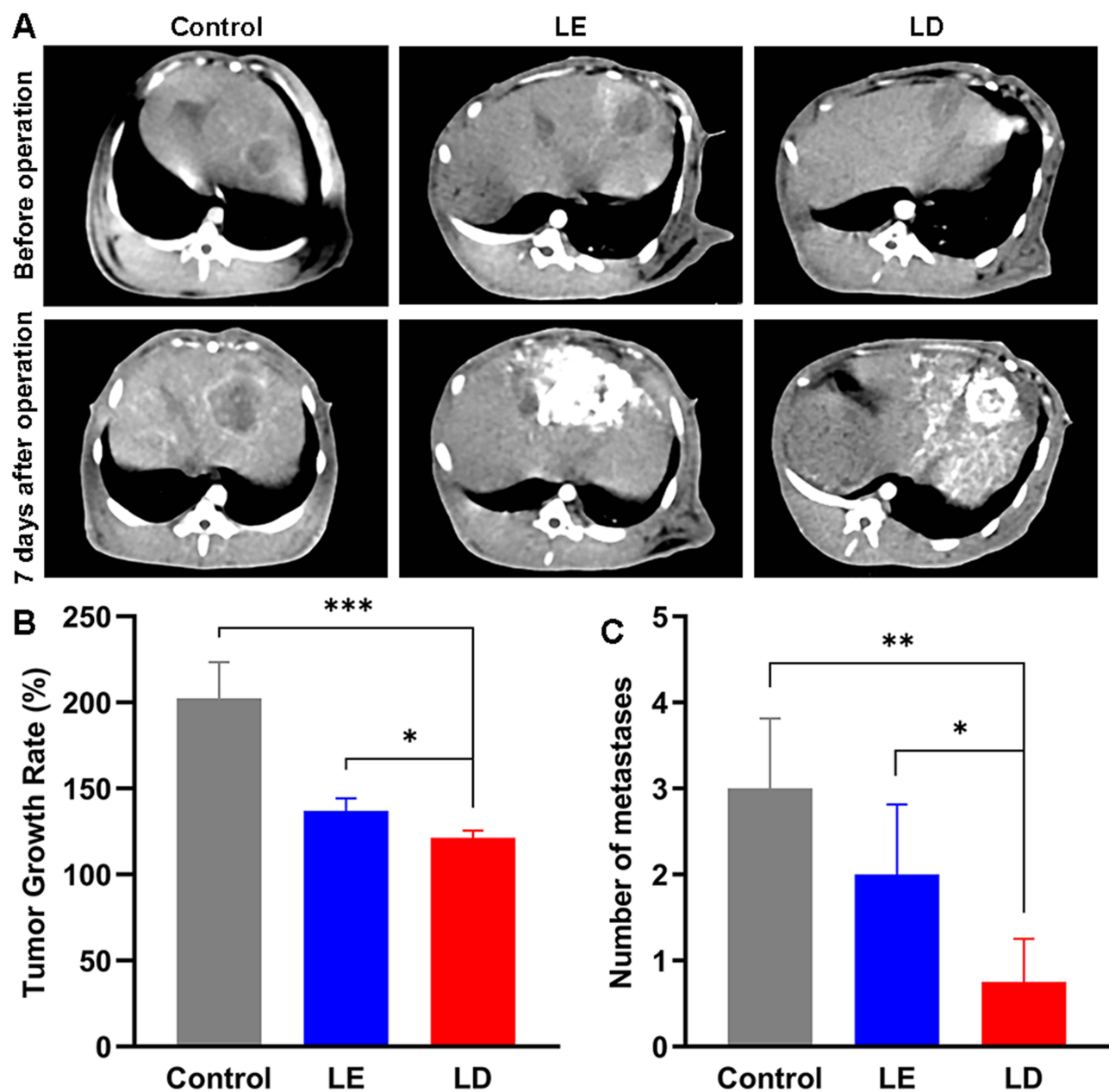


Figure 1 (A) Abdominal dynamic CT scan were performed on the three groups before and 7 days after operation ($n = 4$). (B) Tumor growth rate of each group ($n = 4$). (C) The number of intrahepatic metastases 7 days after operation ($n = 4$). * $P < 0.05$, ** $P < 0.01$, *** $P < 0.001$.

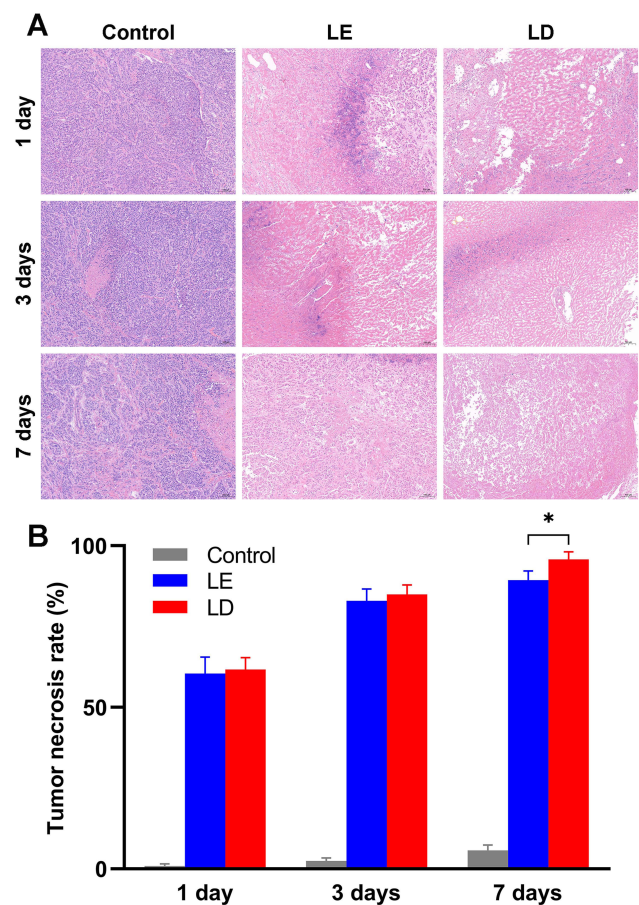


Figure 2 (A) Representative hematoxylin-eosin staining. Scale bar = 100 μ m. **(B)** Tumor necrosis rate of each group. * $P < 0.05$.

treatment (84.98% vs. 82.98%, $P = 0.420$). 95.75% of tumor necrosis rate for LD group was higher than 89.35% of that for LE group 7 days after treatment ($P < 0.05$).

The results of CD31 expression at different time points are presented in Figure 3. The percentages of CD31-positive area were not significant difference between LD and LE group 1 day after treatment (1.45% vs. 2.11%, $P = 0.101$). However, the CD31 expression of LD group was obviously lower than that of LE group 3 and 7 days after treatment ($P < 0.001$). Under fluorescence microscopy, the new blood vessels were greatly increased over time after treatment in LE group, while slowly in LD group.

Tumor Immune Response

The infiltration of CD8-positive T-lymphocytes in VX2 tumor and adjacent liver tissue were compared in the three groups on day 1, 3 and 7 after treatment (Figure 4). In the control group, faint infiltrate of CD8⁺ lymphocytes in the VX2 tumor and adjacent liver tissue on three occasions. There were relatively dense infiltrates of CD8⁺ lymphocytes

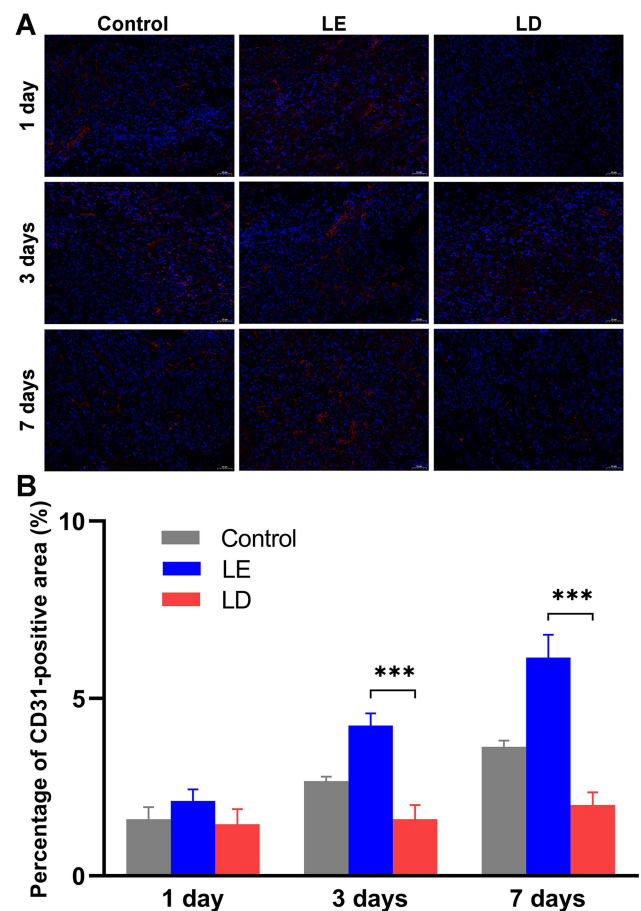


Figure 3 (A) Immunofluorescence of CD31. Nucleus (blue area) and positive expression of CD31 (red area). Scale bar = 50 μ m. **(B)** The percentages of CD31-positive area in VX2 tumor tissue. *** $P < 0.001$.

in the tumor tissue between LD and LE group. On day 1 and 3, the number of infiltrating CD8⁺ lymphocytes in the tumor tissue for LD group was higher than that for LE group ($P < 0.01$), while no significant difference in the adjacent liver tissue between the two groups. On day 7, CD8⁺ lymphocytes infiltration reached a peak in the two group. And it was more pronounced in the LD group than in the LE group, regardless of in the tumor (52.40 ± 3.97 vs. 31.80 ± 1.92 , $P < 0.001$) or adjacent liver tissue (27.20 ± 1.64 vs. 20.60 ± 2.88 , $P < 0.05$).

Cytokine Assay

Serum cytokines were measured as indicated (Figure 5). The pro-inflammatory Th1 related IL-6, TNF- α and IFN- γ were strongly upregulated in tumor-bearing rabbits receiving TAE with donafenib or epirubicin. These cytokines both LD and LE group had a peak level on day 1 after treatment. The IL-6 level in the LD group was 1589.24 ± 126.06 pg/mL and in the LE group was 1322.93 ± 50.06

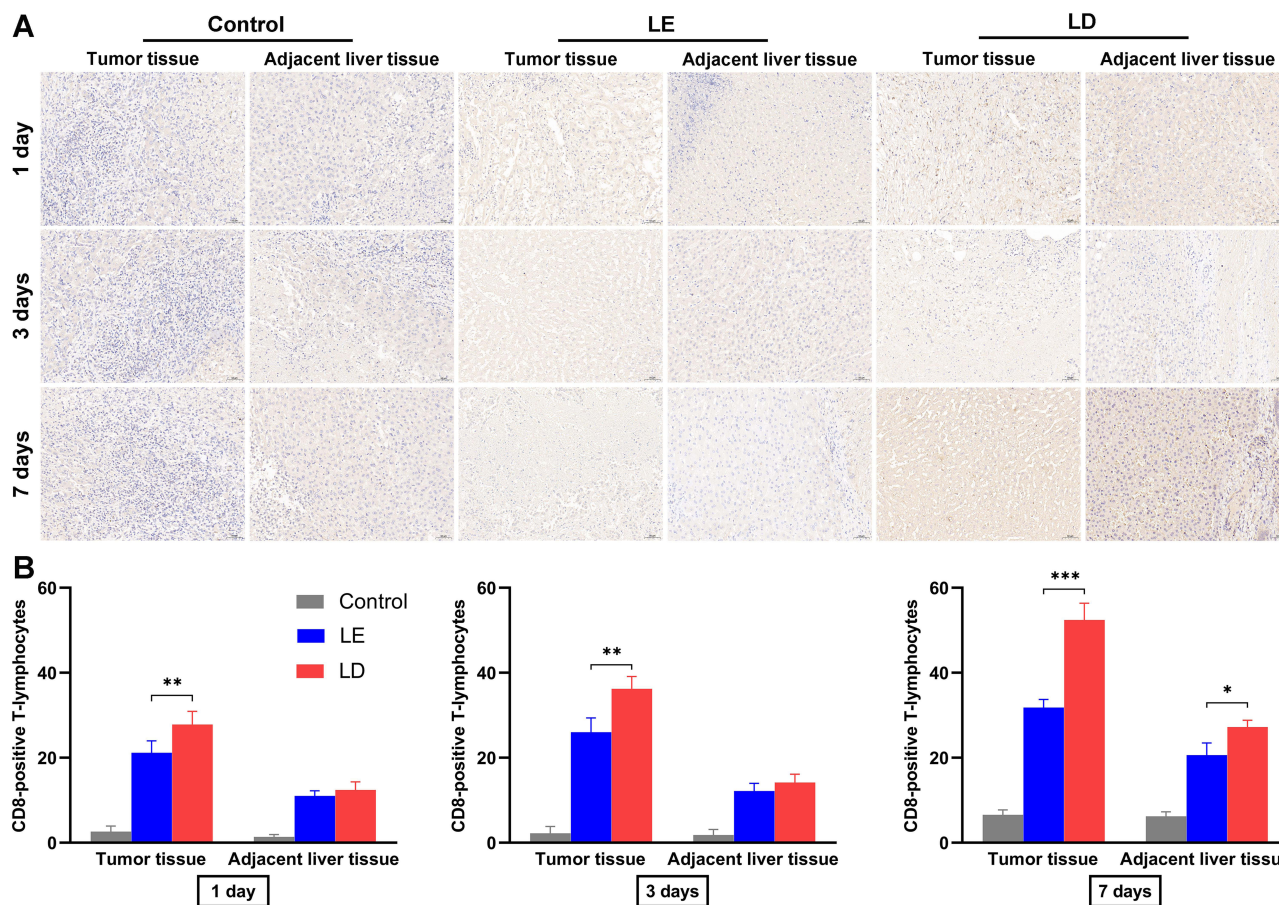


Figure 4 (A) Immunohistochemical staining for CD8 in the VX2 tumor and adjacent liver tissue 1 day, 3 days and 7 days after treatment. (B) Quantification of CD8-positive T-lymphocytes per high magnification (200x). * $P < 0.05$, ** $P < 0.01$, *** $P < 0.001$.

pg/mL ($P < 0.05$). Similarly, the levels of TNF- α and IFN- γ were higher for LD group than that for LE group ($P < 0.05$). Then, serum IL-6, TNF- α and IFN- γ in the LD and LE group showed an obvious decrease over time, and they were the same level as the control group until the day 7.

Hepatorenal Function Changes

The changes of ALT, AST, TBIL and Cr after treatment were shown in Figure 6. The LD and LE group had a similar increase in serum levels of ALT, AST and TBIL 1 day after treatment. Subsequently, these

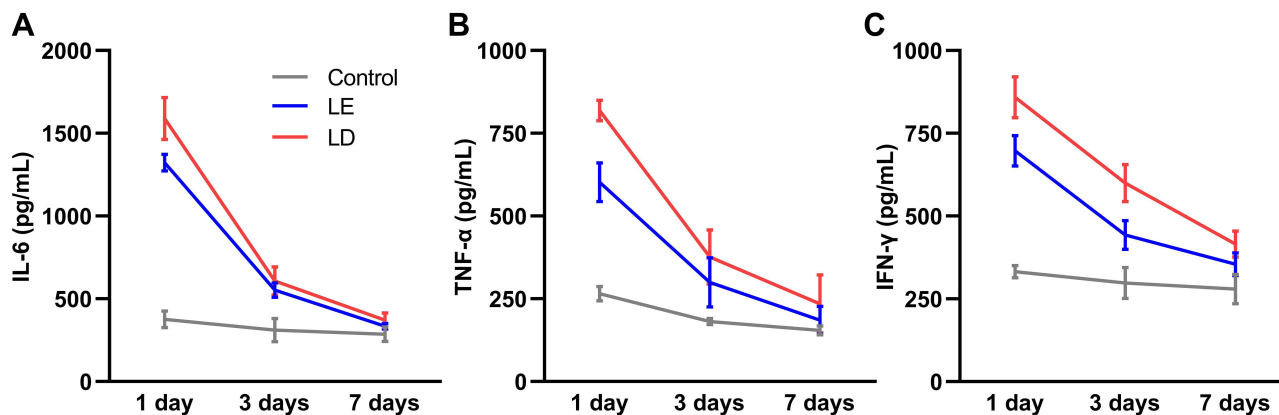


Figure 5 Levels of IL-6 (A), TNF- α (B) and IFN- γ (C) in serum.

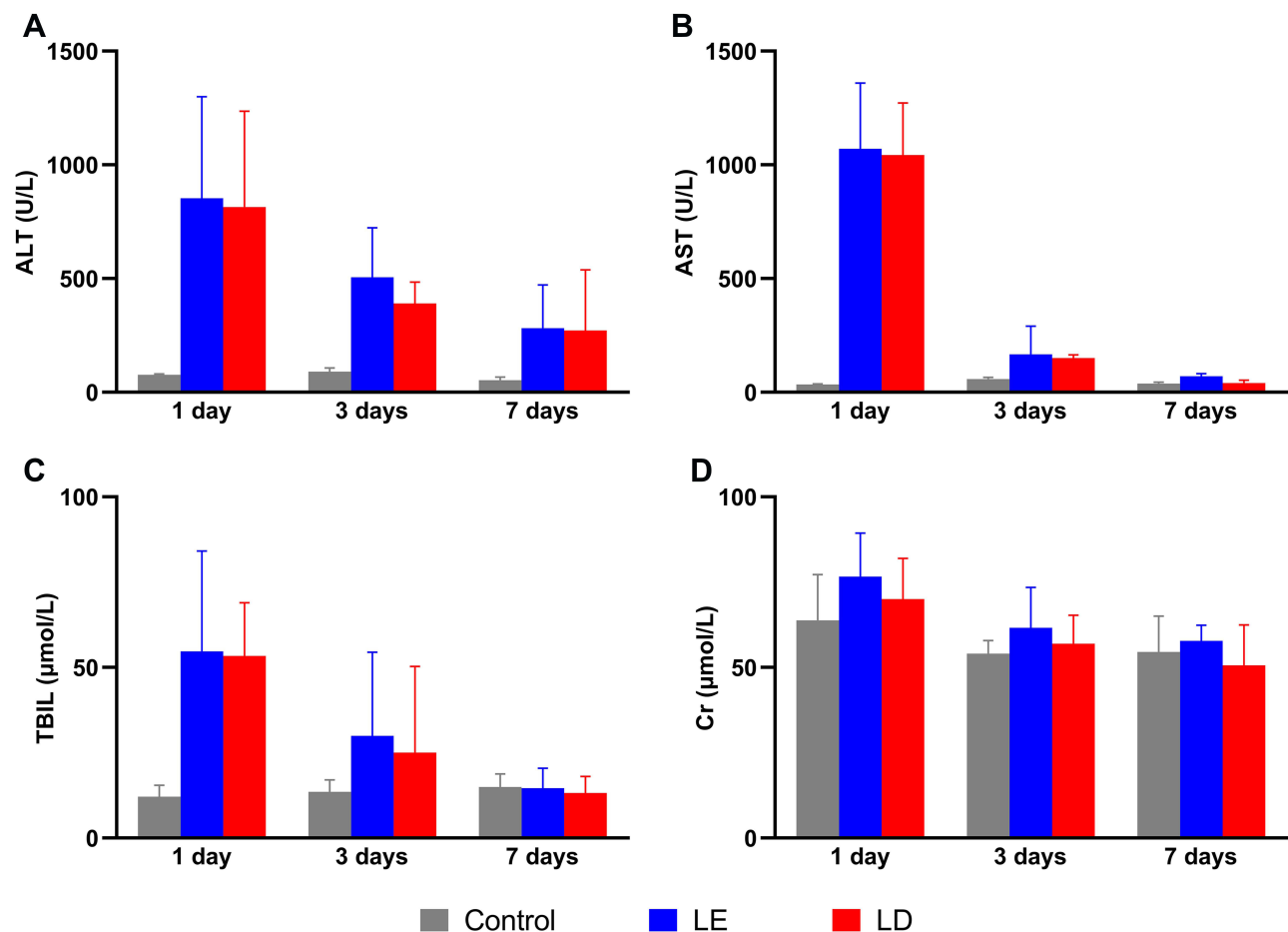


Figure 6 Levels of ALT (A), AST (B), TBIL (C) and Cr (D) in each group.

biochemical tests decreased to a low level in the two groups. Compared to the control group, the Cr level after treatment had no obvious change in the LD group and LE group. There was no significant difference in the hepatorenal function between LD group and LE group after treatment.

Discussion

The treatment of middle-advanced HCC is varied and controversial, according to the latest guidelines.^{21,22} It is widely recognized that TACE and targeted therapy are relatively advocated for those patients. Studies have reported that TACE or TAE has a bidirectional regulation on the tumor microenvironment. On the one hand, tumor necrosis caused by blocking up the tumor's blood supply can activate the response of systemic immune system, further to induce local infiltration of immunoregulatory lymphocytes and expression of corresponding cytokine.^{23,24} On the other hand, tumor hypoxia caused by incomplete embolization contributes to the high

expression of vascular endothelial growth factor (VEGF) and programmed death-ligand 1 (PD-L1), which leads to tumor angiogenesis and immunosuppression.^{25,26} The clinical application of angiogenesis inhibitors has greatly improved tumor response rate and survival.²⁷ It has strongly inhibition effects of angiogenesis by blocking the activation of relevant targets. Angiogenesis inhibitors, meanwhile, can induce the activation of immune system and promote the local infiltration of immunoregulatory lymphocytes.²⁸ However, systemic adverse events are noticeable and intolerable for some patients. In the present study, we confirmed for the first time that the combination of TAE and donafenib is effective in the hepatic arterial treatment of rabbit VX2 liver cancer.

Donafenib is a multi-targeted and multikinase inhibitors developed in China. An open-label, randomized, multicentre phase II/III trial showed that donafenib can achieve improved overall survival, better safety and tolerability compared to sorafenib.²⁹ This may be the preferred drug for the first-line treatment of advanced HCC in China. In the present study,

local application of donafenib can achieve lower tumor growth rate, fewer metastatic lesions and greater degree of tumor necrosis compared to epirubicin. This indicated the combination of TAE and donafenib can indeed reinforce the anti-tumor effect. Previous data had reported the local use of sorafenib and apatinib, the results of tumor response were like ours.^{30,31} The tumor necrosis rate increased after combined treatment over time. This may be because tumor necrosis is a continuous rather than immediate pathological process, and donafenib plays an important role in the late stage of necrosis.

For targeted drugs, the inhibition of angiogenesis is critical. Sorafenib has been used in preclinical and clinical studies in the past decade. It has been confirmed that sorafenib can reduce the tumor angiogenesis by inhibiting the VEGF and Raf kinase signaling pathways, regardless of the systemic or local administration.^{30,32} Similarly, our study showed that the LD group had a lower CD31 expression compared to LE group on day 3 and 7 after treatment. In the LE group, the CD31 expression gradually increased after treatment and peaked on day 7, while it has a negligible growth in the LD group. This suggested that embolization resulted in the increase of new tumor blood vessels and donafenib had a strong anti-angiogenesis effect in tumor tissue.

In some clinical studies, TACE appeared a markedly improved immune function in patients with HCC.^{33–35} It can reduce the percentage of CD4⁺CD25⁺Treg cells in the peripheral blood of HCC patients. However, it is unclear that the effect of local administration of angiogenesis inhibitors on the tumor immune response. In the present study, compared to control group, the combination of TAE with donafenib or epirubicin can achieve more dense infiltration of CD8⁺ lymphocytes. On day 7, the number of infiltrating CD8⁺ lymphocytes in the LD group were significantly higher than that in the LE group, which implied that local administration of donafenib achieved efficiently tumoricidal immune response under the hypoxic environment after embolization. Chuang et al³⁶ found the systemic administration of sorafenib can augment the function of CD8⁺T cells and reverse the tumor immunosuppressive microenvironment. These findings further explained angiogenesis inhibitors can strongly enhance the infiltration of T lymphocytes in the tumor tissue, regardless of local or systemic administration. In addition, the results of cytokines in peripheral blood supported this. The levels of IL-6, TNF- α and IFN- γ correlated closely with the infiltration of antitumor T cells. The increase of these cytokines can induce the activation of antitumor T cells. As for the hepatorenal function, donafenib and epirubicin had a similar toxic reaction,

which was different with the results in regard to the local administration of sorafenib.³⁷

The study had several limitations. Firstly, the evaluation of immune response was limited due to the lack of antibody reagents for rabbits, which is the most suitable model for TAE treatment. Theoretically, the number of NK, Treg cells and other immunoregulatory T cells in the tumor tissue should be used to comprehensively evaluate the tumor immune response. Secondly, the physical properties of lipiodol were so limited that the assessment of pharmacokinetic features has not been performed. More embolic agents with slow-release effect will be further studied in the future.

Conclusions

The study preliminarily confirmed that the combination of TAE and angiogenesis inhibitor donafenib can result in a strong tumoricidal effect, inhibition of angiogenesis and antitumor immune response in rabbit VX2 liver tumor model. This may provide a potential basis for exploring the immune-related mechanisms of embolization in liver cancer.

Statement of Ethics Approval

The Animal Experiment Committee of the Institute for Huazhong University of Science and Technology approved the experimental protocols. All animal experiments were performed in accordance with the National Institutes of Health Guidelines for the Care and Use of Laboratory Animals.

Acknowledgments

The study was supported from the National Natural Science Foundation of China (No. 81873917).

Disclosure

All authors declare that they have no potential conflict of interest in the study.

References

1. Omata M, Cheng AL, Kokudo N, et al. Asia-Pacific clinical practice guidelines on the management of hepatocellular carcinoma: a 2017 update. *Hepatol Int*. 2017;11(4):317–370.
2. Villanueva A. Hepatocellular Carcinoma. *N Engl J Med*. 2019;380(15):1450–1462. doi:10.1056/NEJMr1713263
3. European Association for the Study of the Liver. Electronic address eee, European Association for the Study of the L. EASL Clinical Practice Guidelines: management of hepatocellular carcinoma. *J Hepatol*. 2018;69(1):182–236.
4. Wu X-Z, Xie G-R, Chen D. Hypoxia and hepatocellular carcinoma: the therapeutic target for hepatocellular carcinoma. *J Gastroenterol Hepatol*. 2007;22(8):1178–1182. doi:10.1111/j.1440-1746.2007.04997.x

5. Sergio A, Cristofori C, Cardin R, et al. Transcatheter arterial chemoembolization (TACE) in hepatocellular carcinoma (HCC): the role of angiogenesis and invasiveness. *Am J Gastroenterol.* 2008;103(4):914–921. doi:10.1111/j.1572-0241.2007.01712.x
6. Xiao E-H, Guo D, Bian D-J. Effect of preoperative transcatheter arterial chemoembolization on angiogenesis of hepatocellular carcinoma cells. *World J Gastroenterol.* 2009;15(36):4582–4586. doi:10.3748/wjg.15.4582
7. Malagari K, Pomoni M, Kelekis A, et al. Prospective randomized comparison of chemoembolization with doxorubicin-eluting beads and bland embolization with BeadBlock for hepatocellular carcinoma. *Cardiovasc Intervent Radiol.* 2010;33(3):541–551. doi:10.1007/s00270-009-9750-0
8. Brown KT, Do RK, Gonen M, et al. Randomized Trial of Hepatic Artery Embolization for Hepatocellular Carcinoma Using Doxorubicin-Eluting Microspheres Compared With Embolization With Microspheres Alone. *J Clin Oncol.* 2016;34(17):2046–2053. doi:10.1200/JCO.2015.64.0821
9. Forner A, Reig M, Bruix J. Hepatocellular carcinoma. *Lancet.* 2018;391(10127):1301–1314. doi:10.1016/S0140-6736(18)30010-2
10. Leung HWC, Liu C-F, Chan ALF. Cost-effectiveness of sorafenib versus SBRT for unresectable advanced hepatocellular carcinoma. *Radiat Oncol.* 2016;11:69. doi:10.1186/s13014-016-0644-4
11. Parikh ND, Marshall VD, Singal AG, et al. Survival and cost-effectiveness of sorafenib therapy in advanced hepatocellular carcinoma: an analysis of the SEER-Medicare database. *Hepatology.* 2017;65(1):122–133. doi:10.1002/hep.28881
12. Li X, Qiu M, Wang S, et al. A Phase I dose-escalation, pharmacokinetics and food-effect study of oral donafenib in patients with advanced solid tumours. *Cancer Chemother Pharmacol.* 2020;85(3):593–604. doi:10.1007/s00280-020-04031-1
13. Liu J, Li X, Zhang H, et al. Safety, pharmacokinetics and efficacy of donafenib in treating advanced hepatocellular carcinoma: report from a phase 1b trial. *Pharmazie.* 2019;74(11):688–693.
14. Lin Y-S, Yang H, Ding Y, et al. Donafenib in Progressive Locally Advanced or Metastatic Radioactive Iodine-Refractory Differentiated Thyroid Cancer: results of a Randomized, Multicenter Phase II Trial. *Thyroid.* 2021;31(4):607–615. doi:10.1089/thy.2020.0235
15. Qin S, Bi F, Gu S, et al. Donafenib Versus Sorafenib in First-Line Treatment of Unresectable or Metastatic Hepatocellular Carcinoma: a Randomized, Open-Label, Parallel-Controlled Phase II-III Trial. *J Clin Oncol.* 2021. JCO2100163. doi:10.1200/JCO.21.00163
16. Parvinian A, Casadaban LC, Hauck ZZ, et al. Pharmacokinetic study of conventional sorafenib chemoembolization in a rabbit VX2 liver tumor model. *Diagn Interv Radiol.* 2015;21(3):235–240. doi:10.5152/dir.2014.14394
17. Shi Q, Lu Y, Huang S, et al. Apatinib-loaded CalliSpheres Beads for embolization in a rabbit VX2 liver tumor: characterization in vitro, pharmacokinetics and tumor response in vivo. *Drug Deliv.* 2020;27(1):1301–1307. doi:10.1080/10717544.2020.1818881
18. Bize P, Duran R, Fuchs K, et al. Antitumoral Effect of Sunitinib-eluting Beads in the Rabbit VX2 Tumor Model. *Radiology.* 2016;280(2):425–435. doi:10.1148/radiol.2016150361
19. Lencioni R, Llovet JM. Modified RECIST (mRECIST) assessment for hepatocellular carcinoma. *Semin Liver Dis.* 2010;30(1):52–60. doi:10.1055/s-0030-1247132
20. Hong K, Khwaja A, Liapi E, et al. New intra-arterial drug delivery system for the treatment of liver cancer: preclinical assessment in a rabbit model of liver cancer. *Clin Cancer Res.* 2006;12(8):2563–2567. doi:10.1158/1078-0432.CCR-05-2225
21. Marrero JA, Kulik LM, Sirlin CB, et al. Diagnosis, Staging, and Management of Hepatocellular Carcinoma: 2018 Practice Guidance by the American Association for the Study of Liver Diseases. *Hepatology.* 2018;68(2):723–750. doi:10.1002/hep.29913
22. Xie D-Y, Ren Z-G, Zhou J, et al. 2019 Chinese clinical guidelines for the management of hepatocellular carcinoma: updates and insights. *Hepatobiliary Surg Nutr.* 2020;9(4):452–463. doi:10.21037/hbsn-20-480
23. Liao Y, Wang B, Huang Z-L, et al. Increased circulating Th17 cells after transarterial chemoembolization correlate with improved survival in stage III hepatocellular carcinoma: a prospective study. *PLoS One.* 2013;8(4):e60444. doi:10.1371/journal.pone.0060444
24. Avritscher R, Jo N, Polak U, et al. Hepatic Arterial Bland Embolization Increases Th17 Cell Infiltration in a Syngeneic Rat Model of Hepatocellular Carcinoma. *Cardiovasc Intervent Radiol.* 2020;43(2):311–321. doi:10.1007/s00270-019-02343-1
25. Liu K, Zhang X, Xu W, et al. Targeting the vasculature in hepatocellular carcinoma treatment: starving versus normalizing blood supply. *Clin Transl Gastroenterol.* 2017;8(6):e98. doi:10.1038/ctg.2017.28
26. Fukumura D, Kloepper J, Amoozgar Z, et al. Enhancing cancer immunotherapy using antiangiogenics: opportunities and challenges. *Nat Rev Clin Oncol.* 2018;15(5):325–340. doi:10.1038/nrclinonc.2018.29
27. Pinter M, Peck-Radosavljevic M, Hong K. Review article: systemic treatment of hepatocellular carcinoma. *Aliment Pharmacol Ther.* 2018;48(6):598–609. doi:10.1111/apt.14913
28. Khan KA, Kerbel RS. Improving immunotherapy outcomes with anti-angiogenic treatments and vice versa. *Nat Rev Clin Oncol.* 2018;15(5):310–324. doi:10.1038/nrclinonc.2018.9
29. Bi F, Qin S, Gu S, et al. Donafenib versus sorafenib as first-line therapy in advanced hepatocellular carcinoma: an open-label, randomized, multicentre phase trial. 2020 ASCO Annual Meeting Symposium: abstract 4506; 2020.
30. Kim GM, Kim MD, Kim DY, et al. Transarterial Chemoembolization Using Sorafenib in a Rabbit VX2 Liver Tumor Model: pharmacokinetics and Antitumor Effect. *J Vasc Interv Radiol.* 2016;27(7):1086–1092. doi:10.1016/j.jvir.2016.02.032
31. Zhou C, Yao Q, Zhang H, et al. Combining transcatheter arterial embolization with iodized oil containing Apatinib inhibits HCC growth and metastasis. *Sci Rep.* 2020;10(1):2964. doi:10.1038/s41598-020-59746-1
32. Liu L, Cao Y, Chen C, et al. Sorafenib blocks the RAF/MEK/ERK pathway, inhibits tumor angiogenesis, and induces tumor cell apoptosis in hepatocellular carcinoma model PLC/PRF/5. *Cancer Res.* 2006;66(24):11851–11858. doi:10.1158/0008-5472.CAN-06-1377
33. Xiong B, Feng G, Luo S, et al. Changes of CD4(+) CD25 (+) regulatory T cells in peripheral blood in patients with hepatocellular carcinoma before and after TACE. *J Huazhong Univ Sci Technol Med Sci.* 2008;28(6):645–648. doi:10.1007/s11596-008-0606-7
34. Liao J, Xiao J, Zhou Y, et al. Effect of transcatheter arterial chemoembolization on cellular immune function and regulatory T cells in patients with hepatocellular carcinoma. *Mol Med Rep.* 2015;12(4):6065–6071. doi:10.3892/mmr.2015.4171
35. Zhou W, Deng J, Chen Q, et al. Expression of CD4+CD25+CD127 regulatory T cells and cytokines in peripheral blood of patients with primary liver carcinoma. *Int J Med Sci.* 2020;17(6):712–719. doi:10.7150/ijms.44088
36. Chuang H-Y, Chang Y-F, Liu R-S, et al. Serial low doses of sorafenib enhance therapeutic efficacy of adoptive T cell therapy in a murine model by improving tumor microenvironment. *PLoS One.* 2014;9(10):e109992. doi:10.1371/journal.pone.0109992
37. Seidensticker M, Streit S, Nass N, et al. Modified transarterial chemoembolization with locoregional administration of sorafenib for treating hepatocellular carcinoma: feasibility, efficacy, and safety in the VX-2 rabbit liver tumor model. *Diagn Interv Radiol.* 2016;22(4):378–384. doi:10.5152/dir.2016.15462

Cancer Management and Research

Dovepress

Publish your work in this journal

Cancer Management and Research is an international, peer-reviewed open access journal focusing on cancer research and the optimal use of preventative and integrated treatment interventions to achieve improved outcomes, enhanced survival and quality of life for the cancer patient.

The manuscript management system is completely online and includes a very quick and fair peer-review system, which is all easy to use. Visit <http://www.dovepress.com/testimonials.php> to read real quotes from published authors.

Submit your manuscript here: <https://www.dovepress.com/cancer-management-and-research-journal>