

Dissecting Aortic Aneurysm Complicating Pregnancy

Nootan Chandwaskar, Neeta Natu, Shilpa Sapre, Manjulata Tomar, Ravindra Kumar¹

Department of Obstetrics and Gynecology, Sri Aurobindo Institute of Medical Sciences, ¹Central Research Laboratory, Sri Aurobindo Institute of Medical Sciences, Indore, Madhya Pradesh, India

Correspondence: Dr. Nootan Chandwaskar, Department of Obstetrics and Gynecology, Sri Aurobindo Institute of Medical Sciences, Indore Ujjain State Highway, Indore, Madhya Pradesh, India. E-mail: nootan81@yahoo.in

ABSTRACT

Dissection of the aorta which is very rare in pregnancy usually occurs in the third trimester when blood volume and cardiac output rise to a maximum. We present here, a case of a 38-year-old pregnant woman with acute aortic dissection Type B. Management was conservative and after stabilization of vitals, obstetric hysterotomy was performed.

Key words: Dissecting aorta, aneurysm, pregnancy

ملخص البحث :

يعتبر إنسلاخ الشريان الابهر من الحالات النادرة أثناء الحمل ويحدث عادة في الثلث الأخير منه عندما تكون كمية الدم والضخ القلبي في أعلى مستوياتهما. يعرض الباحثون حالة لسيدة حامل في الثانية والثلاثين من العمر تعاني من إنسلاخ الشريان الابهر الحاد من نوع B. عولجت المريضة تحفظياً وبعد استقرار حالتها أجريت لها عملية إزالة الرحم تفادياً لمضاعفات مشابهة مستقبلاً.

INTRODUCTION

Acute aortic dissection is a life-threatening disease that requires immediate surgical intervention.^[1,2] Acute aortic dissection in pregnancy is rare and carries high risk for both mother and the fetus.^[3] Acute aortic dissection mainly affects patients older than 50 years. It has been estimated that mortality approaches 1% per hour in the first 48 h and exceeds 80% during the 1st month.^[4] In a study done by Immer *et al.*,^[2] more than 50% of pregnant patients with aortic dissection had Marfan syndrome. Even in the absence of risk factors, aortic dissection needs to be considered when evaluating the syncope in a pregnant patient.^[2] Diagnosis of this rare but potentially curable condition is difficult. Mortality occurs when diagnosis is delayed. Here, we describe a case of dissecting aortic aneurysm in a pregnant woman.

CASE REPORT

A 38-year-old, elderly Indian primigravida was referred and underwent ultrasonography (USG) where she was found to have a severe oligohydramnios. The patient had a history of amenorrhea of 6 months and married life of 5 years. Her menstrual history was irregular, and her last menstrual period was not known. Her history indicated dyspnea on moderate exertion and chest pain off and on. There was no significant medical history otherwise. The patient had undergone laparoscopic ovarian cystectomy and infertility treatment about 1-year previously, but detail records were not available. There was no family history of diabetes mellitus, hypertension, and any genetic illness. The patient did not have any side effect with any drug.

There were no symptoms of Marfan-like syndrome or any other dysmorphism. Her gait was normal; pallor was present; clubbing, icterus and cyanosis were absent. Oral hygiene was well-maintained. Neck glands were not palpable, and jugular venous pressure was normal. Pulse rate was 82/minute, irregular, with no radio-femoral delay. Blood pressure (BP) was 150/100 mmHg in right arm supine position. Respiratory rate was 16/min. On cardiovascular examination, we observed apex beat in 4th intercostal space, grade 3 pansystolic murmur over mitral area radiating to aortic area. Chest examination was clear,

Access this article online

Quick Response Code:



Website:

www.sjmms.net

DOI:

10.4103/1658-631X.170889

and no added sounds were observed. No organomegaly except gravid uterus was present during abdominal examination. The size of uterus was 20-22 weeks and fetal heart sounds were present.

The patient was Rhesus negative and Hb was 12 gm%. Complete blood count, thyroid, and coagulation profile were within normal limits. Electrocardiogram (ECG) showed multiple ectopic beats pre-mature ventricular contractions. On two-dimensional echocardiography, dilated cardiomyopathy with concentric left ventricular hypertrophy, mitral regurgitation, tricuspid regurgitation, and aortic regurgitation were observed. Aortic root diameter was 4 cm and left ventricular ejection fraction was 40-45%. The repeat USG showed 25 weeks 4 days fetus with severe oligohydramnios and intrauterine growth restriction with amniotic fluid index 1-2 cm. Fetal targeted scan found no anomaly.

Cardiologist opinion was taken and the patient was put on antihypertensive therapy. Two days later, the patient had a sudden onset of inter-scapular back pain and chest pain. Vitals were stable and ECG was done immediately and was same. The patient was kept under close observation. On the same day evening, patient suddenly had dyspnoea with chest discomfort. On examination, there was pallor + + +, no cyanosis, SpO₂ - was 70%, BP - 90/60 mm Hg, Pulse - 104/m irregular. Respiratory Rate (RR) - 22/m, decreased B/L lung air entry, cardiovascular system-pansystolic murmur was present. Hemoglobin level had fallen to 6 gm%. ECG showed ST depression and sinus tachycardia. Chest X-ray showed a huge collection of fluid in the pleural cavity. USG of chest showed B/L moderate pleural effusion.

X-ray of the chest showed an obliteration of costophrenic angle with a moderate bilateral collection of fluid in pleural cavity, with tracheal shift to right. Repeat obstetric USG showed 26-week single intrauterine fetus in the transverse lie with no cardiac activity. Immediately USG-guided intercostal drain was inserted on the left side of the chest and around 2 liters of frank hemorrhagic fluid were drained from thorax. Cytology of the pleural fluid was found to be exudative.

The chest computed tomography showed a large amount of left hemothorax and mediastinal hematoma with aortic dissection involving the descending thoracic and abdominal aorta (Stanford Type B) with focal tubular outpouching of contrast in mediastinum at the origin of aortic dissection. This was suggestive of aortic contrast extravasation that is Ruptured Aortic Dissection [Figure 1]. An underlying collapsed consolidation of the entire left lung was seen.

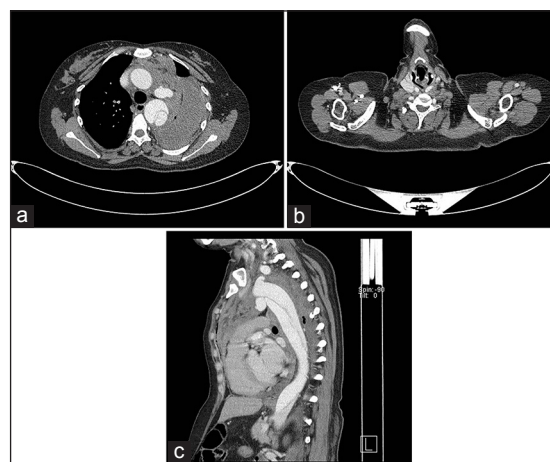


Figure 1: Axial contrast CT. Thorax study showed dissection of the arch and descending aorta extending inferiorly up to the abdominal aorta with left hemothorax and hemomediastinum and collapse of the underlying lung (a and b). Contrast opacified outpouching arising from the inferior arch of the aorta and opposite to subclavian origin (c)

There were cardiomegaly and a small fusiform aneurysm, 2.5 cm long segment with a diameter of 1.6 cm of the left subclavian artery was present. In the Intensive Care Unit, the patient received 4 units of blood transfusion. On stabilization of vitals, obstetric hysterotomy was done under epidural and local anesthesia. A dead fetus of around 800 g was delivered. Placental weight was 150 g. Intraoperative and postoperative period was uneventful except for fever. On the 8th postoperative day, there was complete stitch removal. The patient was followed up 15 days later and was found to be normal.

DISCUSSION

Aortic dissection occurs when there is a tear in the inner muscle wall lining of the aorta allowing blood to split the muscle layers of the aortic wall apart. While there have been different historic classifications of aortic dissection, the Stanford classification is now the most commonly used. Type A dissections involve the ascending aorta, and arch and Type B involves the descending aorta.^[5] Dissection of the aorta is characteristically a disease associated with multiple risk factors and is very rare in young women under the age of 40 years.^[6] Common causes for aortic dissection are high BP (over 70%), bicuspid aortic valve, Marfan syndrome, Ehlers-Danlos syndrome, Turner syndrome, syphilis, cocaine addiction, pregnancy (mostly during the third trimester), trauma, and surgical complications.^[7] Although the clinical manifestations of acute aortic dissection are well-described, the diagnosis is often overlooked. A study over a 27-year period showed that there was a misdiagnosis of 85% of patients presenting with acute dissection.^[8]

A review of the International Registry of Acute Aortic Dissection showed that only 2 out of 346 women were pregnant. The most common risk factors for women were older age and chronic hypertension.^[9] Aortic dissection in pregnancy occurs most commonly in the third trimester. Pregnancy is the period of maximum hyper- hemodynamic stress. During this period, there is maximal increase in heart rate, stroke volume, cardiac output, and in left ventricular wall mass and end-diastolic dimension. In addition, estrogen inhibits collagen and elastin deposition in the aorta while progesterone accelerates deposition of noncollagen proteins in the aorta. These hormonal effects lead to a fragmentation of the reticulin fibers diminished the amount of acid mucopolysaccharides and favored loss of the normal corrugation of the elastic fibers. Therefore, both hemodynamic and hormonal mechanisms increase the susceptibility to dissection in pregnant women.

The mortality rate of aortic rupture is up to 80%, and 50% of these patients die before reaching the hospital. Overall for both types of aortic dissection the survival rate is 10 years for more than 60%.

Type A aortic dissections of the ascending aorta require surgery as the treatment of choice. The area of the aorta that is damaged is replaced with an artificial graft. Medical management (nonsurgical) is usually preferred for Type B dissection of the descending aorta.^[7] Medications are prescribed aggressively to control high BP (beta blockers) and to prevent further dissection and aortic injury.

CONCLUSION

Normal-sized patients with an aortic root size of more than 4 cm or an increase of aortic root size during

pregnancy are at high risk for aortic dissection mainly in the third trimester. If possible, surgical repair of the enlarged aortic root should be done prepartum. In patients in whom the diagnosis of an enlarged aortic root is made during pregnancy, a close echocardiographic follow-up (4-6 weeks) is mandatory.

REFERENCES

1. Zeebregts CJ, Schepens MA, Hameeteman TM, Morshuis WJ, de la Rivière AB. Acute aortic dissection complicating pregnancy. *Ann Thorac Surg* 1997;64:1345-8.
2. Immer FF, Bansi AG, Immer-Bansi AS, McDougall J, Zehr KJ, Schaff HV, *et al.* Aortic dissection in pregnancy: Analysis of risk factors and outcome. *Ann Thorac Surg* 2003;76:309-14.
3. Guo C, Xu D, Wang C. Successful treatment for acute aortic dissection in pregnancy – Bentall procedure concomitant with cesarean section. *J Cardiothorac Surg* 2011;6:139.
4. Aziz F, Penupolu S, Alok A, Doddi S, Abed M. Peripartum acute aortic dissection: A case report & review of literature. *J Thorac Dis* 2011;3:65-7.
5. Braverman AC. Acute aortic dissection: Clinician update. *Circulation* 2010;122:184-8.
6. Kinney-Ham L, Nguyen HB, Steele R, Walters EL. Acute aortic dissection in third trimester pregnancy without risk factors. *West J Emerg Med* 2011;12:571-4.
7. Thrumurthy SG, Karthikesalingam A, Patterson BO, Holt PJ, Thompson MM. The diagnosis and management of aortic dissection. *BMJ* 2011;344:d8290.
8. Crawford ES. The diagnosis and management of aortic dissection. *JAMA* 1990;264:2537-41.
9. Nienaber CA, Fattori R, Mehta RH, Richartz BM, Evangelista A, Petzsch M, *et al.* Gender-related differences in acute aortic dissection. *Circulation* 2004;109:3014-21.

How to cite this article: Chandwaskar N, Natu N, Sapre S, Tomar M, Kumar R. Dissecting aortic aneurysm complicating pregnancy. *Saudi J Med Med Sci* 2016;4:29-31.

Source of Support: Nil. **Conflicts of Interest:** None declared.