

Systemic *Rasamsonia piperina* infection in a German shepherd cross dog

Joanna Lodzinska,¹ Paola Cazzini,² Claire S. Taylor,² Jenifer Harris,² Scott Kilpatrick,³ Tiziana Liuti¹ and Gavin K. Paterson^{2,*}

Abstract

Introduction. Infection with the *Rasamsonia argillacea* species complex represents an emerging problem in human and veterinary medicine with systemic mycoses presenting with significant clinical complications and being a cause of death.

Case presentation. In this report, a case of systemic *Rasamsonia piperina* infection discovered in a 3-year-old male neutered, German shepherd cross dog is described together with the clinical presentation, the course of the disease and diagnosis. This report describes the first case of veterinary mycosis due to *R. piperina* in Europe and the first case in humans or animals in the UK.

Conclusion. Although seemingly rare, *R. argillacea* species complex infection should be a differential diagnosis for dogs, especially German shepherds with the described presenting signs, and radiographic and ultrasonographic findings.

INTRODUCTION

Rasamsonia argillacea species complex infections are an emerging problem in human medicine. In the absence of molecular diagnostics, morphological similarity to other fungi may cause misidentification of *Rasamsonia* species and thus their role as pathogens may be underappreciated. Veterinary *Rasamsonia* species infections have so far been limited to two previous cases and here we report a case of systemic *Rasamsonia piperina* infection in a 3-year-old, male neutered, German shepherd cross dog. In addition to being the first case of veterinary *R. piperina* mycosis in Europe and the first *R. piperina* case in humans or animals in the UK, this is also the first veterinary case of systemic mycosis due to *R. piperina* in a dog with macroscopic pulmonary, pleural, splenic, hepatic and lymphoid involvement.

CASE REPORT

A 3-year-old, male neutered, German shepherd cross dog presented with a 4 week history of intermittent left hind limb, non-weight-bearing lameness. On physical examination the patient was resented extension of hip joints and pain reaction was elicited on palpation of the left humerus. Initial treatment with meloxicam and tramadol did not

resolve the clinical signs and the dog presented again 3 months later. On the second assessment the left hind limb lameness persisted and pain was also found on palpation of the left humeral, and both femoral diaphyses. Radiographs revealed a moderate, generalized and patchy increase in radiopacity in the medulla of the left femoral diaphysis. Smooth, continuous periosteal new bone formation extended along the medial and caudal cortex of the proximal third of the diaphysis. A diagnosis of left femoral panosteitis was made and the patient was discharged with exercise restriction and analgesia. The lameness failed to improve and the dog presented again a few days later, this time with shifting lameness involving left front and hind limbs and pyrexia. Recent lethargy, hyporexia, vomiting and restlessness were also reported.

An investigation of pyrexia of unknown origin was initiated. Blood analysis revealed monocytosis [$12.2 \times 10^9 \text{ l}^{-1}$, reference interval (RI) 0–1.5], hypoalbuminaemia (21.5 g l^{-1} , RI 26–35) and hyperglobulinaemia (42 g l^{-1} , RI 18–37). Radiography of the right femur showed an aggressive proximal diaphyseal lesion, which had progressed compared to previous images, with secondary disuse muscle atrophy (Fig. 1). Differential diagnoses included fungal or bacterial osteomyelitis. An adjacent soft tissue neoplasm was considered less

Received 7 August 2017; Accepted 8 October 2017

Author affiliations: ¹Hospital for Small Animals, Royal (Dick) School of Veterinary Studies, University of Edinburgh, Roslin EH25 9RG, UK; ²Easter Bush Pathology, Royal (Dick) School of Veterinary Studies, University of Edinburgh, Easter Bush Campus, Roslin EH25 9RG, UK; ³Vets Now Referrals, 123–145 North Street, Glasgow G3 7DA, UK.

*Correspondence: Gavin K. Paterson, gavin.paterson@ed.ac.uk

Keywords: systemic *Rasamsonia piperina*; fungal osteomyelitis; lameness; pyrexia; voriconazole; caspofungin; amphotericin B; posaconazole.

Abbreviations: ITS, internal transcribed spacer; RI, reference interval.

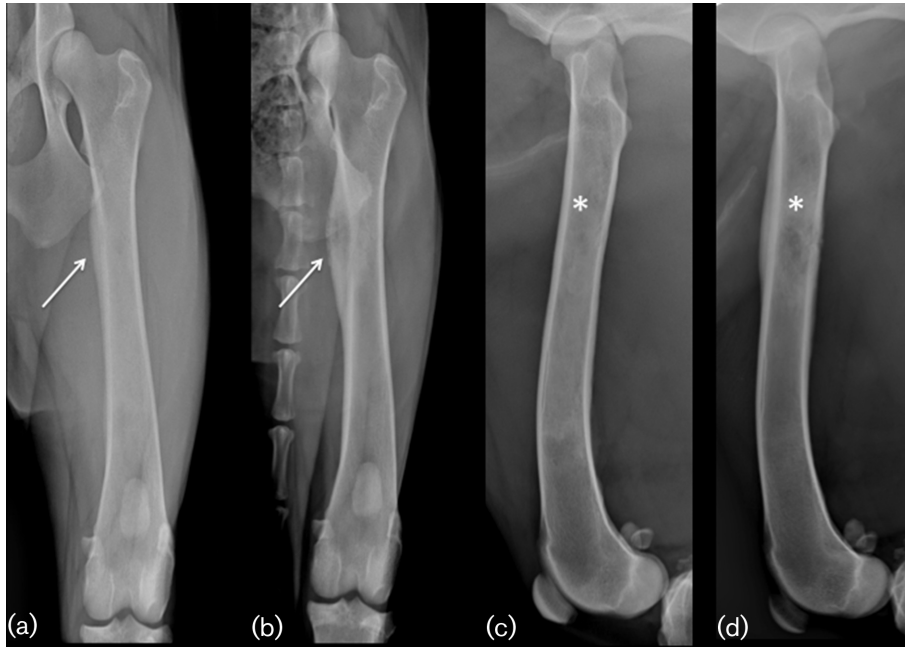


Fig. 1. Caudocranial and mediolateral projections of the left femur on initial presentation (a, c) and on second assessment (b, d) showing disease progression. (a,c) Moderate, generalized and patchy increase in radiopacity within the medulla (star) and smooth, continuous periosteal new bone formation along the medial cortex (arrow). (b,d) Large region of mixed lysis and proliferation affecting the medulla of the proximal diaphysis (star) with associated marked lamellar periosteal reaction (arrow). Note moderate loss of muscle mass visible on the caudocranial view (b) when compared to the first assessment (a).

likely. Thoracic radiographs revealed partial right middle lung lobe consolidation with lobar pneumonia and small- to moderate-volume right-sided pleural effusion.

On abdominal ultrasound there was marked mass effect in the cranial abdomen associated with marked generalized lymphadenopathy, steatitis and minimal peritoneal effusion. The spleen was enlarged with irregular margins, and moderately heterogeneous. Thoracentesis was performed and fine needle aspirates were taken from the spleen, lymph nodes and mass in the cranial abdomen.

Cranial abdominal mass and lymph node fine needle aspirates were consistent with marked pyogranulomatous inflammation with multinucleated giant cells and intralesional fungal hyphae. Hyphae were 2–3 μm in width, and had parallel walls with septate and 45–90° branching. They stained purple, and had a thick, clear outer cell wall (Fig. 2). The pleural effusion was consistent with eosinophilic to mixed inflammation, consistent with a reaction to the disseminated fungal disease. While waiting for culture results a working diagnosis of aspergillosis was made and treatment with itraconazole (5 mg kg^{-1} PO q24h), amphotericin B (1 mg kg^{-1} IV CRI) and terbinafine (20 mg kg^{-1} PO q12h) was initiated. The patient presented again the following day with an episode of bilateral epistaxis and worsening respiratory signs. Repeat radiographs showed moderate progression of pleural effusion and marked sublumbar lymphadenopathy associated with moderate peritoneal

effusion, and hepatomegaly. The dog was persistently pyrexic, so itraconazole and terbinafine were withdrawn and treatment with voriconazole (5 mg kg^{-1} PO q12h) was commenced.

The patient was hospitalized and repeat abdominal ultrasound scans revealed new heterogeneous appearance of the liver with numerous hypoechoic lesions. Cytology of the hepatic lesions revealed marked pyogranulomatous inflammation with fungal hyphae and inter-hepatocellular bile casts, indicating cholestasis.

Microbiological examination of hepatic lesion fluid isolated a pure growth of a fungus described as having macro- and micro-morphological characteristics similar to those of *Purpureocillium* species and *Paecilomyces* species; no *Aspergillus* species was isolated. As the identity of the isolate was not clear from colony morphology or microscopic examination, molecular identification was used. An internal transcribed spacer (ITS) region of the ribosomal DNA gene cluster was amplified and sequenced on both strands with primers ITS-F and ITS-R [1]. The resultant 422 bp ITS region sequence was identified using the ISHAM-ITS database (<http://its.mycologylab.org>) [2]. The highest match was 99.763 % nucleotide identity to the ITS region of the type strain of *R. piperina* (CBS 408.73; NCBI accession no. NR_120176.1, position 71–492). To confirm the identity as *R. piperina*, fragments of the beta-tubulin and calmodulin genes were amplified and sequenced on both strands using the

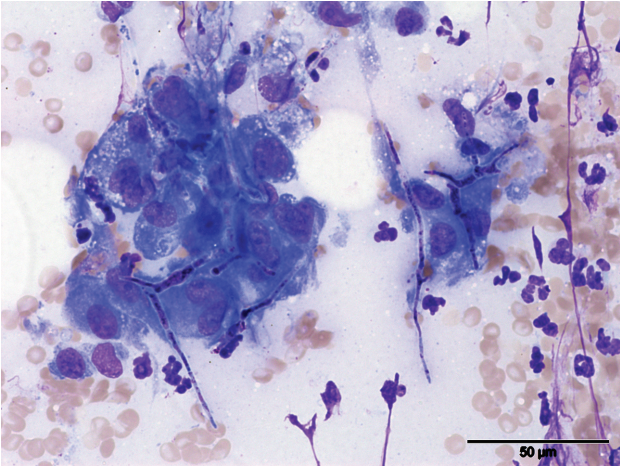


Fig. 2. Image from the abdominal mass: note the presence of high numbers of macrophages associated with several fungal hyphae. A few neutrophils are also present in the background. Romanowsky staining, 400× magnification. Bar, 50 μm.

respective primer pairs Bt2a/Bt2b and Cmd5/Cmd6 as described previously [3]. Both sequences showed 100% nucleotide identity with the respective genes of *R. piperina* CBS 408.73 (beta-tubulin JX273000.1, positions 45–439; and calmodulin JX272936.1, positions 43–422). Antifungal susceptibility was performed using the YS07 Vitek card (bioMérieux), and MICs were as follows: fluconazole 32 mg l⁻¹, voriconazole 4 mg l⁻¹, caspofungin 0.5 mg l⁻¹, micafungin <0.006 mg l⁻¹, amphotericin <0.25 mg l⁻¹ and flucytosine <1 mg l⁻¹.

OUTCOME AND FOLLOW-UP

Despite the ongoing treatment the dog continued to deteriorate: large volumes of pleural fluid were continually drained and peripheral oedema developed. Due to the progressive decline, the owners elected to have the dog euthanized.

DISCUSSION

Infections with the *Rasamsonia* species complex are an emerging problem in human medicine, particularly in immunocompromised patients [4–8]. To date there have only been two previous case reports of *Rasamsonia* species infection in veterinary medicine [9, 10]. Both cases were of single German shepherd dogs infected with *R. argillacea* [10] and *R. piperina* [9] (initially reported as *Geosmithia piperina* [11]).

The main similarities in the two cases include age and breed. Systemic aspergillosis has been most commonly reported in German shepherd dogs between 2 and 8 years of age [12–16] and it has been suggested that a hereditary immune defect might exist [17–20] alongside mucosal immunity dysfunction [21]. This heredity susceptibility may extend to *Rasamsonia* species complex infection and highlights the

need to consider other fungal causes beyond *Aspergillus* species for systemic mycoses in this breed.

Presenting signs in our case were similar to those of *R. argillacea* [10] where an initial lameness was the primary complaint. In the previous case report of *R. piperina* [9], the main presenting signs were acute-onset glaucoma of the right eye together with combined presence of lethargy, spinal hyperpathia, panuveitis, haematuria and pyuria. None of those were seen in our case, where the signs of systemic disease were limited to pyrexia and, later in the disease course, epistaxis and respiratory signs.

Both dogs in previous reports [9, 10] had radiographic signs consistent with discospondylitis. In the case described here the initial radiographic findings were consistent with panosteitis, and lesions characteristic of osteomyelitis did not develop until later.

Neither of the previous veterinary *Rasamsonia* species mycosis reported macroscopic pulmonary or pleural involvement although that has been reported in human medicine in patients with cystic fibrosis undergoing lung transplants [4, 5, 8]. There were abnormalities on abdominal ultrasound of both previous dogs. The previously reported case [9] had bilateral renal pelvic dilation with all other organs appearing normal, unlike in our case where a clear splenic, hepatic and lymphoid involvement was present.

In the case described here the diagnosis of disseminated fungal infection was reached following fine needle aspirates from the spleen, lymph nodes and liver. Fungal hyphae were also observed in the pleural effusion following thoracocentesis, unlike the previous veterinary reports [9, 10] where the diagnosis was reached following aspirates or biopsies of the vertebral bodies or sternebra. Molecular characterization was pivotal in distinguishing the fungal species in all three reports.

Recent antifungal testing [11] on *Rasamsonia* species showed that caspofungin had significant activity *in vitro*, followed by amphotericin B and posaconazole. In another study voriconazole and isavuconazole had poor *in vitro* activity against *Rasamsonia* isolates and the echinocandins were found to be the most effective agents [22]. Voriconazole was the least active of the antifungals tested [11, 22] and amphotericin B was added only late in the course of the disease, which may be the reason for the poor outcome in this case.

It is possible that previous cases reported as *Aspergillus* or *Paecilomyces* might have actually been *Rasamsonia* species infections. We agree with other authors [10] and suggest that molecular fungal identification is warranted in future cases, which so far has only rarely been done in veterinary publications. A study has successfully validated a commercially available real-time PCR assay that reliably detected three species from the *R. argillacea* complex direct from clinical specimens and from culture isolates [23]. We believe

that the *Rasamsonia* species complex is potentially an underappreciated and misdiagnosed pathogen and that molecular approaches should be used in suspect cases because of the potentially aggressive disease pattern and refractoriness to medical treatment [6, 9, 11, 24].

Funding information

The authors received no specific grant from any funding agency.

Acknowledgements

The authors would like to thank the referring veterinarian Debbie Jack, and R(D)SVS Diagnostic Imaging Residents, namely Alison Major, Florence Thierry and Caroline Eivers, for their assistance in reaching the diagnosis.

Conflicts of interest

The authors report no conflicts of interest. The authors alone are responsible for the content and writing of the paper. The authors of this article have no financial or personal relationship with other people or organizations that could inappropriately influence or bias the content of the paper.

Ethical statement

No ethical approval was obtained because this study did not involve a prospective evaluation and did not involve laboratory animals.

References

- Ferrer C, Colom F, Frasés S, Mulet E, Abad JL et al. Detection and identification of fungal pathogens by PCR and by ITS2 and 5.8S ribosomal DNA typing in ocular infections. *J Clin Microbiol* 2001;39:2873–2879.
- Iryni L, Lackner M, de Hoog GS, Meyer W. DNA barcoding of fungi causing infections in humans and animals. *Fungal Biol* 2016;120:125–136.
- Houbraken J, Spierenburg H, Frisvad JC. *Rasamsonia*, a new genus comprising thermotolerant and thermophilic *Talaromyces* and *Geosmithia* species. *Antonie van Leeuwenhoek* 2012;101:403–421.
- Hong G, White M, Lechtzin N, West NE, Avery R et al. Fatal disseminated *Rasamsonia* infection in cystic fibrosis post-lung transplantation. *J Cyst Fibros* 2017;16:e3–e7.
- Doyon JB, Sutton DA, Theodore P, Dhillon G, Jones KD et al. *Rasamsonia argillacea* pulmonary and aortic graft infection in an immune-competent patient. *J Clin Microbiol* 2013;51:719–722.
- Giraud S, Pihet M, Razafimandimby B, Carrère J, Degand N et al. *Geosmithia argillacea*: an emerging pathogen in patients with cystic fibrosis. *J Clin Microbiol* 2010;48:2381–2386.
- Ishiwada N, Takeshita K, Yaguchi T, Nagasawa K, Takeuchi N et al. The first case of invasive mixed-mold infections due to *Emericella nidulans* var. *echinulata* and *Rasamsonia piperina* in a patient with chronic Granulomatous disease. *Mycopathologia* 2016;181:305–309.
- Matos T, Cerar T, Praprotnik M, Krivec U, Pirš M. First recovery of *Rasamsonia argillacea* species complex isolated in adolescent patient with cystic fibrosis in Slovenia—case report and review of literature. *Mycoses* 2015;58:506–510.
- Grant DC, Sutton DA, Sandberg CA, Tyler RD, Thompson EH et al. Disseminated *Geosmithia argillacea* infection in a German Shepherd dog. *Med Mycol* 2009;47:221–226.
- Salgüero R, Borman AM, Herrtage M, Benckekroun G, Abbondati E et al. *Rasamsonia argillacea* mycosis in a dog: first case in Europe. *Vet Rec* 2013;172:581.
- Houbraken J, Giraud S, Meijer M, Bertout S, Frisvad JC et al. Taxonomy and antifungal susceptibility of clinically important *Rasamsonia* species. *J Clin Microbiol* 2013;51:22–30.
- Schultz RM, Johnson EG, Wisner ER, Brown NA, Byrne BA et al. Clinicopathologic and diagnostic imaging characteristics of systemic aspergillosis in 30 dogs. *J Vet Intern Med* 2008;22:851–859.
- Geffré A, Concordet D, Braun JP, Trumel C. Reference Value Advisor: a new freeware set of macroinstructions to calculate reference intervals with Microsoft Excel. *Vet Clin Pathol* 2011;40:107–112.
- Robinson WF, Connole MD, King TJ, Pitt JI, Moss SM. Systemic mycosis due to *Aspergillus deflexus* in a dog. *Aust Vet J* 2000;78:600–602.
- Walker JT, Frazho JK, Randell SC. A novel case of canine disseminated aspergillosis following mating. *Can Vet J* 2012;53:190–192.
- Zhang S, Corapi W, Quist E, Griffin S, Zhang M et al. *Aspergillus versicolor*, a new causative agent of canine disseminated aspergillosis. *J Clin Microbiol* 2012;50:187–191.
- Day MJ, Eger CE, Shaw SE, Penhale WJ. Immunologic study of systemic aspergillosis in German shepherd dogs. *Vet Immunol Immunopathol* 1985;9:335–347.
- Day MJ, Penhale WJ. An immunohistochemical study of canine disseminated aspergillosis. *Aust Vet J* 1991;68:383–386.
- Day MJ, Penhale WJ. Humoral immunity in disseminated *Aspergillus terreus* infection in the dog. *Vet Microbiol* 1988;16:283–294.
- Day MJ, Penhale WJ, Eger CE, Shaw SE, Kabay MJ et al. Disseminated aspergillosis in dogs. *Aust Vet J* 1986;63:55–59.
- Stephen J, Ettinger ECF. *Textbook of Veterinary Internal Medicine: Diseases of the Dog and Cat*, 5th ed. Philadelphia: W.B. Saunders Co; 2000.
- Steinmann J, Dittmer S, Houbraken J, Buer J, Rath PM. *In vitro* activity of isavuconazole against *Rasamsonia* Species. *Antimicrob Agents Chemother* 2016;60:6890–6891.
- Steinmann J, Giraud S, Schmidt D, Sedlacek L, Hamprecht A et al. Validation of a novel real-time PCR for detecting *Rasamsonia argillacea* species complex in respiratory secretions from cystic fibrosis patients. *New Microbes New Infect* 2014;2:72–78.
- Valentin T, Neumeister P, Pichler M, Rohn A, Koidl C et al. Disseminated *Geosmithia argillacea* infection in a patient with gastrointestinal GvHD. *Bone Marrow Transplant* 2012;47:734–736.

Five reasons to publish your next article with a Microbiology Society journal

- The Microbiology Society is a not-for-profit organization.
- We offer fast and rigorous peer review – average time to first decision is 4–6 weeks.
- Our journals have a global readership with subscriptions held in research institutions around the world.
- 80% of our authors rate our submission process as 'excellent' or 'very good'.
- Your article will be published on an interactive journal platform with advanced metrics.

Find out more and submit your article at microbiologyresearch.org.