

Primary cutaneous aspergillosis caused by *Aspergillus fumigatus* in an immunocompetent patient

A case report

Xiaoyan Liu, MD^a, Jun Yang, MD^b, Weiyuan Ma, MD^{c,*}

Abstract

Rationale: Primary cutaneous aspergillosis in immunocompromised patients has been well described in extensive investigations. However, in immunocompetent hosts, primary cutaneous infection of aspergillus occurs rarely, and remains poorly characterized.

Patient concerns: We present a case of primary cutaneous aspergillosis manifested by erythematous plaque covered with flava eschar.

Diagnoses: The patient was diagnosed with primary cutaneous aspergillosis.

Interventions: Treatments with oral itraconazole at a dose of 75 mg/d and local wound care with ciclopirox olamine ointment were administered.

Outcomes: After half a month, a partial resolution and a decrease in tenderness indicated gradual improvement, and a complete remission was achieved 2 months later.

Lessons: Primary cutaneous aspergillosis could occur in immunocompetent hosts. The initial lesions may appear in different forms, including macules, papules, nodules, or plaques. Repeated biopsy of a skin lesion for both culture and histopathology is needed.

Abbreviation: HE = haematoxylin eosin.

Keywords: aspergillus fumigatus, cutaneous aspergillosis, immunocompetent

1. Introduction

In recent years, there has been a remarkable increase in the occurrence of primary cutaneous aspergillosis in immunocompromised patients. Primary cutaneous aspergillosis in immunocompromised patients has been well described in extensive

investigations. However, in immunocompetent hosts primary cutaneous infection of aspergillus occurs rarely and therefore remains poorly characterized. In this report, we present a case of primary cutaneous aspergillosis manifested by erythematous plaque covered with flava eschar.

Editor: N/A.

XL and JY contributed equally to this manuscript.

All procedures performed in this study involving human participant were in accordance with the 1964 Helsinki Declaration and its later amendments or comparable ethical standards. The detailed information regarding this study has been fully disclosed to the patient and his parents, and informed consent has been obtained from his parents.

This research did not receive any specific grant from funding agencies in the public, commercial, or not-for-profit sectors.

The authors have no conflicts of interest to disclose.

^aDepartment of Pulmonary Medicine, Peking Union Medical College Hospital, Chinese Academy of Medical Sciences, Beijing, China, ^bDepartment of Pulmonary Medicine, Ankang Central Hospital, Ankang, ^cDepartment of Dermatology, Qilu Hospital, Shandong University, Jinan, China.

*Correspondence: Weiyuan Ma, 107, Jinan culture road, Jinan 250000, China (e-mail: 521028128@qq.com).

Copyright © 2017 the Author(s). Published by Wolters Kluwer Health, Inc. This is an open access article distributed under the Creative Commons Attribution-NoDerivatives License 4.0, which allows for redistribution, commercial and non-commercial, as long as it is passed along unchanged and in whole, with credit to the author.

Medicine (2017) 96:48(e8916)

Received: 2 October 2017 / Received in final form: 3 November 2017 /

Accepted: 7 November 2017

<http://dx.doi.org/10.1097/MD.0000000000008916>

2. Methods

An approval from the ethics committee of the Qilu Hospital of Shandong University was obtained for this case report study. The detailed information regarding this study has been fully disclosed to the patient and his parents, and informed consent has been obtained from his parents.

3. Case report

A 9-year-old patient presented with erythematous plaque on his left cheek, he was scratched by a branch 3 months ago and a papule appeared on the wound site several days later, which progressively evolved into a slight tender but otherwise unremarkable nodule. Erythromycin ointment had been administered for a month. The lesion did not respond to erythromycin ointment, developed into an erythematous, irregular-shaped plaque measuring 3 × 4 cm covered by flava eschar (Fig. 1). The patient has been living in an orchard since he was born and prior to onset of the lesion he was healthy. History of using immunosuppressive agent or immunodeficient disorders was denied. The physical examination revealed nothing but the cutaneous lesion on the right side of the face. Blood routine, T and B lymphocyte subpopulation, and renal and hepatic function

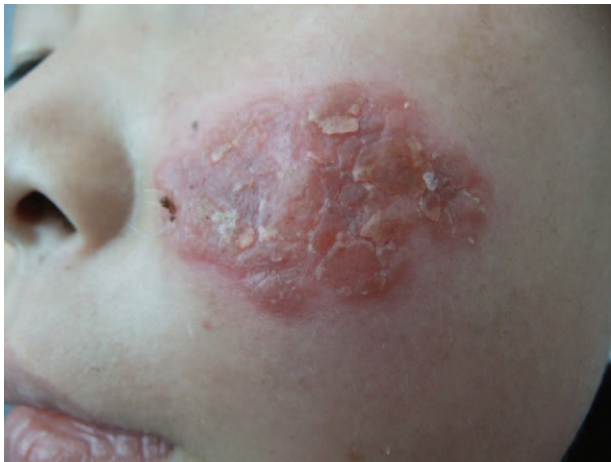

Figure 1. An erythematous plaque covered with flava eschar developed on the wound site.

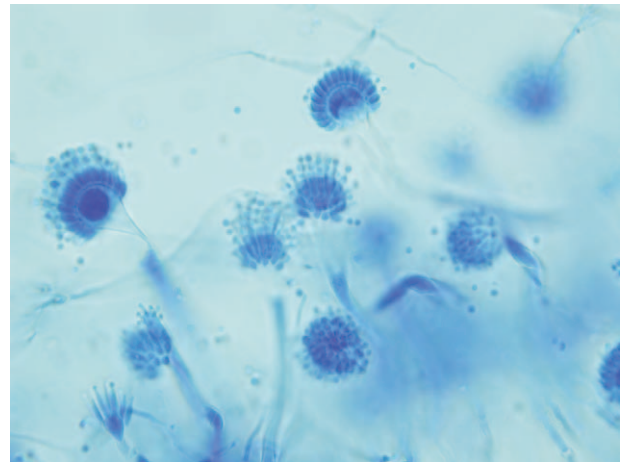


Figure 3. Macroscopic features of *Aspergillus fumigatus* (stain: lactophenole cotton blue).

tests were within normal limits. Skin biopsy was performed. Histopathologically, hematoxylin eosin staining of the skin biopsy specimen demonstrated dermal diffuse and nodular granulomatous infiltration with large amounts of lymphocytes, multinucleated giant cell, eosinophil, and neutrophil. Cultures of the biopsy material from the lesion on Sabouraud dextrose agar at 25°C and 37°C grew numerous and identical fungal colonies, which were dense, smoky, gray-green with a slight creamy-white reverse (Fig. 2). Microscopically, it was characterized by septate and hyaline hyphae, columnar conidia 2.5 to 3 μm in diameter which were produced in chains basipetally from single palisade-like layer phialides that were borne directly on broadly clavate vesicles (Fig. 3). On the basis of the above-mentioned characteristics the pathogen was identified as *Aspergillus Fumigatus*. Combining the clinical manifestation and histopathological and culture results, aspergillosis was diagnosed. Treatment included oral itraconazole at a dose of 75 mg/d and local wound care with ciclopirox olamine ointment. After half a month, a partial resolution and a decrease in tenderness indicated gradual improvement, and a complete recover was achieved 2 months later. No adverse events were reported during the treatment.

4. Discussion

We present a case of primary cutaneous aspergillosis in an immunocompetent patient. *Aspergillus* species are ubiquitous molds that can be isolated from the soil, air, dust, plants, skin, and nails.^[1] The previous study has shown that factors increasing the risk of aspergillosis include severe debilitating illnesses (e.g.,




Figure 2. *Aspergillus fumigatus* growing in Sabouraud dextrose agar.

cancer, burns, and chronic granulomatous diseases) and neutropenia (e.g., patients with leukemia, cytotoxic chemotherapy, corticosteroid therapy, broad-spectrum antibiotic therapy, and human immunodeficiency virus infection).^[2,3] However, no immunodeficient diseases or history of use of immunosuppressive agents was found in our patient.

The host defence mechanism against aspergillus species involves immunologic barriers and physical cutaneous barriers. Macrophages phagocytize aspergillus conidia, whereas polymorphonuclear leukocytes and monocytes damage aspergillus hyphae via oxidative and nonoxidative mechanism.^[4] Of great importance as well is the keratin and epidermal barriers of the skin that serve as an additional front line of mechanical host defence.^[1] It is important to note that our patient developed cutaneous *Aspergillus* infection despite his apparent immunocompetent state. We propose that the long-term inhabitation in the orchard that places the patient in exposure to high spore counts, together with the cutaneous injury—a portal of entry for the causative organism contributes to the infection.

The initial lesions of cutaneous aspergillosis may appear in different forms, including macules, papules, nodules, or plaques.^[5] The various clinical manifestations of cutaneous aspergillosis constitute a great diagnostic and therapeutic challenge, which in turn makes the repeated biopsy of a skin lesion for microbiology and pathology a prerequisite for a definitive diagnosis.

Once the diagnosis of aspergillosis is established, the subsequent efforts should be directed at determining whether the infection has disseminated to or arisen from extracutaneous site and the underlying impairment of patient immune system. Besides, the immune status of the infected patient should be evaluated as the host underlying immunity plays a critical role in the treatment of aspergillosis.^[6] Schimmelpfennig et al^[7] reported a case in which aspergillosis developed and progressed in a patient with chronic myeloid leukemia despite prompt therapy with amphotericin B. Resistance testing of *Aspergillus fumigatus* isolated from the lesion against amphotericin B showed that this species is fully sensitive to amphotericin B in vitro. The ineffectiveness of antifungal treatment in vivo associated with immunodeficient state necessitates approaches to the augmentation or the restoration of host defences. In our

case, the patient responded very well to oral itraconazole treatment, which is at least in part, thanks to his immunocompetent state.

As cutaneous aspergillosis could manifest in different ways, close attention should be paid to lesions that do not respond to antibacterial treatments, and clinicians should remain alert to the possibility of aspergillus infection even in an immunocompetent patient. Subsequent biopsy for microbiology and pathology is warranted for a well-established diagnosis.

References

- [1] Alberti C, Bouakline A, Ribaud P, et al. Relationship between environmental fungal contamination and the incidence of invasive aspergillosis in haematology patients. *J Hosp Infect* 2001;48:198–206.
- [2] Bernardeschi C, Foulet F, Ingen-Housz-Oro S, et al. Cutaneous invasive aspergillosis: retrospective multicenter study of the French invasive-aspergillosis registry and literature review. *Medicine (Baltimore)* 2015;94:e1018.
- [3] Walsh TJ. Primary cutaneous aspergillosis—an emerging infection among immunocompromised patients. Vol. 27, *Clinical infectious diseases: an official publication of the Infectious Diseases Society of America*. United States 1998;453–7.
- [4] Cramer RA, Rivera A, Hohl TM. Immune responses against *Aspergillus fumigatus*: what have we learned? *Curr Opin Infect Dis* 2011;24:315–22.
- [5] van Burik JA, Colven R, Spach DH. Cutaneous aspergillosis. *J Clin Microbiol* 1998;36:3115–21.
- [6] Tataru AM, Mikos AG, Kontoyiannis DP. Factors affecting patient outcome in primary cutaneous aspergillosis. *Medicine (Baltimore)* 2016;95:e3747.
- [7] Schimmelpfennig C, Naumann R, Zuberbier T, et al. Skin involvement as the first manifestation of systemic aspergillosis in patients after allogeneic hematopoietic cell transplantation. *Bone Marrow Transplant* 2001; 27:753–5.