


CASE REPORT

Pyogranulomatous pleuropneumonia caused by *Nocardia asiatica* in a dog coinfecting with canine morbillivirus (canine distemper virus)

Allyne Isabela Teixeira Ribeiro¹ | Mayara da Cruz Burema² | Ana Paula de Souza Borges³ |
 Vanessa Cristina de Melo Bruno⁴ | Pedro Eduardo Brandini Néspoli² |
 Edson Moleta Colodel³ | Fernando Henrique Furlan Gouvêa³ | Valéria Dutra⁴ |
 Luciano Nakazato⁴ | Márcio Garcia Ribeiro⁵ | Daniel Moura de Aguiar⁶ 

¹Infectious Diseases Sector, Veterinary Hospital of the Faculty of Veterinary (HOVET-FAVET), Federal University of Mato Grosso (UFMT), Cuiabá, MT, Brazil

²Imaging Diagnostic Service, HOVET-FAVET, UFMT, Cuiabá, MT, Brazil

³Laboratory of Veterinary Pathology, HOVET-FAVET, UFMT, Cuiabá, MT, Brazil

⁴Laboratory of Microbiology and Molecular Biology, HOVET-FAVET, UFMT, Cuiabá, MT, Brazil

⁵Department of Veterinary Hygiene and Public Health, São Paulo State University (UNESP), Botucatu, SP, Brazil

⁶Laboratory of Virology and Rickettsiosis, HOVET-FAVET, UFMT, Cuiabá, MT, Brazil

Correspondence

Daniel Moura de Aguiar, Laboratory of Virology and Rickettsiosis, HOVET-FAVET, UFMT, Avenida Fernando Corrêa, 2367, Cuiabá, MT 78060-900. Brazil.
 Email: danmoura@ufmt.br

Funding information

This work was supported by Conselho Nacional de Desenvolvimento Científico e Tecnológico, (Grant/Award Number: '303677/2018-0').

Abstract

Nocardia asiatica causing pyogranulomatous pleuropneumonia is reported for the first time in a dog coinfecting with canine morbillivirus (CM), diagnosed based on epidemiological, clinical, haematological, images, microbiological, histopathological, polymerase chain reaction and *hsp65* gene sequencing findings. The immunosuppression of CM probably favoured the opportunistic behaviour of *N. asiatica*. Despite the therapeutic measures, the animal died, mainly due to respiratory distress. The association of methods to improve early diagnosis, therapy procedures and prognosis of canine nocardiosis is discussed, as well as the close relationship between pets and their owners, which may favour the transmission of pathogens such as *Nocardia* from pets-to-humans, which poses an emerging public health issue.

KEYWORDS

actinomycetes, canine nocardiosis, combined infection, *hsp65*, sequencing

1 | INTRODUCTION

Nocardia are well-known actinomycetes characterized as saprophytic and telluric bacteria (Corti & Villafañe-Fiotti, 2002; Fatahi-Bafghi, 2018) found in soil, freshwater, saltwater and decaying vegetation

(Brown-Elliott, Brown, Conville, & Wallace, 2006; Ribeiro, 2010). To date, 92 species are recognized, 54 of which are clinically important (Corti & Villafañe-Fiotti, 2002). Although numerous species are described, their classification is still controversial, given the evolution of molecular diagnostic methods and the frequent changes in

This is an open access article under the terms of the Creative Commons Attribution-NonCommercial-NoDerivs License, which permits use and distribution in any medium, provided the original work is properly cited, the use is non-commercial and no modifications or adaptations are made.

© 2019 The Authors. *Veterinary Medicine and Science* Published by John Wiley & Sons Ltd.

taxonomy (Brown-Elliott et al., 2006). In spite of divergences regarding their classification, the main species associated with clinical disorders in dogs and cats are *Nocardia asteroides*, *N. brasiliensis*, *N. otitidiscaviarum*, *N. transvalensis*, *N. nova*, *N. farcinica* and *N. africana* (Ribeiro, 2010).

The transmission of the pathogen is commonly related to traumatic inoculation of the microorganism through tissues or inhalation of contaminated aerosols in both immunocompetent and immunosuppressed hosts, causing mainly percutaneous abscesses, pulmonary and/or neurological signs (Brown-Elliott et al., 2006).

Nocardia species are resistant to phagocytosis, which facilitates their dissemination and persistence in the host (Ribeiro, 2010). In humans, *Nocardia*-induced infections have been associated with immunocompromised patients either secondary to immunosuppressive therapy or people living with HIV/AIDS (Liu et al., 2011; Wang et al., 2015). Particularly in dogs, it is commonly reported in animals coinfecting with canine morbillivirus (CM; formerly canine distemper virus, CDV) or other immunosuppressive agents (Portilho et al., 2019; Ribeiro, 2010). Lymphocutaneous lesions, such as abscesses, nodules, ulcers and cellulitis especially in the cervicofacial region, are common clinical signs of canine nocardiosis. In complicated cases, they migrate through the haemolymphatic system affecting other organs such as the lungs and central nervous system (Conville et al., 2018).

The epidemiological aspects, clinical examination and complementary exams are commonly used in the routine clinical diagnosis of nocardiosis. Laboratory diagnosis requires identification of the bacterium based on cytology and microbiological culture. At present, species identification has been based on molecular methods, particularly the 16S rRNA gene sequencing (Brown-Elliott, Conville, & Wallace, 2015; Saubolle & Susslan, 2003).

The first-choice treatment of nocardiosis consists of broad-spectrum antimicrobials, in addition to previous in vitro sensitivity profile of isolates. Despite the in vitro susceptibility pattern, few antimicrobials can reach therapeutic concentrations at *Nocardia*-induced lesions due to the development of pyogranulomatous reactions, intracellular location of the pathogen and to the co-occurrence of immunosuppressive disorders (Conville et al., 2018; Ribeiro, 2010).

Canine morbillivirus is a highly contagious infectious disease caused by an immunosuppressive virus (Sykes, 2012) that affects the epithelial and nervous system of domestic dogs that may favour opportunistic coinfections, including by *Nocardia* species (Portilho et al., 2019).

In this scenario, we report for the first time a combined infection by *Nocardia asiatica* and CM in a puppy with pulmonary signs, in which haematological, imaging, microbiological, histopathological, polymerase chain reaction (PCR) and sequencing-based findings were assessed for diagnosis.

1.1 | Case report

In 2018, a 3-month-old female mixed breed with a 3-day history of purulent oculonasal discharge, coughing and hyporexia was admitted

to a veterinary hospital in the city of Cuiabá, state of Mato Grosso, central region of Brazil. According to the owner, the dog lived in an urban area, had free access to the street and no previous history of vaccination against CM or other infectious diseases. Due to its poor clinical condition, the dog was immediately hospitalized which has undergone clinical evaluation and subjected to complementary diagnostic methods, including complete blood count and thoracic radiography. Given their clinical evolution, thoracentesis was performed to drain pleural effusion. The material was immediately subjected to cytological evaluation (Diff Quik staining™, Newprov®) and microbiological culture in defibrinated sheep blood agar, MacConkey agar and Sabouraud dextrose agar, incubated at 37°C for 72 hr in aerobic conditions (Quinn et al., 2011). In addition, a swab of the ocular mucosa was collected to immunochromatographic test for the detection of CM (SensPERT Canine Distemper Virus Test™ [Cdv Ag], Vetall Laboratories®).

Antimicrobial therapy was prescribed using amoxicillin plus potassium clavulanate (20 mg/kg, BID) associated with acetylcysteine (5 mg/kg, TID), and chest percussion treatment for every 4 hr. Moreover, due to clinical signs suggestive of canine distemper, neuroprotectors (Gaballon™, 1/4 tablet, BID), vitamin A (50,000 IU, SID) and an immunostimulant (Thymomodulin™, 5 ml, SID) were included in the therapy. Two days after hospitalization, maropitant citrate (0.1 mg/kg, SID), tramadol hydrochloride (3 mg/kg, TID) and aminophylline (6 mg/kg, TID) were added to the therapeutic procedure due to complications of respiratory distress. The dog's clinical condition worsened, and notwithstanding critical care procedures, the animal died on the fourth day of hospitalization and was immediately subjected to necropsy.

Fragments of lungs and mediastinal lymph nodes were subjected to histopathology and purulent material collected from the lung nodules was submitted to genomic DNA extraction by the phenol chloroform method (Sambrook & Russel, 2012). The purulent lung material was subjected to partial amplification of the heat shock protein gene of approximately 65 kDa (*hsp65* heat shock protein) of *Nocardia* spp., as well as of other actinomycetes (Hoza, Mfinanga, Moser, & König, 2017). The fragments generated by PCR were purified using a GFX PCR DNA and Gel Band Purification Kit (GE Healthcare Bio-Sciences). Subsequently, the fragment was sequenced using a Big Dye Kit (Applied Biosystems, Perkin-Elmer) in an ABI PRISM-310 Genetic Analyzer, following the manufacturer's instructions. The resulting sequences were edited using BioEdit software (Ibis Biosciences) and analysed using the basic local alignment search tool (BLAST) to compare their identity with other sequences available in GenBank.

The sequence generated in the PCR was aligned by means of the MUSCLE program, using Geneious Prime® software, with 10 sequences of different isolates of *Nocardia* spp. from various parts worldwide, available at GenBank: *N. asteroides* (DQ789023), *N. nova* (MG765417), *N. asiatica* (JQ782424, JN041720, AY903631), *N. beijingensis* (KF420485), *N. pneumoniae* (AY903636), *N. araoensis* (AY903637) and *N. abscessus* (AY544983). Then, 405 characters were aligned. The phylogenetic tree for the isolate was inferred by

the Neighbour-Joining method, using Geneious Prime[®] software with the Jukes-Cantor substitution model. The values observed here represent the percentage of 500 resampling bootstraps. The homologous sequence of the HSP gene of *Mycobacterium fortuitum* (KF432769) was used as an outgroup pathogen.

2 | RESULTS

Upon clinical examination, the animal revealed fever (39.9°C), 6% dehydration and discomfort on abdominal palpation. A productive cough with whitish mucus, purulent nasal and ocular discharge and bilateral blepharitis were observed as well. Pulmonary auscultation revealed crackling on the left side of the thorax and respiratory distress. The main haematological findings were leukocytosis, neutrophilia, mild normochromic anaemia, activated monocytes, moderate anisocytosis and discrete polychromasia (Table 1). In addition, the immunochromatographic test for CM was positive.

A thoracic radiograph revealed pleural effusion, with partial loss of definition of the cardiac borders in a ventrodorsal position, homogeneous opacification of the left lung lobes, interlobar fissures, and retraction of the left caudal lobe. The right caudal lobe showed a moderate increase in the radiodensity of bronchial and alveolar patterns (Figure 1).

Approximately 20 ml of rose-colored pleural effusion was collected by thoracentesis. Cytological examination of effusion revealed high cellularity, with a predominance of neutrophils, lymphocytes, multinucleated giant cells and mesothelial cells. No growth of microorganisms was observed in the microbiological culture using a sample of pleural fluid.

The main macroscopic findings observed at necropsy were reddish fluid in the thoracic cavity, yellow material in the mediastinal

region, red translucent liquid in the pericardial cavity, lungs with firm texture and some purulent nodules (Figure 2). Gram-positive basophilic bacillary filamentous and branched structures were observed in the cytoplasm of macrophages from lung, using the Gram staining technique. These organisms showed partial alcohol acid resistance to Ziehl-Neelsen staining (Figure 3). Histopathological findings of the lung revealed the presence of an inflammatory infiltrate composed predominantly of macrophages, lymphocytes and plasmocytes, areas of fibrosis and multifocal caseous necrosis, associated with congestion, haemorrhage and fibrin deposition.

The PCR of purulent material from lungs resulted in an amplification of a fragment of 405 base pairs and this product was 100% similar to *N. asiatica* (JN041720, JQ782424). Based on an analysis of the phylogenetic tree, the sequence of the isolate was included in a clade composed of other *N. asiatica* isolates (Figure 4). The sequence of the *hsp65* gene generated in this study was deposited in GenBank under accession number MH421835.

3 | DISCUSSION

In this case, we report for the first time a combined infection by *N. asiatica* and CM in a dog with pulmonary signs, in which haematological, images, microbiological, histopathological, PCR, and sequencing diagnosis were assessed. The combined infection of the dog with CM, which is an immunocompromised agent, likely favoured the action of opportunistic pathogens, including *Nocardia* spp. This type of combined infection in dogs by pathogens has become increasingly common (Portilho et al., 2019; Sykes, 2012). In this scenario, a recent report describes triple infection by CM, *Rhodococcus equi* and *Toxoplasma gondii* in a dog with pneumonia; underscoring the influence of immunosuppression on pathogenic infections (Portilho et al., 2019).

Based on an analysis of the phylogenetic tree, the sequence of the isolate obtained from lung nodules was included in a clade composed of other *N. asiatica* isolates. The species of *Nocardia* that most affect humans are *N. asteroides* and *N. brasiliensis*. *N. asteroides*, *N. brasiliensis* and *N. otitidiscaviarum* have been identified in human patients with pulmonary and disseminated infections, and uncharacterized species have also been isolated from those patients (Wang et al., 2015). Likewise, in addition to *N. asteroides* and *N. brasiliensis*, *N. otitidiscaviarum* has also been reported in domestic animals (Beaman & Beaman, 1994; Conville et al., 2018; Sykes, 2012).

In humans, the first case of *N. asiatica* was reported in 2004, when five strains belonging to the same species were isolated from patients with nocardiosis (Kageyama, Poonwan, Yazawa, Mikami, & Nishimura, 2004). *Nocardia asiatica* has been described in patients causing brain (Jeong et al., 2017; Uneda et al., 2016) and lung (Okawa et al., 2015) abscesses, as well as mediastinal tumours (El-Herte, Kanj, Araj, Chami, & Gharzuddine, 2012). All these cases involved immunosuppression of patients due to some underlying condition (El-Herte et al., 2012; Jeong et al., 2017; Okawa et al., 2015; Uneda et al., 2016). However, *N. asiatica*-induced

TABLE 1 Haematology laboratory results of a case of canine nocardiosis by *Nocardia asiatica* in a dog coinfecting with canine morbillivirus

Blood count	Values	Reference ^a	
		Minimum	Maximum
Erythrocytes ($\times 10^6/\mu\text{l}$)	3.81	5.5	8.5
Haemoglobin (g/dl)	8.50	12	18
Haematocrit (%)	25	37	55
MCV (g/dl)	65.6	60	70
MCHC (g/dl)	34	32	36
Leukocyte ($/\mu\text{l}$)	43,800	6,000	17,000
Neutrophil ($/\text{mm}^3$)	34,200	3,000	11,500
Lymphocyte ($/\text{mm}^3$)	400	1,000	4,800
Monocyte ($/\text{mm}^3$)	8,300	150	1,350
Platelet ($/\text{mm}^3$)	305,000	200,000	500,000

MCHC, mean corpuscular hemoglobin concentration; MCV, mean corpuscular volume.

^aFeldman, Zinkl, Jain, and Schalm (2016).

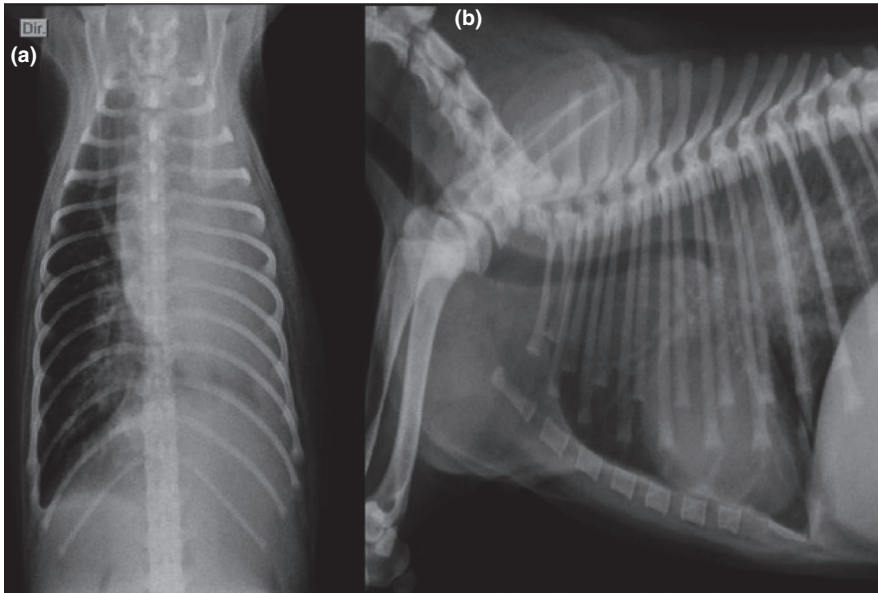


FIGURE 1 A, Ventrodorsal canine radiograph image. Image indicative of pleural effusion. In the right caudal lung lobe, note the moderate increase in bronchial pattern radiodensity. B, Latero-lateral radiograph image. Right caudal lung lobe presenting moderately augmented alveolar pattern radiodensity

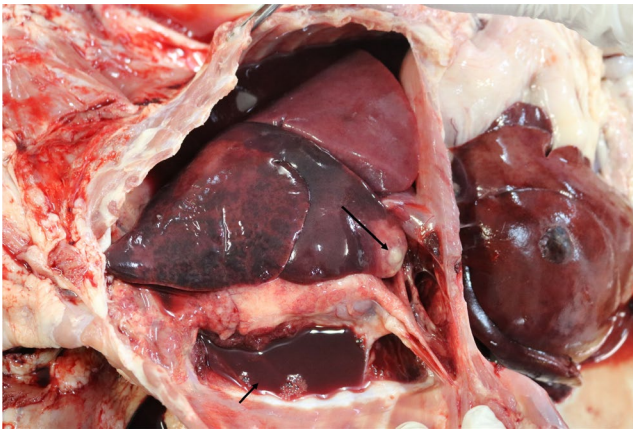

FIGURE 2 Opaque reddish liquid (~60 ml) in the thoracic cavity (small arrow) with coagulated clots and fibrin; amorphous, yellow, soft and lumpy material on the mediastinal region and red translucent liquid in the pericardial cavity. Lungs presenting nodule (large arrow), firm texture and irregular borders, hepatized aspect of parenchyma presenting some areas with purulent material. Intercostal muscles and parietal pleura exhibiting petechiae and suffusions on the intercostal muscles and parietal pleura

infections in domestic animals have not been reported or have gone unnoticed.

In the dog we reported, the main findings revealed by the complete cell count were marked leukocytosis (by neutrophilia), and mild normochromic anaemia. This result is expected because leukograms of domestic animals with bacterial pneumonia are characterized by neutrophilia with or without a left shift (Dear, 2014).

The main clinical manifestation of canine nocardiosis is lymphocutaneous, for example, abscesses, nodules, ulcers and lymphadenopathy in the cervicofacial and inguinal regions, and less frequently in the respiratory tract (Ribeiro, 2010; Sykes, 2012) as opposed to humans, where nocardiosis occurs mainly in the lungs (Okawa et al., 2015). However, the puppy reported here had no skin lesions. Upon admission to the veterinary hospital, the dog showed non-specific clinical signs, including fever, coughing, dehydration, hyporexia, ocular and nasal secretion, and abdominal discomfort suggestive of CM infection (Sykes, 2012), making the initial diagnosis difficult.

The radiological images were crucial to guide the initial diagnosis procedures, as well as a prognosis of the case. Pleural effusion

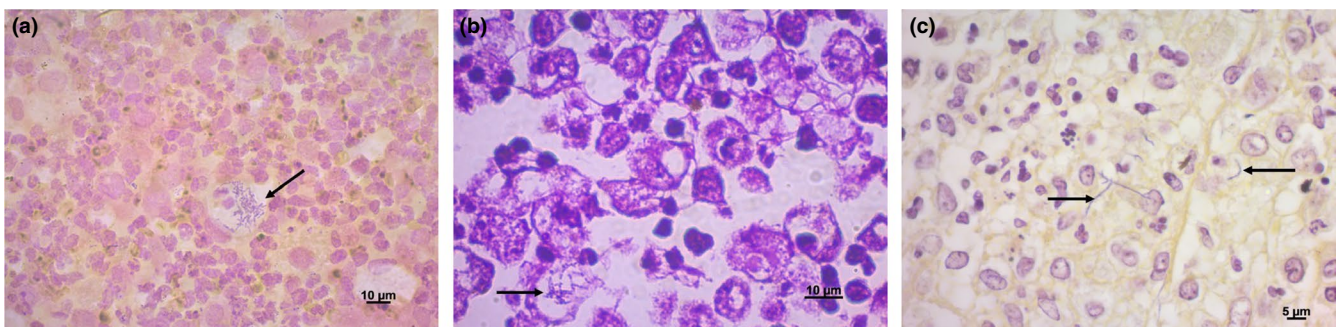


FIGURE 3 A, Gram-positive basophilic bacillary structures, filamentous and branched (arrow). B, Bacteria partially alcohol acid resistant to Ziehl-Neelsen staining. C, Filamentous format of *Nocardia* visualized by Wartin-Starry staining

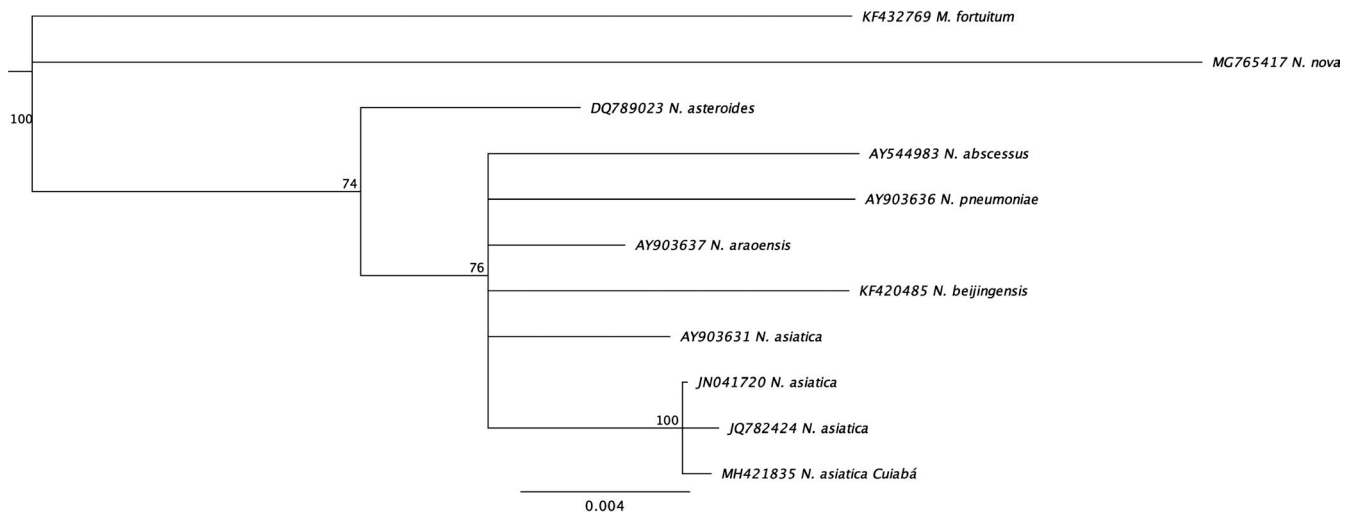


FIGURE 4 Phylogenetic tree constructed from the alignment of multiple sequences of the *hsp65* gene, inferred by the Neighbour-Joining method, using Geneious Prime® software. The sequence of *Mycobacterium fortuitum* was included as an outgroup

makes it difficult to evaluate the lungs since it can disguise important information such as the presence of masses both on the pulmonary surface and in the mediastinum. The characteristics of fluid draining from the thoracic cavity in the dog reported here are indicative of septic exudate (Alleman, 2003; Dempsey & Ewing, 2001). Given the predominance of neutrophils in the effusion, and based on the morphological characteristic of cells, the cytological findings were compatible with an acute inflammatory reaction, probably caused by bacteria (Alleman, 2003; Dempsey & Ewing, 2001).

Nocardia was not successfully isolated in the bacterial culture under the microbiological procedures employed in this case. Some species of pathogen grow more slowly than conventional bacteria and require more time for isolation, that is, up to 4 weeks (Conville et al., 2018). In this case, the culture media were kept for only 72 hr, which could justify no growth of *Nocardia* and may be considered a limitation of the current report.

CM also disseminates throughout the respiratory tract, causing mild bronchitis to bronchopneumonia (Sykes, 2012). A relevant clinical sign of pulmonary nocardiosis is haemoptysis, which was observed in this case as well, an indication of poor prognosis (Jeong et al., 2017; Ribeiro, 2010). This clinical complication occurs by the progression of the lesions to alveolar spaces, frequently eroding into blood vessels (Sykes, 2012). Less commonly, these lesions may spread to the lungs (Baldi, Santana, & Takagaki, 2006; Sykes, 2012) and compromise structures are in close proximity to the thorax, for example, the pleura, mediastinum, and pericardium (Sykes, 2012).

The main macroscopic necropsy findings of canine nocardiosis include abscesses and nodules containing purulent material in thoracic organs. Histopathological findings are characterized by pyogranulomatous reaction (Corti & Villafañe-Fioti, 2002; Saubolle & Susslan, 2003). The lungs of the puppy reported here, presented a hepatic appearance, consolidation, and intense purulent content in all the lobes. Histologically, an inflammatory infiltrate was also observed in the lungs with the presence of Gram-positive bacillary filamentous

and branching organisms, partially alcohol acid resistant, compatible with *Nocardia*-induced infections (Brown-Elliott et al., 2015; Corti & Villafañe-Fioti, 2002; Fatahi-Bafghi, 2018; Saubolle & Susslan, 2003).

Given that methods for the identification of *Nocardia* species based on phenotypic analysis are time-consuming, and that the pathogen has similar characteristics to those of other actinomycetes, for example, *Rhodococcus*, *Trueperella*, *Gordonia* and *Mycobacterium* species (Fatahi-Bafghi, 2018; Saubolle & Susslan, 2003). PCR targeting *hsp65* gene combined with sequencing has so far been used to identify *Nocardia*, the taxonomy of the genus and new species (Ribeiro et al., 2008). Although the target gene used in this case be more specific than other genes, for example, 16S rRNA, more sequences of *hsp65* gene are not widely available in public databases, which limits their use for comparison (Esch & Petersen, 2013; Patel et al., 2004). Nevertheless, the phylogenetic analysis of the amplicon generated from the lesion of the dog was enough to identify the isolate as *N. asiatica*.

The efficacy of treatment of generalized canine nocardiosis is poor (Ribeiro, 2010), since several factors may influence the success of a therapy: formation of pyogranulomas, low therapeutic rates of antimicrobials in foci of lesions, intracellular location of the pathogen in phagocytic cells and coinfection with immunosuppressive agents. The drug of choice used in the initial treatment of the dog described in this report was amoxicillin plus potassium clavulanate, which can be used as a monotherapy, or in combination (Sykes, 2012). However, retrospective studies on the susceptibility profiles indicated that *Nocardia* strains presented poor to intermediate sensitivity for amoxicillin plus potassium clavulanate (Ribeiro et al., 2008; Zhao et al., 2017), which could be associated with unsuccessful of therapy, leading to the death of the dog. Despite the approach of antimicrobial therapy, the death of the dog reported here reinforces the poor prognosis of generalized canine nocardiosis, especially in CM-induced coinfections (Ribeiro,

2010; Ribeiro et al., 2008; Sykes, 2012). To date, the most in vitro effective antimicrobials against *Nocardia* spp., including *N. asiatica*, is represented by amikacin, ceftiofur, ceftriaxone, gentamicin, imipenem and sulfamethoxazole/trimethoprim (Ribeiro et al., 2008; Zhao et al., 2017).

Overall, to our knowledge, pleuropneumonia caused by *N. asiatica* in a dog coinfecting with an immunosuppressive virus (CM) is reported for the first time, which likely worsened the clinical condition of the dog. In addition, we highlight the importance of nocardiosis in companion animals, which is still underestimated or goes unnoticed, either due to non-specific clinical signs or lack of access to laboratories to molecular diagnosis. The high sensitivity and specificity of molecular techniques makes them valuable diagnostic methods for the identification and taxonomic classification of *Nocardia*, in addition to knowledge of the virulence and molecular epidemiology of the pathogen, enabling early diagnosis and control measures against this agent.

The increasing number of companion animals and their importance for the physical and mental health of their owners have been described globally. Nevertheless, the close relationship and direct contact between pets and their owners may favour the transmission of pathogens from pets-to-humans (Esch & Petersen, 2013; Portilho et al., 2019), including by *Nocardia* species, which poses an emerging public health issue.

ETHICS STATEMENT

The authors confirm that the ethical policies of the journal, as noted on the journal's author guidelines page, have been adhered to. No ethics approval was required as no experimentation was conducted on the treated dog and the consultation was conducted normally.

ACKNOWLEDGEMENTS

The authors thank the Brazilian Ministry of Education (MEC) for scholarships awarded to A. Ribeiro, M. M. Burema, A. Borges, and V. Bruno, and the National Council for Scientific and Technological Development (CNPq) for research productivity grants awarded to V. Dutra, L. Nakazato, M.G. Ribeiro and D.M. Aguiar.

CONFLICT OF INTEREST

The authors report no conflict of interest.

ORCID

Daniel Moura Aguiar  <https://orcid.org/0000-0001-8631-522X>

REFERENCES

Alleman, A. R. (2003). Abdominal, thoracic, and pericardial effusions. *Veterinary Clinics of North America: Small Animal Practice*, 33, 89–118. [https://doi.org/10.1016/S0195-5616\(02\)00057-8](https://doi.org/10.1016/S0195-5616(02)00057-8)

- Baldi, B. G., Santana, A. N. C., & Takagaki, T. Y. (2006). Nocardiose pulmonar e cutânea em paciente usuário de corticosteroide. *Jornal Brasileiro De Pneumologia*, 32, 592–595. <https://doi.org/10.1590/S1806-37132006000600019>
- Beaman, B. L., & Beaman, L. (1994). *Nocardia* species: Host-parasite relationships. *Clinical Microbiology Reviews*, 7, 213–264. <https://doi.org/10.1128/CMR.7.2.213>
- Brown-Elliott, B. A., Brown, J. M., Conville, P. S., & Wallace, R. J. Jr (2006). Clinical and laboratory features of the *Nocardia* spp. based on current molecular taxonomy. *Clinical Microbiology Reviews*, 19, 259–282. <https://doi.org/10.1128/CMR.19.2.259-282.2006>
- Brown-Elliott, B. A., Conville, P., & Wallace, R. J. (2015). Current status of *Nocardia* taxonomy and recommended identification methods. *Clinical Microbiology Newsletter*, 37, 25–32. <https://doi.org/10.1016/j.clinmicnews.2015.01.007>
- Conville, P. S., Brown-Elliott, B. A., Smith, T., & Zelazny, A. M. (2018). The complexities of *Nocardia* taxonomy and identification. *Journal of Clinical Microbiology*, 56, e01419-17. <https://doi.org/10.1128/JCM.01419-17>
- Corti, M. E., & Villafañe-Fioti, M. F. (2002). Nocardiosis: A review. *International Journal of Infectious Diseases*, 7, 243–250. [https://doi.org/10.1016/S1201-9712\(03\)90102-0](https://doi.org/10.1016/S1201-9712(03)90102-0)
- Dear, J. D. (2014). Bacterial pneumonia in dogs and cats. *Veterinary Clinics of North America: Small Animal Practice*, 44, 143–159. <https://doi.org/10.1016/j.cvsm.2013.09.003>
- Dempsey, S. M., & Ewing, P. J. (2001). A review of the pathophysiology, classification, and analysis of canine and feline cavity effusions. *Journal of the American Animal Hospital Association*, 47, 1–11. <https://doi.org/10.5326/JAAHA-MS-5558>
- El-Herte, R. I., Kanj, S. S., Araj, G. F., Chami, H., & Gharzuddine, W. (2012). First report of *Nocardia asiatica* presenting as an anterior mediastinal mass in a patient with myasthenia gravis: A case report and review of the literature. *Case Reports in Infectious Diseases*, 2012, 325767. <https://doi.org/10.1155/2012/325767>
- Esch, K. J., & Petersen, C. A. (2013). Transmission and epidemiology of zoonotic protozoal diseases of companion animals. *Clinical Microbiology Reviews*, 26, 58–85. <https://doi.org/10.1128/CMR.00067-12>
- Fatahi-Bafghi, M. (2018). Nocardiosis from 1888 to 2017. *Microbial Pathogenesis*, 114, 369–384. <https://doi.org/10.1016/j.micpath.2017.11.012>
- Feldman, B. V., Zinkl, J. G., Jain, N. C., & Schalm, O. W. (2016). *Schalm's veterinary hematology* (6th ed.). New Jersey, NJ, USA: Wiley-Blackwell.
- Hoza, A. S., Mfinanga, S. G. S., Moser, I., & Konig, B. (2017). Isolation, biochemical and molecular identification of *Nocardia* species among TB suspects in northeastern, Tanzania; a forgotten or neglected threat? *BMC Infectious Diseases*, 17, 407. <https://doi.org/10.1186/s12879-017-2520-8>
- Jeong, J. H., Moon, S. M., Park, P. W., Ahn, J. Y., Kim, K. H., Seo, J. Y., ... Seo, Y. H. (2017). Multiple brain abscesses caused by *Nocardia asiatica* in a patient with systemic lupus erythematosus: The first case report and literature review. *Annals of Laboratory Medicine*, 37, 459–461. <https://doi.org/10.3343/alm.2017.37.5.459>
- Kageyama, A., Poonwan, K., Yazawa, Y., Mikami, Y., & Nishimura, K. (2004). *Nocardia asiatica* sp. nov., isolated from patients with nocardiosis in Japan, and clinical specimens from Thailand. *International Journal of Systematic and Evolutionary Microbiology*, 54, 125–130. <https://doi.org/10.1099/ijs.0.02676-0>
- Liu, W. L., Lai, C. C., Hsiao, C. H., Chien-Ching, H., Yu-Tsung, H., Chun-Hsing, L., & Po-Ren, H. (2011). Bacteremic pneumonia caused by *Nocardia veterana* in an HIV-infected patient. *International Journal of Infectious Diseases*, 15, 430–432. <https://doi.org/10.1016/j.ijid.2011.03.001>
- Okawa, S., Sonobe, K., Nakamura, Y., Nei, T., Kamio, K., & Gemma, A. (2015). Pulmonary nocardiosis due to *Nocardia asiatica* in an

- immunocompetent host. *Journal of Nippon Medical School*, 82, 159–162. <https://doi.org/10.1272/jnms.82.159>
- Patel, J. B., Wallace, R. J., Brown-Elliott, B. A., Taylor, T., Imperatrice, C., Leonard, D. G. B., ... Nachamkin, I. (2004). Sequence-based identification of aerobic *Actinomyces*. *Journal of Clinical Microbiology*, 42, 2530–2540. <https://doi.org/10.1128/JCM.42.6.2530-2540.2004>
- Portilho, F. V. R., Paes, A. C., Megid, J., Hataka, A., Neto, R. T., Headley, S. A., ... Ribeiro, M. G. (2019). *Rhodococcus equi* pVAPN type causing pneumonia in a dog coinfecting with canine morbillivirus (distemper virus) and *Toxoplasma gondii*. *Microbial Pathogenesis*, 129, 112–117. <https://doi.org/10.1016/j.micpath.2019.01.048>
- Quinn, P. J., Markey, B. K., Leonard, F. C., Hartigan, P., Fanning, S., & Fitzpatrick, E. S. (2011). *Veterinary microbiology and microbial disease* (2nd ed., p. 2011). Oxford, UK: Wiley-Blackwell.
- Ribeiro, M. G. (2010). Nocardiosis. In: C. M. Kahn (Ed.), *The Merck veterinary manual* (10th ed., pp. 72–75). Atlanta, GA: Merck & CO Inc.
- Ribeiro, M. G., Salerno, T., Mattos-Guaraldi, A. L. D., Camello, T. C. F., Langoni, H., Siqueira, A. K., ... Lara, G. H. B. (2008). Nocardiosis: An overview and additional report of 28 cases in cattle and dogs. *Revista do Instituto De Medicina Tropical De São Paulo*, 50, 177–185. <https://doi.org/10.1590/S0036-46652008005000004>
- Sambrook, J., & Russel, D. W. (2012). *Molecular cloning: A laboratory manual* (4th ed., p. 2012). New York, NY, USA: Cold Spring Harbor Laboratory Press.
- Saubolle, M. A., & Susslan, D. (2003). Nocardiosis: Review of clinical and laboratory experience. *Journal of Clinical Microbiology*, 41, 4497–4501. <https://doi.org/10.1128/JCM.41.10.4497-4501.2003>
- Sykes, J. E. (2012). Actinomycosis and nocardiosis. In C. E. Greene (Ed.), *Infectious diseases of the dog and cat* (4th ed., pp. 490–495). Louis, MO: Elsevier Saunders: St.
- Uneda, A., Suzuki, K., Okubo, S., Hirashita, K., Yunoki, M., & Yoshino, K. (2016). Brain abscess caused by *Nocardia asiatica*. *Surgical Neurology International*, 18, 74. <https://doi.org/10.4103/2152-7806.186509>
- Wang, H.-K., Sheng, W.-H., Hung, C.-C., Chen, Y.-C., Lee, M.-H., Lin, W. S., ... Chang, S.-C. (2015). Clinical characteristics, microbiology, and outcomes for patients with lung and disseminated nocardiosis in a tertiary hospital. *Journal of the Formosan Medical Association*, 114, 742–749. <https://doi.org/10.1016/j.jfma.2013.07.017>
- Zhao, P., Zhang, X., Du, P., Li, G., Li, L., & Li, Z. (2017). Susceptibility profiles of *Nocardia* spp. to antimicrobial and antituberculous agents detected by a microplate Alamar Blue assay. *Scientific Reports*, 7, 43660 <https://doi.org/10.1038/srep43660>

How to cite this article: Teixeira Ribeiro AI, da Cruz Burema M, de Souza Borges AP, et al. Pyogranulomatous pleuropneumonia caused by *Nocardia asiatica* in a dog coinfecting with canine morbillivirus (canine distemper virus). *Vet Med Sci*. 2020;6:25–31. <https://doi.org/10.1002/vms3.202>