

## Report of a Case that Expands the Phenotype of Infantile Krabbe Disease

Authors' Contribution:  
Study Design A  
Data Collection B  
Statistical Analysis C  
Data Interpretation D  
Manuscript Preparation E  
Literature Search F  
Funds Collection G

BDEF 1 **Marwan Nashabat**  
ABDE 2 **Sultan Al-Khenaizan**  
ADE 1 **Majid Alfadhel**

1 King Abdullah International Medical Research Centre, King Saud bin Abdulaziz University for Health Sciences, Genetic Division, Department of Pediatrics, King Abdulaziz Medical City, Ministry of National Guard Health Affairs (NGHA), Riyadh, Saudi Arabia  
2 King Abdullah International Medical Research Centre, King Saud bin Abdulaziz University for Health Sciences, Department of Dermatology, King Abdulaziz Medical City, Ministry of National Guard Health Affairs (NGHA), Riyadh, Saudi Arabia

**Corresponding Author:** Majid Alfadhel, e-mail: dralfadhel@gmail.com  
**Conflict of interest:** None declared

**Patient:** Female, 6  
**Final Diagnosis:** Krabbe disease  
**Symptoms:** Developmental delay • Atypical hypopigmentation lesions and hypoventilation  
**Medication:** —  
**Clinical Procedure:** —  
**Specialty:** Pediatrics and Neonatology





**Objective:** Rare disease  
**Background:** Krabbe disease, or globoid cell leukodystrophy, is an autosomal recessive disease caused by the deficiency of lysosomal galactocerebrosidase. The most common form is infantile Krabbe disease, which is usually diagnosed within the first year of life and has high morbidity and mortality. Patients usually present with irritability, progressive neurodegeneration, spasticity, and peripheral neuropathy. This report is of a 6-year-old girl who had Krabbe disease since she was 5 weeks of age.

**Case Report:** A 6-year-old female Saudi patient had initially presented at 5 weeks of age with hypoventilation, recurrent attacks of fever, and failure to thrive. The patient also skin hypopigmentation involving the face, neck, upper extremities, and lower extremities. Peripheral blood galactocerebrosidase enzyme activity was normal but was reduced in tissue fibroblasts. Whole exome sequencing (WES) and whole genome sequencing (WGS) showed a homozygous mutation in the *GALC* gene c.334A>G (p.Thr112Ala), which was previously reported in a compound heterozygous state with another mutation.

**Conclusions:** This case report describes a patient with homozygous mutation status Krabbe disease. Although this patient had the phenotype of early infantile-onset Krabbe disease, which usually has high morbidity and mortality, her condition is now relatively stable at 6 years of age, which could be due to relatively higher enzyme activity. This case also expanded the presentation or typical phenotype of infantile Krabbe disease as the patient also presented with hypoventilation and skin hypopigmentation.

**MeSH Keywords:** Hypopigmentation • Hypoventilation • Leukodystrophy, Globoid Cell

**Full-text PDF:** <https://www.amjcaserep.com/abstract/index/idArt/914275>

 1781   1  13



## Background

Krabbe disease, or globoid cell leukodystrophy, is an autosomal recessive disease that was first described by Krabbe in 1916 [1]. The symptoms and signs of Krabbe disease are caused by a deficiency of the enzyme, lysosomal galactocerebrosidase, which is responsible for the degradation of galactosylceramide and galactosylsphingosine [2]. The majority of patients with Krabbe disease present within the first year of life with the infantile form, with irritability, progressive neurodegeneration, spasticity, and peripheral neuropathy. Infantile Krabbe disease is associated with high morbidity and mortality [3]. Other phenotypes include juvenile Krabbe disease and adult Krabbe disease, which are associated with a better clinical outcome than the infantile form [3].

Early diagnosis of Krabbe disease can be made by measuring the activity of galactocerebrosidase in a sample of a dried spot of blood during the screening of newborn infants [4,5]. Radiological investigations can show diffuse brain and cerebellar atrophy, and demyelination can be identified by magnetic resonance imaging (MRI). Demyelination may also involve the spinal cord and cranial nerves [6]. Other diagnostic neurological investigations include nerve conduction studies, electroencephalography (EEG), auditory evoked responses, visual evoked potentials, and measurement of galactocerebrosidase levels [5].

The definitive diagnosis of Krabbe disease is made by measuring the activity and enzyme levels of galactocerebrosidase, which may show variable degrees of remnant activity of the enzyme. Sequencing studies of the *GALC* gene, which encodes the galactocerebrosidase enzyme, are also used to diagnose Krabbe disease [7].

The treatment of Krabbe disease is limited to palliative care for symptomatic patients. However, asymptomatic patients can be eligible for hematopoietic stem cell transplant (HSCT). The combination of gene therapy with HSCT is currently under investigation for patients with Krabbe disease [8].

This report is of a 6-year-old girl who had a diagnosis of Krabbe disease since she was 5 weeks of age.

## Case Report

### Clinical presentation at birth

A female Saudi patient was born at full-term by spontaneous vaginal delivery following an unremarkable pregnancy. Her parents were not consanguineous. At birth, her Apgar score was 9 at one minute and at five minutes following birth.

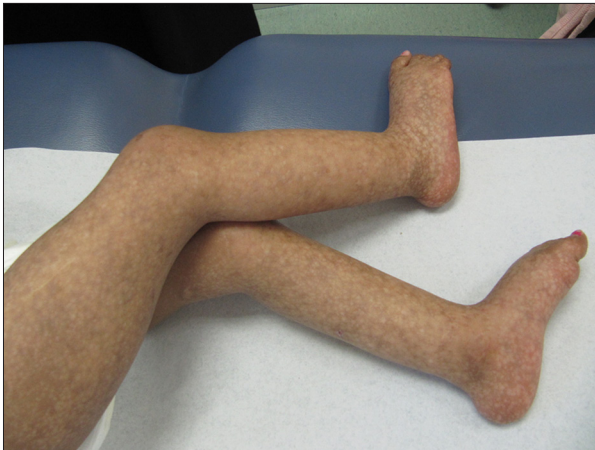Birth parameters were all average and included body length of 50 cm, weight of 2,615 gm, and head circumference of 34 cm. She appeared to be healthy at birth and was discharged home with her mother soon after birth. At the age of 5 weeks, she developed respiratory distress, fever, and was unable to feed, and she was admitted to the pediatric intensive care unit (PICU) to exclude sepsis. At that time, clinical examination showed low oxygen saturation of 70% on room air, a fever with a body temperature of 38.5°C, heart rate of 76 beats per minute, respiratory rate of 30 breaths per minute, and blood pressure of 90/51 mmHg.

### Clinical presentation at 5 weeks of age

On clinical presentation at 5 weeks of age, her growth parameters included a weight of 2,710 gm (<5<sup>th</sup> percentile), body length of 50 cm (5<sup>th</sup> percentile), and head circumference of 35 cm (25<sup>th</sup> percentile). On examination, she was floppy, pale, and had respiratory distress. She continued to be oxygen-dependent as she was found to have hypoventilation based on repeated sleep studies, which raised the possibility of a neuromuscular cause. She had a persistently high PCO<sub>2</sub> >50 mmHg (normal range, 35–45 mmHg). She had a prolonged hospital stay, during which time, extensive investigations were performed including biochemical, genetic and radiological tests that were all negative. Tandem mass spectrometry was performed on urine for organic acids, and on plasma for amino acids, and biochemical investigations for glycogen storage disease and neuronal ceroid lipofuscinosis were negative. Investigation of a gene panel for primary immune deficiency genes was unremarkable, and complement levels were normal.

### Clinical presentation at 4 months of age

At the age of 4 months, well defined multiple areas of skin hypopigmentation were identified in the upper limbs, lower limbs, and face. A skin biopsy taken from the lesions showed post-inflammatory hypopigmentation. The patient developed three attacks of fever of unknown origin within the first year of life, with a completely negative workup for sepsis. Further investigations included enzyme studies for galactocerebrosidase levels from a blood sample using tandem mass spectrometry, which showed a normal enzyme level at 0.45 μmol/l/h (normal, >0.3 μmol/l/h). Cerebrospinal fluid (CSF) analysis was unremarkable including the protein level at 0.19 g/L (normal, <0.4 g/L). *GALC* gene sequencing showed a homozygous variant, NM\_000153.3, c.334A>G (p.Thr112Ala). At the time, this gene variant had not been previously described in Krabbe disease, which was assumed not to confirm the diagnosis of Krabbe disease at that time. The patient's condition improved as she became afebrile and she was discharged from the hospital. Later, she had recurrent admissions to the hospital due to recurrent chest infections.



**Figure 1.** The lower limbs of a 6-year-old girl with Krabbe disease shows areas of skin hypopigmentation and the legs are extended and crossed.

Brain magnetic resonance imaging (MRI) was performed at the age of 2 months, which showed delayed myelination and later at 9 months of age, which was unremarkable. MRI of the spine, electroencephalography (EEG), and muscle and nerve biopsies were all unremarkable.

#### Clinical status at 6 years of age

At the time of writing this case report, the patient is 6 years of age and has global developmental delay. Current growth parameters include a height of 94 cm (<5<sup>th</sup> percentile), weight of 10.6 kg (<5<sup>th</sup> percentile), and head circumference of 50 cm (50<sup>th</sup> percentile). Her most recent physical examination showed spastic diplegia with crossed legs, mild laryngomalacia, and prominent skin hypopigmentation (Figure 1). No neurocutaneous stigmata were found. Ophthalmic examination showed a normal iris and normal fundus.

Whole exome sequencing (WES) and whole genome sequencing (WGS) showed the same homozygous variant in *GALC* gene, which was reclassified as pathological mutation following a published report of its association with Krabbe disease in a case of heterozygous disease combined with another mutation [9], and also a published report of a previous functional study [10]. The mutation was confirmed by Sanger sequencing. Segregation analysis showed that both parents, as well as a healthy sister, were heterozygous carriers for the mutation. Galactocerebrosidase enzyme activity from cultured fibroblasts was measured using fluorescent substrate 6-hexadecanoylamino-4-methylumbelliferyl- $\beta$ -D-galactoside (HMU), which showed low enzyme levels at 5.0 nmol/18 h/mg protein (normal range, 8–32 nmol/18 h/mg protein). A recent EEG showed intermittent background slowing, which was consistent with mild encephalopathy.

## Discussion

The course of infantile Krabbe disease consists of three consecutive stages. The first stage is characterized by irritability, spasticity, and fever of unknown origin. The second stage is characterized by developmental delay and worsening spasticity. In the third stage or end-stage Krabbe disease, the infants became decerebrate, blind, and unresponsive. Most of the patients with infantile Krabbe disease die within the first two years of life [8]. Although this patient's presentation fits the first and second stages of infantile Krabbe disease, she has never reached the third stage, as her condition at the age of 6 years has stabilized.

The unique presentation of this case, including skin hypopigmentation, involving the extremities (Figure 1) and the face, that spared the trunk have rarely been previously described in association with the clinical phenotypes of Krabbe disease. A recent review discussed the neuroinflammatory pathophysiology in Krabbe disease [11]. The authors of the review showed that inflammation often precedes demyelination, and described the factors that may explain inflammation, including the accumulation of the highly cytotoxic lipid, psychosine, and the induction of inflammatory cytokines [11]. The patient reported in this study had progressive skin hypopigmentation lesions, and the skin biopsy, showed post-inflammatory hypopigmentation, supporting the possibility of an inflammatory cause.

Reaching the definitive diagnosis for this patient was complicated by early lack of correct interpretation of the results, particularly the low blood galactocerebrosidase enzyme levels, which is expected to be low in Krabbe disease. In 2012, Jalal et al. investigated the correlation between the galactocerebrosidase enzyme levels and the phenotype and age of presentation of Krabbe disease [12]. They concluded that an increased enzyme level was associated with late onset of Krabbe disease, but that reduced activity of the enzyme did not determine the phenotype of the disease [12]. In this patient, although the enzyme activity in fibroblasts was slightly reduced, she had early infantile onset Krabbe disease, which might indicate that while reduced enzyme activity in a blood sample can confirm the diagnosis of Krabbe disease, normal enzyme activity may not exclude the diagnosis or predict the phenotype. Also, the correct type of method used to determine enzyme activity should be selected so that the correct diagnosis is made.

This case adds to the challenges in the biochemical diagnosis of lysosomal storage disease, in which testing the enzyme activity in cultured skin fibroblasts is recommended to confirm the diagnosis [13]. The mutation gene mutation identified in this patient, c.334A>G (p.Thr112Ala), was previously reported to be associated with the adult-onset Krabbe disease

phenotype but was combined in a compound heterozygous genotype with another mutation, c.592G>A (p.Glu198Lys) [9]. To the best of our knowledge, this is the first report to describe the phenotype of infantile Krabbe disease associated with the homozygous mutation c.334A>G (p.Thr112Ala). The effect of the p.T112A and p.I562T mutations on galactocerebrosidase enzyme activity was previously evaluated by Luzzi et al. who published the findings from a functional study that showed a significant reduction in the activity of the enzyme in COS-1 fibroblast-like cells *in vitro* that were transfected with pcDNA3 for both mutations [10].

In this case report whole exome sequencing (WES) and whole genome sequencing (WGS) was performed due to the atypical presentation of the patient, and to exclude the possibility of other genetic diseases. The phenotype and genotype of this patient support the view that there is no absolute correlation between genotype and phenotype in Krabbe disease [7]. Although this patient had the phenotype of early infantile-onset Krabbe disease, which usually has high morbidity and mortality, her condition is now relatively stable at the age of 6 years, which could be due to relatively higher enzyme activity.

## References:

1. Krabbe K: A new familial, infantile form of diffuse brain-sclerosis. *Brain*, 1916; 39(1-2): 74-114
2. Suzuki K, Suzuki Y: Krabbe's globoid cell leukodystrophy: Deficiency of galactocerebrosidase beta-galactosidase activity. *J Neuropathol Exp Neurol*, 1971; 30(1): 145
3. Duffner PK, Jalal K, Carter RL: The Hunter's Hope Krabbe family database. *Pediatr Neurol*, 2009; 40(1): 13-18
4. Wenger DA, Sattler M, Clark C, McKelvey H: An improved method for the identification of patients and carriers of Krabbe's disease. *Clin Chim Acta*, 1974; 56(2): 199-206
5. Allewelt H, Taskindoust M, Troy J et al: Long-term functional outcomes after hematopoietic stem cell transplant for early infantile Krabbe disease. *Biol Blood Marrow Transplant*, 2018; 24(11): 2233-38
6. Given CA 2<sup>nd</sup>, Santos CC, Durden DD: Intracranial and spinal MR imaging findings associated with Krabbe's disease: Case report. *Am J Neuroradiol*, 2001; 22(9): 1782-85
7. Wenger DA: Krabbe disease. In: Pagon RA, Adam MP, Ardinger HH et al. (eds.), *Gene Reviews*. Seattle, WA, 1993
8. Wenger DA, Rafi MA, Luzzi P: Krabbe disease: One hundred years from the bedside to the bench to the bedside. *J Neurosci Res*, 2016; 94(11): 982-89
9. Shao YH, Choquet K, La Piana R et al: Mutations in GALC cause late-onset Krabbe disease with predominant cerebellar ataxia. *Neurogenetics*, 2016; 17(2): 137-41
10. Luzzi P, Rafi MA, Wenger DA: Multiple mutations in the GALC gene in a patient with adult-onset Krabbe disease. *Ann Neurol*, 1996; 40(1): 116-19
11. Potter GB, Petryniak MA: Neuroimmune mechanisms in Krabbe's disease. *J Neurosci Res*, 2016; 94(11): 1341-48
12. Jalal K, Carter R, Yan L et al: Does galactocerebrosidase activity predict Krabbe phenotype? *Pediatr Neurol*, 2012; 47(5): 324-29
13. Wenger DA, Coppola S, Liu SL: Lysosomal storage disorders: Diagnostic dilemmas and prospects for therapy. *Genet Med*, 2002; 4(6): 412-19

## Conclusions

This case report has shown that clinicians should have a high index of suspicion for the diagnosis of Krabbe disease, and should not rely single clinical or diagnostic factors to exclude this rare disease. The early diagnosis and management of patients with Krabbe disease have an impact on patient outcome. In this case, the typical presentation of Krabbe disease included an expanded phenotype with a clinical presentation that included hypoventilation and skin hypopigmentation.

## Acknowledgments

The authors would like to thank the patient and her family for their agreement to publish this case report.

## Statement of ethics

Ethics approval and consent for publication were approved by the institutional review board (IRB) of King Abdullah International Medical Research Center (IRB approval number: RC16/113). Written informed consent for publication of this case was obtained from the parents.

## Conflict of interest

None.