

# The Use of Ultrasound to Exclude Extremity Fractures in Adults

Kaj Døssing, MD, Inger Mechlenburg, PhD, Lars Bolvig Hansen, MD, Kjeld Søballe, DMSc, and Helle Østergaard, MSc

*Investigation performed at the Orthopaedic Department, Viborg Regional Hospital, Denmark*

**Background:** The purpose of the present study was to investigate whether ultrasonography can be used as a diagnostic tool to exclude extremity fractures in adults.

**Methods:** This prospective comparative study involved 91 patients (age,  $\geq 18$  years) who had been referred by general practitioners for a conventional radiographic examination of a suspected extremity fracture. No additional clinical examination was performed. Ultrasound examination was consistently carried out prior to conventional radiographic examination, which was regarded as the gold standard. At the end of the study, the positive scans were confirmed by a specialist who was highly skilled in ultrasonography.

**Results:** The prevalence of fractures in the study population was 27%. Ultrasonography had a sensitivity of 92%, a specificity of 94%, a positive predictive value of 85%, a negative predictive value of 97%, a positive likelihood ratio of 15.33, and a negative likelihood ratio of 0.085. There seemed to be no association between the anomalous results and patient age or the specific anatomical region of the fracture.

**Conclusions:** The present study indicates that ultrasonography, when performed and interpreted by experienced ultrasonographers, has high accuracy for the diagnosis of a suspected extremity fracture. No systematic differences were found between the results of radiography and ultrasonography, and ultrasonography showed a high sensitivity and specificity.

**Level of Evidence:** Diagnostic Level II. See Instructions for Authors for a complete description of levels of evidence.

The conventional diagnostic approach for a suspected extremity fracture is usually a clinical and radiographic examination. The examination time is often long, and a large percentage of radiographs show no fracture and therefore could have been avoided. The use of ultrasonography as a diagnostic tool in cases of suspected fractures may have economic, prognostic, and clinical benefits, especially the reduced exposure to unnecessary radiation. A systematic review of 8 studies on the use of ultrasonography for the diagnosis of extremity fractures demonstrated a sensitivity of 85% to 100% and a specificity of 73% to 100%.<sup>1</sup> Few studies have investigated the interrater agreement associated with the use of ultrasonography for the assessment of patients with a suspected fracture. Barata et al.<sup>2</sup> reported a kappa value of 0.74, whereas Bolandparvaz et al.<sup>3</sup> reported kappa values of between 0.25 and 0.58, depending on the extremity examined. The aim of the present study was to investigate whether ultrasonography

can be used as a diagnostic tool to exclude extremity fractures in adults as a way to improve clinical decision-making. We hypothesized that the use of ultrasonography as a diagnostic tool to exclude extremity fractures in adults would (1) detect the same proportion of fractures as conventional radiography and (2) have a minimum sensitivity of 90% and a minimum specificity of 85% when conventional radiography was used as the gold standard.

## Materials and Methods

The present prospective comparative study was approved by the Central Denmark Region Committee on Biomedical Research Ethics (Journal number: M-1-16-02-75-13) and by the Danish Data Protection Agency (Journal number: 2007-58-0010). From February to November 2013, we evaluated 91 patients with a suspected extremity fracture, including 50 men and 41 women with a mean age (and

**Disclosure:** No external funds were received in support of this study. The **Disclosure of Potential Conflicts of Interest** forms are provided with the online version of the article (<http://links.lww.com/JBJSOA/A18>).

Copyright © 2017 The Authors. Published by The Journal of Bone and Joint Surgery, Incorporated. All rights reserved. This is an open-access article distributed under the terms of the [Creative Commons Attribution-Non Commercial-No Derivatives License 4.0](https://creativecommons.org/licenses/by-nc-nd/4.0/) (CCBY-NC-ND), where it is permissible to download and share the work provided it is properly cited. The work cannot be changed in any way or used commercially without permission from the journal.

TABLE I Demographic and Clinical Variables	
Demographic and Clinical Variables	Value
Sex (no. of patients)	
Male	50 (55%)
Female	41 (45%)
Age (yr)	
Mean and standard deviation	43 ± 16
Minimum	18
Maximum	79
Anatomical region (no. of patients)	
Hand	22 (24%)
Wrist	17 (19%)
Elbow	9 (10%)
Shoulder	2 (2%)
Foot	24 (26%)
Leg	15 (16%)
Knee	2 (2%)

standard deviation) of  $43 \pm 16$  years (Table I). All patients had been referred by their general practitioner to the Department of Radiology at Viborg Regional Hospital for the evaluation of a suspected extremity fracture, and all patients were included in the study on random days when at least 1 of 2 experienced ultrasound investigators (shoulder surgeon K.D. and shoulder physiotherapist H.Ø.) could perform the ultrasound examination. The inclusion criteria were a suspected closed fracture of an extremity, an age of  $\geq 18$  years, and referral to the department during the day. The exclusion criteria were an open fracture, an obvious fracture on

inspection, and a fracture involving the femoral neck or trochanter.

When a patient fulfilling the inclusion criteria arrived at the Department of Radiology, 1 of the 2 ultrasound investigators was called. The patient was informed about the study and, after written consent had been obtained, was enrolled in the study. The patient pointed to the area with maximum pain. No additional clinical examination was performed. As a consequence of this procedure, we always included a scan of the nearby bones.

#### Ultrasound Examination

Ultrasound examination was performed by 1 of the ultrasound investigators prior to conventional radiographic examination. The ultrasound examinations were carried out in accordance with a standardized protocol that had been pilot tested by the 2 investigators prior to initiation of the present study. A Philips HDII ultrasound system and L 12-5 linear transducer were used for all examinations. One scanner was used exclusively during the study period to ensure that the scan parameters were unchanged. Only depth and focus were adjusted according to the scanned structure. The extremity with a suspected fracture was scanned in the longitudinal and transverse planes of the bone with the transducer moved  $360^\circ$  around the bone (or as far as possible). Two sets of images were saved, 1 with a marker of the fracture and 1 without (Figs. 1, 2, and 3). The date and time of all images were registered, and a scan sheet for each patient was completed and saved with the images for documentation purposes. The baseline data that were entered included the patient name, injury date, scan date, and anatomical location. In addition, continuity breaches of bone, modified configuration of the bone,

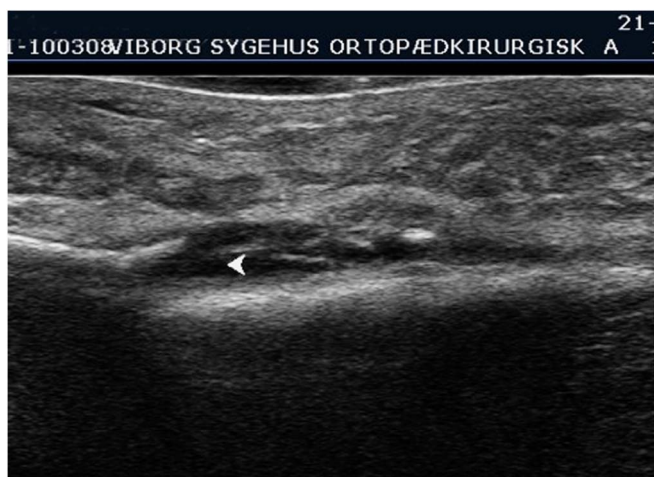

Fig. 1

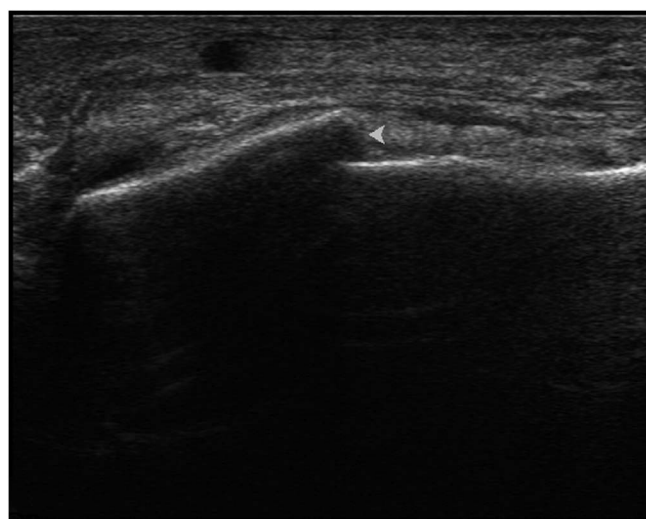


Fig. 2

**Fig. 1** Ultrasound scan showing a fracture in the ankle; this fracture is the same as that shown in the radiograph in Figure 4. The arrowhead shows the fracture as a discontinuity in the highly intense white line. **Fig. 2** Ultrasound scan showing a fracture in the fourth metacarpal; this fracture is the same as that shown in the radiograph in Figure 5. The arrowhead shows the fracture as a discontinuity in the highly intense white line.

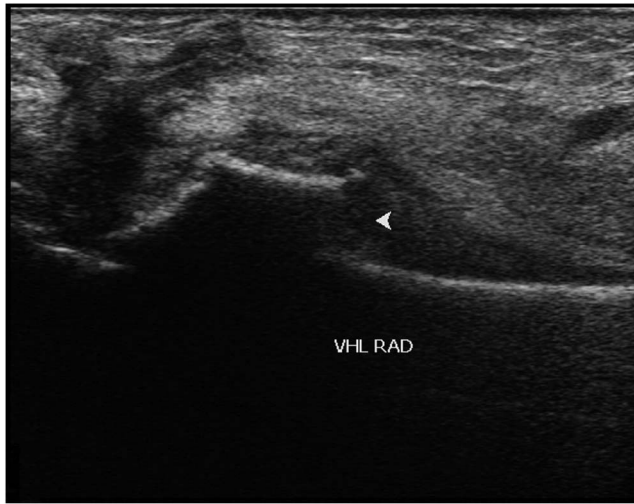


Fig. 3

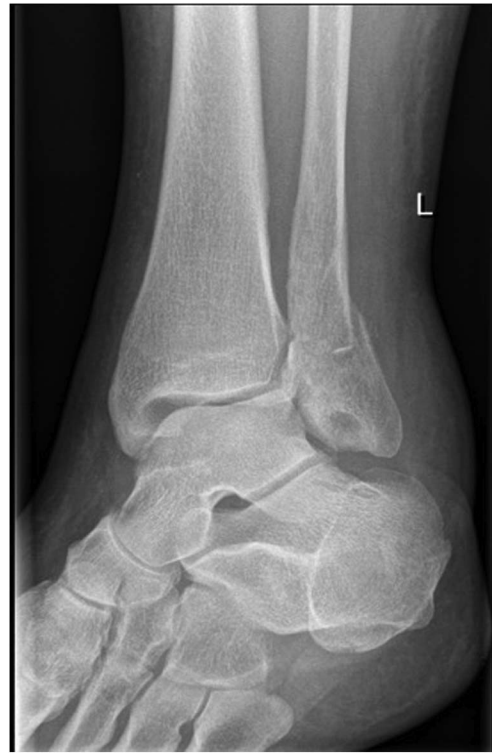

Fig. 4

**Fig. 3** Ultrasound scan showing a fracture in the distal aspect of the radius; this fracture is the same as that shown in the radiograph in Figure 6. The arrowhead shows the fracture as a discontinuity in the highly intense white line. **Fig. 4** Radiograph showing a fracture in the ankle.

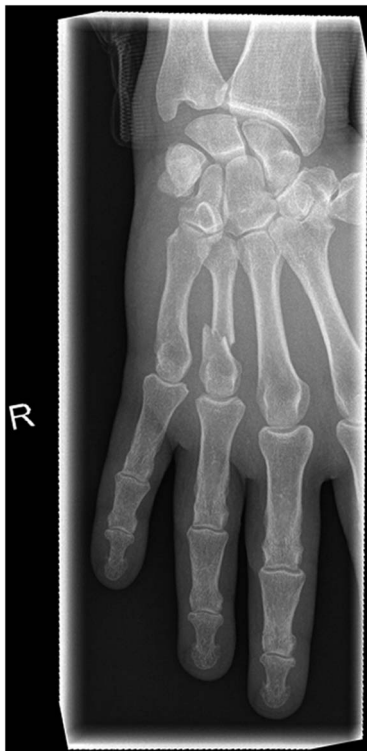

Fig. 5

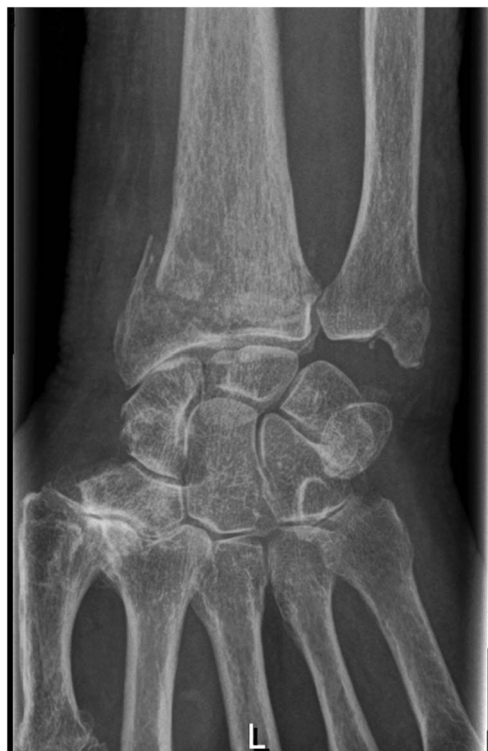

Fig. 6

**Fig. 5** Radiograph showing a fracture in the fourth metacarpal. **Fig. 6** Radiograph showing a fracture in the distal aspect of the radius.

**TABLE II Comparison of Ultrasound and Radiographic Findings\***

Ultrasound	Conventional Radiography (Gold Standard)		
	Fracture	Normal	Total
Fracture	23	4	27
Normal	2	62	64
Total	25	66	91

\*The values are given as the number of patients.

hematoma, and possible Doppler activity were recorded. The results were registered in an electronic database. After data collection was complete, all still ultrasound images for patients who were identified as having a fracture were verified by a radiologist specializing in musculoskeletal ultrasonography (L.B.H.).

#### *Conventional Radiographic Examination*

After ultrasound examination, a routine conventional radiographic examination was carried out on a Siemens Ysio system (Figs. 4, 5, and 6). The tentative diagnosis of the

**TABLE III Fracture Distribution According to Body Region**

Body Region	No. of Fractures Identified on Radiography	Ultrasonographic Findings*			
		True Positive	True Negative	False Positive	False Negative
Hand	6	5	14	1	1
Wrist	4	4	12	1	0
Elbow	0	0	2	0	0
Shoulder	3	2	6	0	1
Foot	10	10	14	0	0
Leg	2	2	11	2	0
Knee	0	0	2	0	0

\*The values are given as the number of each type of result on ultrasonography, with radiography used as the gold standard.

**TABLE IV Fracture Distribution According to Anatomical Region**

Anatomical Region	No. of Patients	Ultrasonographic Findings*			
		True Positive	True Negative	False Positive	False Negative
Clavicle	2	0	1	0	1
Shoulder	4	2	2	0	0
Humerus	2	1	1	0	0
Elbow	2	0	2	0	0
Distal part of radius	13	4	8	1	0
Scaphoid	5	0	5	0	0
Metacarpal	12	3	8	0	1
Finger	11	5	5	1	0
Knee	2	0	2	0	0
Ankle	14	2	10	2	0
Hindfoot	3	0	3	0	0
Midfoot	0	0	0	0	0
Forefoot	21	6	15	0	0

\*The values are given as the number of each type of result on ultrasonography, with radiography used as the gold standard.

referring doctor was registered. Images were assessed by an experienced radiologist, and conventional radiography was regarded as the gold standard. If a fracture was identified on radiographs, the patient was referred for relevant treatment at the hospital.

### Statistical Analysis

To test our first hypothesis, data were analyzed with use of the McNemar test. Odds ratios (ORs) with corresponding 95% confidence intervals (CIs) were calculated along with an exact *p* value to test for systematic differences. To test our second hypothesis, the sensitivity and the specificity as well as the positive and negative predictive values were calculated.

### Results

A total of 91 patients (55% men; mean age, 43 years) were included in the study (Table I). The prevalence of an extremity fracture was 27%. We tested for systematic differences between the results of ultrasound and conventional radiographic examination. There were 4 false-positive and 2 false-negative results (Table II). There were no systematic differences between the results of ultrasound and those of conventional radiography (*p* = 0.69). The 6 conflicting results were equally distributed with regard to patient age and anatomical region (Table III). A wide spectrum of bones were represented (Table IV). There was no displacement (<1 mm) of the fracture in 16 patients and displacement (≥1 mm) in 9 patients.

We hypothesized that the use of ultrasonography as a diagnostic tool would have a minimum sensitivity of 90% and a minimum specificity of 85% when conventional radiography was the gold standard for identifying fractures. We found that ultrasonography had a sensitivity of 92% (95% CI, 74% to 100%), a specificity of 94% (95% CI, 85% to 100%), a positive predictive value of 85% (95% CI, 66% to 96%), a negative predictive value of 97% (95% CI, 89% to 100%), a positive likelihood ratio of 15.33, and a negative likelihood ratio of 0.085. Thus, the probability of having a fracture if the ultrasound examination was positive was 85% and the probability of not having a fracture if the ultrasound examination was negative was 97%.

### Discussion

The purpose of the present study was to investigate whether ultrasonography can be used as a diagnostic tool to exclude extremity fractures in adults. We found that ultrasonography, when performed and interpreted by experienced ultrasonographers, had high accuracy as a diagnostic modality for the evaluation of suspected extremity fractures. There were no systematic differences between the results of ultrasound and those of conventional radiography, and ultrasound had a high sensitivity and specificity. This finding indicates that ultrasonography can be used as a diagnostic tool to exclude extremity fractures in adults.

The design of the present study differs from those of previous investigations. Our patients were referred directly from their general practitioner to the Department of Radiology at Viborg Regional Hospital, and no clinical examination by the investigators was performed prior to ultrasound examination. Therefore, we performed a fair comparison between ultrasonography and conventional radiography without additional clinical information that might have helped the investigator to diagnose or rule out a fracture. All patients who were diagnosed with a fracture on the basis of conventional radiography were referred for additional treatment. In the present study, ultrasound was associated with 2 false-negative results (missing 1 minimally displaced fracture of the base of the fifth metacarpal and 1 fracture in which a small piece of bone had been stripped from the clavicle) and 4 false-positive results (incorrectly identifying fractures in 1 finger, 1 wrist, and 2 ankles). All of the false-positive results were caused by irregularities in the bones.

When an examination method is compared with a gold standard, the agreement or systematic differences between the results of the 2 methods can be investigated. In the present study, the McNemar test demonstrated no systematic differences between the results of the 2 modalities. To our knowledge, no other studies have used the McNemar test and therefore comparison of our results is not possible.

There seemed to be no association between the conflicting results and the age of the patient or the specific anatomical region of the fracture. We performed no statistical tests because there were only 6 conflicting results—too few to test statistically. Some studies have indicated that it is particularly difficult to identify a fracture in the hand and in the metatarsals<sup>4-7</sup>, whereas other studies evaluating specific bones have shown good results<sup>8-10</sup>. Age did not seem to have an impact on whether a patient with a suspected fracture had a fracture or not<sup>11</sup>.

Only a few studies have examined the interrater agreement of ultrasound examinations to identify fractures. Barata et al. reported substantial agreement, with a kappa value of 0.74<sup>2</sup>. Bolandparvaz et al. reported much lower kappa values of between 0.25 and 0.58, depending on the scanned limb<sup>3</sup>; however, their study population involved patients with multiple trauma and was not fully comparable with our study population.

We acknowledge that the present study had some limitations. The prevalence of fractures that were verified with radiography was fairly low (27%) and there were few cases of disagreement between the 2 modalities (6.6%). The present study included a small, but representative, sample of a selected group of patients who were seen during the daytime. A larger study population would have enabled us to examine whether the accuracy of ultrasonography depends on which extremity is examined. Moreover, if conventional radiography did not provide true results of the examination, then the present study might be biased. Theoretically, the 4 patients in

whom a fracture was identified with ultrasound but not verified with conventional radiographs might actually have had a fracture, in which case the results of those examinations were misclassified and the discriminative ability of ultrasonography has been underestimated. Furthermore, the specificity of ultrasound may be overestimated because scaphoid fractures were included in the study and conventional radiography is not the gold standard for the diagnosis of scaphoid fractures. We did not follow up with the patients after the ultrasound and conventional radiographic examinations and thus do not know if any of the patients sought medical assistance after the initial referral to the hospital, nor do we have any cost data.

In conclusion, the present study indicates that ultrasonography, when performed and interpreted by experienced ultrasonographers, has high accuracy as a diagnostic modality for the evaluation of suspected extremity fractures. No systematic differences were found between the results of the 2 modalities, and ultrasonography showed a high sensitivity

and specificity and most notably a high negative predictive value. ■

Kaj Døssing, MD<sup>1</sup>  
Inger Mechlenburg, PhD<sup>2</sup>  
Lars Bolvig Hansen, MD<sup>2</sup>  
Kjeld Søballe, DMSc<sup>2</sup>  
Helle Østergaard, MSc<sup>1</sup>

<sup>1</sup>Orthopaedic Department (K.D.) and Department of Physiotherapy and Occupational Therapy (H.Ø.), Viborg Regional Hospital, Denmark

<sup>2</sup>Orthopaedic Department (I.M. and K.S.), Centre of Research in Rehabilitation (I.M.), and Radiological Department (B.H.), Aarhus University Hospital, Denmark

E-mail address for K. Døssing: kaj.doessing@viborg.rm.dk

ORCID iD for K. Døssing: [0000-0002-9657-6076](https://orcid.org/0000-0002-9657-6076)

## References

- Joshi N, Lira A, Mehta N, Paladino L, Sinert R. Diagnostic accuracy of history, physical examination, and bedside ultrasound for diagnosis of extremity fractures in the emergency department: a systematic review. *Acad Emerg Med*. 2013 Jan;20(1):1-15.
- Barata I, Spencer R, Suppiah A, Raio C, Ward MF, Sama A. Emergency ultrasound in the detection of pediatric long-bone fractures. *Pediatr Emerg Care*. 2012 Nov;28(11):1154-7.
- Bolandparvaz S, Moharamzadeh P, Jamali K, Pouraghaei M, Fadaie M, Sefidbakht S, Shahsavari K. Comparing diagnostic accuracy of bedside ultrasound and radiography for bone fracture screening in multiple trauma patients at the ED. *Am J Emerg Med*. 2013 Nov;31(11):1583-5. Epub 2013 Sep 21.
- Beltrame V, Stramare R, Rebellato N, Angelini F, Frigo AC, Rubaltelli L. Sonographic evaluation of bone fractures: a reliable alternative in clinical practice? *Clin Imaging*. 2012 May-Jun;36(3):203-8.
- Munk B, Bolvig L, Krøner K, Christiansen T, Borris L, Boe S. Ultrasound for diagnosis of scaphoid fractures. *J Hand Surg Br*. 2000 Aug;25(4):369-71.
- Christiansen TG, Rude C, Lauridsen KK, Christensen OM. Diagnostic value of ultrasound in scaphoid fractures. *Injury*. 1991 Sep;22(5):397-9.
- Carpenter CR, Pines JM, Schuur JD, Muir M, Calfee RP, Raja AS. Adult scaphoid fracture. *Acad Emerg Med*. 2014 Feb;21(2):101-21.
- Yesilaras M, Aksay E, Atilla OD, Sever M, Kalenderer O. The accuracy of bedside ultrasonography as a diagnostic tool for the fifth metatarsal fractures. *Am J Emerg Med*. 2014 Feb;32(2):171-4. Epub 2013 Nov 12.
- Kocaoğlu S, Özhasenekler A, İçme F, Pamukçu Günaydın G, Şener A, Gökhan Ş. The role of ultrasonography in the diagnosis of metacarpal fractures. *Am J Emerg Med*. 2016 Sep;34(9):1868-71. Epub 2016 Jun 29.
- Aksay E, Kilic TY, Yesilaras M, Tur FC, Sever M, Kalenderer O. Accuracy of bedside ultrasonography for the diagnosis of finger fractures. *Am J Emerg Med*. 2016 May;34(5):809-12. Epub 2016 Jan 12.
- Waterbrook AL, Adhikari S, Stolz U, Adrien C. The accuracy of point-of-care ultrasound to diagnose long bone fractures in the ED. *Am J Emerg Med*. 2013 Sep;31(9):1352-6. Epub 2013 Jul 26.