

# Duodenal Transection without Pancreatic Injury following Blunt Abdominal Trauma

Sanket Subhash Bankar, Vikas S. Gosavi, Mohd. Hamid

Department of General Surgery, Government Medical College, Miraj, India

## INTRODUCTION

Isolated duodenal transection is a rare occurrence following blunt abdominal trauma and its clinical picture is often obscure. High index of suspicion on the basis of mechanism of injury is important in early diagnosis. Early interventions in duodenal injuries have improved outcome. Here we report a case of complete duodenal transection following blunt abdominal trauma without pancreatic injury.

## CASE REPORT

A 26-year-old male presented with a history of road traffic accident due to head on collision between a bus and truck. Patient was admitted at a nearby hospital and then developed abdominal pain along with single episode of bilious vomiting the next morning. On examination, patient had tachycardia and hypotension along with tenderness in the upper abdomen. An abdominal ultrasonography showed a collection along the right para colic gutters and pelvic cavity along with gas artifacts in the hepatorenal pouch and right para colic gutters. X-ray erect abdomen was normal. Patient was resuscitated and on the basis of high index of clinical suspicion exploratory laparotomy was done which showed 50 ml collection in the peritoneal cavity with crepitations over duodenum with retroperitoneal collection. Kocherisation was done, and duodenum

## ABSTRACT

With the inventions of faster cars and even more faster motorbikes there is a worldwide increase in road traffic accidents, which has increased the incidence of blunt abdominal trauma but still duodenal injury following a blunt abdominal trauma is uncommon and can pose a formidable challenge to the surgeon and failure to manage it properly can result in devastating results. It may typically occur in isolation or with pancreatic injury. Here, we report a case of an isolated transection of the third part of the duodenum with normal pancreas following a blunt abdominal trauma. The initial clinical changes in isolated duodenal injury may be extremely subtle before life-threatening, peritonitis develops. Hence, a high index of suspicion, on the basis of mechanism of injury and physical examination is the key in early detection of duodenal injury especially in a rural hospital like ours where the facilities for computed tomography scan are not available.

**Key words:** Duodenal injury, peritonitis, transection

mobilized. There was complete transection of the third part of the duodenum [Figure 1] with normal pancreas. Edges were freshened and primary anastomosis was done with 3.0 mersilk in two layers. Whole length 20 Fr Ryle's tube was passed across the anastomosis and fixed. Another 16 Fr Ryle's tube was passed through opposite nostril into the stomach. Abdominal drains were kept in sub-hepatic space and the pelvis. Patient was kept nil per orally postoperatively and feeds were started on postoperative day 3 through Ryles tube passed across the anastomosis, and oral feeds were started on postoperative day 10. Postoperatively patient had normal serum amylase levels. Patient was discharged on postoperative day 40.

## DISCUSSION

Because of its retroperitoneal location isolated injuries to the duodenum are uncommon. However, due to this location, patients with injuries to the duodenum after a blunt abdominal trauma are diagnosed late, although more apparent injuries to other organs or vessels are addressed.<sup>[1,2]</sup> The duodenum is only mobile at the pylorus and its fourth part sharing its blood supply with the pancreas and because its proximity to the bile duct there is a high difficulty in suturing or resecting a segment of the duodenum, especially when the traumatic lesion involves its second part.<sup>[3]</sup>

### Access this article online

#### Quick Response Code:



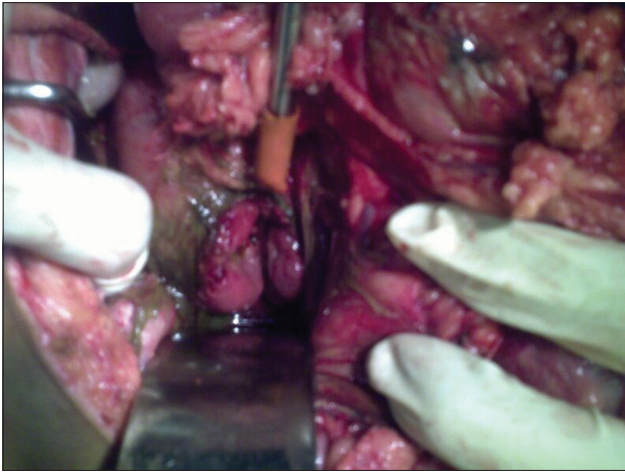
#### Website:

www.jstcr.org

#### DOI:

10.4103/2006-8808.147264

**Address for correspondence:** Dr. Sanket Subhash Bankar, Room No. 901, Golden Jubilee Building, Tata Memorial Hospital, Dr. E. Borges Road, Parel, Mumbai - 12, Maharashtra, India.  
E-mail: sanketbankar23@gmail.com



**Figure 1:** Duodenal transection

Injury to the duodenum following a blunt force can occur either by crushing the duodenum against the rigid vertebral column or due to the impact of shearing forces, as may occur during falls or bursting energy as seen in seat belt injury.<sup>[4,5]</sup> In our case, the most likely mechanisms of injury, based on the information from the site of the accident, were the combined effect of crushing and the impact of shearing forces.

Early diagnosis of a patient with a duodenal injury is priceless, and the time interval from injury to definitive treatment influences morbidity and mortality. The mortality rate shoots up from 11% to 40% if the patients are not explored within 24 h.<sup>[6]</sup> Information about the mechanism of injury and physical examination is valuable to suspect duodenal injury. However, the retroperitoneal location of duodenum may preclude early manifestations of injury, and physical examination may be misleading. Retroperitoneal duodenal perforation is usually subtle on presentation, although tachycardia, right upper-quadrant tenderness, vomiting and a progressive rise in temperature and heart rate are common findings in patients with this presentation.<sup>[7]</sup> When our patient was brought to the emergency room, he was hemodynamically unstable, presenting with abdominal pain and tenderness on examination, and with bilious vomiting. Information about the mechanism of injury combined with the clinical findings aroused our suspicion of an intraabdominal organ injury which prompted us for surgical intervention in this patient.

A computed tomography (CT) scan of the patient's abdomen with intraluminal and intravenous contrast is the diagnostic test of choice in stable patients with blunt abdominal trauma. However, CT scanning cannot always distinguish duodenal perforations from duodenal hematomas.<sup>[8,9]</sup> In our case, the deterioration of the

patient's clinical status including bilious vomiting and the inherent high suspicion of abdominal injury indicated the investigation of the intraperitoneal and retroperitoneal space with a CT scan. Although the CT scan could not be performed, ultrasonography findings combined with the clinical findings and the history of the accident increased our suspicion of a possible retroperitoneal duodenal injury. A combined pancreatico-duodenal injury is regarded as a separate category of injury, with a high mortality.<sup>[10]</sup> In this case, there was no associated pancreatic injury. As the third part of the patient's duodenum was completely transected, our choice for reconstruction was limited either to a primary end-to-end anastomosis or Roux-en-Y duodenojejunostomy with closure of the distal duodenal stump.<sup>[11]</sup> A primary end-to-end anastomosis was done as it is the preferred method in complete duodenal transection. With this technique, the restoration of the duodenal continuity is more physiological as there was no undue tension at the anastomotic sites, and the repair was technically easier. The patient presented with no other postoperative complications and was discharged on the 40<sup>th</sup> postoperative day in excellent condition. Hospital stay was prolonged due to associated compound fracture of right femur.

## CONCLUSION

Even in this modern era where technology forms a vital part in the diagnosis, clinical judgment of a surgeon based on the history and clinical examination still forms the crux in evaluating a patient with blunt abdominal trauma, especially in cases with duodenal injuries where early intervention makes a significant difference in the outcome of the patient. A Ryles tube can be used for proximal duodenal injuries if nasojejun tube is not available, especially in a rural setup where the resources are limited.

## REFERENCES

1. Allen GS, Moore FA, Cox CS Jr, Mehall JR, Duke JH. Delayed diagnosis of blunt duodenal injury: An avoidable complication. *J Am Coll Surg* 1998;187:393-9.
2. Fang JF, Chen RJ, Lin BC. Surgical treatment and outcome after delayed diagnosis of blunt duodenal injury. *Eur J Surg* 1999;165:133-9.
3. Asensio JA, Feliciano DV, Britt LD, Kerstein MD. Management of duodenal injuries. *Curr Probl Surg* 1993;30:1023-93.
4. Boone DC, Peitzman AB. Abdominal injury-duodenum and pancreas. In: Peitzman AB, Rhodes M, Schwab SW, Wealy DM, editors. *The Trauma Manual*. Philadelphia: Lippincott-Raven; 1998. p. 242.
5. Cocke WM Jr, Meyer KK. Retroperitoneal duodenal rupture. Proposed mechanism, review of literature and report of a case. *Am J Surg* 1964;108:834-9.
6. Lucas CE, Ledgerwood AM. Factors influencing outcome after blunt duodenal injury. *J Trauma* 1975;15:839-46.
7. Carrillo EH, Richardson JD, Miller FB. Evolution in the management of duodenal injuries. *J Trauma* 1996;40:1037-45.

8. Kunin JR, Korobkin M, Ellis JH, Francis IR, Kane NM, Siegel SE. Duodenal injuries caused by blunt abdominal trauma: Value of CT in differentiating perforation from hematoma. *AJR Am J Roentgenol* 1993;160:1221-3.
9. Timaran CH, Daley BJ, Enderson BL. Role of duodenography in the diagnosis of blunt duodenal injuries. *J Trauma* 2001;51:648-51.
10. Asensio JA, Buckman RF. Duodenal injuries. In: Ritchie WP, editor. *Shackelford's Surgery of the Alimentary Tract*. 4<sup>th</sup> ed., Vol. II. Philadelphia: WB Saunders; 1996. p. 110.
11. Degiannis E, Boffard K. Duodenal injuries. *Br J Surg* 2000;87:1473-9.

**How to cite this article:** Bankar SS, Gosavi VS, Hamid M. Duodenal transection without pancreatic injury following blunt abdominal trauma. *J Surg Tech Case Report* 2014;6:67-9.

**Source of Support:** Nil, **Conflict of Interest:** None declared.

### Author Help: Online submission of the manuscripts

Articles can be submitted online from <http://www.journalonweb.com>. For online submission, the articles should be prepared in two files (first page file and article file). Images should be submitted separately.

- 1) **First Page File:**  
Prepare the title page, covering letter, acknowledgement etc. using a word processor program. All information related to your identity should be included here. Use text/rtf/doc/pdf files. Do not zip the files.
- 2) **Article File:**  
The main text of the article, beginning with the Abstract to References (including tables) should be in this file. Do not include any information (such as acknowledgement, your names in page headers etc.) in this file. Use text/rtf/doc/pdf files. Do not zip the files. Limit the file size to 1 MB. Do not incorporate images in the file. If file size is large, graphs can be submitted separately as images, without their being incorporated in the article file. This will reduce the size of the file.
- 3) **Images:**  
Submit good quality color images. Each image should be less than 4096 kb (4 MB) in size. The size of the image can be reduced by decreasing the actual height and width of the images (keep up to about 6 inches and up to about 1800 x 1200 pixels). JPEG is the most suitable file format. The image quality should be good enough to judge the scientific value of the image. For the purpose of printing, always retain a good quality, high resolution image. This high resolution image should be sent to the editorial office at the time of sending a revised article.
- 4) **Legends:**  
Legends for the figures/images should be included at the end of the article file.