

“I have chicken fat in my urine!” A case of *Candida tropicalis* induced emphysematous pyelitis



Ahmed Alansari*, Manuel Duran Borrás, Noella Boma

Metropolitan Hospital Center, New York Medical College, New York 10029, USA

ARTICLE INFO

Article history:

Received 22 December 2015

Received in revised form

26 January 2016

Accepted 29 January 2016

Keywords:

Emphysematous pyelitis

Candida tropicalis

ABSTRACT

A patient with uncontrolled diabetes mellitus presented with fever and flank pain. A computed tomography scan showed free air within both collecting systems. A diagnosis of emphysematous pyelitis was made after other alternative diagnoses were ruled out. Urine culture grew *Candida tropicalis*. The emphysematous pyelitis resolved with conservative management using antifungal therapy.

© 2016 Published by Elsevier B.V. on behalf of International Society for Human and Animal Mycology

1. Introduction

Emphysematous urinary tract infections (UTIs) are infections associated with gas formation that may present as cystitis, pyelitis, or pyelonephritis. Uncontrolled diabetes mellitus is a major risk factor for this type of infection, as it provides a favorable micro-environment for the gas forming organisms to grow [1,2]. We present a case of emphysematous pyelitis caused by *Candida tropicalis* with good outcome due to early recognition and treatment.

2. Case

A 49 year old man presented to the emergency department on day 0 with a two week history of intermittent right flank pain associated with nausea and vomiting. His medical history included diabetes mellitus, hepatitis C, schizophrenia, and intravenous (IV) substance abuse. His home medications included nateglinide, metformin, clonazepam, risperidone, fluoxetine, trazodone, and benztropine.

On initial physical examination, he had a fever of 38.7 °C (101.6 °F), blood pressure of 150/80 mm Hg with a heart rate of 80 beats per minute, and right costovertebral angle tenderness, with otherwise unremarkable findings. The initial laboratory workup showed a hyperglycemia of 496 mg/dl, but no leukocytosis or abnormal renal functions. Urine analysis was positive for white and red blood cells with negative nitrite and leukocyte esterase. Urine and blood cultures were sent to the lab for cultures.

Computed tomography (CT) scan showed free air within both collecting systems and urinary bladder with no signs of air inside the renal parenchyma. Both kidneys were edematous with perinephric stranding (Fig. 1).

IV ceftriaxone and insulin therapy were started, foley catheter was placed, and urine cytology was sent to the lab. On further questioning, the patient reported passing friable pinkish material with his urine, “like chicken fat” he described. On day 1, the patient's fever persisted and antibiotic were switched to piperacillin-tazobactam. On day 2, the hemoglobin A1c was 14.9% and a repeat CT scan with IV contrast was still suggestive of emphysematous pyelitis (Fig. 2). Enterovesical fistula was ruled out by an oral-activated charcoal test.

On day 4, urine cytology showed numerous yeast cells. The urine culture came back positive for *C. tropicalis* (> 100,000 CFU/ml) identified by Vitek MS system. IV fluconazole 400 mg was started followed by 200 mg daily. On day 5, the fever resolved and his symptoms improved. A final CT scan on day 6 showed resolution of the emphysematous pyelitis with some remaining mild parenchymal edema and he remained afebrile. The patient was discharged on oral fluconazole 200 mg to complete two weeks of therapy.

3. Discussion

Emphysematous infections are usually caused by gas-producing organisms; mainly bacterial like *Escherichia coli*, *Klebsiella pneumoniae*, *Proteus mirabilis* and *Pseudomonas aeruginosa*. Fungal etiology has rarely been reported, but in this case the infection was caused by *C. tropicalis* [3]. Emphysematous infections should be higher on the differential for diabetic patients. The method of

* Corresponding author.

E-mail address: aalansari.md@gmail.com (A. Alansari).

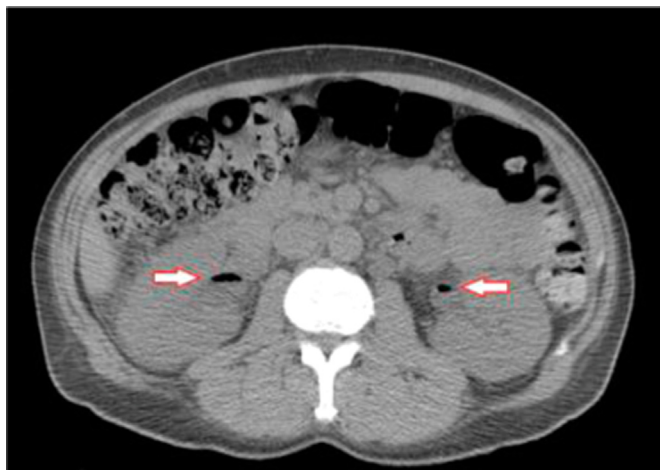


Fig. 1. Initial abdominal CT scan with air in the bilateral collecting system.

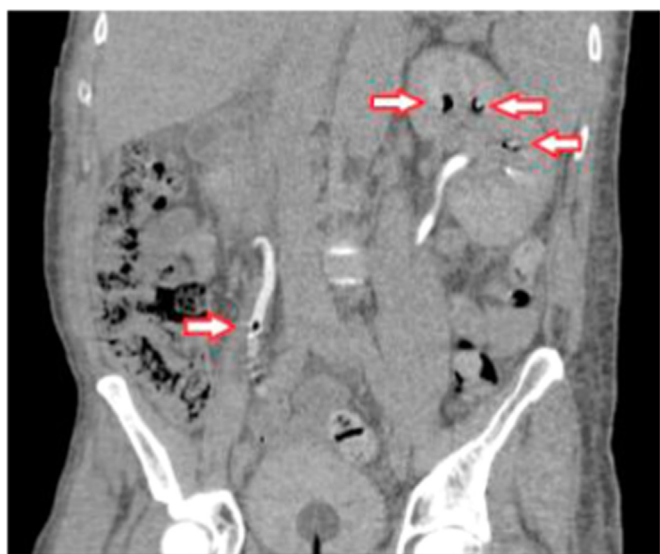

Fig. 2. Follow up CT abdomen showing air in the left collecting system and right ureter.

choice for diagnosis and follow up of emphysematous UTI is CT scan. Furthermore, Huang and Tseng et al. classify emphysematous

pyelonephritis or pyelitis into four classes. Class 1, is when gas is only limited to the collecting system. In class 2, gas is found in the renal parenchyma without extension to the extrarenal space. In class 3A, gas extends to the perinephric space and in class 3B, it extends to the pararenal space. In class 4, there is bilateral renal involvement or emphysematous pyelonephritis of a solitary kidney [1,4].

The new approach in treating emphysematous UTIs is the use of systemic antibiotics, together with percutaneous drainage of gas and purulent material. If urinary tract obstruction is present, it must be relieved as well [5–7]. In this case, the patient was class 1 and was successfully managed by systemic antibiotic and antifungal therapy, together with decompression of the urinary system by foley catheter. No invasive intervention was required. He responded well to treatment, mainly due to early diagnosis, sequential radiological assessment, and the fact that it was pyelitis rather than pyelonephritis.

Conflict of interest

There are none.

Acknowledgments

There are none.

References

- [1] J.J. Huang, C.C. Tseng, Emphysematous pyelonephritis: clinicoradiological classification, management, prognosis, and pathogenesis, *Arch. Intern. Med.* 160 (2000) 797.
- [2] M. Grupper, A. Kravtsov, I. Potasman, Emphysematous cystitis: illustrative case report and review of the literature, *Medicine (Baltimore)* 86 (2007) 47.
- [3] J.M. Wang, H.K. Lim, K.K. Pang, Emphysematous pyelonephritis, *Scand. J. Urol. Nephrol.* 41 (2007) 223–229.
- [4] I.B. Dubey, V. Agrawal, B.K. Jain, Five patients with emphysematous pyelonephritis, *Iran J. Kidney Dis.* 5 (2011) 204–206.
- [5] C. Roy, D.D. Pfeiffer, C.M. Tuchmann, et al., Emphysematous pyelitis: findings in five patients, *Radiology* 218 (2001) 647.
- [6] J.H. Mydlo, G.J. Maybee, M.M. Ali-Khan, Percutaneous drainage and/or nephrectomy in the treatment of emphysematous pyelonephritis, *Urol. Int.* 70 (2003) 147.
- [7] B.K. Somani, G. Nabi, P. Thorpe, et al., Is percutaneous drainage the new gold standard in the management of emphysematous pyelonephritis? Evidence from a systematic review, *J. Urol.* 179 (2008) 1844.