



Contents lists available at ScienceDirect

International Journal of Surgery Case Reports

journal homepage: www.casereports.com

Case report on the non-operative management of a retrievable inferior vena cava filter perforating the duodenum

Joseph S. Fernandez-Moure^{a,b,1}, Keemberly Kim^c, M. Haseeb Zubair^{a,1}, Wade R. Rosenberg^{a,*}^a Houston Methodist Hospital, Dept. of Surgery, 6550 Fannin Street, Houston, TX 77030, United States^b Department of Regenerative and Biomimetic Medicine, Houston Methodist Research Institute, 6670 Bertner Ave., Houston, TX 77030, United States^c Texas A&M College of Medicine, 8447 TX-47, Bryan, TX 77807, United States

ARTICLE INFO

Article history:

Received 11 April 2017

Received in revised form 23 June 2017

Accepted 25 June 2017

Available online 10 July 2017

Keywords:

Filter

Perforation

Duodenum

Melena

Inferior vena cava

ABSTRACT

INTRODUCTION: Deep vein thrombosis (DVT) continues to be a significant source of morbidity for surgical patients. Placement of a retrievable inferior vena cava (IVC) filter is used when patients have contraindications to anticoagulation or recurrent pulmonary embolism despite therapeutic anticoagulation. Although retrievable IVC filters are often used, they carry a unique set of risks.

PRESENTATION OF CASE: A 67-year-old man presents to the Emergency Room (ER) following large volume melena and complaining of syncope. One year prior, the patient had been diagnosed with Glioblastoma multiforme, for which he underwent a craniotomy with near-total resection of the mass. He subsequently developed a deep vein thrombosis and underwent placement of a retrievable inferior vena cava (IVC) filter. Computerized tomography (CT) and esophagogastroduodenoscopy showed duodenal perforation by the retrievable IVC filter. The filter was successfully retrieved through an endovascular approach.

DISCUSSION: Retrievable IVC filter placement is the preferred method of pulmonary embolism prevention in patients with significant risk for bleeding. Duodenal perforation by a retrievable IVC filter is a rare and serious complication. It is usually managed surgically, but can also be managed non-operatively.

CONCLUSION: For patients with significant comorbidities or patients who are poor surgical candidates, non-operative management with close monitoring can serve as an initial approach to the patient with a caval enteric perforation secondary to a retrievable IVC filter.

© 2017 Published by Elsevier Ltd on behalf of IJS Publishing Group Ltd. This is an open access article under the CC BY-NC-ND license (<http://creativecommons.org/licenses/by-nc-nd/4.0/>).

1. Introduction

Deep vein thrombosis (DVT) continues to be a significant source of morbidity for surgical patients [1]. The physiologic conditions that predispose a patient to the development of DVT are stasis, endothelial injury, and inflammation; these are known as Virchow's Triad [2]. Other risk factors for DVT are cancer, pregnancy and trauma [3–5]. Once a DVT is diagnosed, treatment is required and consists of therapeutic anticoagulation or inferior vena cava interruption via filter placement.

The only other treatment option for DVT in patients with significant risk for bleeding is placement of inferior vena cava (IVC) filters [6]. The primary indications for IVC filters include contraindications to anticoagulation and recurrent pulmonary embolism despite therapeutic anticoagulation; IVC filters can also be used as an adjunctive therapy in people with poor cardiopulmonary

capacity or respiratory and hemodynamic compromise [7,8]. However, this modality of treatment carries its own risks, such as IVC penetration (0–41%), IVC occlusion (2–40%), access site thrombosis (0–25%), insertion complication (5–23%), filter migration (0–18%), filter fracture (2–10%), IVC filter deployment outside of the target region (1–9%), recurrent pulmonary embolism (PE) (0.5–6%), filter embolization (<1%), and death (0.12%) [3,9]. Inferior vena cava perforation can cause significant hemorrhage and can result in a surgical emergency. In this case study, we report on the management of duodenal perforation by an indwelling retrievable IVC filter resulting in gastrointestinal bleed. This work has been reported in line with the SCARE criteria [19].

2. Case report

A 67-year-old Chinese man presented to the emergency room (ER) following large volume of melena and complaining of syncope. Approximately one year earlier, the patient was diagnosed with Glioblastoma multiforme (GBM), for which he underwent a craniotomy with near-total resection of the mass. He subsequently developed a deep vein thrombosis during the course of his

* Corresponding author.

E-mail address: wrosenberg@houstonmethodist.org (W.R. Rosenberg).¹ Authors contributed equally to this work.

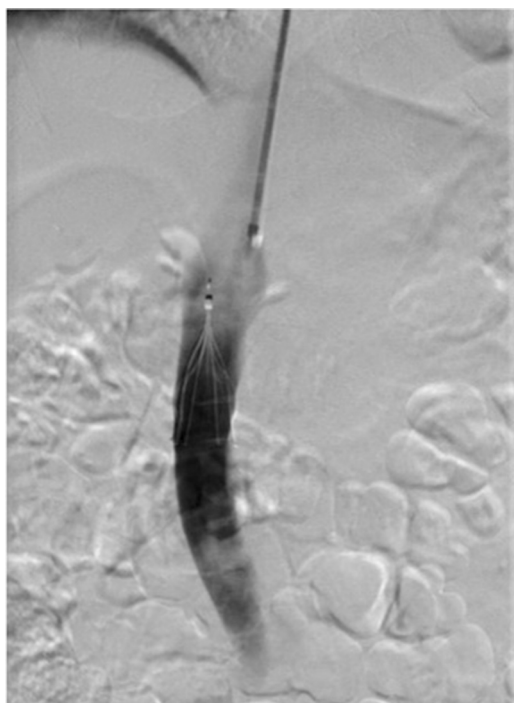


Fig. 1. Angiogram of retrievable IVC filter placement in inferior vena cava.

initial hospitalization and underwent placement of a Cook Celect Platinum filter, a retrievable IVC filter, because of his significant bleeding risk (Fig. 1). The patient was in his usual state of health when he presented to the ER with melena and syncope.

Two days prior to his presentation in the ER, the patient reported having a large-volume maroon-colored bloody bowel movement followed by a moderate volume of bright red blood, which eventually stopped after 2 h. The patient did not seek medical attention during or immediately after this episode. The following morning, the patient had another bowel movement of bright red blood that soaked his bed sheets. The patient reported some dizziness and presyncope after trying to get up following the bloody bowel movement. The patient was then taken to an outside emergency room by his family where he was found to be in hemorrhagic shock with hemoglobin of 4.6 g/dL and a systolic blood pressure of 60 mmHg.

After resuscitation with crystalloid intravenous fluids and four units of packed red blood cells, the patient was transferred to our institution for higher level of care. On arrival, the patient continued to require blood transfusions. Once the patient stabilized, his physician ordered computed tomography (CT) scans of the abdomen and pelvis; these revealed an infrarenal IVC filter with tines extending beyond the wall of the inferior vena cava and into the lumen of the distal second and proximal third portion of the duodenum (Fig. 2). One of the tines also extended close to, but did not clearly transgress, the proximal right ureter. There was no retroperitoneal hematoma or pneumoperitoneum.

The surgical team was consulted by the admitting physician. Following initial evaluation, an esophagogastroduodenoscopy (EGD) was ordered to evaluate the extent of duodenal perforation and whether any active bleeding communication was present. Endoscopic evaluation of the patient showed the retrievable IVC filter tines perforating the second part of the duodenum, although there was no evidence of gross blood (Fig. 3). The patient was hemodynamically stable without any evidence of melena or hematochezia and had stable hemoglobin of 9.8 g/dL.

Based on the patient's hemodynamic stability, the absence of active bleeding, and the extreme risk of an open procedure to

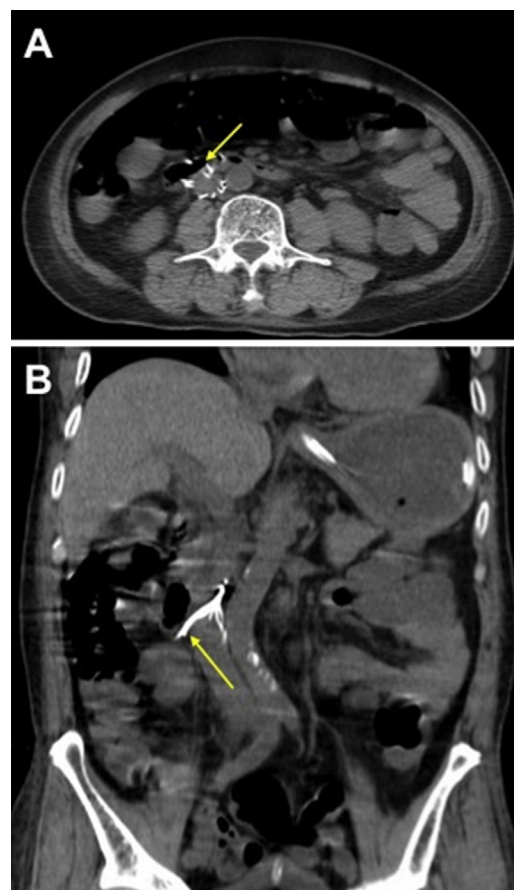


Fig. 2. (A and B) Axial and coronal CT views of abdomen and pelvis demonstrating the perforation of retrievable IVC filter tines through IVC into duodenum (yellow arrows). (For interpretation of the references to colour in this figure legend, the reader is referred to the web version of this article.)

remove the filter, the team elected to pursue endovascular removal of the retrievable IVC filter rather than surgery. The retrievable IVC filter was successfully retrieved through an endovascular approach and the patient was monitored for bleeding (Fig. 4). The patient did well without any complications following the endovascular retrieval of the retrievable IVC filter. A bleeding scan was ordered to confirm the absence of bleeding, and the study was negative. The patient resumed an oral diet and was subsequently discharged home.

3. Discussion

Deep vein thrombosis is commonly encountered in clinical practice with significant amount of morbidity and mortality. In cases where bleeding poses a significant risk, IVC filter placement is the preferred method of pulmonary embolism prevention. The only validated and precise indications for IVC filter placement in patients with thromboembolism are an inability to administer anticoagulation because of concurrent pathologies such as intracranial bleeding, bleeding diathesis, platelet count of less than 50,000/ μ L, recent planned or emergent surgical operation, major trauma, history of heparin induced thrombocytopenia (HIT), and development of DVT while on therapeutic anticoagulation.

Up until 1967, surgical interruption of the inferior vena cava (IVC) to prevent pulmonary embolization was performed with general anesthesia via a retroperitoneal incision. It was not until after 1967 that transvenous interruption of the IVC (via direct venous

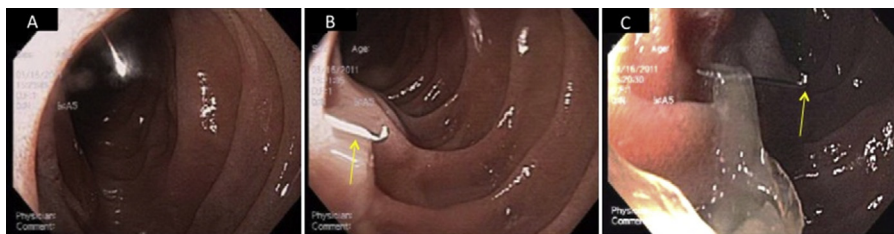

Fig. 3. Esophagogastroduodenoscopy (EGD) (multiple views A–C) revealing retrievable IVC filter tines perforating the second portion of duodenum without evidence of bleeding.

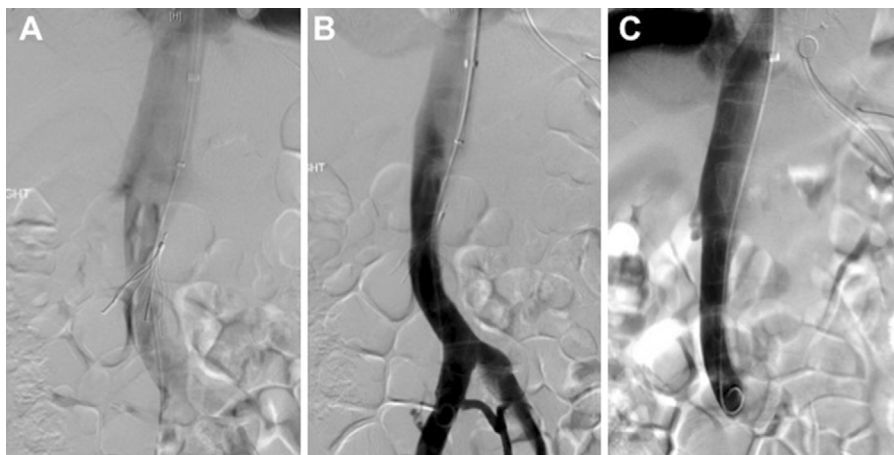


Fig. 4. Angiogram of retrievable IVC filter being removed. Initially scout film demonstrating the tines extending into the gas filled duodenum (A). The initially contrast study showing no active extravasation from the IVC (B). Completion angiogram after removal of the filter shows no extravasation (C).

access) became clinically feasible [10]. Since then, IVC filters have been used for the prevention of DVT in high-risk patients.

There are currently two types of vena cava filters available: permanent and retrievable. Since the United States Federal Drug Administration approved the use of retrievable filters in the early 2000s, there has been an exponential increase in the use of IVC filters [16]. The average complication rate of IVC filter placement varies with the type of filter used, its location, duration of filter placement, and follow-up metrics. Retrievable filters have consistently shown an increased rate of post-procedure and filter retrieval complications when compared to permanent filters. They have been found to have higher rates of filter fracture, thrombosis and perforation compared to permanent filters, particularly when they are left longer than intended [16]. In our case, the patient did have a retrievable filter that had been in place for approximately one year, possibly putting him at increased risk for complications, specifically filter perforation.

Some of the most common complications from IVC filters are penetration of adjacent tissues, thrombosis of the access site, migration of the filters from their original position, IVC placement outside the normal indicated location, and pulmonary embolism and death. Mortality from IVC filter insertion is relatively rare; two series of studies reported death rates of 0.12% (3/2557) patients undergoing filter insertion, and another series reported major complication rates of 0.3% [8,15]. Late complications of vena cava filter placement are uncommon and include filter migration (which can also occur acutely during filter placement), filter erosion, and perforation through the IVC wall [11–14]. The literature on IVC filter perforation into the duodenum is scant because of its rare incidence. The number of cases reported in literature has increased over the past four decades, but this could be due to the universal availability of routine workup using CT and EGD for abdominal complaints or the rise in use of retrievable IVC filters [18]. Excellent outcomes with low complication rates have been reported in cases

where an open procedure was performed with either extraction of the filter or removal of the offending struts, suggesting surgery as the mainstay treatment for duodenal perforation by an IVC filter [17,18]. In a systematic review [18] from 2012, all 25 patients with duodenal perforation but 1, were treated with laparotomy with or without venotomy. In this case we presented the successful retrieval of a retrievable IVC filter non-operatively by interventional radiology. It is an excellent example of the assessment and non-operative management of duodenal and IVC perforation by a retrievable IVC filter.

4. Conclusion

This report highlights that retrievable IVC filters as an alternative to anticoagulation therapy in patients at risk for pulmonary embolisms are not exempt from complications. In rare cases, retrievable IVC filters may erode into surrounding structures. Although excellent outcomes with low complication rates have been reported in cases where an open procedure was performed, we demonstrate that surgery is not always necessary, even in the most serious of cases. For patients with significant comorbidities or patients who are poor surgical candidates, non-operative management with close monitoring can serve as an initial approach to the patient with a caval enteric perforation secondary to a retrievable IVC filter.

Conflicts of interest

The authors declare that there is no conflict of interest.

Funding

This research did not receive any specific grant from funding agencies in the public, commercial, or not-for-profit sectors.

Ethics approval

Not applicable.

Consent

Consent was obtained as a part of the institutional informed consent process. All relevant patient data has been de-identified and no face pictures are submitted.

Author contribution

JSFM, KK, and MHZ were equally responsible for drafting the manuscript, revising the manuscript, and creating the figures. All authors reviewed and approved the final version of the manuscript for submission. WRR, as the senior attending, was involved in all aspects of the manuscript preparation.

Guarantor

JSFM assumes full responsibility for all aspects of the work.

References

- [1] S.R. Deitcher, T.L. Carman, Deep venous thrombosis and pulmonary embolism, *Curr. Treat. Option Cardiovasc. Med.* 4 (3) (2002) 223–238.
- [2] G.D. Lowe, Common risk factors for both arterial and venous thrombosis, *Br. J. Haematol.* 140 (5) (2008) 488–495.
- [3] M.M. Knudson, F.R. Lewis, A. Clinton, K. Aitkinson, J. Megerman, Prevention of venous thromboembolism in trauma patients, *J. Trauma Acute Care Surg.* 37 (3) (1994) 480–487.
- [4] H.T. Sørensen, L. Mellemkjær, F.H. Steffensen, J.H. Olsen, G.L. Nielsen, The risk of a diagnosis of cancer after primary deep venous thrombosis or pulmonary embolism, *N. Engl. J. Med.* 338 (17) (1998) 1169–1173.
- [5] C.A. Che Yaakob, A.A. Dzarr, A.A. Ismail, N.A. Zuky Nik Lah, J.J. Ho, Anticoagulant therapy for deep vein thrombosis (DVT) in pregnancy, *Cochrane Database Syst. Rev.* 6 (2010) CD007801.
- [6] R. Kai, H. Imamura, S. Kumazaki, Y. Kamiyoshi, M. Koshikawa, T. Hanaoka, et al., Temporary inferior vena cava filter for deep vein thrombosis and acute pulmonary thromboembolism: effectiveness and indication, *Heart Vessels* 21 (4) (2006) 221–225.
- [7] R.H. White, H. Zhou, J. Kim, P.S. Romano, A population-based study of the effectiveness of inferior vena cava filter use among patients with venous thromboembolism, *Arch. Intern. Med.* 160 (13) (2000) 2033–2041.
- [8] D.M. Becker, J.T. Philbrick, J.B. Selby, Inferior vena cava filters: indications, safety, effectiveness, *Arch. Intern. Med.* 152 (10) (1992) 1985–1994.
- [9] Procedural and Indwelling Complications with Inferior Vena Cava Filters: Frequency, Etiology, and Management, in: L. Milovanovic, S.A. Kennedy, M. Midia (Eds.), 2015 (*Semin Intervent Radiol.*).
- [10] M.J. Martin, K.S. Blair, T.K. Curry, N. Singh, Vena cava filters: current concepts and controversies for the surgeon, *Curr. Probl. Surg.* 47 (7) (2010) 524–618.
- [11] R. Almestady, J. Spain, M.D.P. Bayona-Molano, W. Wang, Iatrogenic migration of VenaTech LP IVC filter to superior vena cava secondary to guidewire entrapment case report and review of literature, *Vasc. Endovasc. Surg.* 47 (1) (2013) 48–50.
- [12] T.N. Yegul, S.M. Bonilla, S.C. Goodwin, G.C. Wong, S. Vott, A.C. Lai, et al., Retrieval of a greenfield IVC filter displaced to the right brachiocephalic vein, *Cardiovasc. Interv. Radiol.* 23 (5) (2000) 403–405.
- [13] K.M. Bochenek, J.E. Aruny, M.G. Tal, Right atrial migration and percutaneous retrieval of a Günther Tulip inferior vena cava filter, *J. Vasc. Interv. Radiol.* 14 (9) (2003) 1207–1209.
- [14] E.H. Caldwell, T.L. Fridley, E.L. Erb, S.R. Fleischer, Endovascular retrieval of an inferior vena cava filter with simultaneous caval, aortic, and duodenal perforations, *Vasc. Endovasc. Surg.* 46 (8) (2012) 671–674.
- [15] C.A. Athanasoulis, J.A. Kaufman, E.F. Halpern, A.C. Waltman, S.C. Geller, C.-M. Fan, Inferior vena caval filters: review of a 26-year single-center clinical experience, *Radiology* (2000).
- [16] S. Grewal, M.R. Chamarthy, S.P. Kalva, Complications of inferior vena cava filters, *Cardiovasc. Diagn. Ther.* 6 (6) (2016) 632–641.
- [17] A. Jehangir, A. Rettew, B. Shaikh, et al., IVC filter perforation through the duodenum found after years of abdominal pain, *Am. J. Case Rep.* 16 (2015) 292–295.
- [18] R.D. Malgor, N. Labropoulos, A systematic review of symptomatic duodenal perforation by inferior vena cava filters, *J. Vasc. Surg.* 55 (3) (2012).
- [19] R.A. Agha, et al., The SCARE statement: consensus-based surgical case report guidelines, *Int. J. Surg.* 34 (2016) 180–186.

Open Access

This article is published Open Access at [sciencedirect.com](https://www.sciencedirect.com). It is distributed under the [IJSCR Supplemental terms and conditions](#), which permits unrestricted non commercial use, distribution, and reproduction in any medium, provided the original authors and source are credited.