

## Phagocytic Cell Responses to *in Vivo* and *in Vitro* Exposure to the Lyme Disease Spirochete

JORGE L. BENACH, Ph.D.,<sup>a</sup> GAIL S. HABICHT, Ph.D.,<sup>b</sup>  
BARBARA L. GOCINSKI, B.S.,<sup>b</sup> AND JAMES L. COLEMAN, M.S.<sup>c</sup>

<sup>a</sup>State of New York Department of Health, Department of Pathology, State University of New York at Stony Brook; <sup>b</sup>Department of Pathology, State University of New York at Stony Brook; <sup>c</sup>State of New York Department of Health, State University of New York at Stony Brook, Stony Brook, New York

Received November 16, 1983

---

An experimental skin lesion induced in rabbits by the bite of infected adult *Ixodes dammini* showed dense dermal interstitial inflammatory cell infiltrates composed of mononuclear cells (histiocytes and lymphocytes) and granulocytes. The prevalence of phagocytic cells in this experimental lesion motivated a study on the interactions of macrophages and neutrophils with Lyme disease spirochetes. Interactions as measured by uptake of radiolabeled spirochetes and by indirect immunofluorescence were enhanced by opsonization of spirochetes with immune serum and not significantly decreased by heat inactivation of the same. Phagocytosis was inhibited by treatment of cells with Cytochalasin B. Adherence of opsonized spirochetes to neutrophils was decreased by blocking Fc receptors with heat-aggregated IgG, suggesting an important role for this receptor.

---

Lyme disease is a chronic inflammatory syndrome characterized by a skin lesion and by various secondary manifestations involving joints, central nervous system, and the heart [1]. The spirochetal etiology of this disease, now well established, provides a specific mechanism to understand the pathogenesis of this disease [2-4]. There appear to be two possible avenues for pathogenesis. Some spirochetal diseases such as syphilis are characterized by multiple symptoms involving more than one organ system which are temporally separated from each other, and relapsing fever, caused by spirochetes of the genus *Borrelia*, produces recurrent periods of fever. Lyme disease seems to fit within the pattern of other diseases of spirochetal etiology in that various organ systems are affected and their manifestations can occur within days to months from one another. However, in the case of syphilis and relapsing fever, the causative spirochetes seem to persist so that pathogenesis for each relapse or manifestation may be related directly to the presence of the same or antigenically altered organisms. It is not known whether the spirochete of Lyme disease persists for long periods of time within the organ systems involved in the disease. There is evidence, however, that circulating immune complexes occur and persist in the serum of Lyme disease patients [5]. Pathogenesis due to deposition of circulating immune complexes triggered by an initial spirochete infection has to be considered as an alternative mechanism to pathogenesis due to persistent organisms.

It is doubtful that the pathogenesis of Lyme disease will be elucidated using only human-derived specimens, since Lyme disease is seldom, if ever, fatal so tissues from vital organs may not be readily available to answer some of these questions. Therefore, the development of an animal model seems to be crucial for understanding of the mechanisms of disease. The spirochetes are transmitted by ticks [2,6]. This implies that the portal of entry of the organism is the skin. In the majority of patients, the skin lesion, or erythema chronicum migrans (ECM) is the first, and sometimes the only manifestation of Lyme disease [1]. The skin is the most likely organ to be affected directly by the spirochete and also the location where the initial encounter of the spirochete with the host's immune system takes place. Spirochetes have been isolated from human ECM lesions [4] and also recently in our laboratory, as well as detected by silver stains in skin tissues [7].

We have been able to induce a skin lesion in rabbits after a ten- to eleven-day period of attachment of spirochete-infected adult *Ixodes dammini*. These lesions were uniformly erythematous, indurated, and centered around the sites of tick attachment. Spirochetes were recovered from the blood of the rabbits while the ticks were still attached so that experimental transmission of the organisms has been achieved. Sections of the lesions show an interstitial mixed inflammatory cell infiltrate in the dermis. This infiltrate was denser in the deeper dermis, sometimes extending into the subcutaneous fat and the skeletal muscle (Fig. 1). Although the composition of the infiltrate varies within different areas of the skin, the predominant cell was the histiocyte identified morphologically by hematoxylin and eosin stains and histochemically by  $\alpha$ -naphthyl acetate esterase (ANAE) staining [8]. Mononuclear cells of thymus origin [9] were present in these lesions (identified by

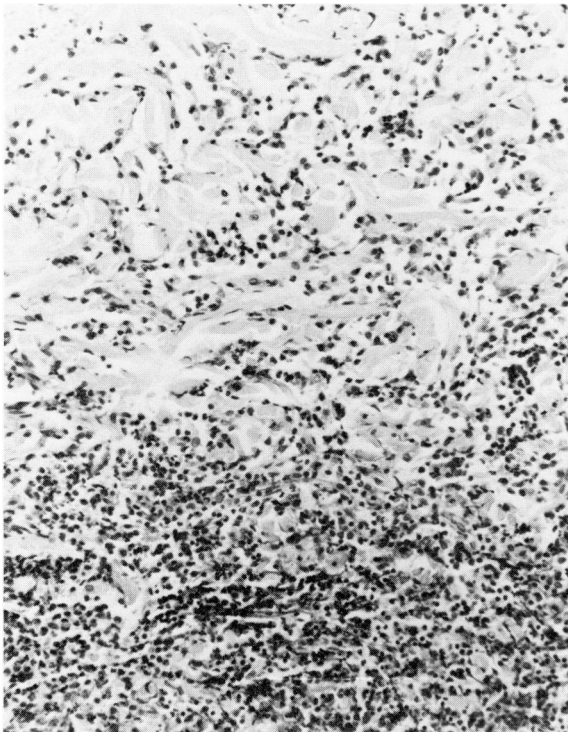


FIG. 1. Border area between the superficial and deep dermis of a skin lesion experimentally induced by feeding spirochete-injected adult *Ixodes dammini* ticks on a rabbit. There is a mixed inflammatory cell infiltrate with predominant histiocytes, granulocytes, and lymphocytes. (Hematoxylin and eosin, 160  $\times$ )

rabbit anti-thymocyte serum, generously supplied by Dr. Sheila Lukehart, University of Washington, Seattle) in numbers ranging from 10–20 percent of the infiltrate but were most numerous in the deep dermis. Mononuclear cells bearing surface immunoglobulin (sIg; identified by direct immunofluorescence with goat anti-rabbit Ig) and plasma cells were present, but in extremely low numbers. Granulocytes accounted for 40 percent of the infiltrate and were most prominent in perivascular areas and in necrotic abscesses thought to be the areas of tick mouthpart attachments. Although readily identifiable in peripheral blood smears, rabbit neutrophils, also called heterophils or pseudoeosinophils [10], cannot be easily distinguished from eosinophils in tissues with dense infiltrates. Naphtol AS-D chloroacetate esterase activity is present in neutrophils but not in eosinophils [8]. Granulocytes in the perivascular areas possessed this activity but those in other parts of the lesion did not, although some were polymorphonuclear. Thus, at the present time, we can only indicate that the granulocyte component of these lesions is mixed and contains both neutrophils and eosinophils. This experimental rabbit lesion bears some histological similarities to human ECM. Human ECM lesions have been characterized as having three infiltrate patterns composed of lymphocytes, plasma cells, and eosinophils [7] and as being primarily lympho-histiocytic [11]. Skin lesions from rabbits exposed to presumably infected *Ixodes dammini* adults have also been shown to have a mononuclear cell infiltrate [2]. Experimentally induced skin lesions in rabbits after intradermal inoculation of *Treponema pallidum* also show a lympho-histiocytic infiltrate [9]. It is of further interest that intradermal inoculations of cultured Lyme disease spirochetes to rabbits do not produce a gross skin lesion but tissue sections of the sites of inoculation show diffuse histiocytic involvement. Although a mononuclear cell response seems to be associated with human ECM, and with lesions caused by other spirochetes, it is difficult to determine whether the experimental lesion in rabbits exposed to infected ticks is due to the presence of spirochetes or to tick bite injury, or both. A very comprehensive, quantified study of the response of rabbits to colony-reared *Ixodes dammini* ticks also showed a predominant mononuclear cell infiltrate in lesions induced by subadult ticks, although no lesions were reported in rabbits after exposure to adults [12].

On the other hand, granulocytes could have a role in the mediation of tick bite injury. Numerous studies involving other tick species and various laboratory animals report neutrophil infiltrates as the predominant inflammatory cell [13–16].

Regardless of the pathogenesis of our infected, tick-induced, experimental lesions in rabbits, it is clear that the phagocytic components of the immune system are deeply involved in the early skin response of the rabbit, and mononuclear cells are also prominent in the human ECM. In a series of studies, we attempted to demonstrate the interactions of the Lyme disease spirochetes by peritoneal exudate macrophages from laboratory animals, macrophage cell cultures, and human neutrophils. Three methods were used to demonstrate *in vitro* interactions. The spirochetes were successfully labeled with <sup>3</sup>H thymidine (10  $\mu$ Ci) after overnight incubation. Incorporation of <sup>3</sup>H thymidine occurred only during the time of active spirochete growth; addition of the label to newly passed cultures did not result in significant uptake by the organisms. Phagocytosis or adherence of labeled spirochetes by adherent, thyoglycollate elicited peritoneal exudate macrophages from mice (Balb/c), rats (Sprague-Dawley), rabbits (New Zealand white), and a cell line P388D1 [17,18] was measured as a percentage of the uptake of labeled spirochetes (approximately 8–12 percent of the radiolabel). The uptake of labeled spirochetes by macrophages from various laboratory animals was enhanced by opsonization of spirochetes with homologous

immune sera (30–35 percent of the radio label) and was significantly greater than the uptake of spirochetes opsonized with normal sera ( $p < 0.05$ ). Serum heat-labile factors (removed by heat inactivation of sera at 56°C for 45 minutes) did not appear to have a significant role in the interactions of spirochetes with the macrophages since their removal did not significantly decrease uptake of the  $^3\text{H}$  thymidine label.

The other technique for measurement of phagocytosis was first used successfully to detect the uptake of *Treponema pallidum* by macrophages [19] and involves indirect immunofluorescence procedures. After incubation with spirochetes opsonized with immune, heat-inactivated immune, normal, and heat-inactivated normal sera, as well as non-opsonized spirochetes, the cells were smeared on slides followed by methanol fixation, overlaid with heterologous anti-spirochete immune sera, followed by FITC labeled anti-species specific immunoglobulin conjugates. Examination of these smears under UV light permitted counting of those cells which showed fluorescent spirochetes, spirochete fragments, or fluorescent bodies (Fig. 2). Macrophages by themselves had no fluorescent activity. Approximately half of the cells incubated with spirochetes opsonized with immune serum showed fluorescence. The rates decreased slightly with spirochetes opsonized with heat-inactivated immune serum (35–40 percent), and significantly with spirochetes opsonized with normal serum ( $p < 0.05$ ) (18–20 percent). Murine macrophages (Balb/c peritoneal exudate macrophages and P388D1) appeared to have more fluorescent bodies after exposure to opsonized as well as non-opsonized spirochetes than rat or rabbit macrophages, but these differences were not significant. Results obtained by the use of the immunofluorescence procedure paralleled those obtained by the uptake of  $^3\text{H}$  thymidine-labeled spirochetes.

Treatment of the murine cell line P388D1 with Cytochalasin B [20] (10  $\mu\text{g}/\text{ml}$ ) showed a significant ( $p < 0.05$ ) decrease in the number of cells with fluorescent bodies after exposure to spirochetes opsonized with immune serum (5–9 percent) of the cells, rather than half of the cells as measured by the immunofluorescence procedure). An equal volume (10  $\mu\text{l}$ ) of Dimethyl sulfoxide (DMSO) used as diluent control for Cytochalasin B had no effect.

Human neutrophils were obtained by dextran sedimentation followed by lysis of erythrocytes in distilled water and restoration of isotonicity. Neutrophils were incubated in tubes with opsonized and non-opsonized spirochetes (as described for macrophages) at 37°C in 1 ml of culture medium for one hour. Neither technique

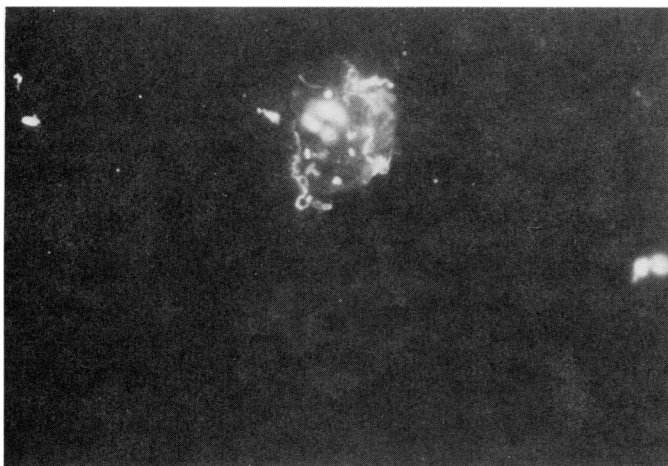


FIG. 2. Murine macrophage containing spirochetes, spirochete fragments, and fluorescent bodies. The faint outline of a macrophage without fluorescing organisms or bodies can be seen below. (Oil immersion, 1,000  $\times$ )

could be used for measuring interactions with neutrophils since numerous cells had spirochetes radiating from their surfaces, and consequently the uptake of  $^3\text{H}$  thymidine-labeled organisms could not be determined since attached organisms artificially elevated the DPMs of the cell fraction. Likewise, uncertainty as to whether an organism or a fragment was attached or inside precluded counts by the immunofluorescence procedure. The adherence of opsonized spirochetes to the surface of the neutrophils, a phenomenon not observed with macrophages, may be due to differences in techniques. The ratios of spirochetes to phagocytes were standardized at 10:1 for all experiments. Neutrophils were incubated with the spirochetes in suspension whereas the macrophages were incubated while adhered to plates. The adherent properties of macrophages allowed almost total removal of free spirochetes by vigorous washing of the plates. The neutrophils, however, had to be separated from free spirochetes by differential centrifugation but this maneuver was not completely effective. Nonetheless, transmission electron microscopy of neutrophil pellets suggested that approximately 30 percent of the cells incubated for one hour with opsonized spirochetes contained fragments within phagosomes (Fig. 3).

Neither technique, uptake of  $^3\text{H}$  thymidine nor indirect immunofluorescence, provides definitive proof that spirochetes have been ingested. However, previous studies utilizing similar techniques for the study of interactions between other species of spirochetes and phagocytes have not hesitated in establishing the interactions as actual ingestion of organisms [19,21-24]. The fact that phagocytes pretreated with Cytochalasin B, a known inhibitor of ingestion but not of attachment, had significantly reduced numbers of fluorescent bodies provides evidence of

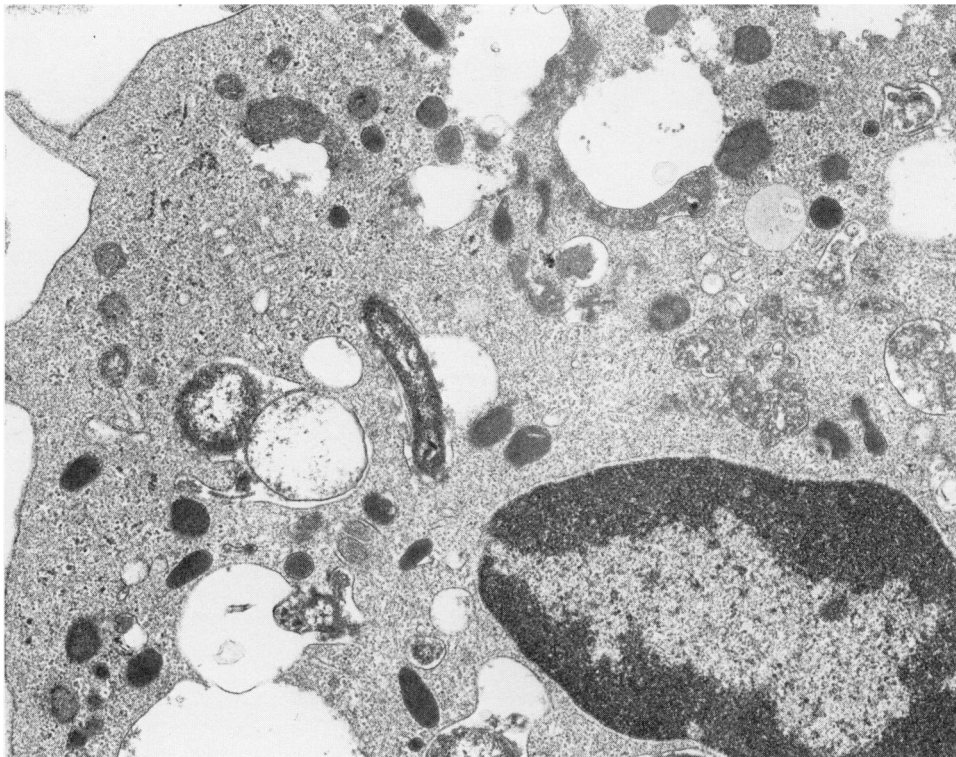


FIG. 3. Spirochete fragment within phagosome of a human neutrophil. (36,900  $\times$ )

phagocytosis rather than just attachment. Indeed, the adherence of opsonized spirochetes to neutrophils precluded utilization of the techniques used for macrophages; yet this phenomenon provided a mechanism for investigating the role of the Fc receptor in surface attachment. Pretreatment of neutrophils with DEAE-purified, heat-aggregated human IgG (20 mg/ml for one hour) to block the Fc receptors resulted in an almost total absence of attached organisms, suggesting a role for this receptor. (The purified human IgG was obtained through the courtesy of the American Red Cross.)

We have obtained evidence that professional phagocytes can interact with the Lyme disease spirochete in the absence of opsonins and to a much greater extent after opsonization of the organisms with immune serum. This interaction may reflect attachment of spirochetes to the cell surface and may also include actual phagocytosis as evidenced by the use of phagocytosis inhibitors. In fact, immune serum factors may be a requirement for attachment and interiorization utilizing the Fc receptors of the phagocytes. Studies involving phagocytosis with other species of spirochetes uniformly provide evidence that immune serum is needed for ingestion [19,21-24]. The possibility that other surface receptors of macrophages and neutrophils may be utilized to promote binding and phagocytosis needs to be investigated. Macrophages possess a large array of surface receptors which may be important in the initial encounters of phagocyte and spirochetes. Receptors for complex carbohydrates [25] and for fibronectin fragments [26] may be instrumental in initial binding of spirochetes to the macrophage surface in the absence of specific immunoglobulin. Chemotaxis generated by activation of the complement and/or clotting cascades or by the presence of organism-derived chemotactic peptides may be the mechanism for the large phagocytic infiltrate of the skin lesion of Lyme disease. The finding of a mixed inflammatory infiltrate with phagocytes and lymphocytes of thymic origin as well as few plasma cells and cells bearing sIg in the experimental skin lesion in the rabbit suggest that specific and non-specific host defenses against the spirochete may be initiated and effected in the skin.

#### ACKNOWLEDGEMENT

We wish to thank Dr. Bernard Lane and Edward Drummond of the Department of Pathology at Stony Brook for electron microscopy.

#### REFERENCES

1. Steere AC, Malawista SE, Hardin JA, et al: Erythema chronicum migrans and Lyme arthritis. *Ann Intern Med* 86:685-698, 1977
2. Burgdorfer W, Barbour AG, Hayes SF, et al: Lyme disease, a tick-borne spirochetosis. *Science* 216:1317-1319, 1982
3. Benach JL, Bosler EM, Hanrahan JP, et al: Spirochetes isolated from the blood of two patients with Lyme disease. *New Eng J Med* 308:740-742, 1983
4. Steere AC, Grodzicki RL, Kornblatt AN, et al: The spirochetal etiology of Lyme disease. *New Eng J Med* 308:733-740, 1983
5. Hardin JA, Walker LC, Steere AC, et al: Circulating immune complexes in Lyme arthritis: detection by <sup>125</sup>I-C1q binding, C1q solid phase and Raji cell assays. *J Clin Invest* 63:468-477, 1979
6. Bosler EM, Coleman JL, Benach JL, et al: Natural distribution of the *Ixodes dammini* spirochete. *Science* 220:321-322, 1983
7. Berger BW, Clemmensen OJ, Ackerman AB: Lyme disease is a spirochetosis. *Am J Dermatopathol* 5:111-124, 1983
8. Yam LT, Crosby WH: Cytochemical identification of monocytes and granulocytes. *Am J Clin Pathol* 56:283-290, 1971

9. Sell S, Gamboa D, Baker-Zander SA, et al: Host responses to *Treponema pallidum* in intradermally infected rabbits. *Invest Dermatol* 75:470-475, 1980
10. Schalm OW, Jain NC, Carroll EJ: *Veterinary Hematology*. Philadelphia, Lea & Febiger, 1975, 807 pp
11. Steere AC, Bartenhagen NH, Craft JE, et al: The early clinical manifestations of Lyme disease. *Ann Intern Med* 99:76-82, 1983
12. Krinsky WL, Brown SJ, Askenase PW: *Ixodes dammini*: induced skin lesions in guinea pigs and rabbits compared to erythema chronicum migrans in patients with Lyme arthritis. *Exp Parasitol* 53:381-395, 1982
13. Berenberg JL, Ward PA, Sonenshine DE: Tick bite injury: mediation by complement derived chemotactic factor. *J Immunol* 109:451-456, 1972
14. Brown SJ, Knapp FW: *Amblyomma americanum*: Sequential histological analysis of larval and nymphal feeding sites on guinea pigs. *Exp Parasitol* 49:188-205, 1980
15. Brown SJ, Knap FW: *Amblyomma americanum*: Sequential histological analysis of adult feeding sites on guinea pigs. *Exp Parasitol* 49:303-318, 1980
16. Brossard M, Fivaz V: *Ixodes ricinus* L: mast cells, basophils and eosinophils in the sequence of cellular events in the skin of infested or reinfested rabbits. *Parasitol* 85:583-592, 1982
17. Koren HS, Handwerger BS, Wanderlich JR: Identification of macrophage like characteristics in a cultured murine tumor line. *J Immunol* 114:894-897, 1975
18. Rosenstreich DL, Mizel SB: Participation of macrophages and macrophage cell lines in the activation of T lymphocytes by mitogens. *Immunol Rev* 40:102-135, 1978
19. Lukehart SA, Miller JA: Demonstration of the in vitro phagocytosis of *Treponema pallidum*. *J Immunol* 121:2014-2024, 1978
20. Malawista SE, Gee JBL, Bensch KG: Cytochalasin B reversibly inhibits phagocytosis: Functional, metabolic, and ultrastructural effects in human blood leukocytes and rabbit alveolar macrophages. *Yale J Biol Med* 44:286-300, 1971
21. Spagnuolo PJ, Butler T, Block EH, et al: Opsonic requirements for phagocytosis of *Borrelia hermsii* by human polymorphonuclear leukocytes. *J Inf Dis* 145:358-364, 1982
22. Musher DM, Hague-Park M, Gyorkey F, et al: The interaction between *Treponema pallidum* and human polymorphonuclear leukocytes. *J Inf Dis* 147:77-86, 1983
23. Butler T, Aikawa M, Habte-Michael A, et al: Phagocytosis of *Borrelia recurrentis* by blood polymorphonuclear leukocytes is enhanced by antibiotic treatment. *Inf Immun* 28:1009-1013, 1980
24. Butler T, Spagnuolo PJ, Goldsmith GH, Aikawa M: Interaction of *Borrelia* spirochetes with human mononuclear leukocytes causes production of leukocytic pyrogen and thromboplastin. *J Lab Clin Med* 99:709-721, 1982
25. Werb Z, Goldstein IM: Phagocytic cells: Chemotaxis and effector functions of macrophages and granulocytes. In *Basic and Clinical Immunology*. Edited by DB Sites, JD Stobo, HH Fudenberg, JV Wells. Lange, Los Altos, Medical Publications, 1982, pp 109-123
26. Norris DA, Clark RAF, Swigart BM, et al: Fibronectin fragments are chemotactic for human peripheral blood monocytes. *J Immunol* 129:1612-1618, 1982