

Parasitic leiomyoma causing small bowel perforation: A case report

Anya Laibangyang^a, Cassandra Law^a, Gunjan Gupta^b, Xiang Da Dong^c, Linus Chuang^{a,*}

^a Departments of Obstetrics, Gynecology, and Reproductive Biology, Danbury Hospital, Danbury, CT, United States of America

^b Pathology & Laboratory Medicine, Danbury Hospital, Danbury, CT, United States of America

^c Department of Surgery, Nuvance Health, Danbury, CT, United States of America

ARTICLE INFO

Keywords:

Bowel
Perforation
Parasitic
Leiomyoma

ABSTRACT

Background: Parasitic leiomyomas are rare extra-uterine tumors that can be seen in patients after myomectomy or morcellation of leiomyomas.

Case: A 63-year-old woman with a history of abdominal myomectomy 20 years prior presented with worsening abdominal distension and pain for the past eight months. The patient delayed care due to fear of the COVID-19 pandemic and was found to have a 42 cm parasitic leiomyoma attached to the small bowel causing obstruction and perforation.

Conclusion: Parasitic leiomyomas can cause small bowel obstruction and perforation.

1. Introduction

Parasitic leiomyomas are rare extra-uterine smooth muscle neoplasms. Originally described by Kelly and Colon in 1909, they were thought to originate from subserosal myomas that twisted off their uterine pedicle and survived via neovascularization of adjacent organs [1]. More recently, parasitic leiomyomas have been found after myomectomies or morcellation of leiomyomas, though the true pathophysiology is still unclear [2]. Few cases have been documented of parasitic leiomyomas attaching to the small bowel, omentum, and pelvic sidewall causing a small bowel obstruction (SBO). No cases have been documented of a parasitic leiomyoma causing bowel perforation. Here, the authors present a case of a parasitic leiomyoma causing a small bowel perforation after a delay of care due to the coronavirus disease 2019 (COVID-19) pandemic.

2. Case Presentation

A 63-year-old Caucasian woman, G2P2003, with a surgical history significant for two cesarean sections and an abdominal myomectomy 20 years prior, presented to the emergency department with complaints of abdominal distension that had been progressively worsening for the past 8 months since the beginning of the pandemic. For over three weeks prior to presentation, she had worsening shortness of breath and abdominal pain secondary to the distension. She had been reluctant to seek medical care due to the COVID crisis. On examination, her

abdomen was distended and firm with an approximately 30- to 40-week-sized uterus which was nontender to palpation. Her pelvic exam was significant for fullness appreciated in the posterior cul-de-sac. Given her tachypnea, at 40 breaths/min, significant leukocytosis $>20,000/\mu\text{L}$, and suspected infection, she met criteria for sepsis at this time.

A CT scan of the abdomen and pelvis without contrast demonstrated multiple pelvic masses, including an approximately 14 cm mixed density mass in the posterior cul-de-sac separate from an abdominal mass measuring $25.5 \times 20.5 \times 20.5$ cm. Pneumoperitoneum, ascites, and abnormal omental and mesenteric surfaces were also noted (Fig. 1). The uterus and ovaries were not identified on the CT scan. Given these findings and the concern for a bowel perforation, the patient underwent an emergent exploratory laparotomy with possible bowel resection, hysterectomy, bilateral salpingo-oophorectomy and debulking surgery.

Upon entry into the abdomen, an approximately 40×40 cm necrotic mesenteric tumor that compressed the mid-jejunum was visualized. There was also secondary peritonitis with approximately 1500 cc of purulent fluid drained during surgery secondary to perforation of the jejunum. In addition, a mass in the posterior cul-de-sac causing a partial bowel obstruction was noted. The uterus, fimbria and ovaries were identified separately from the posterior cul de sac tumor. Due to the patient's worsening status, she was left in discontinuity and transferred to the ICU intubated after evacuation of the purulent fluid and an en-bloc removal of the necrotic mesenteric tumor and the adjacent small bowel with a plan to return once hemodynamically stable.

Two days later, the patient returned to the operating room for small

* Corresponding author at: 24 Hospital Avenue, Danbury, CT, United States of America.

E-mail address: linus.chuang@nuvancehealth.org (L. Chuang).

<https://doi.org/10.1016/j.crwh.2021.e00349>

Received 23 June 2021; Received in revised form 29 July 2021; Accepted 30 July 2021

Available online 6 August 2021

2214-9112/© 2021 Published by Elsevier B.V. This is an open access article under the CC BY-NC-ND license (<http://creativecommons.org/licenses/by-nc-nd/4.0/>).

bowel anastomosis and resection of the pelvic mass. As the mass in the posterior cul-de-sac was being resected, it was felt that the mass was continuous with the left fallopian tube and ovary. The mass was sent to pathology for an intraoperative frozen section and a total abdominal hysterectomy and bilateral salpingo-oophorectomy were performed. Intraoperative frozen section demonstrated a mesenchymal mass. The patient was then closed and transferred to the ICU for continued care.

The final pathology report for both the abdominal and pelvic mass indicated leiomyomas with ischemic necrosis and hemorrhage. The abdominal leiomyoma measured 42x30x13 cm with multiple sites of perforation containing pus and feculent material from the perforated site while the multinodular, lobulated pelvic leiomyoma measured 17 × 14.5 × 8 cm (Figs. 2, 3). The uterus, cervix, bilateral fallopian tubes and ovaries were negative for malignancy. The patient's postoperative course was uneventful and the patient was discharged home on hospital day 12.

3. Discussion

As defined originally by Kelly and Colon, parasitic leiomyomas were derived from uterine myomas that were adjacent to nearby organs; the myomas would then begin to derive their blood supply from that organ, no longer reliant on the uterus and slowly becoming detached from it [1]. However, parasitic leiomyomas have become increasingly prevalent within the last 20 years. This increase coincides with another possible explanation regarding the pathophysiology of parasitic leiomyomas, in which parasitic leiomyomas are created iatrogenically after pelvic surgery, particularly after morcellation [2,3]. Patients with parasitic myomas can present with a range of symptoms varying anywhere from asymptomatic to sepsis as a result of colonic serositis [4]. However, parasitic myomas most commonly present with abdominal pain or distension. A literature search revealed three published cases of a parasitic leiomyoma presenting as a small bowel obstruction [5-7].

In the case presented by Khan et al., a 45-year-old woman complaining of increasing abdominal growth over the past several years with past medical history of fibroids presented with symptoms concerning for a small bowel obstruction and was found to have a 12x12x8cm parasitic leiomyoma of the greater omentum with a small fibrotic attachment to the uterus [5]. Shaukat et al. presented a case of a 45-year-old woman with acute abdominal pain, nausea and vomiting, with a past surgical history significant for a laparoscopic hysterectomy with morcellation of fibroids 4 years prior, who was found to have a small bowel obstruction caused by a parasitic leiomyoma arising from the peritoneum measuring 8 cm⁶. In a postmortem analysis by Jacobs et al., a 64-year-old woman

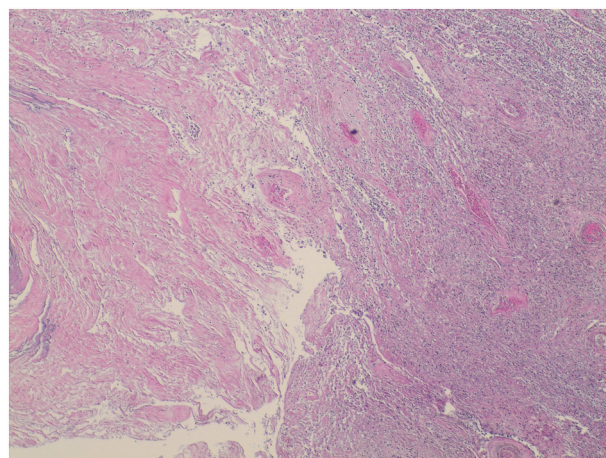


Fig. 2. Leiomyoma with infarction (left) and acute and chronic inflammation (right) (hematoxylin-eosin, original magnification x 20).

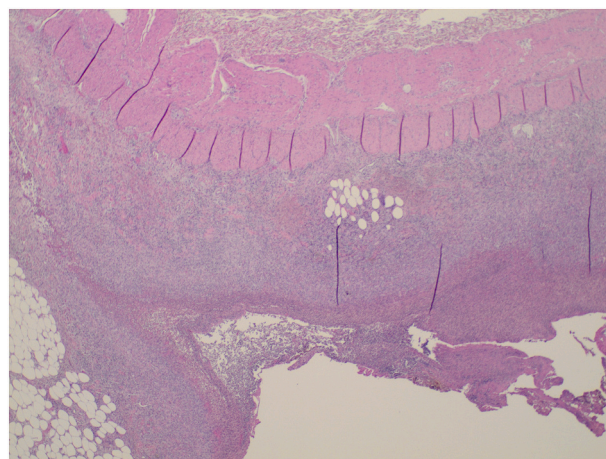


Fig. 3. Small intestine wall with acute and organizing peritonitis and focal perforation (hematoxylin-eosin, original magnification x 20).

with symptoms concerning for a small bowel obstruction was found to have an ileal obstruction caused by an intraluminal, calcified spiculated mass which was consistent with a uterine leiomyoma [7].

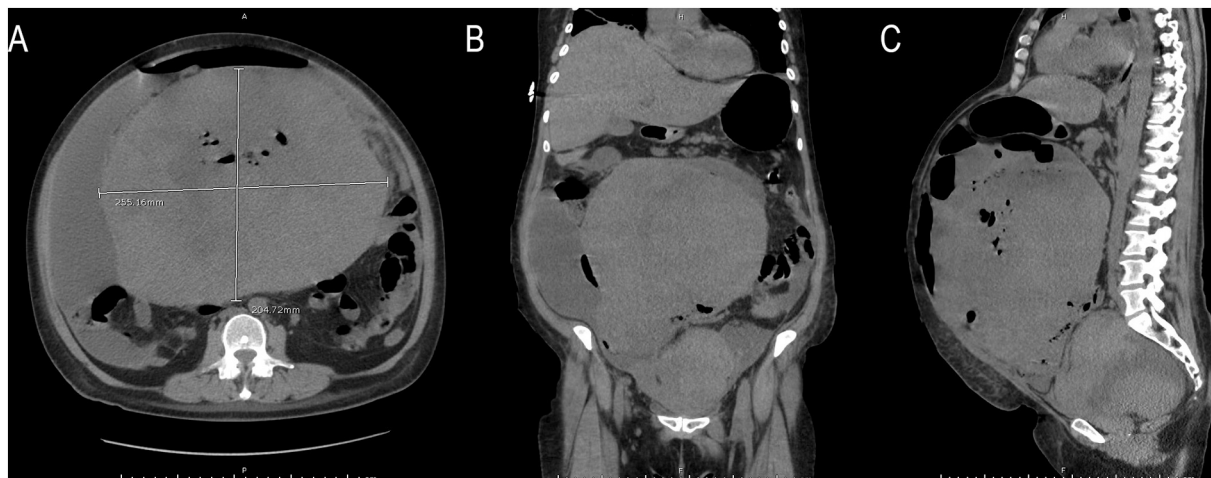


Fig. 1. CT images of the abdomen and pelvis upon patient presentation: (A) axial, (B) coronal, (C) sagittal views. CT images demonstrate a large intra-abdominal mass occupying the majority of the abdomen. There was also evidence of free air consistent with bowel perforation.

Similar to the case presented by Shaukat et al., our patient had had fibroids for which she had undergone abdominal myomectomy 20 years prior. Though our patient first noticed symptoms at the beginning of the COVID-19 crisis, her 8-month delay in care likely caused her acute presentation of sepsis secondary to small bowel perforation. Given the size of her parasitic leiomyomas and the amount of frank pus, it is not difficult to imagine the severity and worsening nature of her symptoms leading up to her acute presentation.

This case demonstrates that parasitic leiomyomas can cause not just obstruction but also outright perforation of the bowel. This patient's clinical course highlights the importance of seeking care in a prompt fashion that should not be delayed by the COVID-19 pandemic.

Contributors

Anya Laibangyang drafted the manuscript and was involved in the patient's care.

Cassandra Law contributed to the review and editing of the manuscript and was involved in the patient's care.

Gunjan Gupta contributed to the review and editing of the manuscript.

Xiang Da Dong contributed to the review and editing of the manuscript and was involved in the patient's care.

Linus Chuang contributed to the review and editing of the manuscript and was involved in the patient's care.

Conflict of interest

The authors declare that they have no conflict of interest regarding

the publication of this case report.

Funding

This work did not receive any specific grant from funding agencies in the public, commercial, or not-for-profit sectors.

Patient consent

Obtained.

Provenance and peer review

This case report was peer reviewed.

References

- [1] H.A. Kelly, T.S. Cullen, *Myomata of the Uterus*, WB Saunders, 1909.
- [2] K.A. Kho, C. Nezhat, Parasitic myomas, *Obstet. Gynecol.* 114 (3) (2009) 611–615.
- [3] I. Lete, J. González, L. Ugarte, N. Barbadillo, O. Lapuente, J. Álvarez-Sala, Parasitic leiomyomas: a systematic review, *Eur. J. Obstet. Gynecol. Reprod. Biol.* 203 (2016) 250–259.
- [4] D. Dan, D. Harnanan, S. Hariharan, R. Maharaj, I. Hosein, V. Naraynsingh, Extrauterine leiomyomata presenting with sepsis requiring hemicolectomy, *Rev. Bras. Ginecol. Obstet.* 34 (6) (2012) 285–289.
- [5] A. Khan, A. Shawl, P.S. Leung, Parasitic leiomyoma of the greater omentum presenting as small bowel obstruction, *J. Surg. Case Rep.* 2018 (7) (2018).
- [6] I. Shaukat, S. Yassin, A. Paudel, N. Höti, S. Mustafa, Unusual presentation of parasitic leiomyoma; a tale of twists and turns, *J. Commun. Hospital Internal Med. Perspect.* 9 (2) (2019) 168–170.
- [7] L.B. Jacobs, B.S. Bhagavan, Intraluminal obstruction of distal ileum caused by a uterine leiomyoma, *Mod. Pathol.* 6 (2) (1993) 229–231.