

CASE REPORT

Rectal ischemia causes mass formation, masquerading as rectal cancer

Fotios Fousekis^{1,*}, Panagiota Aggeli¹, Spyridon Gkogkos²,
Panagiota Christou³ and George Pappas-Gogos²

¹Department of Gastroenterology and Endoscopy Unit, Filiates General Hospital, Filiates 46300, Greece,

²Department of Surgery, Filiates General Hospital, Filiates 46300, Greece, and ³Department of Internal Medicine, Filiates General Hospital, Filiates 46300, Greece

*Correspondence address. Pargas 23B, Igoumenitsa 46100, Greece, Tel: +30-698-852-0072; E-mail: fotisfous@gmail.com

Abstract

Rectal ischemia rarely occurs because of the rich vascular supply of the rectum, while endoscopic presentation of ischemic colitis always is not distinct and can uncommonly mimic malignant neoplasm. We present a case of a rectal ischemia, which presented with haematochezia and proctoscopy revealed a large ulcerating mass, masquerading as rectal cancer and obstructed the lumen of rectum. However, histological examinations showed only features for ischemic colitis and no evidence for malignancy. The patient was treated conservatively and 10 days later, new endoscopy showed complete disappearance of ulcerated mass, and new biopsies confirmed the initial diagnosis. Awareness and early diagnosis of ‘mass forming’ entity of ischemic colitis is very essential in order to carry out appropriate treatment and avoid severe complications.

INTRODUCTION

Acute ischemic colitis most frequently occurs in elderly patients. Its incidence rate ranges from 4.5 to 44 cases per 100 000 person-years and accounts for 1 in 2000 hospital admissions [1]. Ischemic colitis is most commonly presented with acute onset and crampy abdominal pain, which is often followed by bright red bloody stools and diarrhea. Depending on the extent of the colonic wall depth injury, acute ischemic colitis can be divided into nongangrenous form, which is limited to the mucosa and submucosa and is usually transient and spontaneously resolved, and gangrenous form, which leads to full thickness injury and can cause life threatening complications, such as peritonitis and septic shock. Rectal ischemia is very rare due to the rich vascular supply of the rectum and therefore the rectum is involved only in 2–5% of all cases of acute ischemic colitis [2]. Also, seldom severe ischemic colitis can mimic

cancer in an endoscopy examination and histological examinations are essential for early diagnosis and appropriate treatment [3]. We present the case of a severe rectal ischemia which masqueraded as rectal carcinoma, causing ulcerated mass formation.

CASE PRESENTATION

The patient was a 75-year-old woman, who arrived at the emergency department and referred to haematochezia during the 3 h before and weakness the previous days. She suffered from arterial hypertension, diabetes mellitus type 2 and heart failure, for which she was on medication including, metformin, low doses of aspirin, nebivolol, furosemide and valsartan. Physical examination demonstrated hypotension (BP: 90/65 mmHg), tachycardia and low-grade fever. There was no

Received: February 1, 2018. Revised: July 8, 2018. Accepted: July 16, 2018

© The Author(s) 2018. Published by Oxford University Press.

This is an Open Access article distributed under the terms of the Creative Commons Attribution Non-Commercial License (<http://creativecommons.org/licenses/by-nc/4.0/>), which permits non-commercial re-use, distribution, and reproduction in any medium, provided the original work is properly cited. For commercial re-use, please contact journals.permissions@oup.com

abdominal tenderness and bowel sounds were normal. The rectal examination revealed bright red blood and an irregular hard mass 4–5 cm from the anal verge. Laboratory tests showed mild leucocytosis (WBC: 12 700), an elevated CRP of 9.6 mg/dL and mild elevation of creatinine and urea. The hemoglobin was normal.

The patient was easily stabilized hemodynamically with intravenous fluids and 1 day after admission, the endoscopy revealed hemorrhagic, edematous and ulcerated mucosa with submucosal hemorrhages, and 5 cm from anal verge, there was a large ulcerating mass, causing complete obstruction of the lumen (Fig. 1). However, biopsies from the mass and the mucosa of the rectum showed features for ischemic colitis and there was no evidence for malignancy. Stool and blood cultures were negative and CEA, a-FP, PSA and Ca 19.9 were within normal limits. Additionally, computed tomography of the abdomen showed segmental wall thickening of rectal and sigmoid colon. The patient received ciprofloxacin and metronidazole intravenously. Three days later, she was nonfebrile with clinical and laboratory improvement. Ten days later, the proctoscopy demonstrated endoscopic improvement and the obstructive mass did not exist, though there were pseudomembranes, which may have been caused by mucosal hypoperfusion (Fig. 2). New biopsies were taken and confirmed the initial diagnosis. The patient was discharged 2 days later. The outpatient repeat colonoscopy demonstrated, 3 weeks later, a more evident endoscopic improvement and mucosal healing (Fig. 3). The patient remained asymptomatic during the following months.

DISCUSSION

Ischemic colitis is the most frequent form of gastrointestinal ischemia and can be caused by alterations in the systematic circulation or by anatomical or functional problems of the mesenteric vasculature, which result in the reduction of the blood supply to the colon, leading to the colon ischemia. The causes can be divided into two groups: occlusive and non-occlusive causes. To the occlusive causes belong amyloidosis, strangulated hernia, volvulus, surgery and procedures, vasculitis and vasculopathy, thromboembolism, hematologic disorders and coagulopathies. While the non-occlusive causes include septic shock, hemorrhage shock, heart failure, cardiac arrhythmias, hemodialysis and medications [4]. Approximately 20% of patients with ischemic colitis have a potentially obstructing lesion, such as colon cancer, diverticulitis or leiomyoma [5]. Furthermore, risk factors associated with the development of disorder are age, diabetes mellitus, dyslipidemia, heart failure, peripheral arterial disease and treatment with hypotensive drugs. In our case, the patient suffered from diabetes mellitus and received acetylsalicylic acid and angiotensin converting enzyme inhibitor, which have been correlated with ischemic colitis [6].

Clinical image of ischemic colitis can be mimicked in various diseases and diagnosis is based on a combination of clinical suspicion, radiographic, endoscopic and histological findings. Colonoscopy with biopsies remains the most sensitive study for the diagnosis of ischemic colitis. Endoscopic findings, suggestive of ischemic colitis, include patchial hemorrhages, edematous and fragile mucosa, mucosal bleeding, segmental erythema, scattered erosions and longitudinal ulcerations. Histological findings of ischemic colitis include edema, distorted crypts, mucosal and submucosal hemorrhage, inflammatory infiltration in the lamina propria, intravascular thrombi and necrosis. Also, stool cultures may exclude infectious colitis, which

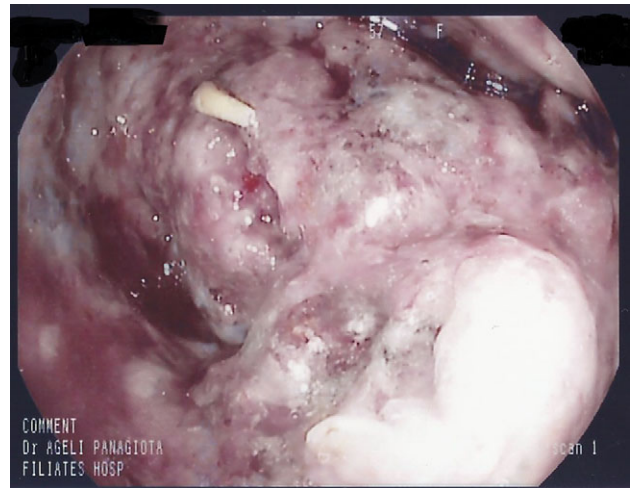


Figure 1: One day after admission. The lumen of the rectum was completely obstructed by a large ulcerating mass

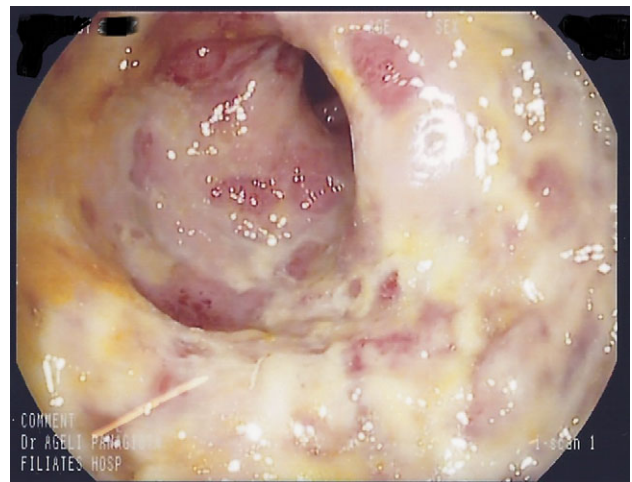


Figure 2: Ten days after the first endoscopy. The mass had completely disappeared and there were pseudomembranes on the mucosa

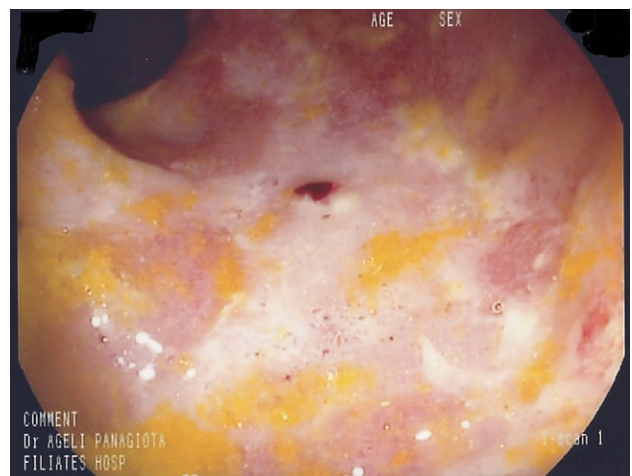

Figure 3: A month later, healing is more evident

endoscopically mimics ischemic colitis. Computed tomography is useful, showing the extent of the disease. In mild or early cases of ischemic colitis, CT may be normal, while in more severe cases, CT shows thickening of the colon wall and irregularly narrowed lumen. Intramural or portal venous gas is suggestive of bowel infarction. In addition, CT may rule out other causes of abdominal pain or sepsis [7].

Treatment depends on the severity of the disease and 80% of patients can be treated with conservative management, which consists of intravenous fluids, bowel rest, antibiotics and stabilization. Close clinical and endoscopic follow-up would be mandatory. When there are peritoneal signs, massive bleeding, toxic megacolon and gangrenous colitis, surgery should be performed. Furthermore, predictors of the severity of ischemic colitis include male gender, lack of rectal bleeding, shock or arterial hypotension (90 mmHg) and right sided ischemic colitis [8]. In our case, there was a severe rectal ischemia with transmural involvement, but due to the patient's comorbidities and no peritoneal signs, we preferred non-operative treatment.

Also, it is worth noting that atypical endoscopic image and other diseases, such as rectal syphilis and mucosal prolapsed syndrome, may mimic rectal cancer and should be included in differential diagnosis of an endoscopically likely rectal cancer [9, 10].

In conclusion, biopsies always play a critical role in the diagnosis of ischemic colitis and it is essential that endoscopists be aware of atypical rare endoscopic presentation of ischemic colitis, because a misdiagnosis of cancer can lead to erroneous treatment and severe complications.

CONFLICT OF INTEREST STATEMENT

The authors declare that there is no conflict of interest regarding the publication of this article.

FUNDING

The authors received no financial support for the research, authorship and/or publication of this article.

REFERENCES

1. Higgins PD, Davis KJ, Laine L. Systematic review: the epidemiology of ischaemic colitis. *Aliment Pharmacol Ther* 2004;**19**:729–38.
2. Sharif S, Hyser M. Ischemic proctitis: case series and literature review. *Am Surg* 2006;**72**:1241–7.
3. Deepak P, Devi R. Ischemic colitis masquerading as colonic tumor: case report with review of literature. *World J Gastroenterol* 2011;**17**:5324–6.
4. Washington C, Carmichael JC. Management of ischemic colitis. *Clin Colon Rectal Surg* 2012;**25**:228–35.
5. Karamouzis MV, Badra FA, Papatsoris AG. A case of colonic ischemia mimicking carcinoma. *Int J Gastrointest Cancer* 2002;**32**:165–8.
6. Cubiella Fernandez J, Nunez Calvo L, Gonzalez Vazquez E, Garcia Garcia MJ, Alves Perez MT, Martinez Silva I, et al. Risk factors associated with the development of ischemic colitis. *World J Gastroenterol* 2010;**16**:4564–9.
7. Theodoropoulou A, Koutroubakis IE. Ischemic colitis: clinical practice in diagnosis and treatment. *World J Gastroenterol* 2008;**14**:7302–8.
8. Sun D, Wanq C, Yanq L, Liu M, Chen F. The predictors of the severity of ischaemic colitis: a systematic review of 2823 patients from 22 studies. *Colorectal Dis* 2016;**18**:949–58.
9. Libanio D, Meireles C, Afonso LP, Henrique R, Pimentel-Nunes P, Dinis-Ribeiro M. Mucosal prolapse polyp mimicking rectal malignancy: a case report. *GE Port J Gastroenterol* 2016;**23**:214–7.
10. Pisani Ceretti A, Viridis M, Maroni N, Arena M, Masci E, Magenta A, et al. The great pretender: rectal syphilis mimic a cancer. *Case Rep Surg* 2015;**2015**:434198.