

## Case report

## *Nocardia arthritidis* as a cause of disseminated nocardiosis in a patient with chronic lymphocytic leukemia



Amity L. Roberts<sup>c,\*</sup>, Rebecca M. Davidson<sup>d</sup>, Alison G. Freifeld<sup>b</sup>, Peter C. Iwen<sup>a</sup>

<sup>a</sup> Department of Pathology and Microbiology, University of Nebraska Medical Center, Omaha, NE, United States

<sup>b</sup> Immunocompromised Host Program, Department of Medicine, University of Nebraska Medical Center, Omaha, NE, United States

<sup>c</sup> Department of Pathology, Anatomy and Cell Biology, Sidney Kimmel Medical College at Thomas Jefferson University, 117 N 11th Street, PAV 207, Philadelphia, PA 19107, United States

<sup>d</sup> Center for Genes, Environment and Health, National Jewish Health, Denver, CO, United States

## ARTICLE INFO

## Article history:

Received 18 August 2016

Received in revised form 26 September 2016

Accepted 26 September 2016

## Keywords:

Nocardiosis

*Nocardia*

*Arthritidis*

Disseminated

## ABSTRACT

A case of disseminated nocardiosis caused by *Nocardia arthritidis* in an immunocompromised patient with a history of chronic lymphocytic leukemia and rheumatoid arthritis is presented. This report highlights the use for multilocus sequence typing (MLST) in addition to single gene molecular sequencing to identify rare *Nocardia* species.

© 2016 The Authors. Published by Elsevier Ltd. This is an open access article under the CC BY-NC-ND license (<http://creativecommons.org/licenses/by-nc-nd/4.0/>).

## Case report

A 71-year-old Caucasian female with a history of chronic lymphocytic leukemia (CLL) and rheumatoid arthritis (RA) presented to her primary care physician with a 2 month history of worsening cough and dyspnea without fevers, chills or sinus congestion. She was maintained on a low dose of prednisone (homeopathic not treatment dose), at 5 mg daily, for treatment of RA. Four years prior to presentation, she was treated with chlorambucil for 6 months followed by IV immunoglobulin for 9 months for CLL.

At presentation, the patient underwent a computed tomography (CT) scan which showed a 4.5 cm non-calcified solid mass in the superior segment of the right lower lobe (RLL) followed by an ultrasound (US) guided needle biopsy. A Gram-stain of the biopsy showed gram-positive branching, beaded filamentous bacilli; however, culture was not performed at this time. The histology (performed by an outside institution) was originally negative for both bacterial and fungal elements. The patient was subsequently treated empirically with 5 weeks of oral levofloxacin (750 mg, once daily) followed by 2 weeks of oral azithromycin (500 mg daily) without improvement. Following a continued complaint of

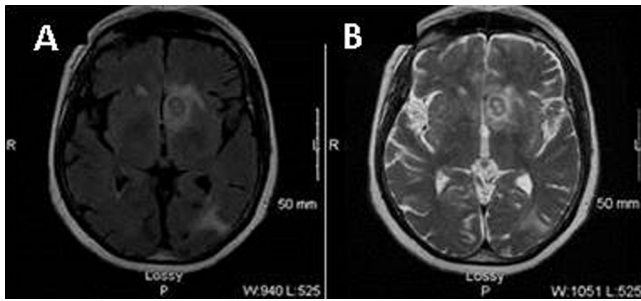
progressive breathlessness, exacerbated by activity, the patient was referred to The Nebraska Medical Center (TNMC) for further evaluation as an outpatient.

When seen in the TNMC outpatient clinic, the patient appeared well and her physical examination was normal. The absolute lymphocyte count was  $1300 \mu\text{L}^{-1}$  (normal  $700\text{--}3900 \mu\text{L}^{-1}$ ). Repeat CT scan demonstrated enlargement of the RLL mass with new cavitation. A CT-guided fine-needle biopsy of the RLL mass was performed 5 days prior to inpatient admission. Histological exam of the tissue revealed organizing acute and chronic inflammation which was reported negative for bacteria by Fite-Faraco modified acid fast (FITE) stain and negative for bacterial and for fungal elements by the Gomori methenamine-silver (GMS) stain. Five days later the patient developed fever, chills and dyspnea and was admitted to TNMC (day 0, post-admission (PA)). The RLL biopsy tissue subsequently became culture positive for a *Nocardia* species 8 days after culture on Sabouraud dextrose agar (SAB). The FITE stain of the TNMC RLL fine-needle biopsy was subsequently re-reviewed at  $1000\times$  magnification and determined to be positive for rare long thin branching filamentous bacilli that were modified acid-fast negative. Consequently the histology stain report was amended to state, "morphologically consistent with nocardiosis." The re-reviewed GMS-stained biopsy remained negative for bacterial and fungal elements.

Empiric antibacterial and antifungal agents were discontinued and high-dose oral trimethoprim-sulfamethoxazole (TMP-STX) (2 double-strength tablets (800 mg/160 mg), twice a day) was

\* Corresponding author.

E-mail addresses: [amity.roberts@jefferson.edu](mailto:amity.roberts@jefferson.edu) (A.L. Roberts), [davidsonr@njhealth.org](mailto:davidsonr@njhealth.org) (R.M. Davidson), [afreifeld@unmc.edu](mailto:afreifeld@unmc.edu) (A.G. Freifeld), [piwen@unmc.edu](mailto:piwen@unmc.edu) (P.C. Iwen).



**Fig. 1.** The MRI detected multiple intracerebral multifocal ring enhancing lesions, indicative of nocardiosis (A, B).

initiated. Although no neurological symptoms were present and the neurologic exam was normal, a magnetic resonance imaging (MRI) of the brain was performed due to the known propensity for *Nocardia* species to disseminate to the central nervous system (CNS) in immunocompromised individuals. The MRI detected multiple intracerebral multifocal ring enhancing lesions, indicative of nocardiosis (Fig. 1A, B). On day 4 PA, the patient developed a nodular lesion on the lower right leg. Biopsy of this leg lesion and histologic staining again showed the presence of modified acid-fast stain negative branching filamentous bacteria, subsequently identified in culture as *Nocardia* species. The patient was treated with a course of oral TMP-STX for a planned minimum of 12 months, in conjunction with IV ceftriaxone (2 g every 12 h) for the initial 3 months. Serum sulfamethoxazole levels were maintained at 12–16 mg/dL range over the duration of therapy.

A marked improvement of pulmonary symptoms and a decrease in the size of the brain lesions as observed by MRI after 12 weeks of combination therapy was noted. The patient continued to improve and never developed neurologic symptoms. MRI of the brain after one year of treatment with high-dose oral TMP-STX showed resolution of the abscesses and the drug was discontinued. Two months later she had a sudden syncope episode and although no changes were seen on repeat brain MRI, oral TMP-SMX was re-instituted for chronic maintenance therapy.

## Materials and methods

To determine the *Nocardia* species and to obtain the antimicrobial susceptibility testing (AST) profile, two isolates (SQ-14-947 and SQ-14-948) were submitted to an outside reference laboratory for testing (ARUP Laboratories, Salt Lake City, UT). Sequence analysis of the partial 16S rRNA target identified the isolates as *Nocardia abscessus complex/Nocardia gamkensis*. The AST minimum inhibitory concentration (MIC ( $\mu\text{g}/\text{mL}$ )) results for both case isolates were: amoxicillin/clavulanate  $\geq 128/64$  (Resistant (RR)); ceftriaxone  $\leq 4$  (Susceptible (SS)); ciprofloxacin  $\geq 8$  (RR); clarithromycin 4 (Intermediate); imipenem  $\leq 4$  (SS); tobramycin  $\leq 1$  (SS); and trimethoprim/sulfamethoxazole  $\leq 0.25/4.8$  (SS). The AST profiles and the corresponding drug patterns were inconsistent with the Type I drug susceptibility pattern for *N. abscessus complex* [1] and neither a drug pattern nor antimicrobial susceptibilities had been described for *N. gamkensis* [2,3]. Interestingly, *N. gamkensis* has yet to be reported in association with human disease, with the original isolates being discovered in soil removed from the Gamka River in Western Cape Province, South Africa [3]. Based on the AST pattern, additional analyses were pursued to confirm the species level identification. Moreover, multiple reports have shown that the partial 16S rRNA gene sequence could not differentiate between *Nocardia exalbida* and *Nocardia gamkensis* [1,4–8].

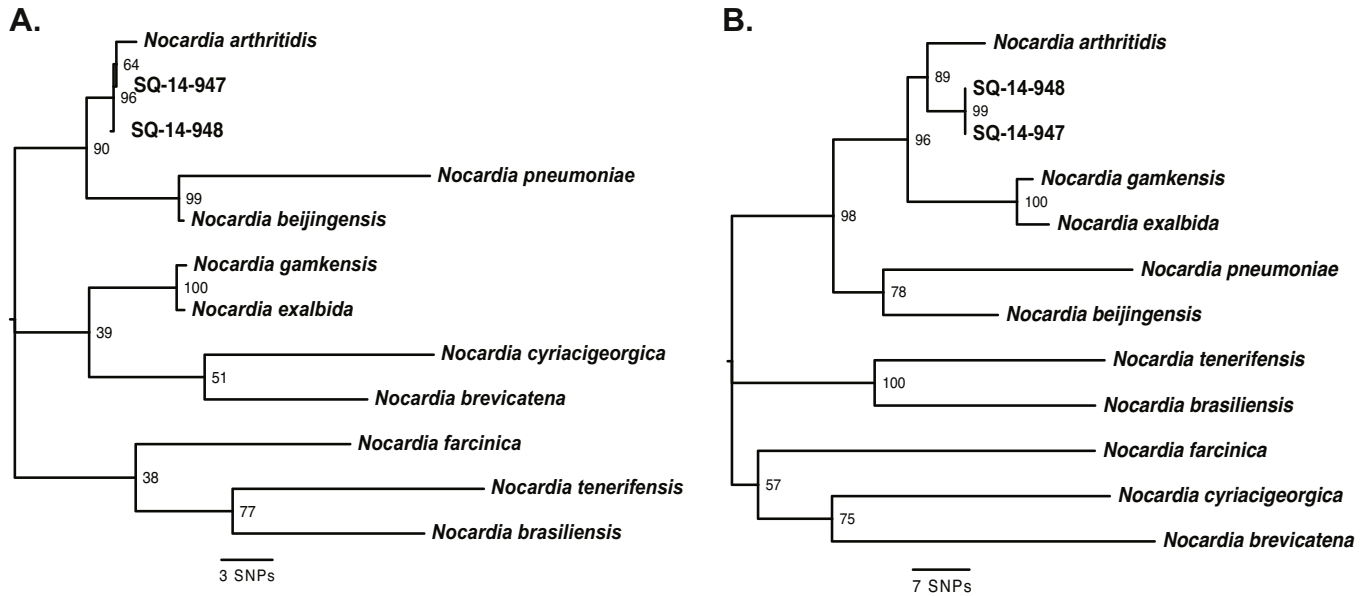
To further evaluate the species identification, the complete 16S rRNA gene as well as the *secA*, gene and *hsp65* gene were sequenced and analyzed by the Mycobacterial/Nocardia Research Reference Lab at the University of Texas Health Science Center at Tyler (UTHSC, CLIA regulated). Each gene was sequenced and analyzed per the UTHSC standard protocol [5,9,10]. The sequence analysis results showed that the complete 16S rRNA gene resulted in 99.9% match (1391/1392 bp) to *N. arthritidis* type strain, 99.5% match (1406/1413 bp) to *N. araoensis* type strain, and 99.0% match (1399/1413) to *N. exalbida* type strains for both isolates. All of these species belong to or are closely associated with *N. abscessus* complex. The CLSI recommends that  $\geq 99.6\%$  identity occur to confirm for genus and the species identification [10]. *SecA1* amino acid analysis of *secA1* gene sequencing provided a 100% match to *N. arthritidis* and *N. exalbida* type strains and 99.36% match to *N. araoensis* type strain giving a final identification of *Nocardia arthritidis/exalbida/araoensis*. For *Nocardia, secA1* has been the preferred gene for sequencing, and for 0–1 amino acid mis-match corresponding to  $\geq 99\%$  identity consider reporting the confirmed genus and species [5]. Finally, *hsp65* gene sequencing resulted in a 98.8% match (417/422 bp) to *N. arthritidis* type strain, 98.3% match (393/400 bp) to *N. exalbida* type strain and 97.4% match (411/422 bp) to *N. araoensis*. There are currently no CLSI guidelines for the interpretation of *hsp65* gene sequences in *Nocardia* species.

To improve on the resolution of the single gene sequencing results, a multi locus strain typing (MLST) approach was performed for all three gene targets (16S rRNA, *hsp65* and *secA*). Gene sequence data for the 3 loci were extracted for 10 diverse *Nocardia* species (Table 1) from the prokaryotic genome database at the National Center for Biotechnology Information (NCBI), and sequences were concatenated for each species. Then, neighbor joining phylogenetic analyses [11] with 100 replicate searches were performed for each gene separately and the concatenated sequences (MLST) for all 12 strains using the SeaView software package [27]. The results following analysis showed that for Phylogenies: 1.) for the individual gene analyses, 2 of the 3 genes (16S rRNA and *hsp65*) suggested that SQ-14-947 and SQ-14-948 are most closely related to *Nocardia arthritidis* while *secA1* supported placement next to *N. exalbida* and *N. gamkensis*. Both of these trees, however, had low bootstrap support ( $< 50$ ) at the basal nodes indicating unreliable branching patterns (Fig. 2A). 2.) For the MLST analysis, the bootstrap support values were  $\geq 57$  at all nodes, and SQ-14-947 and SQ-14-948 are monophyletic with *Nocardia arthritidis* (Fig. 2B). The 16S rRNA alignment contained only 49 informative positions (out of 1489 total positions) while the MLST consensus sequence alignment contained 123 informative positions (out of 2375 total positions) illustrating the increased resolution of the MLST approach. Pairwise distance comparisons of concatenated MLST sequences: 1.) SQ-14-947 and SQ-14-948 isolates were identical (100% identity); 2.) with 12/2389 variable sites between SQ-14-947 and *Nocardia arthritidis* (99.5%

**Table 1**  
*Nocardia* species included in the MLST phylogenetic analysis.

Species	Strain Name	Accession Number <sup>a</sup>
<i>Nocardia arthritidis</i>	NBRC 100137	BDBB01000084.1
<i>Nocardia beijingensis</i>	NBRC 16342	BDBC01000022.1
<i>Nocardia brasiliensis</i>	ATCC 700358	NC_018681.1
<i>Nocardia brevicatena</i>	NBRC 12119	NZ_BAFU010000024.1
<i>Nocardia cyriacigeorgica</i>	GUH-2	NC_016887.1
<i>Nocardia exalbida</i>	NBRC 100660	NZ_BAFZ01000028.1
<i>Nocardia farcinica</i>	IFM 10152	NC_006361.1
<i>Nocardia gamkensis</i>	NBRC 108242	BDBM01000066.1
<i>Nocardia pneumoniae</i>	NBRC 100136	NZ_BAGF01000021.1
<i>Nocardia tenerifensis</i>	NBRC 101015	NZ_BAGH01000146.1

<sup>a</sup> Gene sequences were extracted from publicly available genomes in the GenBank database at NCBI.



**Fig. 2.** Phylogenetic analyses of strains SQ-14-947 and SQ-14-948 compared to 10 diverse *Nocardia* species. A.) 16S rRNA sequences and B.) concatenated sequences of 16S rRNA, *hsp65* and *secA1* were aligned, and phylogenies were constructed with the neighbor joining method. Bootstrap support values of 100 replicate searches are shown at each node.

identity); 3.) with 22/2389 variable sites between SQ-14-947 and *Nocardia gamkensis* (99.1% identity); 4.) with 25/2389 variable sites between SQ-14-947 and *Nocardia exalbida* (99% identity); and 5.) with are 38/2389 variable sites between SQ-14-947 and *Nocardia beijingensis* (98.4% identity). These results showed via MLST that both isolates were identified as *Nocardia arthritis*.

## Discussion

Greater than 80 valid species of *Nocardia* have been described (List of Prokaryotic Names, [www.bacterio.net](http://www.bacterio.net), accessed 22 April 2014), with only 11 species reported as isolated from human infections to include *N. abscessus*, *N. brasiliensis*, *N. cyriacigeorgica*, *N. farcinica*, *N. nova*, *N. otitidiscaviarum*, *N. paucivorans*, *N. pseudobrasiliensis*, *N. transvalensis*, *N. veteran*, and *N. wallacei* [17,18]. Initially, *Nocardia* species that cause human infection were typically classified as *N. asteroides* or *N. asteroides* complex. But with the advent of molecular analysis for more precise identification, *N. asteroides* complex became an obsolete species [1,12]. Overall, *Nocardia* species are typically associated with environmental sources [13]. The *Nocardia* species are long thin, finely beaded branching gram-positive bacilli that are strict aerobic, generally modified acid-fast positive and typically stain positive by the Gomori methanamine silver (GMS) stain in tissue [4]. Amplification and sequencing of individual conserved genes, such as the 16S rRNA gene, *hsp65* gene, *secA* gene, and *gyrB* gene have been used for the identification of *Nocardia* species [1,4,7,14]. Genomic sequencing has led to the discovery of numerous previously unrecognized or rare *Nocardia* species that cause human disease. This report describes a case of disseminated infection by *Nocardia arthritis* within the United States and highlights the methods used to verify the species identification.

*Nocardia arthritis* was first published as a valid species in 2004 by Kageyama et al., who reported a Japanese patient from whom *N. arthritis* type strain IFM 10035<sup>T</sup> (NBRC 100137<sup>T</sup>, JCM 12120<sup>T</sup>, DSM 44731<sup>T</sup>) was isolated from the sputum of a patient with rheumatoid arthritis [15]. This isolate was classified by the 16S rRNA sequence, DNA–DNA hybridization, and biochemical phenotypic properties [15]. Since this initial publication, additional

cases caused by *N. arthritis* have been reported to include a recovery of *N. arthritis* from a frontal lobe lesion in a patient in Spain with a history of silicosis [16]; a case of cerebral nocardiosis in an immunosuppressed patient with systemic lupus erythematosus in Turkey [17]; and a case of *N. beijingensis* and *N. arthritis* coinfection in a retrotracheal necrotic mass of an immunosuppressed patient in Ohio, USA [18]. Each of these reports primarily utilized 16S rRNA sequencing or species identification [16–18].

Conditions that contribute to the risk for nocardiosis include cellular immune dysfunction, usually due to high-dose steroids, hematologic malignancy (such as CLL in the patient presented here), or chronic immune suppression following solid organ transplantation [19–21] (Rosman article, 21, 22). Chronic obstructive pulmonary disease may also be a risk factor, and up to a quarter of nocardiosis cases are noted in immunocompetent individuals [19,20]. The present case patient was treated with prednisone (5 mg per day) for RA, a dose that is not considered to be immunosuppressive, although corticosteroid use has been shown to correlate with the development of pulmonary or disseminated nocardiosis in 64.5% (n = 20 of 31) of nocardiosis cases [19,20].

Regardless of immune status there is a risk for progression to disseminated disease in about 30% of all patients with primary nocardiosis [20]. Disseminated infection is characterized by abscess formation at multiple body sites with common sites being the brain, retina, skin, subcutaneous tissue, kidney, bone and heart [19]. The criteria for disseminated nocardiosis include involvement of two or more noncontiguous site organs [22]. *Nocardia* species reported associated with disseminated nocardiosis included *N. abscessus*, *N. beijingensis*, *N. cyriacigeorgica*, *N. farcinica*, *N. higoensis*, *N. nova*, *N. otitidiscaviarum*, *N. paucivorans*, *N. pseudobrasiliensis* and *N. transvalensis* [1]. CNS involvement has been noted in 11.7–44% of systemic nocardiosis cases, usually in the form of one or more brain abscesses [6,19,23].

In the present case, *N. arthritis* was isolated from tissue obtained from both the lung and leg in pure culture from a febrile patient with a history of CLL and RA. The original modified acid fast (FITE) stain of a fine-needle biopsy of the RLL was reported as negative for bacteria. Following a positive culture, the original FITE-stained tissue slides were re-observed using 1000×

magnification. Subsequently, rare filamentous modified AFB negative bacteria were discovered. Due to a lack of contrast between the organism and background, the organisms were not visible under 40× magnification (standard procedure used to observe histology slides). Over-decolorization during the staining process of the rare finely beaded *Nocardia* cells present in the sample may also have accounted for the inability to observe the filamentous bacteria in the original stain. A positive control slide (containing a *Mycobacterium* species) that was used at the time of staining the original specimen correctly stained as modified AFB positive. A modified Ziehl-Neelsen acid-fast stain performed from culture of the isolate was also positive. The GMS stained slide of the original biopsy sample remained negative for both bacteria and fungal cells after observation under 1000× magnification. Rare reports have shown that a negative GMS stain was seen for some *Nocardia* species although the reason for this was not elucidated [24,25].

Molecular sequencing of the variable regions of the 16S rRNA gene, *hsp65* gene, *secA* gene, and *gyrB* gene targets have been shown to be discriminatory enough to distinguish among closely related *Nocardia* species [1,4–8]. Historically, the AST pattern type groups were utilized to separate among species and complexes within the *Nocardia* genus. The six major drug pattern groups have been classified as Types I–VI [1]. As indicated previously, *N. abscessus* belongs to the AST pattern designated as Type I; whereas, *N. beijingensis* and *N. arthritidis* do not have officially accepted AST patterns [1,26]. Although the AST patterns for *Nocardia* can remain useful in the initial characterization of *Nocardia* species, inconsistencies in this pattern recognition have been noted and are now used less frequently than molecular methods. In conclusion, this report describes a unique case of disseminated nocardiosis caused by *N. arthritidis*. The difficulty of recognizing *Nocardia* species in tissue and the complexity of methods needed to provide a confirmed species identification were shown. The benefit of utilizing MLST for difficult to speciate is described in this report. Increased use of molecular methods and the expansion of mass spectrometry for identification purposes will likely expand the number of *Nocardia* species associated with human disease. Consequently, human infections linked to rarely detected *Nocardia* species such as *N. arthritidis* and newly described species will likely be encountered more frequently from a wider geographical distribution. Finally, the observation of tissue following histological staining using high-power magnification is suggested when negative results are seen from patients who are at high risk for nocardiosis.

### Conflict of interest

All authors report no conflicts of interest.

### References

- [1] Brown-Elliott BA, Brown JM, Conville PS, Wallace Jr. RJ. Clinical and laboratory features of the *Nocardia* spp. based on current molecular taxonomy. *Clin Microbiol Rev* 2006;9(2):259–82.
- [2] Validation list no. 113. List of new names and new combinations previously effectively, but not validly, published, *Int J Syst Evol Microbiol* 57(Pt 1) (2007) 1.
- [3] le Roes M, Meyers PR. *Nocardia gamkensis* sp. nov. *Antonie Van Leeuwenhoek* 2006;90(3):291–8.
- [4] Conville PS, Witebsky FG. The complexity of *Nocardia* taxonomy: implications for the clinical microbiology laboratory. *Clin Microbiol News* 2010;32(16):119–25.
- [5] Conville PS, Zelazny AM, Witebsky FG. Analysis of *secA1* gene sequences for identification of *Nocardia* species. *J Clin Microbiol* 2006;44(8):2760–6.
- [6] Lerner PI. Nocardiosis. *Clin Infect Dis* 1996;22(6):891–903.
- [7] Rodriguez-Nava V, Couble A, Devulder G, Flandrois JP, Boiron P, Laurent F. Use of PCR-restriction enzyme pattern analysis and sequencing database for *hsp65* gene-based identification of *Nocardia* species. *J Clin Microbiol* 2006;44(2):536–46.
- [8] Wauters G, Avesani V, Charlier J, Janssens M, Vaneechoutte M, Delmee M. Distribution of nocardia species in clinical samples and their routine rapid identification in the laboratory. *J Clin Microbiol* 2005;43(6):2624–8.
- [9] A. bio-systems. Fast Microseq 500 16S rRNA Bacterial Identification Kits Protocol. Foster City, CA, USA: Life Technologies Corporation; 2010.
- [10] Interpretive criteria for identification of bacteria and fungi by DNA targetsequencing. Approved Guideline, CLSI. Wayne, PA, USA: C.L.S. Institute; 2008.
- [11] Saitou N, Nei M. The neighbor-joining method: a new method for reconstructing phylogenetic trees. *Mol Biol Evol* 1987;4(4):406–25.
- [12] Wilson JW. Nocardiosis: updates and clinical overview. *Mayo Clin Proc* 2012;87(4):403–7.
- [13] Parte AC. LPSN—list of prokaryotic names with standing in nomenclature. *Nucleic acids research* 2014;42(Database issue):D613–6.
- [14] Reddy AK, Garg P, Kaur I. Speciation and susceptibility of *Nocardia* isolated from ocular infections. *Clin Microbiol Infect* 2010;16(8):1168–71.
- [15] Kageyama A, Torikoe K, Iwamoto M, Masuyama J, Shibuya Y, Okazaki H, et al. *Nocardia arthritidis* sp. nov., a new pathogen isolated from a patient with rheumatoid arthritis in Japan. *J Clin Microbiol* 2004;42(6):2366–71.
- [16] Tamarit M, Poveda P, Baron M, Del Pozo JM. Four cases of nocardial brain abscess. *Surg Neurol Int* 2012;3:88.
- [17] Yildiz O, Alp E, Tokgoz B, Tucer B, Aygen B, Sumerkan B, et al. Nocardiosis in a teaching hospital in the Central Anatolia region of Turkey: treatment and outcome. *Clin Microbiol Infect* 2005;11(6):495–9.
- [18] Aragaki-Nakahodo A, Benzaquen S, Kirschner M. Coinfection by *Nocardia beijingensis* and *Nocardia arthritidis* in an immunocompromised patient diagnosed by endobronchial ultrasound guided transbronchial needle aspiration (EBUS-TBNA). *Respir Med Case Rep* 2014;12:22–3.
- [19] Sorrell TC, Mitchell DH, Iredell JR, Chen SCA. *Nocardia* Species, Mandell, Douglas, and Bennett's Principles and Practice of Infectious Diseases. Philadelphia, PA: Churchill Livingstone Elsevier; 2010. p. 3199–207.
- [20] Martinez Tomas R, Menendez Villanueva R, Reyes Calzada S, Santos Durantez M, Valles Tarazona JM, Modesto Alapont M, et al. Pulmonary nocardiosis: risk factors and outcomes. *Respirology* 2007;12(3):394–400.
- [21] Rosenthal T, Rosenmann E, Tomassoni D, Amenta F. Effect of lercanidipine on kidney microanatomy in Cohen-Rosenthal diabetic hypertensive rats. *J Cardiovasc Pharmacol Ther* 2007;12(2):145–52.
- [22] Simpson GL, Stinson EB, Egger MJ, Remington JS. Nocardial infections in the immunocompromised host: a detailed study in a defined population. *Rev Infect Dis* 1981;3(3):492–507.
- [23] Beaman BL, Beaman L. *Nocardia* species: host-parasite relationships. *Clin Microbiol Rev* 1994;7(2):213–64.
- [24] Lum CA, Vadmal MS. Case report *Nocardia asteroides* mycetoma. *Ann Clin Lab Sci* 2003;33(3):329–33.
- [25] Karnatovskaia S. Reatment of nocardia higoensis/shimofusensis masquerading as bronchitis and presenting as a solitary mass in a bone marrow transplant recipient. *Chest J* 2012 (4\_MeetingAbstracts).
- [26] CLSI. Susceptibility testing of *Mycobacteria*, *Nocardiae*, and other Aerobic Actinomycetes; Approved Standard-Second Edition, CLSI M24-A2, CLSI, Editor 2011, Wayne, PA, 2011.
- [27] Gouy M, Guindon S, Gascuel O. SeaView version 4: a multiplatform graphical user interface for sequence alignment and phylogenetic tree building. *Mol Biol Evol* 2010;27:221–4.