



ORIGINAL ARTICLE

Can serial cerebral MRIs predict the neuronopathic phenotype of MPS II?

Audrey A. M. Vollebregt^{1,2}  | Berendine J. Ebbink¹ | Dimitris Rizopoulos³ |
 Maarten H. Lequin⁴ | Femke K. Aarsen⁵ | Elsa G. Shapiro⁶ |
 Ans T. van der Ploeg¹ | Johanna M. P. van den Hout¹ 

¹Center for Lysosomal and Metabolic Diseases (Department of Pediatrics), Erasmus MC, University Medical Center, Rotterdam, The Netherlands

²Department of Pediatrics, Maastricht University Medical Center, Maastricht, The Netherlands

³Department of Biostatistics, Erasmus MC, University Medical Center, Rotterdam, The Netherlands

⁴Department of Radiology, Imaging Division & Utrecht Cancer Center, Utrecht, The Netherlands

⁵Department of Psychosocial Care and Psychology, Princess Maxima Center for Pediatric Cancer, Utrecht, The Netherlands

⁶Center for Neurobehavioral Development, University of Minnesota, Minneapolis, Minnesota

Correspondence

Johanna M. P. van den Hout, Erasmus MC, University Medical Center, Sophia Children's Hospital, P.O. Box 2060, 3000 CB Rotterdam, The Netherlands.
 Email: j.vandenhout@erasmusmc.nl

Funding information

FP7 Health, Grant/Award Number: FP7/2007-2013; MeusIX, Grant/Award Number: 304999; Stichting Zeldzame Ziekten Fonds, Grant/Award Number: 1415151; European Community's Seventh Framework Programme

Communicating Editor: Roberto Giugliani

Abstract

Objective: To advance the prediction of the neurocognitive development in MPS II patients by jointly analyzing MRI and neurocognitive data in mucopolysaccharidosis (MPS) II patients.

Methods: Cognitive ability scores (CAS) were obtained by neuropsychological testing. Cerebral MRIs were quantified using a disease-specific protocol. MRI sumscores were calculated for atrophy, white-matter abnormalities (WMA) and Virchow-Robin spaces (VRS). To distinguish between atrophy and hydrocephalus the Evans' index and the callosal angle (CA) were measured. A random effects repeated measurement model was used to correlate CAS with the three MRI sumscores.

Results: MRI (n = 47) and CAS scores (n = 78) of 19 male patients were analyzed. Ten patients were classified as neuronopathic and nine as non-neuronopathic. Neuronopathic patients had normal cognitive development until age 3 years. Mental age plateaued between ages 3 and 6, and subsequently declined with loss of skills at a maximum developmental age of 4 years. MRIs of neuronopathic patients showed abnormal atrophy sumscores before CAS dropped below the threshold for intellectual disability (<70). White-matter abnormalities (WMA) and brain atrophy progressed. The calculated sumscores were inversely correlated with CAS ($r = -.90$ for atrophy and

The Center for Lysosomal and Metabolic Diseases is a joint initiative of the Departments of Pediatrics, Clinical Genetics, Neurology, Internal Medicine, and Hospital Pharmacy.

This is an open access article under the terms of the Creative Commons Attribution-NonCommercial-NoDerivs License, which permits use and distribution in any medium, provided the original work is properly cited, the use is non-commercial and no modifications or adaptations are made.

© 2020 The Authors. *Journal of Inherited Metabolic Disease* published by John Wiley & Sons Ltd on behalf of SSIEM.

–.69 for WMA). This was not biased by the influence of hydrocephalus as shown by measurement of the Evans' and callosal angle. Changes over time in the Virchow-Robin spaces (VRS) on MRI were minimal.

Conclusion: In our cohort, brain atrophy showed a stronger correlation to a decline in CAS when compared to WMA. Atrophy-scores were higher in young neuronopathic patients than in non-neuronopathic patients and atrophy was an important early sign for the development of the neuronopathic phenotype, especially when observed jointly with white-matter abnormalities.

KEYWORDS

hunter syndrome, lysosomal, MPS II, MRI, mucopolysaccharidosis, neuropsychological, phenotype

1 | INTRODUCTION

Mucopolysaccharidosis type II (MPS II, OMIM #309900) is an X-linked, lysosomal storage disorder caused by a deficiency of iduronate-2-sulphatase; it is characterized by storage of heparan and dermatan sulphate.¹ Patients with MPS II represent a broad clinical spectrum. At the severe end are the neuronopathic patients who experience progressive cognitive decline and behavioral problems and generally do not survive into adulthood.^{2,3} At the milder end are patients with the non-neuronopathic phenotype, who survive into adulthood and whose cognitive development is close to normal.⁴

Since 2007, intravenously administered enzyme replacement therapy (ERT) with recombinant human iduronidate-2-sulfatase (EC 3.1.6.13; Elaprase, Shire, Cambridge, Massachusetts) has been available for MPS II patients. As these enzymes cannot pass the blood-brain barrier, ERT does not halt disease progression in the brain.^{2,4,5}

Especially in children with MPS II, very little information is available about the development of cognitive skills, in particular related to magnetic resonance imaging (MRI) analysis. Attempts have been made to identify early clinical markers in prospective follow up studies of cognitive development or in cross sectional or follow-up brain MRI studies, but so far these studies did not analyze the relation of both parameters over time.⁶⁻¹⁰ It was further indicated that longer prospective follow up studies were needed in young MPS II patients starting before they develop cognitive impairment.

Currently, no accurate distinction can be made between the neuronopathic and non-neuronopathic phenotypes in very young children. Early markers such as baseline GAG levels and iduronate-2-sulphatase activity are not fully distinctive.^{1,11} The genotype-phenotype correlation in MPS II is also poor. While the phenotype

SYNOPSIS

The combined analysis of MRI and neuropsychological data improves the management and understanding of MPS II and improves the prediction of early cognitive decline.

appears to be relatively consistent for some genetic variants, such as deletion and rearrangements, the large number of de novo missense mutations makes early prediction impossible in most patients.¹¹ Due to the current development of new therapies which are intended to target the brain, such as intrathecal ERT and gene therapy, it is even more important to diagnose patients at an early stage, and to predict the neuronopathic phenotype as accurate and early as possible. Not only would early prediction give parents a clearer perspective on their children's future, an early and accurate prediction of the course of disease is essential to selecting suitable patients for clinical trials and to interpreting the effects of future therapies. We therefore jointly analyzed MRI and neurocognitive data in neuronopathic and non-neuronopathic children and adults with MPS II in order to identify early MRI changes specific to the neuronopathic phenotype.

2 | METHODS

The participants in this study were all the MPS II patients who had been referred before February 1, 2016 to the Dutch national reference center for MPS II, that is, the Center for Lysosomal and Metabolic Diseases at Erasmus MC in Rotterdam. All diagnoses had been established on the basis of mutation analysis, elevated urinary glycosaminoglycans (uGAG), and decreased iduronate-

2-sulphatase levels in leukocytes and/or fibroblasts. The study protocol was approved by the Medical Ethical Committee at Erasmus MC, and written informed consent was obtained from patients and/or their legal guardians.

2.1 | Neuropsychological testing

Annual neuropsychological testing was performed in patients younger than 21 years. Neuropsychological tests were conducted by two experienced neuropsychologists at our center (B.J.E. and F.K.A.). The following tests were used: the Griffiths Mental Developmental Scales (Griffiths) for patients with an estimated cognitive developmental age under 6 years; the Dutch third edition of the Wechsler Intelligence Scales for Children (WISC-III-NL) for patients with an estimated developmental age of 6 to 16 years; and the Wechsler Adult Intelligence Scales (WAIS-VI-NL) for patients with an estimated developmental age of 16 years or higher. The Snijders-Oomen Nonverbal Intelligence test-Revised (SON-R 2 ½ -7) was used for patients with uncompensated hearing loss. In rare cases, developmental testing was performed by licensed local psychologists associated with the children's educational environment (Figure S1). In preschool children, or children with an intellectual developmental equivalent of preschool children, the term developmental quotient (DQ) is used instead of IQ. For convenience, the term Cognitive ability scores (CAS) was used for the

outcome of all standardized tests evaluating cognitive skills. Patients were classified as neuronopathic if their CAS at the latest assessment had been below 70. Adult patients for whom no neuropsychological data was available were classified for the statistical analysis as neuronopathic or non-neuronopathic on the basis of their educational level and functioning in society.

2.2 | Imaging

MRI of the brain was scheduled annually (Figure 1). No MRI was performed if (a) patients did not give their consent, or (b) their clinical condition (eg, narrowing of the upper airway) gave a contra-indication for the sedation needed for optimal neuroimaging. Patients were scanned on a 1.5T system with a dedicated 8-channel head coil (EchoSpeed; GE Healthcare, Milwaukee, Wis.). T1-weighted, T2-weighted and FLAIR sequences were included in the scanning protocol. All available brain MRIs were reviewed using a scoring system specifically designed for this study, which combined information derived from four articles on brain abnormalities in MPS II patients.^{2,12-14} The MRIs were scored independently by two observers (A.A.M.V and J.M.v.d.H) trained specifically for this study by an experienced pediatric neuroradiologist (M.H.L). Normal scans provided by the radiology department served as a reference. If scores differed, the two observers reevaluated the MRIs in order to reach consensus. The following items were evaluated: (a) size

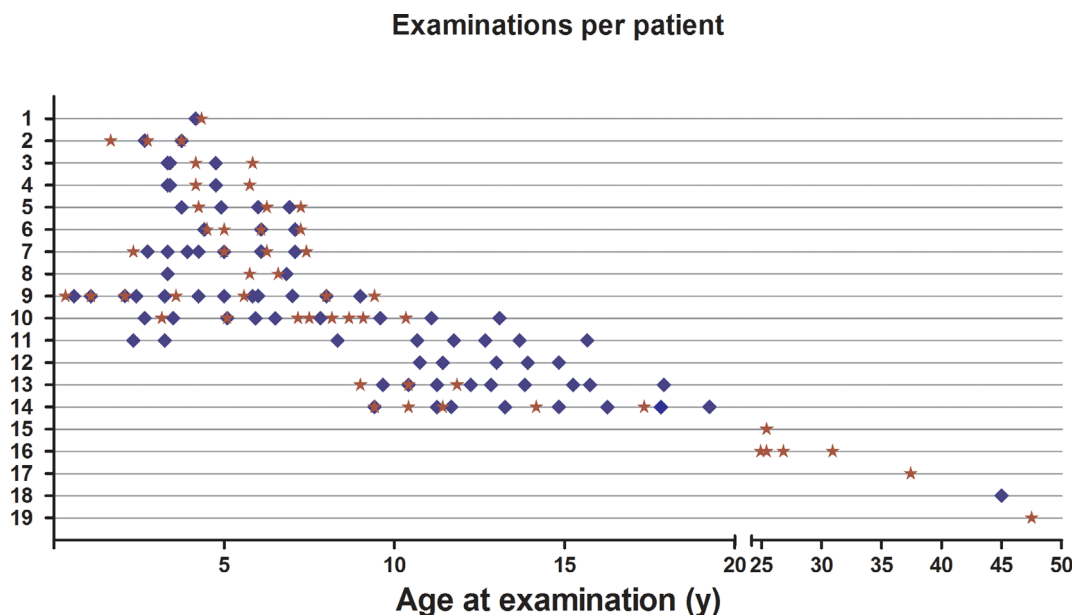


FIGURE 1 Overview of the frequency of MRI and neuropsychological assessment. The numbers on the y-axis correspond to the patient numbers shown in Table 1. A red star represents a single MRI and a blue diamond represents a neuropsychological test. Neuropsychological tests are further defined in Figure S1

and number of Virchow-Robin spaces (VRS) in multiple areas of the brain; (b) size and location of white-matter abnormalities (WMA) in two areas (occipital and frontal); (c) cerebral atrophy (diameters of the lateral, third and fourth ventricles, widths of the fissure and sulci and Evans Index¹⁵; and (d) corpus-callosum size, diameters of the optic nerve sheaths, hyperostosis of the skull, sella turcica enlargement and shape, skull shape, mega cisterna magna, and Chiari malformation. To distinguish between atrophy and hydrocephalus the callosal angle (CA) was measured. For the measurement of both the Evans' Index and the callosal angle scans were realigned according to AC-PC plane. The CA was measured through the posterior commissure, perpendicular to the anterior commissure plane. Multiplanar reconstruction was performed interactively in the Picture Archiving and Communication System (PACS) for patients to obtain such a coronal image. The Evans Index was calculated as the ratio between the maximal width of the frontal horns and the maximal width of the inner diameter of the skull, which were measured on the individual T1-weighted axial images. Hydrocephalus was defined as a callosal angle of less than 90° and atrophy as a callosal angle of over 90°. ¹⁶ For statistical analysis, sumscores were calculated for Virchow-Robin spaces (range: 0-20); white-matter abnormality (range 0-12); and cerebral atrophy (range 0-7). Table S1 provides full details of the scoring system used and calculation of the composite sumscores.

2.3 | Statistical analysis

Statistical analysis was performed using R (version 3.2.1) with nlme (linear and nonlinear mixed-effects models).¹⁷ With this model we were able to analyze the repeated measurements of all individual patients for the following variables: VRS over time, WMA over time, Atrophy over time and CAS over time. To analyze the change in CAS and MRI sumscores, while also accounting for the correlations in the repeated measurements of each patient, we used the framework of linear mixed-effects models. MRI and CAS were analyzed at group level by generating a linear mixed-effect model based on all individual linear models. Time was expressed as age in months. Since our main goal was statistical substantiation of the relation between mental development and MRI characteristics we analyzed the interaction between CAS and each separate sumscore. The following three bivariate mixed models were used in which CAS over time were analyzed jointly with (a) VRS sumscore over time, (b) WMA sumscore over time; and (c) atrophy sumscore over time. The relationship between these

outcomes was measured with the random effects variance covariance matrix.

3 | RESULTS

3.1 | Patients

Nineteen male MPS II patients were enrolled in this study (Table 1). Figure 1 shows the timepoints at which MRI and neuropsychological tests were performed. Eighteen patients received ERT; unless indicated otherwise, they continued to receive it until their latest evaluation. Three patients died during the course of the study, at the ages of 15, 16 and 20 years. Two patients received a ventriculo-peritoneal (VP) shunt for the treatment of their hydrocephalus: patient 9 at the age of 2 years, and patient 10 at the age of 7 years.

3.2 | Cognitive ability score

Fifteen patients underwent neuropsychological testing. A total of 78 neuropsychological tests were performed, 51 of them in patients aged under 6 years (Figure S1). The patients' age range at first assessment was 0.6 to 45 years (Figure 1). The time span between the first and last assessment ranged from 1 to 13.3 years (median 4.3 years). Ten patients were classified as neuronopathic (patients 2, 5, 6, 7, and 9-14; age range at latest assessment 5-20 years; CAS range 2-50). Nine were classified as non-neuronopathic (patients 1, 3, 4, 8 and 15-19; age range at latest assessment 5-50 years; CAS range 73-112) (Table 1).

Figure 2A shows the mental age expressed against chronological age and Figure 2B shows the trajectory of CAS. Before the age of 3, all patients had a mental age close to normal (Figure 2A). In the neuronopathic patients, cognitive development slowed or halted between 3 and 6 years of age. Thereafter, mental age gradually declined, reflecting loss of skills. Of patients whom mental age scores were available, the maximum mental age achieved in neuronopathic patients was 4 years. In terms of chronological age, the plateauing of mental age shown in Figure 2A actually represented a strong decline in CAS.

Figure 2B shows the trajectory of CAS. The decline in CAS in neuronopathic patients was initially rapid, slowing later due to a floor effect (Figure 2B). In contrast, all but one patient, who had been classified as non-neuronopathic had a CAS above 96 and remained stable throughout the study. The exception, patient 8, declined by 9 CAS points in 3.5 years to a borderline non-

TABLE 1 Patient characteristics

Patient no.	Age at start of ERT (y)	Age at latest visit (y)	IDS variant coding DNA	IDS variant protein	Latest CAS*	Number of MRIs
1	4.4	4.9	c.673T>G	p.Tyr225Asp	96	1
2	2.8	4.8	c.998C>T	p.Ser333Leu	50	3
3	3.6	6.1	c.410T>C	p.Phe137Ser	107	2
4	3.6	6.1	c.410T>C	p.Phe137Ser	116	2
5	4.1	7.5	Total IDS deletion	No protein	25	3
6	\$	8.0	Total IDS deletion	No protein	13	4
7	2.3	8.2	c.544del	p.Leu182Cysfs*31	32	4
8	5.2	8.2	c.1511delG	p.Gly504Valfs*8	73	2
9	1.0	9.7	c.349_c.351delTCC	p.Ser117del	17	5
10	5.5	14.0	c.998C>T	p.Ser333Leu	11	7
11	8.6	15.7 [#]	c.1375G>T	p.Glu459*	15	0
12	10.9	16.7 [#]	c.1561G>A	p.Glu521Lys	2	0
13	9.7	18.3	c.257C>T	p.Pro86Leu	9	3
14	5.2	20.5 [#]	c.1047C>A	p.Ser349Arg	14	4
15	25.4	30.0	c.1122C>T	p.Gly373Gly	N/A ^Δ	1
16	24.5	32.9	c.1265G>A	p.Cys422Tyr	N/A ^Δ	4
17	36.9 ^α	44.7	c.182C>A	p.Ser61Tyr	N/A ^Δ	1
18	44.6	45.7	c.1024C>T	p.His342Tyr	112	0
19	47.3 ^β	50.3	c.806A>T	p.Asp269Val	N/A ^Δ	1

Note: Patients are ordered according to their age at latest visit defined by the endpoint of the study regardless of ERT or when marked with a # defined by age at death. ERT = enzyme replacement therapy; CAS = Cognitive ability scores; N/A Not applicable; \$ Did not start ERT; α ERT stopped after 24 months; β ERT stopped after 19 months; * For convenience reasons, the term Cognitive Ability Score (CAS) was used for the outcome of all standardized tests evaluating cognitive skills; Δ classified as non-neuronopathic for statistical analysis.

neuronopathic patient, CAS of 73 at the age of 8 years, the last time point in this study.

3.3 | MRI

In total, 47 cerebral MRIs were performed in 16 patients (age range 1.7–47.5 years). In 12 patients, more than one MRI was performed, ranging from 2 to 7 MRIs per individual. The intervals between the first and last MRI ranged from 0.8 to 7.9 years (median 2.9 years).

The following cerebral abnormalities were observed: VRS (in 87% of patients); enlargement of the lateral ventricle (73%) and of the third ventricle (60%); widening of the fissures (67%); white-matter lesions (67%); mega cisterna magna (60%); and enlarged optic-nerve sheath (53%). No Chiari malformation was observed. In addition, the following bone abnormalities were found: hyperostosis (in 73% of patients); abnormal skull shape (in 60%); and abnormally shaped sella turcica (in 40%).

Serial MRIs in individual patients showed that Virchow-Robin spaces barely changed over time (Figure 3A–C). Most

VRS were periventricular (in 87% of patients); subcortical (in 87%); in the corpus callosum (in 80%); and/or in the basal ganglia (in 60%). White-matter abnormalities did progress over time (Figure 3D–F): initially, small lesions were observed mainly around the occipital horn of the lateral ventricles; later, they also appeared around the frontal horns. A clear pattern was observed: small solitary white-matter lesions that expanded slowly. Eventually these large areas of abnormal white matter—which were present mainly in the occipital, lateral and frontal periventricular horn—merged and extended to the subcortical u-fibers. As for WMA, brain atrophy also progressed over time (Figure 3G–I). The presence of atrophy was generalized and not restricted to specific areas of the brain. An Evans' index > 0.3 was present in 30/47 MRIs of 12/16 patients (all 10 neuronopathic children and the 2 oldest non-neuronopathic adults; Figure S2). In 20/30 MRIs in which the Evans' Index > 0.3, the callosal angle was more than 90° indicative for atrophy¹⁶, this included the non-neuronopathic patients. In 2 of the 12 patients (7/30 MRIs) the coronal image could not be reconstructed. In one of these patients the volume of the corpus callosum and the

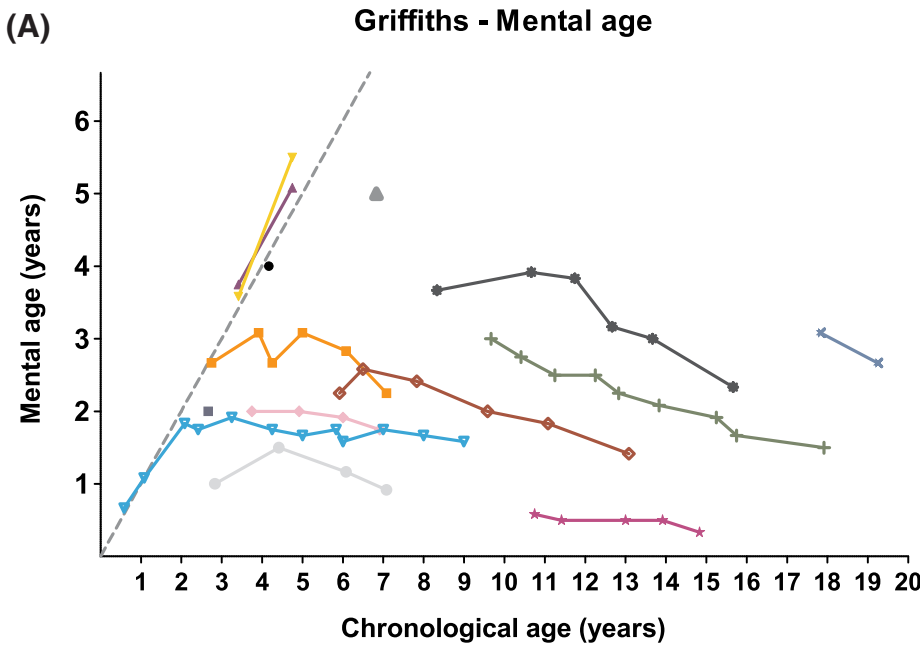
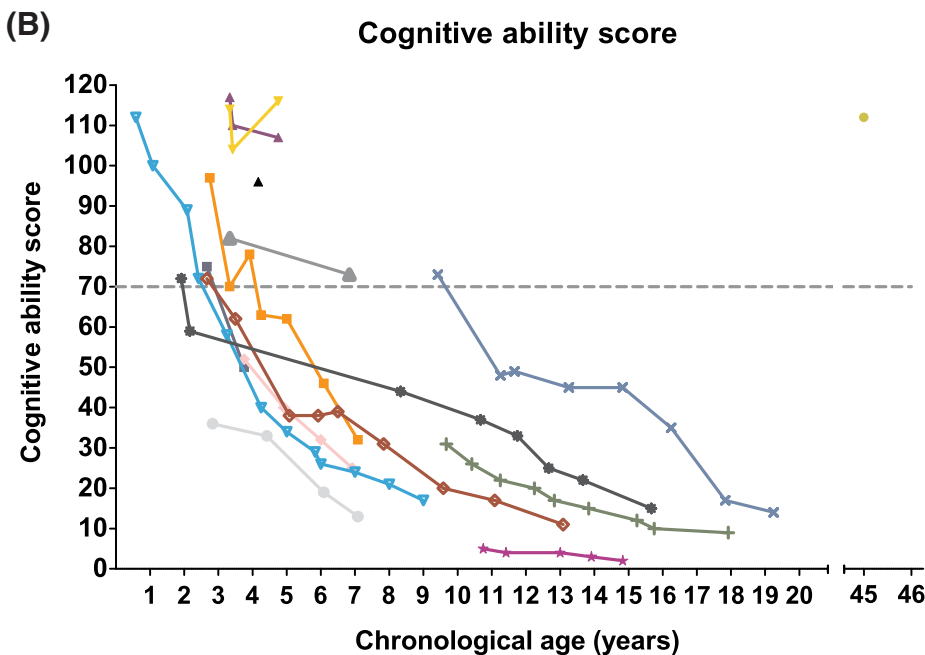


FIGURE 2 Neuropsychological follow-up. The numbers in the legends correspond to the patient numbers shown in Table 1. A, Mental age as determined by the Griffiths mental-developmental scales; this graph does not include neuropsychological tests other than the Griffiths mental-developmental scales. B, Cognitive ability scores (CAS) determined by all neuropsychological tests used; for convenience reasons, the term CAS was used for the outcome of all standardized tests evaluating cognitive skills; no neuropsychological data was available for patients 15, 16, 17, and 19



limited amount of white matter in the centrum semi-ovalis suggested atrophy while in the other patient a callosal angle could not be measured at the age of 86, 98, and 109 months, but was over 90° at the age of 104 and 124 months compatible with atrophy. Only one patient (patient 5) had signs of a hydrocephalus with an Evans' Index exceeding 0.3 in three MRIs while the callosal angle measured < 90°. Overall this indicates that the atrophy as measured by the atrophy score was indeed

atrophy and not widening of the lateral ventricles due to hydrocephalus.

3.4 | Combined CAS and MRI results

We studied the development of atrophy, white matter abnormality and VRS over time to investigate if any of these MRI characteristics was correlated to the development of CAS over time. To visualize this Figure 4A-C

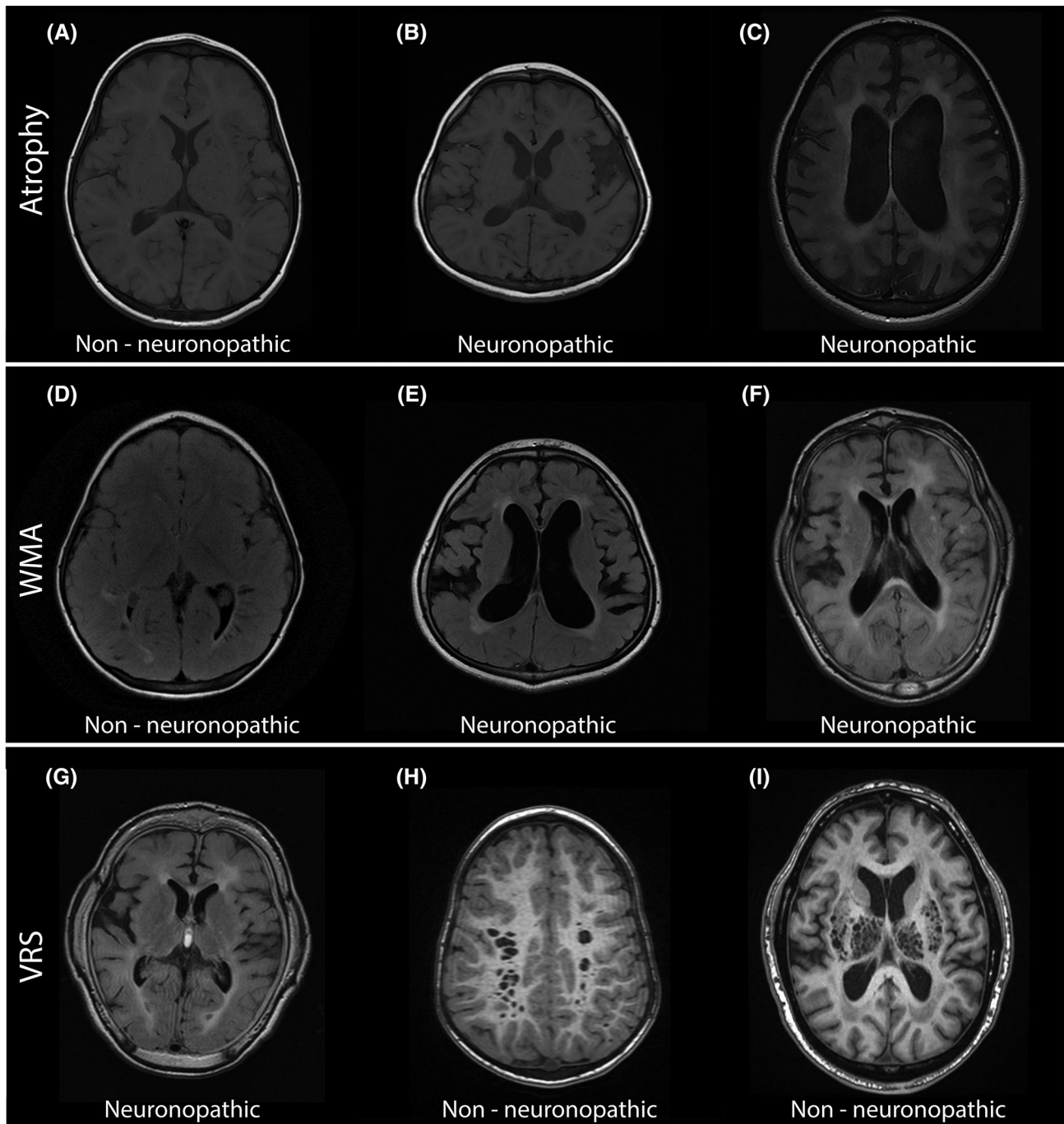


FIGURE 3 Magnetic resonance images of MPS II patients. Examples of MRI images ordered from mild (left) to severe (right). A-C show atrophy, D-F show white-matter abnormalities (WMA), and G-I show Virchow-Robin spaces (VRS). A, T1 image of a non-neuronopathic patient at 2.3 years; B, T1 image of a neuronopathic patient at 4.2 years; C, T1 image of a neuronopathic patient at 14.2 years; D, T2-FLAIR image of a non-neuronopathic patient at 4.1 years; E, T2-FLAIR image of a neuronopathic patient at 7.2 years; F, T2-FLAIR image of a neuronopathic patient at 8.0 years; G, T2-FLAIR image of a neuronopathic patient at the age of 10.2 years; H, processed image of a non-neuronopathic patient at 4.1 years; I, processed image of a non-neuronopathic patient at 46.9 years

show 3D charts, which combine information on the following three variables: chronological age (*x*-axis); CAS (*y*-axis); and the MRI sumscores (bubble size) for brain atrophy (Figure 4A), for white-matter abnormalities (Figure 4B), and in Virchow-Robin spaces (Figure 4C).

The larger the bubble, the more abnormal the MRI sumscore. MRI and CAS were obtained at approximately the same time, with a median time difference between MRI scan and neuropsychological testing of 3.1 months (SD of time difference = 2.4 months). Abnormal atrophy

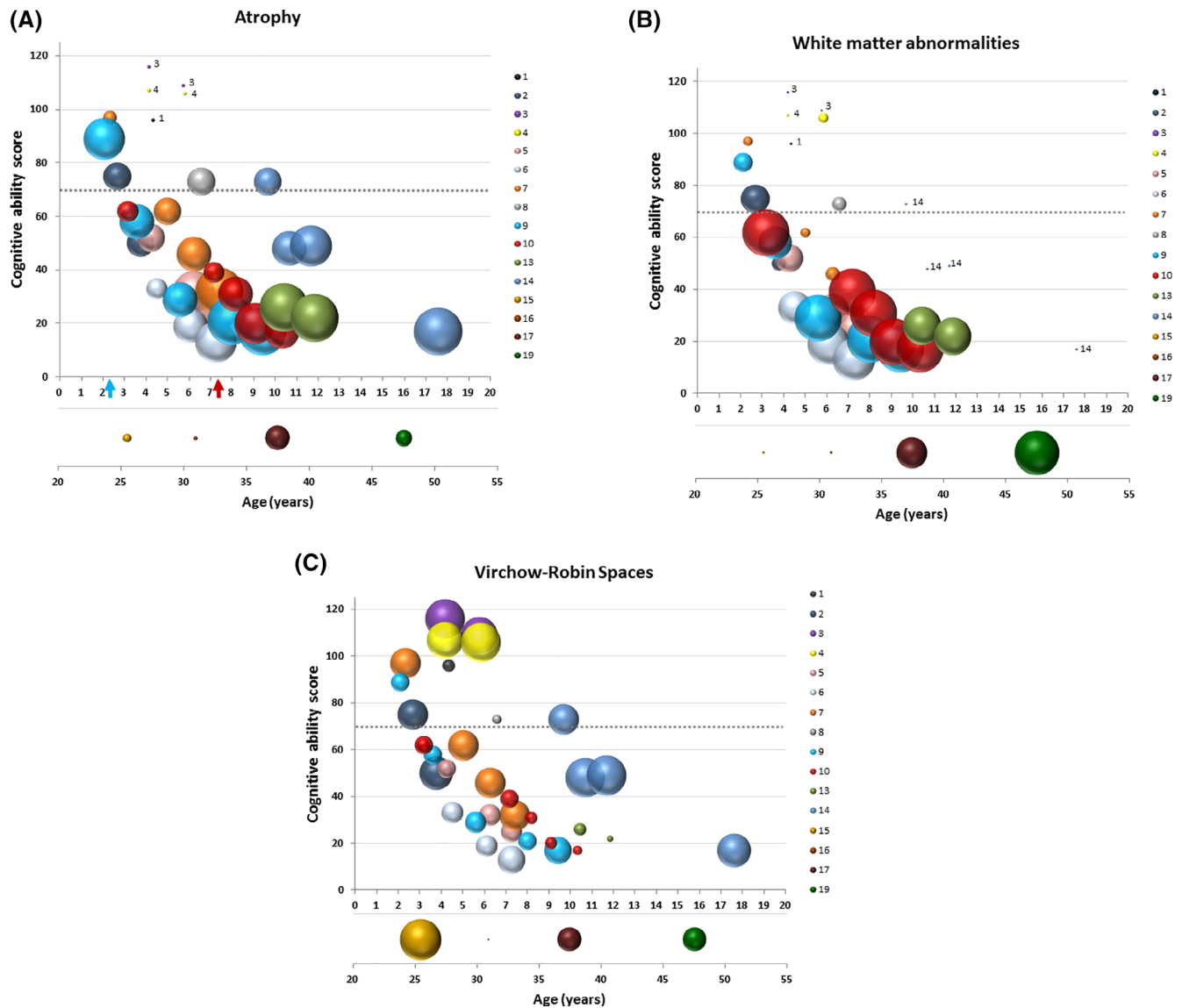


FIGURE 4 3D charts with combine information of the repeated measurements of cognitive ability scores, and MRI sumscores in individual patients. Each 3D chart combines the data derived from age- and patient-specific Cognitive ability scores (CAS) and MRI results showing three variables: chronological age (*x*-axis); CAS (*y*-axis); and the MRI sumscores (bubble size). The size of the bubbles represents the level of the MRI sumscores for brain atrophy (Figure 4A), for white-matter abnormalities (Figure 4B), and in Virchow-Robin spaces (Figure 4C). The larger the bubble, the more abnormal the MRI sumscore. Since no combined CAS and MRI sumscores were available for patients 15, 16, 17, and 19, the combined data of chronological age (*x*-axis) and the MRI sumscores (bubble size) are presented in charts below the *x*-axis of Figure 4A-C. No MRIs were available for patients 11, 12, and 18. MRI and CAS were obtained at approximately the same time, with a median time difference between MRI scan and neuropsychological testing of 3.1 months (SD of time difference = 2.4 months). A, 3D chart of the sumscore for cerebral atrophy. The size of a bubble reflects the MRI sumscores, ranging from 0 (smallest bubble) to 7 (largest bubble). The arrows indicate the age at ventriculoperitoneal (VP) shunt placement of patients 9 (blue) and 10 (red). B, 3D chart of white-matter abnormalities. The size of the bubble reflects the MRI sumscores, ranging from 0 (smallest bubble) to 10 (largest bubble). C, 3D chart of the sumscore of Virchow-Robin spaces. The size of the bubble reflects the MRI sumscores, ranging from 0 (smallest bubble) to 10 (largest bubble). No patient had a VRS sumscore above 14

sumscores were observed before CAS dropped below the threshold for intellectual disability (<70). When we studied CAS and atrophy score at the first MRI we found that 4 patients (5, 6, 10, 13) already had a CAS <70 at first MRI. 8 patients had a CAS >70 at their first MRI. Of these 4 patients (2, 8, 9, 14) had a high atrophy score (>3)

and an Evans' Index >0.3 (average age 5.5 years, range age 2.1 to 9.7 years). In 3 of these patients (2, 9, 14) the CAS declined thereafter, whereas CAS was just above the threshold for patient 8 (73). In the other 4 patients the atrophy score was <3 and the Evans' Index normal (<0.3). The CAS of 3 of these patients (1, 3, and 4)

remained normal. In the last patient (7) the CAS declined parallel to an increase of both the atrophy score and the Evans' Index in the subsequent MRIs. Notably in 2 of the 4 adult non-neuronopathic patients (patient 17 and 19) the Evans' Index was elevated with a callosal angle $> 90^\circ$ while the atrophy scores were 3 and 2 respectively, potentially indicating atrophy. The other patients did not show signs of atrophy on their MRIs.

At group level, the MRI sumscores for atrophy is strongly correlated with CAS (correlation = -0.90), indicating that brain atrophy is an early sign for the neuronopathic phenotype. WMA sumscores also progressed over time (Figure 3B), and although they were also correlated with CAS at group level (correlation = -0.69), this correlation was not as strong as for atrophy. This indicates that white-matter abnormalities alone do not serve as an early indicator for the neuronopathic phenotype. This is illustrated by the difference between patient 14 (one of the neuronopathic patients), who showed no white-matter lesions at the age of 17 years (Figure 4B), while some adult non-neuronopathic patients clearly showed white-matter lesions (Figure 4B).

Irrespective of CAS, Virchow-Robin spaces were seen in neuronopathic and non-neuronopathic patients alike (Figure 4C), and, at group level, did not seem to progress over time. As a consequence, the wide range of MRI sumscores and the lack of change meant that no statistically significant model could be fitted, and no correlation could be calculated between VRS sumscores and CAS.

In other words, VRS were not an indicator for the neuronopathic phenotype, but brain atrophy is an important early sign for the neuronopathic phenotype, especially when observed jointly with white-matter abnormalities.

4 | DISCUSSION

For this analysis of prospectively obtained, longitudinal data, we quantified brain atrophy, white-matter abnormalities, and the number and size of Virchow-Robin spaces, and related them to CAS. Our results are based on the data of neuronopathic and non-neuronopathic patients of all ages who had undergone a large number of assessments (47 MRIs and 78 neuropsychological tests) over a maximum time span of 13.3 years. The large amount of young patients partly fills the knowledge gap in literature. This enabled us to study the relationship between neuropsychological development and early MRI changes. Our findings provided insight into early neuropsychological development and early cerebral MRI changes. These MRI findings can be used to improve the identification of the neuronopathic phenotype and for accelerating early detection. The inclusion of both

children and adults with the neuronopathic and non-neuronopathic forms helped us to discern which MRI changes are most relevant over time.

4.1 | Cognitive ability scores

At the chronological age of 4 to 4.5 years, cognitive development in neuronopathic MPS II patients has been reported to diverge from that in their peers.^{3,7,8} While the current literature contains little data on young MPS II patients, the relatively large amount of data in young MPS II patients we present reveals a greater variation in the (a) initiation and/or (b) duration of the plateauing phase than previously reported. At ages between 3 and 10 years, the CAS of neuronopathic patients in our cohort dropped below the threshold of 70.

This greater variation is particularly illustrated by two patients in our cohort. Based on a CAS of 73, the first, patient 8, was classified as non-neuronopathic at the age of 7 years. Unlike the other non-neuronopathic patients, he declined 9 points in the last 3.5 years and is now expected to decline even further. As a result, he will cross the threshold for intellectual disability in the near future. Based on a CAS of 14, the second patient, patient 14, was classified as neuronopathic at the age of 19. Unlike the other neuronopathic patients, he still had a CAS above 70 at the age of 9 years. This was followed by a strong decline in CAS over consecutive years, leading to a CAS of 14 at study endpoint.

The wide variations in (a) the duration of the mental age plateauing phase, and (b) the variations in CAS decline, indicated that the classification of MPS II patients may need to be revised. Either the disease spectrum is a continuum rather than a dichotomy, or an intermediate group should be defined. Our youngest non-neuronopathic patients, who were aged 5 to 6 years (IQ 96-116), performed notably better than their neuronopathic peers—although, in view of the relatively short follow-up, future neurocognitive decline cannot be ruled out. This indicates the importance of longitudinal neurocognitive follow-up and the inclusion of other markers besides CAS that may predict the neuronopathic phenotype. The marker we used in our study was MRI.

4.2 | MRI

Our findings indicate that atrophy and white-matter changes are important hallmarks of the neuronopathic phenotype. This is in agreement with earlier studies.^{2,6,9,10,13,18} We developed a scoring system based on

findings in earlier studies. Using this system we calculated sumscores. It should be noted that high MRI atrophy sumscores—which, we assume, reflect a reduced amount of brain tissue—can be biased by the presence of hydrocephalus, a common co-morbidity in MPS II. Although all patients with an atrophy sumscore of 3 or more also had wide fissures and sulci, making a hydrocephalus less likely at that stage, it remains difficult to discriminate between atrophy and hydrocephalus. Therefore we assessed the Evans' Index as well as the callosal angle. An Evans' Index > 0.3 combined with a callosal angle $> 90^\circ$ indicates atrophy; an Evans' Index > 0.3 combined with a callosal angle $< 90^\circ$ corresponds to hydrocephalus.¹⁶ In this way we found that we indeed measured atrophy. The atrophy sumscore had the strongest correlation with CAS and, importantly, at no point did our neuronopathic patients have normal atrophy sumscores (sumscore 0). Two non-neuronopathic patients showed atrophy; patient 8 whose CAS decreased below 70 after the study termination and one of the oldest patients (16) at the age of 37 years. Importantly the atrophyscores of young neuronopathic patients generally were higher than the atrophy scores of young and old non-neuronopathic patients, even at CAS > 70 . On the basis of our results we can conclude that a high atrophy sumscore in young MPS II patients is a sign that the development of a neuropathic phenotype is emerging.

Various studies have concluded that neuronopathic patients presented with more severe WMA than non-neuronopathic patients.^{2,9,10,13,18} Our study is only in partial agreement with this. Although, in our study, the progressive severity of WMA was also correlated to a decline in CAS, this correlation was not as strong as for atrophy. At the age of 46, for example, patient 19, a non-neuronopathic patient, had extensive WMA but minimal atrophy. In contrast, patient 14, a neuronopathic patient, showed progressive atrophy, but no WMA were observed during the full 10 years of follow-up. Our study shows that also adult patients with relatively normal function in society may show considerable WMA.

While we therefore conclude that atrophy may occur without WMA, and that WMA are not inevitably related to the development of severe intellectual disability, this does not mean that MRI abnormalities such as WMA do not cause subtle neurocognitive deficits.⁴ A study by Zalfa et al identified three stages of WMA progression in MPS II patients: neuro-inflammation, followed by glial degeneration and eventually neuronal degeneration.¹⁹ Although it has also been shown that abnormalities in the brain at the cellular level may already occur during fetal life,^{20,21} it is unclear whether they result in WMA, and at which stage the sequence of events described above eventually produces WMA visible on MRI.

VRS occurred in both neuronopathic and non-neuronopathic patients as well, this is in agreement with earlier studies in MPS II as well as in other MPS subtypes.^{12,14} For example VRS occur in MPS VI patients, patients without intellectual disability.²² It should be noted that VRS surround the walls of vessels as a “sleeve” connected to the subarachnoid space, and that their anatomical location is outside the blood-brain barrier.²³ Although ERT did not seem to dissolve the VRS during the study period for our cohort, it is still unclear whether the stabilization in the size and number of VRS can be attributed to ERT treatment.

The protocol we used for our structural analysis of cerebral MRIs was a qualitative method derived from four protocols previously described.^{2,12-14} Lee et al, were the first to demonstrate that a standardized MRI scoring system could be useful to compare individuals with MPS. Manara et al and Seto et al then showed that it was also useful for objectifying individual MRI changes in serial MRIs. In our study, we additionally calculated sumscores for atrophy, WMA and VRS in order to correlate them with the change in CAS at group level. In the near future, it may be relevant to compare or combine our approach with the computerized method published by Yund et al for quantifying corpus callosum, gray-matter and white-matter volumes in non-neuronopathic patients. Volumetry has the advantage of being quantitative. A limitation of our study is that we use a semi-quantitative method which may be sensitive to bias. However the implementation of volumetry would require further investigation; as Yund et al indicated that VRS interfere with volume quantification, the presence of VRS might be a potential pitfall of using a computerized method alone.

The inclusion of both children and adults with neuronopathic and non-neuronopathic forms, enabled us to learn that VRS were not an indicator for the neuronopathic phenotype. WMA were correlated to a decline in CAS, but were observed in both neuronopathic and non-neuronopathic patients, adults and children. As abnormal atrophy sumscores were present before CAS dropped below the threshold for intellectual disability, and as the progressive atrophy was strongly related to a decline in CAS, we conclude that brain atrophy is an important early sign for the neuronopathic phenotype, especially when observed jointly with white-matter abnormalities, and therefore can be used for early identification of the neuronopathic phenotype.

ACKNOWLEDGMENTS

We thank all Dutch MPS II patients and their families for their cooperation, Dr. E. Oussoren for her structural clinical follow-up of the patients, Wilma Mouthaan for her planning of neuropsychological testing, David Alexander

for critically reading the manuscript, and Priya Doerga for providing reference MRIs for training purposes. Research on MPS at Erasmus MC is financially supported by the European Community's Seventh Framework Programme (FP7/2007-2013)—MeuSIX [304999] and by the Stichting Zeldzame Ziekten Fonds/WE Foundation, grant number 1415151.

CONFLICT OF INTEREST

B. J. E. has received a fee for speaking at a consensus meeting for MPS II. These consultations are arranged via agreements with Erasmus MC and the company. B. J. E., A. A. M. V., D. R., M. H. L., F. K. A., and I. P. reports no disclosures. E. G. S. has participated in scientific advisory boards of ReGenXBio, Armagen, Shire, SOBI, Biomarin, Eloxx, Sanofi Genzyme, JCR Pharmaceuticals, Orchard Therapeutics, United Multiple Sulfatase Deficiency Foundation, and Phoenix Nest. Travel and/or speaking honoraria has been provided by Shire, Biomarin, Sanofi Genzyme, JCR Pharmaceuticals, ReGenX, US National MPS Society, UK MPS Society, Orchard Therapeutics, and Chiesi Farmaceutici. Consultancies were provided for ReGenXBio, Armagen, Shire, SOBI, Biomarin, Eloxx, Alexion, Chiesi, BluebirdBio, Sangamo, Aeglea, Lyso-gene, Orchard Therapeutics, JCR Therapeutics, Denali Therapeutics, and Sanofi Genzyme. A. T. v. d. P. has provided consultancy services for Amicus, Sanofi-Genzyme, Spark Therapeutics, Ultragenyx, Sarepta, Dynacure and Biomarin. These consultations are arranged via agreements with Erasmus MC and the company. A. T. v. d. P. has no personal interests. J. M. P. v. d. H. has provided consultancy services for Chiesi, Sanofi, Shire and Armagen. These consultations are arranged via agreements with Erasmus MC and the company. J. M. P. v. d. H. has no personal interests.

All procedures followed were in accordance with the ethical standards of the responsible committee on human experimentation (institutional and national) and with the Helsinki Declaration of 1975, as revised in 2000 (5). Informed consent was obtained from all patients for being included in the study.

AUTHOR CONTRIBUTIONS

Audrey A. M. Vollebregt conceptualized and designed the study, and also aggregated the patients' clinical characteristics. She analyzed the brain MRIs, analyzed and interpreted the data, designed the tables and figures, drafted the initial manuscript, revised the manuscript for important intellectual content, and gave final approval for the version to be published. Berendine J. Ebbink performed the patients' neuropsychological tests, analyzed and interpreted the neuropsychological data, revised the manuscript for important intellectual content, and gave

final approval for the version to be published. Dimitris Rizopoulos conducted the statistical analysis and analyzed and interpreted the data. He also gave final approval for the version to be published. Maarten H. Lequin trained Audrey A. M. Vollebregt and Johanna M. P. van den Hout, revised the manuscript for important intellectual content, and gave final approval for the version to be published. Femke K. Aarsen performed the patients' neuropsychological tests, analyzed and interpreted the data, revised the manuscript for important intellectual content, and gave final approval for the version to be published. Elsa G. Shapiro analyzed and interpreted the data, revised the manuscript for important intellectual content, and gave final approval for the version to be published. Ans T. van der Ploeg conceptualized and designed the study, analyzed and interpreted the data, revised the manuscript for important intellectual content, and gave final approval for the version to be published. Johanna M. P. van den Hout is the guarantor and corresponding author, she analyzed the brain MRIs, analyzed and interpreted the data, revised the manuscript for important intellectual content, and gave final approval for the version to be published.

ETHICS APPROVAL

The study protocol was approved by the Medical Ethical Committee at Erasmus MC.

PATIENT CONSENT

For all patients written informed consent was obtained from patients and/or their legal guardians.

INFORMED CONSENT

This article does not contain any studies with human or animal subjects performed by the any of the authors.

ORCID

Audrey A. M. Vollebregt  <https://orcid.org/0000-0001-5604-916X>

Johanna M. P. van den Hout  <https://orcid.org/0000-0001-8091-263X>

REFERENCES

1. Neufeld E, Muenzer E. The mucopolysaccharidoses. In: Scriver CR, Beaudet AL, Sly W, Valle D, eds. *The Metabolic & Molecular Bases of Inherited Disease*. New York: McGraw-Hill; 2001.
2. Manara R, Priante E, Grimaldi M, et al. Brain and spine MRI features of Hunter disease: frequency, natural evolution and response to therapy. *J Inherit Metab Dis*. 2011;34: 763-780.
3. Young ID, Harper PS, Archer IM, Newcombe RG. A clinical and genetic study of Hunter's syndrome. 1. Heterogeneity. *J Med Genet*. 1982;19:401-407.

4. Yund B, Rudser K, Ahmed A, et al. Cognitive, medical, and neuroimaging characteristics of attenuated mucopolysaccharidosis type II. *Mol Genet Metab.* 2015;114:170-177.
5. Begley DJ, Pontikis CC, Scarpa M. Lysosomal storage diseases and the blood-brain barrier. *Curr Pharm Des.* 2008;14:1566-1580.
6. Fan Z, Styner M, Muenzer J, Poe M, Escolar M. Correlation of automated volumetric analysis of brain MR imaging with cognitive impairment in a natural history study of mucopolysaccharidosis II. *AJNR Am J Neuroradiol.* 2010;31:1319-1323.
7. Holt J, Poe MD, Escolar ML. Early clinical markers of central nervous system involvement in mucopolysaccharidosis type II. *J Pediatr.* 2011a;159(320-326):e322.
8. Holt JB, Poe MD, Escolar ML. Natural progression of neurological disease in mucopolysaccharidosis type II. *Pediatrics.* 2011b;127:e1258-e1265.
9. Vedolin L, Schwartz IV, Komlos M, et al. Brain MRI in mucopolysaccharidosis: effect of aging and correlation with biochemical findings. *Neurology.* 2007a;69:917-924.
10. Vedolin L, Schwartz IV, Komlos M, et al. Correlation of MR imaging and MR spectroscopy findings with cognitive impairment in mucopolysaccharidosis II. *AJNR Am J Neuroradiol.* 2007b;28:1029-1033.
11. Vollebregt AAM, Hoogeveen-Westerveld M, Kroos MA, et al. Genotype-phenotype relationship in mucopolysaccharidosis II: predictive power of IDS variants for the neuronopathic phenotype. *Dev Med Child Neurol.* 2017;59:1063-1070.
12. Lee C, Dineen TE, Brack M, Kirsch JE, Runge VM. The mucopolysaccharidoses: characterization by cranial MR imaging. *AJNR Am J Neuroradiol.* 1993;14:1285-1292.
13. Matheus MG, Castillo M, Smith JK, Armao D, Towle D, Muenzer J. Brain MRI findings in patients with mucopolysaccharidosis types I and II and mild clinical presentation. *Neuroradiology.* 2004;46:666-672.
14. Seto T, Kono K, Morimoto K, et al. Brain magnetic resonance imaging in 23 patients with mucopolysaccharidoses and the effect of bone marrow transplantation. *Ann Neurol.* 2001;50:79-92.
15. Sari E, Sari S, Akgun V, et al. Measures of ventricles and evans' index: from neonate to adolescent. *Pediatr Neurosurg.* 2015;50:12-17.
16. Ishii K, Kanda T, Harada A, et al. Clinical impact of the callosal angle in the diagnosis of idiopathic normal pressure hydrocephalus. *Eur Radiol.* 2008;18:2678-2683.
17. Pinheiro J, Bates D, DebRoy S, Sarkar D. nlme: linear and nonlinear mixed effects models. *Book Nlme: Linear and Nonlinear Mixed Effects Models.* R package version 3.1-131 Vienna, Austria: The R Foundation for Statistical Computing; 2017.
18. Muenzer J, Beck M, Eng CM, et al. Multidisciplinary management of Hunter syndrome. *Pediatrics.* 2009;124:e1228-e1239.
19. Zalfa C, Verpelli C, D'Avanzo F, et al. Glial degeneration with oxidative damage drives neuronal demise in MPSII disease. *Cell Death Dis.* 2016;7:e2331.
20. Hamano K, Hayashi M, Shioda K, Fukatsu R, Mizutani S. Mechanisms of neurodegeneration in mucopolysaccharidoses II and IIIB: analysis of human brain tissue. *Acta Neuropathol.* 2008;115:547-559.
21. Wiesmann UN, Spycher MA, Meier C, Liebaers I, Herschkowitz N. Prenatal mucopolysaccharidosis II (hunter): a pathogenetic study. *Pediatr Res.* 1980;14:749-756.
22. Ebbink BJ, Brands MM, van den Hout JM, et al. Long-term cognitive follow-up in children treated for Maroteaux-Lamy syndrome. *J Inherit Metab Dis.* 2016;39(2):285-292.
23. Kwee RM, Kwee TC. Virchow-Robin spaces at MR imaging. *Radiographics.* 2007;27:1071-1086.

SUPPORTING INFORMATION

Additional supporting information may be found online in the Supporting Information section at the end of this article.

How to cite this article: Vollebregt AAM, Ebbink BJ, Rizopoulos D, et al. Can serial cerebral MRIs predict the neuronopathic phenotype of MPS II? *J Inherit Metab Dis.* 2021;44:751-762. <https://doi.org/10.1002/jimd.12342>