

# Unmasking Cryptococcal Meningitis Immune Reconstitution Inflammatory Syndrome due to Granulocyte Colony-Stimulating Factor Use in a Patient with a Poorly Differentiated Germ Cell Neoplasm

Nathan C. Bahr<sup>a-c</sup> James Wallace<sup>a</sup> Anne E.P. Frosch<sup>a-c</sup>  
David R. Boulware<sup>a-c</sup>

<sup>a</sup>Department of Medicine, <sup>b</sup>Center for Infectious Diseases and Microbiology Translational Research, and <sup>c</sup>Division of Infectious Diseases and International Medicine, Department of Medicine, University of Minnesota, Minneapolis, Minn., USA

## Key Words

Cryptococcal meningitis · Immune reconstitution inflammatory syndrome · Granulocyte colony-stimulating factor · Immunosuppressed host · Chemotherapy

## Abstract

Cryptococcal meningitis immune reconstitution inflammatory syndrome (IRIS) is frequently seen in patients with HIV and less frequently in patients on immune suppressive medications for other conditions. Here, we describe the first reported case of unmasking cryptococcal IRIS due to granulocyte colony-stimulating factor used in an HIV-negative patient with chemotherapy-induced neutropenia.

© 2014 S. Karger AG, Basel

## Introduction

Cryptococcal meningitis (CM) is the most common cause of meningitis in adults in Sub-Saharan Africa [1]. Cryptococcal immune reconstitution inflammatory syndrome (IRIS) can occur in two forms. First, *paradoxical IRIS*, in which a patient previously effectively treated for cryptococcosis has a recurrence of symptoms as the immune system is restored (e.g. by

Nathan C. Bahr, MD  
Division of Infectious Disease and International Medicine  
Department of Medicine, University of Minnesota  
MMC 250, 420 Delaware Street SE, Minneapolis, MN 55455 (USA)  
E-Mail [bahrx026@umn.edu](mailto:bahrx026@umn.edu)

antiretroviral therapy in HIV-infected persons or by removal of immunosuppressive medications required for another medical condition). Second, *unmasking IRIS*, where upon restoration of immune function, a previously subclinical infection is ‘unmasked’ by a large inflammatory reaction by the now more potent immune system [2].

These syndromes are most frequently described in the setting of HIV, where paradoxical IRIS has been noted in 13–30% of patients with cryptococcosis who survive to receive HIV therapy, while unmasking IRIS has been described less frequently, in 0.4–1.7% of CM cases [3]. Cryptococcal IRIS has also been described as both unmasking and paradoxical IRIS in persons without HIV, due to withdrawal of immunosuppressive medications either in transplant recipients or conditions such as myasthenia gravis requiring immunosuppressive treatments [4, 5]. Here, we describe the first reported case, to our knowledge, of unmasking IRIS due to treatment of chemotherapy-induced neutropenia with filgrastim (Neupogen®), a granulocyte colony-stimulating factor (G-CSF) analog.

### Case Report

A 56-year-old male visited his primary care physician to be evaluated for abdominal pain, and the subsequent workup revealed a large retroperitoneal mass measuring 21.8 × 17.5 × 11 cm. A diagnostic workup revealed a poorly differentiated germ cell neoplasm, most likely an embryonal carcinoma. Two months after his initial presentation he began chemotherapy (bleomycin, etoposide and cisplatin). By day 10 of cycle 3 (approximately 4 months after initial presentation), imaging showed a drastic decrease in tumor size.

Six days after his most recent dose of chemotherapy, he presented to the emergency department noting intermittent fatigue, nausea, vomiting and diarrhea since his last chemotherapy treatment. He also noted headache and fever over the past day. In the emergency department (hospital day 0), he was found to be neutropenic with a total white blood cell (WBC) count of  $0.6 \times 10^9$  cells/l and an absolute neutrophil count (ANC) of  $0.4 \times 10^9$  cells/l. He appeared to be in no acute distress but febrile with a temperature of 38.7°C. No obvious signs of an infectious source were noted, including examination of his port-a-cath. The patient was started on cefepime and admitted to the inpatient oncology service for treatment of neutropenic fever.

The admitting physician noted tachycardia, but the patient’s blood pressure was within normal limits. The only possible localizing sign of infection was a questionable cellulitis of the right lower leg. As the patient had previously been on prophylactic levofloxacin and had frequently been to infusion clinics, vancomycin was added for methicillin-resistant *Staphylococcus aureus* coverage. The patient was also started on G-CSF (480 µg/day) for neutropenia. Over the subsequent 2 days, his fever and tachycardia continued, and on hospital day 3 the patient became lethargic and confused. A chest radiograph (which showed no sign of pneumonia), blood and urine cultures and a CT scan of the head without contrast showed no acute changes. Throughout this period his ANC remained  $<1.0 \times 10^9$  cells/l.

By hospital day 4, the patient was unable to respond to commands and was transferred to our institution for further care; his WBC count had risen to  $1.8 \times 10^9$  cells/l (ANC not measured) and he remained febrile. His vancomycin was continued while cefepime was changed to ceftazidime out of concern for cefepime-induced encephalopathy [6]; G-CSF was continued. Shortly after arrival, the patient had 2 tonic clonic seizures, and lorazepam and fosphenytoin were given. He became more lethargic, with periods of apnea, and was transferred to the intensive care unit for endotracheal intubation. An MRI of the brain and MRA of the brain and neck with and without contrast showed an acute punctate infarct in

the right hippocampus and no major vascular findings. Continuous EEG monitoring was started. His WBC count shortly after intubation was  $11.4 \times 10^9$  cells/l with an ANC of  $7.0 \times 10^9$  cells/l. Fig. 1 shows ANC, WBC count, G-CSF dosing and the patient's symptoms over time.

A lumbar puncture was performed on hospital day 5 and revealed 64 WBC/ $\mu$ l, 30% neutrophils, 39% lymphocytes, glucose 37 mg/dl and protein 99 mg/dl. No organisms were seen on Gram staining. No cerebrospinal fluid opening pressure was measured. A thorough cerebrospinal fluid workup for infection was sent for evaluation, and empiric acyclovir was started. Cerebrospinal fluid India ink stain was completed in the early evening of hospital day 5 and showed rare encapsulated yeast, and the cerebrospinal fluid cryptococcal antigen (Latex Agglutination, IMMY, Inc., Norman, Okla., USA) was positive at a dilution of 1:32.

The infectious disease service was informed of the result, amphotericin B lipid complex was started at a dose of 5 mg/kg, and flucytosine 100 mg/kg/day was also ordered but was not but available until hospital day 7. On hospital day 6, the WBC count rose to  $28.0 \times 10^9$  cells/l and G-CSF, acyclovir, ceftazidime and vancomycin were stopped.

Throughout hospital days 6 and 7, the patient was minimally responsive despite no sedation since intubation; however, he did withdraw from painful stimuli. No additional seizures occurred. On hospital day 8, the patient moved his lower extremities on command, and his neurological function rapidly improved. Repeat lumbar puncture was performed on hospital day 9 with an opening pressure of 16 cm H<sub>2</sub>O. By hospital day 10, the patient's neurologic status had improved, and he was extubated. His culture showed *Cryptococcus neoformans* resistant to flucytosine, and so flucytosine was replaced with fluconazole 800 mg daily.

After 14 days total of amphotericin-based combination therapy, the patient continued on fluconazole 800 mg daily consolidation monotherapy. Repeat lumbar puncture at the time of stopping amphotericin showed a decreased cryptococcal antigen titer of 1:4 and an opening pressure of 22 cm H<sub>2</sub>O. On hospital day 21, the patient was discharged to a transitional care unit. Since hospital discharge, the patient has continued to do well in terms of his CM, although he has required hospitalization for pericarditis. He is being maintained on fluconazole 200 mg daily for secondary prophylaxis, and further chemotherapy has been postponed pending improvement of his other health issues.

## Discussion

We describe the first reported case, to our knowledge, of unmasking IRIS due to filgrastim, a G-CSF analog. Cryptococcal IRIS, both paradoxical and unmasking, has been described most frequently in patients with HIV. Less often cases have been described in patients without HIV but with other conditions that require immune suppressive therapy. In these non-HIV cases, patients who require lessening of their immune suppressive medication (e.g. tacrolimus, mycophenolate, corticosteroids and cyclosporine) can subsequently develop IRIS [4, 5].

Interestingly, a patient given alemtuzumab (Campath®) as treatment for T cell prolymphocytic leukemia was described as having paradoxical cryptococcal IRIS [7]. This patient developed CM while lymphopenic and neutropenic due to alemtuzumab, was treated and improved but later developed recurrent meningitis symptoms without culture-positive infection, thereby representing paradoxical IRIS. IRIS in this case was attributed to the waning effect of alemtuzumab allowing for immune reconstitution. Alemtuzumab frequently causes decreases in all cell lines but is most commonly seen to cause lymphopenia, in

particular, depletion of T lymphocytes [7], making the patient's immune system similar to that of a person with advanced HIV.

Our patient had a rapid increase of WBCs, primarily neutrophils, after G-CSF administration. CM-IRIS has not, to our knowledge, been previously described in this setting. Interestingly, autoantibodies to granulocyte-macrophage CSF (GM-CSF) were recently identified in cryptococcal patients without HIV, potentially implicating the clinical importance of GM-CSF in the immune response to protection from *Cryptococcus* [8].

Although CSFs, such as G-CSF and GM-CSF, are well known to increase bone marrow production of neutrophils and monocytes, these CSFs also have direct immunomodulatory properties. Chiller et al. [9] demonstrated enhanced killing of *Cryptococcus* when G-CSF or GM-CSF was added in vitro to neutrophils, monocytes or monocyte-derived macrophages with or without azole antifungals, suggesting that G-CSF and GM-CSF do, in fact, stimulate existing innate cells to phagocytize and kill *Cryptococcus*. Additionally, HIV-infected persons with CM who go on to develop cryptococcal IRIS have a relative paucity of G-CSF and GM-CSF prior to initiation of HIV therapy as compared to those who do not go on to develop IRIS [10]. We hypothesize that our patient's leukopenia-induced anergy was reversed due to G-CSF administration, which resulted in an unmasking IRIS event with an exaggerated immune response and rapid, profound clinical deterioration in the setting of minimal infectious burden (i.e. cryptococcal antigen titer 1:32).

In summary, we describe the first case, to our knowledge, of unmasking CM-IRIS due to G-CSF administration for neutropenia. This is a potentially life-threatening side effect of CSF therapy that clinicians should consider in patients presenting with signs of meningitis or altered mental status.

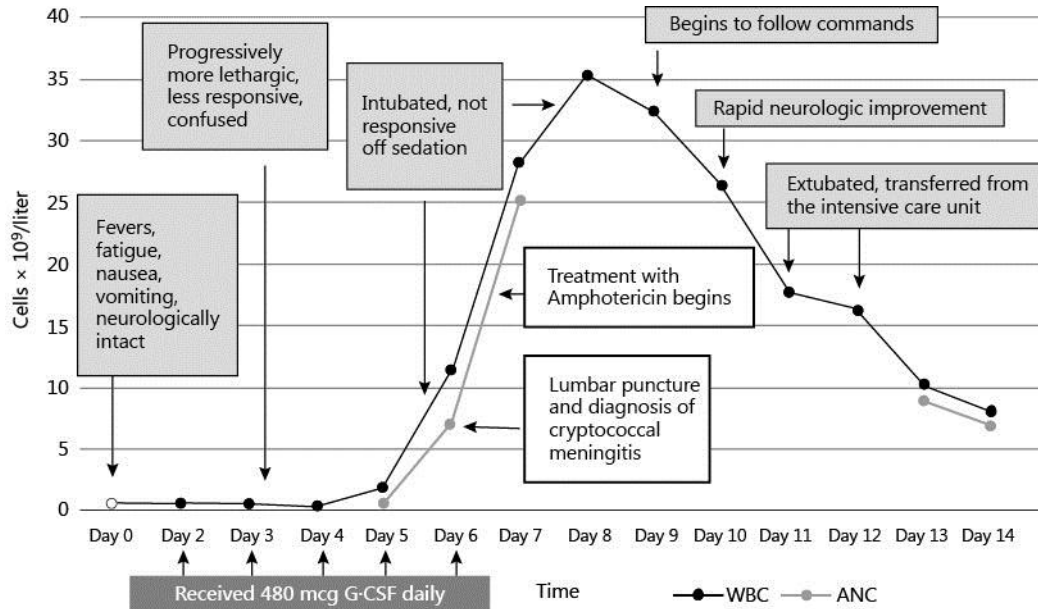
### Disclosure Statement

This work was supported by the National Institute of Allergy and Infectious Diseases and Fogarty International Center at the National Institutes of Health (K23AI073192, U01AI089244, R25TW009345).

### References

- 1 Jarvis JN, Meintjes G, Williams A, Brown Y, Crede T, Harrison TS: Adult meningitis in a setting of high HIV and TB prevalence: findings from 4961 suspected cases. *BMC Infect Dis* 2010;10:67.
- 2 Haddow LJ, Colebunders R, Meintjes G, et al: Cryptococcal immune reconstitution syndrome in HIV-1 infected individuals: proposed clinical case definitions. *Lancet Infect Dis* 2010;10:791–802.
- 3 Bahr N, Boulware DR, Marais S, et al: Central nervous system immune reconstitution inflammatory syndrome. *Curr Infect Dis Rep* 2013;15:583–593.
- 4 Narayanan S, Banerjee C, Holt PA: Cryptococcal immune reconstitution syndrome during steroid withdrawal treated with hydroxychloroquine. *Int J Infect Dis* 2011;15:e70–e73.
- 5 Singh NS, Lortholary O, Alexander BD, et al: An immune reconstitution syndrome-like illness associated with *Cryptococcus neoformans* infection in organ transplant recipients. *Clin Infect Dis* 2005;40:1756–1761.
- 6 Capparelli FJ, Diaz MF, Hlavnika A, et al: Cefepime and cefixime-induced encephalopathy in a patient with normal renal function. *Neurology* 2005;65:1840.
- 7 Ingram PR, Howman R, Leahy MF, Dyer JR: Cryptococcal immune reconstitution inflammatory syndrome following alemtuzumab therapy. *Clin Infect Dis* 2007;44:e115–e117.
- 8 Rosen LB, Freeman AF, Yang LM, et al: Anti-GM-CSF autoantibodies in patients with cryptococcal meningitis. *J Immunol* 2013;190:3959–3966.
- 9 Chiller T, Farrokhsad K, Brummer E, Stevens DA: Effect of granulocyte colony-stimulating factor and granulocyte-macrophage colony-stimulating factor on polymorphonuclear neutrophils, monocytes or monocyte-derived macrophages combined with voriconazole against *Cryptococcus neoformans*. *Med Mycol* 2002;40:21–26.

- 10 Boulware DR, Meya DB, Bergemann TL, et al: Clinical features and serum biomarkers in HIV immune reconstitution inflammatory syndrome after cryptococcal meningitis: a prospective cohort study. *PLoS Med* 2010;7:e1000384.



**Fig. 1.** Clinical and biological response to G-CSF. WBC count, ANC, filgrastim dose and the patient's symptoms over time.