

# One-point posterior ablation for complete isolation of the posterior left atrium



Kohei Kawajiri, MD, Seiji Fukamizu, MD, PhD, Takeshi Kitamura, MD, Rintaro Hojo, MD, PhD

*From the Department of Cardiology, Tokyo Metropolitan Hiroo Hospital, Tokyo, Japan.*

## Introduction

The posterior wall of the left atrium (LA) plays an important role in the maintenance of atrial fibrillation (AF).<sup>1</sup> Box isolation in addition to pulmonary vein (PV) isolation improves the outcome of persistent AF ablation.<sup>2</sup> However, in some cases, ablation of the roof and bottom line was insufficient for posterior isolation, and ablation within the boundaries of the posterior box was required.<sup>3</sup> In addition, achieving LA posterior isolation while avoiding elevation of esophageal temperatures can be technically difficult. Recent studies have reported that linear ablation was not necessary in all cases for posterior isolation.<sup>4,5</sup> We report a rare case of recurrent AF with 1-point bottom ablation after roofline ablation leading to successful posterior isolation.

## Case report

A 72-year-old man presented to our hospital with fatigue and shortness of breath. He had a history of PV isolation for paroxysmal AF 5 years prior. A 12-lead electrocardiogram revealed recurrent AF with no signs of heart failure. We initiated anticoagulation therapy and continued outpatient follow-ups. AF persisted for 4 months with symptoms, and a redo procedure targeting recurrent persistent AF was planned.

An electrophysiological study and a radiofrequency catheter ablation procedure were performed using the CARTO 3 system (Biosense Webster, Diamond Bar, CA). A temperature probe was inserted into the esophagus to monitor the luminal esophageal temperature. Atrial fibrillation was observed at baseline. After cardioversion, LA mapping under right atrium pacing with a 20-electrode mapping catheter (PentaRay; Biosense Webster) was performed. As in our other AF cases, a voltage range of 0.05–0.5 mV was

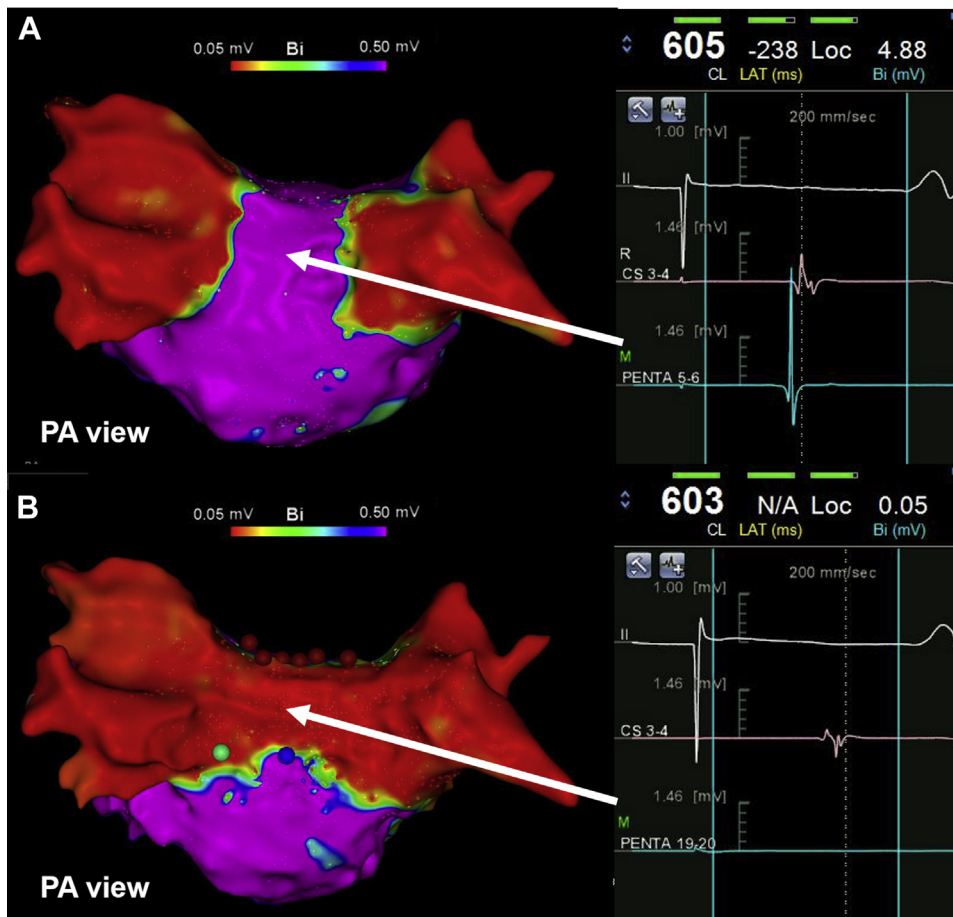
## KEY TEACHING POINTS

- Although a continuous linear ablation is considered necessary to achieve box isolation, we encountered a rare case of isolation of the posterior left atrium (LA) with 1-point bottom ablation after roofline ablation.
- Anatomical dissections in some cases have revealed posterior inferior walls with abrupt changes in the orientation of the myocardial strands. This suggests that a functional block may exist near the bottom line in select patients. In our case, these fiber orientations and the functional block near the bottom line may allow for isolation of the posterior LA with minimum bottom ablation.
- This case demonstrates the possibility of box isolation without the ablation of points near the esophagus. Furthermore, it may be possible to start LA posterior ablation from points farther from the esophagus to help minimize procedure-related complications, and linear ablation may not be necessary for all cases.

used. There was no evidence of LA-PV reconnection. Voltage mapping did not reveal any low-voltage zones along the anterior and posterior areas of the LA (Figure 1A). A box isolation for recurrent AF was planned with a PentaRay catheter that was placed on the posterior wall to monitor electrical isolation. At first, roofline ablation with a SmartTouch Surround Flow (Biosense Webster) was performed from the left to right sides. After linear ablation, the posterior potential sequence changed from a downward to upward trend, suggesting a complete roofline. Next, we started ablation of the posterior line from near the left inferior PV. However, ablation was ceased at 10 seconds owing to high esophageal temperatures (Figure 1B, green tag). We restarted ablation (25 watts) at its center to avoid esophageal injury. The posterior potential disappeared 5 seconds after we started the ablation, so we continued ablation for 30 seconds

**KEYWORDS** Atrial fibrillation; Box isolation; Catheter ablation; Voltage mapping; Esophageal injury  
(Heart Rhythm Case Reports 2020;6:738–740)

**Funding Sources:** The authors have no funding sources to disclose. **Disclosures:** The authors have no conflicts of interest to disclose. **Address reprint requests and correspondence:** Dr Kohei Kawajiri, Department of Cardiology, Tokyo Metropolitan Hiroo Hospital, 2-34-10 Ebisu, Shibuya-ku, Tokyo, Japan. E-mail address: [ability.0824@gmail.com](mailto:ability.0824@gmail.com).



**Figure 1** Voltage map of the left atrium (LA) before and after the ablation. **A:** The voltage map before the ablation did not reveal any low voltage zones at the LA posterior wall. It also revealed that there was no reconnection of the pulmonary veins. **B:** Ablation was stopped at 10 seconds at the location marked by the green tag because of high esophageal temperatures. After ablation to the location marked by the blue tag, the LA posterior wall did not have a potential, and the LA voltage map showed complete LA posterior isolation. An intracardiac electrogram acquired by a PentaRay catheter (Biosense Webster, Diamond Bar, CA) at the same location revealed that the potential of the LA posterior wall disappeared compared to before ablation. CS = coronary sinus; PA view = posterior anterior view; PENTA= PentaRay catheter.

(Figure 1B, blue tag). The voltage map confirmed posterior isolation (Figure 1B). Posterior wall capture with exit block were confirmed using the PentaRay catheter after high-dose isoproterenol provocation (Figure 2). Subsequently, we were unable to induce AF. The patient had no recurrence of AF over a 5-month follow-up period.

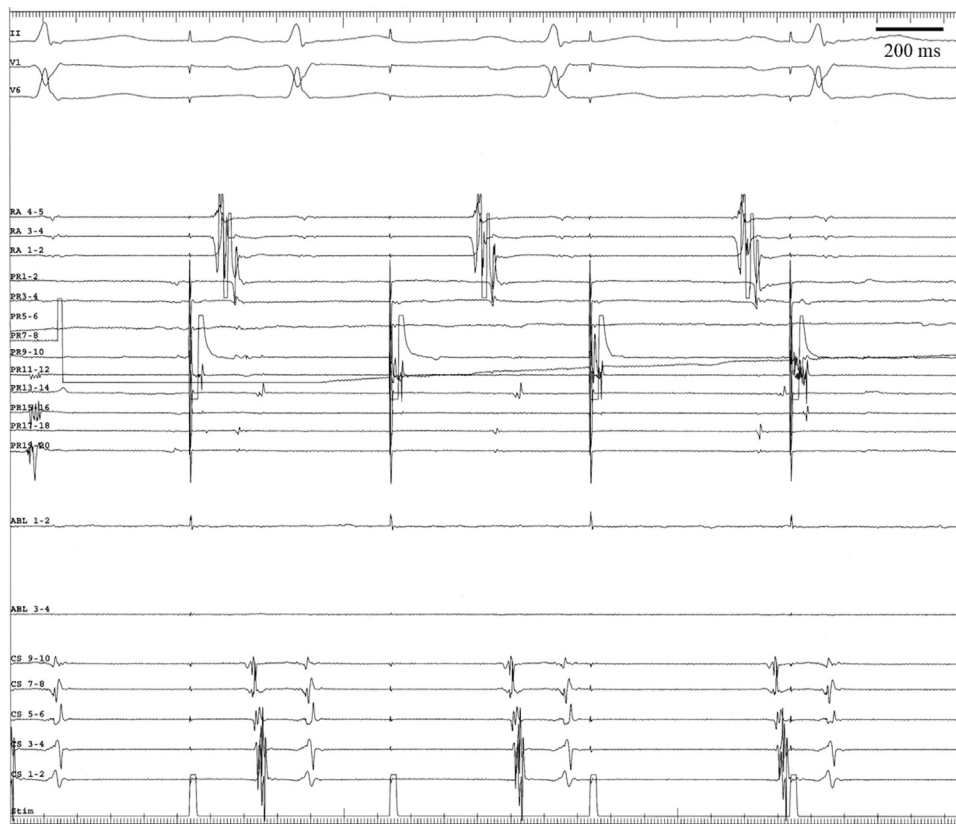
## Discussion

The LA posterior wall and PVs originate from the same cells during development, which suggests that the LA posterior wall is an arrhythmogenic structure and has a unique electrophysiological characteristic, similar to PVs.<sup>6</sup> A previous study of 16 specimens revealed that the LA posterior fiber has a common pattern in most cases.<sup>7</sup> A main circular fascicle runs peripherally around the opening areas of the PVs. Nathan and Eliakim<sup>7</sup> also reported that the posterior fiber can contain mixed variations of vertical, horizontal, oblique, and mixed patterns. Furthermore, in a study by McLellan and colleagues,<sup>8</sup> 41% of patients needed

intra-box ablation in addition to linear ablation. Therefore, an ablation procedure with only box isolation can be technically difficult.

Recent studies have suggested that linear ablation, especially bottom line ablation, may not be essential for posterior isolation. Mahajan and colleagues<sup>4</sup> reported utilizing single ring isolation for AF. In 1 case, the PV and posterior wall were isolated with minimal ablation along the bottom line. As mentioned above, posterior wall fibers have many variations. Anatomical dissections in some cases have revealed posterior inferior walls with abrupt changes in the orientation of the myocardial strands.<sup>9</sup> This suggests that a functional block may exist near the bottom line in select patients. In our case, these fiber orientations and the functional block near the bottom line may allow for isolation of the posterior LA with minimum bottom ablation.

Several limitations should be acknowledged. First, the voltage map of the posterior wall before the ablation was



**Figure 2** Pacing from the left posterior wall after posterior ablation. Pacing from the left posterior wall following high-dose isoproterenol provocation was performed because the post-voltage map suggested posterior wall isolation. Posterior wall capture with exit block was confirmed using PentaRay catheter (Biosense Webster, Diamond Bar, CA). ABL = ablation catheter; CS = coronary sinus; PR = PentaRay catheter.

of low resolution. Although 1050 total points were taken in the entire LA, the number of points on the posterior wall was slightly low. Therefore, the low voltage zone and functional block may not have been detected. Second, the location of the posterior isolation was taken because the point on the left side showed a high esophagus temperature. If we had started the ablation from the right side, we may not have achieved minimum ablation. Third, unusual activation near the LA bottom line before ablation may not have been detected. An activation map before the ablation was performed under right atrium pacing; therefore, the propagation at the posterior was mainly from the LA roof to the posterior-inferior wall. The creation of a map during coronary sinus pacing may have allowed for more precise assessments of the activation around the posterior-inferior LA.

## Conclusion

Although a continuous linear ablation is considered necessary to achieve box isolation, we encountered a rare case of isolation of the posterior LA with minimum posterior ablation. This case demonstrates the possibility of box isolation without the ablation of points near the esophagus. Furthermore, it may be possible to start LA posterior ablation from points farther from the esophagus to help minimize procedure-related complications, and linear ablation may not be necessary for all cases.

## Acknowledgments

The authors are deeply grateful to all members of Tokyo Metropolitan Hiroo Hospital who provided insightful comments and suggestions.

## References

1. Sanders P, Berenfeld O, Hocini M, et al. Spectral analysis identifies sites of high-frequency activity maintaining atrial fibrillation in humans. *Circulation* 2005;112:789–797.
2. Bai R, Biase LD, Mohanty P, et al. Proven isolation of the pulmonary vein antrum with or without left atrial posterior wall isolation in patients with persistent atrial fibrillation. *Heart Rhythm* 2016;13:132–140.
3. McLellan AJA, Prabhu S, Voskoboinik A, et al. Isolation of the posterior left atrium for patients with persistent atrial fibrillation: routine adenosine challenge for dormant posterior left atrial conduction improves long-term outcome. *Europace* 2017;19:1958–1966.
4. Mahajan R, Thiagarajah A, Lau DH, Sanders P. Single ring isolation for atrial fibrillation ablation: How to do it and avoid the esophagus. *HeartRhythm Case Rep* 2020;6:169–173.
5. Higuchi S, Sohara H, Nakamura Y, et al. Is it necessary to achieve a complete box isolation in the case of frequent esophageal temperature rises? Feasibility of shifting to a partial box isolation strategy for patients with non-paroxysmal atrial fibrillation. *J Cardiovasc Electrophysiol* 2016;27:897–904.
6. Suenari K, Chen YC, Kao YH, et al. Discrepant electrophysiological characteristics and calcium homeostasis of left atrial anterior and posterior myocytes. *Basic Res Cardiol* 2011;106:65–74.
7. Nathan H, Eliakim M. The junction between the left atrium and the pulmonary vein. *Circulation* 1966;34:412–422.
8. Thiagarajah A, Kadhim K, Lau DH, et al. Feasibility, safety and efficacy of posterior wall isolation during atrial fibrillation ablation. *Circ Arrhythm Electrophysiol* 2019;12:e007005.
9. Ho SY, Cabrera JA, Sanchez-Quintana D. Left atrial anatomy revisited. *Circ Arrhythm Electrophysiol* 2012;5:220–228.