




ORIGINAL RESEARCH

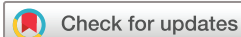Safety, patient acceptance and diagnostic accuracy of ultrasound core needle biopsy of parotid or submandibular glands in primary Sjögren's syndrome with suspected salivary gland lymphoma

Ivan Giovannini,¹ Michele Lorenzon,² Valeria Manfrè,¹ Sara Zandonella Callegher,^{1,3} Enrico Pegolo,⁴ Chiara Zuiani,² Rossano Girometti,² Alojzija Hocevar ,⁵ Christian Dejaco ,^{3,6} Luca Quartuccio,¹ Salvatore De Vita,¹ Alen Zabotti ¹

To cite: Giovannini I, Lorenzon M, Manfrè V, *et al.* Safety, patient acceptance and diagnostic accuracy of ultrasound core needle biopsy of parotid or submandibular glands in primary Sjögren's syndrome with suspected salivary gland lymphoma. *RMD Open* 2022;**8**:e001901. doi:10.1136/rmdopen-2021-001901

► Additional supplemental material is published online only. To view, please visit the journal online (<http://dx.doi.org/10.1136/rmdopen-2021-001901>).

Received 27 August 2021
Accepted 20 December 2021



© Author(s) (or their employer(s)) 2022. Re-use permitted under CC BY-NC. No commercial re-use. See rights and permissions. Published by BMJ.

For numbered affiliations see end of article.

Correspondence to

Professor Salvatore De Vita; salvatore.devita@asufc.sanita.fvg.it

ABSTRACT

Background Enlargement of the major salivary glands (SGs) is a major risk factor for B-cell lymphoma among patients with primary Sjögren's syndrome (pSS). Ultrasound-guided core needle biopsy (US-guided CNB) could be a novel technique to manage SG enlargement among patients with pSS.

Objective Accordingly, this study's main aim was to evaluate the safety, patient tolerance and diagnostic accuracy of US-guided CNB procedure for patients with pSS with major SG enlargement.

Methods Patients with clinical diagnosis of pSS and a clinical indication for SG biopsy consecutively underwent US-guided CNB between September 2019 and June 2021. These patients were evaluated clinically 1, 2 and 12 weeks after US-guided CNB. Patients were asked to complete a questionnaire about postprocedural complications as well as periprocedural pain, using the Visual Analogue Scale. Complications were categorised as *transient* (<12 weeks) or *persistent* (≥12 weeks).

Results US-guided CNB was performed on 30 major salivary glands (22 parotid glands and 8 submandibular glands). The procedure was well tolerated. Transient complications—such as haematoma, swelling—were observed among 43% of patients, and mean periprocedural pain was low. However, no persistent complications were reported during the study's follow-up period.

Conclusion US-guided CNB represents a novel approach for the management of patients with pSS with SG enlargement. The procedure showed remarkable patient safety and tolerance, allowing adequate glandular sampling and a definite diagnosis for almost all participating patients without long-term complications.

INTRODUCTION

Primary Sjögren's syndrome (pSS) is a connective tissue disease characterised by a

Key messages

What is already known about this subject?

► Salivary gland enlargement in primary Sjögren's syndrome (pSS) is a main risk of lymphoma development, whose diagnosis must be pathologically proven through histological analysis. In this scenario, ultrasound-guided core needle biopsy (US-guided CNB) has been proposed as a diagnostic tool, but evidence for its safety, tolerance and procedural standardisation remains limited.

What does this study add?

► This study provides insights into the technical aspects and anatomical issues of the US-guided CNB procedure, the safety and patients' tolerability through objective measures (ie, pain visual analogue scale).

How might this impact on clinical practice or further developments?

► US-guided CNB could be a valuable procedure for salivary gland lymphoma diagnosis in patients with pSS, and in the next future, it might obtain a growing prognostic value, empowering disease activity and tissue damage monitoring as well as shedding light on patients' response to treatment.

wide spectrum of glandular and extraglandular features.¹ The hallmark of pSS is considered to be the immune-mediated destruction of exocrine glands and B-cell hyperactivation. This condition exposes patients with pSS to an increased risk of lymphoproliferative disease,² the highest risk among various autoimmune diseases,³ usually affecting the mucosa-associated lymphoid tissue (MALT).^{4,5}

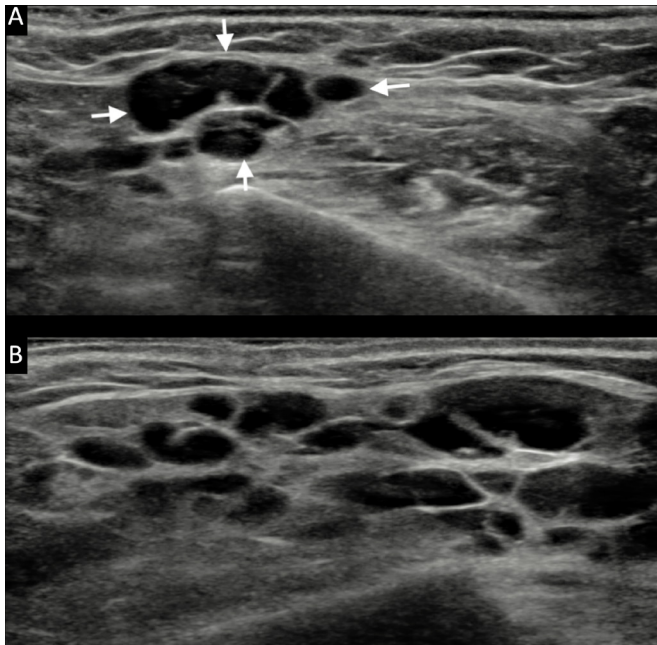


Figure 1 Sonographic images of a focal lesion (the white arrows) in the salivary gland parenchyma (A); a peculiar appearance of the salivary gland, showing confluent hypoechoic areas (B).

Persistent major salivary gland (SG) enlargement is a major clinical risk factor for B-cell lymphoma, and it may signify an established lymphoma stage, a prelymphomatous stage or even a completely different disease.^{6 7} The parotid glands are the main site of B-cell lymphoma development among patients with pSS, and biopsies of the major SGs are reserved for patients with pSS suspected of having glandular lymphoma, mainly based on SG swelling.

An ultrasonographic examination of the major SGs could assist clinicians in assessing the gland's typical structural abnormalities and detecting parenchyma lesions,^{8–10} suggesting that SG ultrasonography (SGUS) may come to be used as a stratification (scoring system) and prognostic tool.^{11–13}

The presence of a focal lesion within altered glandular parenchyma (figure 1A) or severe glandular inhomogeneity (eg, diffuse, large-confluent, hypoechoic areas; figure 1B) or both are the typical sonographic patterns of SG lymphoma among patients with pSS.^{14–16} Nevertheless, currently, lymphoma is mainly suspected among patients with pSS due to clinical characteristics, rather than imaging features, and the diagnosis of B-cell lymphoma must be pathologically proven.^{17 18}

An open surgical biopsy of the parotid gland is the recommended procedure in case of SG enlargement;^{19 20} however, the need of a skilled surgeon and the risk of potential complications limit its generalisability.^{20 21} Recently, ultrasound (US)-guided core needle biopsy (US-guided CNB) has been proposed as a diagnostic procedure for patients with pSS with suspected glandular lymphoma.^{17 22} However, evidence of this

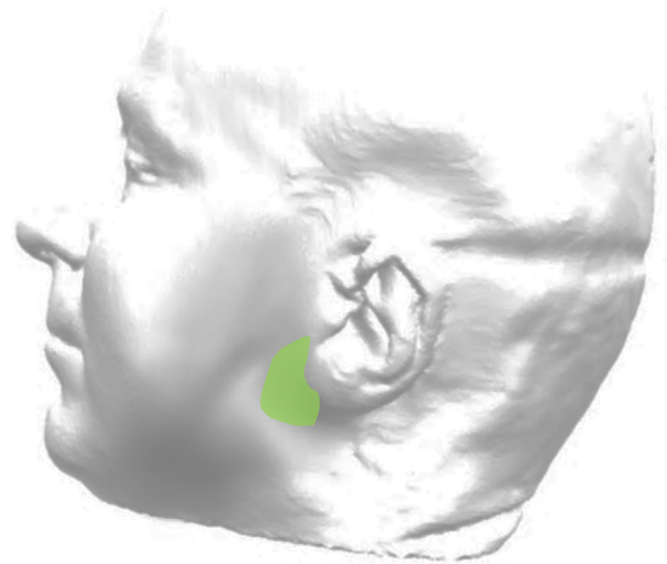


Figure 2 The 'safety area' or 'safety zone' (green area) for a parotid biopsy.

procedure's safety, patient tolerance and standardisation remains limited.²³ The most feared complication is the injury of the facial nerve, which presents a strict anatomical relation with the parotid gland. In interventional procedures on the parotid glands, a 'safety zone' or 'safety area' has been identified. This region is located between 1 cm anterior and 1 cm below the ear lobe, where the facial nerve runs in the glandular parenchyma protected by the superficial lobe of the parotid for a length of approximately 2 cm (figure 2).

To overcome these limitations, the current prospective study aimed to (1) strengthen our preliminary experience,¹⁵ (2) describe the US-guided CNB procedure in detail and (3) evaluate the procedure's safety, patient tolerance and the diagnostic accuracy for lymphoproliferative disease of US-guided CNB among a cohort of definite patients with pSS or patients suspected to have pSS with persistent parotid or submandibular gland swelling.

METHODS

Patients

Our study included consecutive patients referring to the Institute of Rheumatology, University Hospital of Udine (Italy), from September 2019 to June 2021, with a clinical diagnosis of pSS, who underwent US-guided CNB due to suspected major SG lymphoma. The suspicion of lymphoma development was clinically based on parotid and/or submandibular gland swelling, defined as either (1) chronic (>12 months), unilateral or bilateral parotid or submandibular gland swelling or (2) recurrent glandular swelling of at least 2 months of duration in one episode.^{24 25}

Written informed consent was obtained from each patient in accordance with the Declaration of Helsinki and with local guidelines for good clinical practice.²⁶

Demographic, clinical and laboratory data

Patients' clinical data were collected from their medical charts, including their age, gender, disease duration, previous unstimulated sialometry and Schirmer's tests and evidence of serum antibodies, as well as antinuclear, anti-Ro/SSA and anti-La/SSB antibodies. Furthermore, the presence of lymphoma development risk factors for patients with pSS was noted at the time of participants' biopsy procedures (glandular swelling, lymphadenopathy, cryoglobulinemia, a serum monoclonal component, rheumatoid factor, low serum C4 and leucopenia).⁶

The US-guided CNB procedure for the major SGs

In this study, US-guided CNB was performed by a radiologist (ML) with extensive experience (ie, 10 years of practice) in ultrasound-guided biopsies. The procedures were conducted under real-time US guidance with linear high-frequency transducers (RS85, probe LM4-15B (Samsung, Seoul, South Korea) or Affiniti 70G, probe L18-5 (Philips, Amsterdam, the Netherlands)). The procedures were performed with an aseptic, free-hand technique under real-time US guidance in a non-operating room.

Biopsies were performed with a 14-gauge, semiautomatic CNB system (Precisa 14G, HS Hospital Service, Aprilia, Italy), with a sampling length set on 10 mm or, more frequently, 20 mm, depending on the size of the target area. US-guided CNB was performed on participants' clinically most swollen gland. The biopsy was performed on the area with the most suspicious ultrasonographic appearance (severe inhomogeneity of the glandular parenchyma or focal lesion, whenever present). For deep lesions, the procedure's risks and benefits were weighed by the radiologist and the clinicians. The optimal procedure technique was adapted to participants' SG type (ie, parotid vs submandibular glands) and lesion type (ie, localised vs diffuse).

During their biopsies, patients were positioned in a supine position.²⁷ Their shoulders were slightly lifted (usually with a pillow below their upper back), and their necks were slightly hyperextended, turned towards the contralateral side of the target gland (figure 3A).

For patients with parotid focal lesions, the spatial relationship between the 'safety area' and the lesions themselves was primarily assessed to determine the procedure's technical feasibility and safety. After the radiologist analysed the safety and feasibility, the procedure targeted lesions posteriorly through the 'safety area', maintaining the shortest path and the most superficial needle position possible within a depth of 1–1.5 cm from the glandular surface.

For patients with diffusely inhomogeneous parenchyma without focal lesions, parotid biopsies targeted the posterior-caudal part of the gland in a caudocranial direction. The needle entered within the 'safety area', maintaining the most superficial needle direction possible within 1–1.5 cm of the glandular surface.

For US-guided submandibular gland biopsies, patients were positioned like patients receiving a US-guided biopsy

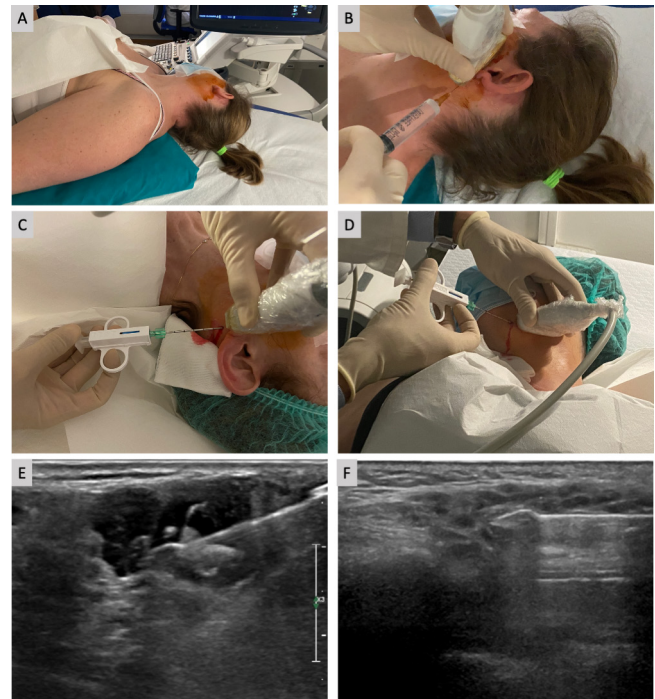


Figure 3 (A): A patient's supine positioning for a parotid gland CNB, with their shoulders slightly lifted (and a pillow below their upper back), slight hyperextension of their neck and facing towards the contralateral side of the target gland. (B): Local anaesthetic injected under ultrasound guidance into the subcutaneous tissue and the posterior, superficial part of the parotid gland while moving the needle in a caudocranial direction. (C): A semi-automatic needle inserted into the 'safety area' of the left parotid gland. (D): A semi-automatic needle inserted into the left submandibular gland, (E): The needle's sonographic appearance in a focal lesion of the parotid gland. (F): The needle's sonographic appearance in a peculiar appearance of the salivary gland, in the absence of focal lesion. CNB, core needle biopsy.

of the parotid gland, with their heads fully turned to the opposite side. Patients' submandibular glands were accessed anteriorly or posteriorly, depending on patients' cooperation, operator preferences and the eventual US detection of a focal lesion, as described above, in this case, nerve injury was not a concern. Attention was paid also on localising and then avoiding the path of the facial artery, which represents the major noble anatomical structure in strict contact with the gland.

The asepsis of the procedure was guaranteed by accurate disinfection of the skin with gluconate chlorhexidine or povidone-iodine solution and the use of single use probe covers. A local anaesthetic was injected under US guidance with a fine needle (23 G) through the skin and subcutaneous fat (figure 3B). Shortly after this local anaesthetic injection, a small incision of the anaesthetised skin was made with a scalpel. The biopsy was then performed with a 14 G semiautomatic needle under US guidance (figure 3B,C). One to five needle passes were performed through the same skin incision (figure 3E,F). The biopsy samples were fixed in formalin and sent for histological analysis. After this procedure, patients

compressed their puncture sites and remained under observation for at least 30 min.

Evaluation of postbiopsy complications and peri-procedural pain

This study's participants were evaluated clinically 1, 2 and 12 weeks after their US-guided CNB and beyond the 12 weeks in case of persistent complications. All patients were asked to complete a questionnaire, reporting any postprocedural complications (online supplemental figure 1) as well as assessing their intraprocedural and postprocedural pain using the Visual Analogue Scale (VAS 0–10). Complications were categorised as *transient* (lasting <12 weeks) or *persistent* (lasting ≥12 weeks). Any complication that had developed during the follow-up period was assessed and recorded, including swelling, haematoma, bleeding, pain, local infection, anaesthesia or paraesthesia, sialoceles and fistulae. Potential damage of the facial nerve was assessed by clinically monitoring the eventual development of sensorimotor signs or symptoms.

RESULTS

Patients' demographic and clinical characteristics and laboratory findings

Thirty patients who had undergone US-guided CNB of the major SGs were evaluated. Of these patients, 27 (90%) were

women. Patients' mean age at the time of the biopsies was 59.8 years (SD: 13.2 years). Moreover, 23 of the study's 30 patients (76.6%) met the American College of Rheumatology (ACR) and EULAR classification criteria for pSS,²⁸ and 24 (80%) had anti-Ro/SSA antibodies. Among the seven patients who did not fulfil the 2016 ACR/EULAR criteria, pSS was highly suspected based on clinical grounds in five patients, while in two patients, the clinical picture did not allow one particular disease as much more likely. They all refused a minor SG biopsy performed concomitantly with US-guided CNB of the major SGs.

Additionally, 22 patients (73.3%) had parotid gland swelling. Among this group, 11 patients showed chronic (≥12 months) parotid gland enlargement, 8 patients presented with episodic parotid enlargement of long duration (2–11 months) and 3 patients showed episodic parotid gland enlargement of short duration (<2 months). Eight patients (26.7%) reported submandibular gland swelling. Particularly, five patients presented chronic submandibular gland enlargement, while three patients presented episodic submandibular enlargement of long duration. Patients' characteristics are presented in [table 1](#).

Sonographic characteristics

SGUS examinations were performed in all studied patients before US-guided CNB. SGUS detected a focal

Table 1 Patients' clinical and laboratory features

| Patients, N | 30 |
|---|----------------------------|
| Gender, female, n (%) | 27 (90%) |
| Age at evaluation, mean (SD), years | 59.8 years (SD 13.2 years) |
| Disease duration, mean (SD), years | 13.3 years (SD 15.2 years) |
| Fulfilment of ACR-EULAR classification criteria for pSS, n/N (%) | 23/30 (76.6%) |
| Parotid gland enlargement, n/N (%) | 22/30 (73.3%) |
| Chronic (≥12 months) | 11/22 |
| Parotid enlargement of long duration (2–11 months) | 8/22 |
| Parotid enlargement of short duration (<2 months) | 3/22 |
| Submandibular gland enlargement, n/N (%) | 8/30 (26.7%) |
| Chronic (≥12 months) | 5/8 |
| Submandibular enlargement of long duration (2–11 months) | 3/8 |
| Submandibular enlargement of short duration (<2 months) | 0 |
| Duration of parotid and/or submandibular swelling at the time of biopsy, median (25–75 quartiles), months | 12 (4.25–14.75) |
| Anti-Ro/SSA or anti-La/SSB positive, n/N (%) | 24/30 (80%) |
| Lymphadenopathy, n/N (%) | 11/30 (36.67%) |
| Cryoglobulinemia, n/N (%) | 5/30 (16.67%) |
| Cryoglobulinaemic vasculitis, n/N (%) | 4/30 (13.3%) |
| Serum monoclonal component, n/N (%) | 12/30 (40%) |
| Rheumatoid factor positive, n/N (%) | 22/30 (73.3%) |
| Leucopenia (WBC<4.0x10 ⁹ /L, n/N (%) | 10/30 (33.3%) |
| Low C4, n/N (%) | 13/30 (43.3%) |

ACR, American College of Rheumatology; pSS, primary Sjögren Syndrome; WBC, white blood cells.

lesion among 19 of 30 (63.3%) patients, whereas 11 patients (36.7%) showed inhomogeneous glandular parenchyma, suggesting lymphoproliferative disease in the absence of glandular focal lesions. All biopsied glands showed a sonographic OMERACT (Outcome Measures in Rheumatology) score ≥ 2 (grade 2 in 4 out of 30 patients and grade 3 in 26 out of 30 patients). Overall, 22 parotid glands (73.33%) and 8 submandibular glands (26.67%) were biopsied.

Out of 22 US-guided CNBs of the parotid glands, 14 (63.6%) were performed on focal lesions, and in all cases, the procedure was technically and safely feasible through the ‘safety area’. For biopsies of the submandibular glands, five of eight (62.5%) procedures were performed on focal lesions. At least two samples were taken in all suspected cases. During the US-guided parotid gland CNB, the facial nerve was not clearly identifiable by SGUS in none of 22 patients (100%).

Safety and patient acceptance

US-guided CNB was well tolerated, and patients reported no long-term complications during the follow-up period of mean \pm SD: (10.6 \pm 7.3 months). Only transient complications (lasting <12 weeks) were reported by 13 patients (43%). Specifically, five cases of local swelling at the biopsy site were reported, lasting no more than 6 days, along with two cases of local bleeding and subsequent haematoma of the submandibular area, one case of transient facial paresis (lasting less than 1 hour, due to the anaesthetic) and four cases of local paraesthesia lasting

less than 2 hours. More details about these complications are presented in [figure 4A](#).

Intraprocedural pain, evaluated using the VAS, was assessed via a questionnaire and found to be low (mean VAS: 1.67 \pm 2.47), like postprocedural pain (mean VAS: 1.23 \pm 2.3). Specifically, 17 of 30 patients (56.67%) reported no intraprocedural pain, eight patients (26.67%) reported mild pain, two patients (6.67%) reported moderate pain and three patients (10%) reported severe pain (maximum VAS pain: 8/10). Postprocedural pain did not occur for 21 of 30 patients (70%), while 5 patients (16.67%) experienced mild postprocedural pain, two patients (6.67%) experienced moderate postprocedural pain and two patients (6.67%) experienced severe postprocedural pain. [Figure 4B](#) presents more details about participants’ procedure-related pain.

Overall, for the 9 of 30 patients (30%) who reported postprocedural pain, their median postprocedural pain duration was only 2 days (Q25–75: 1–3 days). No statistically significant difference was found between parotid and submandibular US-guided CNB in pain assessment. Importantly, patients did not report any surgical wounds or scar formation after the procedures’ skin incisions. The entire duration of the US-guided CNB procedure, from patients’ entrance into the examination room to their exit, took a maximum of 40 min.

Histopathological diagnoses

The biopsy samples were diagnostic in 28 of 30 patients (93.3%), in two cases (one parotid, one submandibular gland biopsy), a tissue sample of sufficient quality for histopathological diagnosis was not obtained. Patients’ pathological diagnoses included MALT lymphoma for 14 of 30 patients (46.6%), focal lymphoepithelial sialadenitis (LESA) with initial acquisition of the MALT tissue for two patients (6.7%), LESA for three patients (10%). Other histopathological diagnoses were reported in online supplemental table 1. In 3 of 30 patients, the gland biopsies’ histological results allowed respective differential diagnoses of sarcoidosis, IgG4-related disease and chronic sclerosing sialadenitis without pSS.

Of note, in 11 out of 14 cases (78.6%), MALT lymphoma was identified in patients satisfying pSS ACR/EULAR criteria. Moreover, in 10 out of 14 cases (71.42%), MALT lymphoma was detected in a focal lesion. All patients diagnosed with MALT lymphoma underwent further investigations (ie, PET/CT imaging, haematologic consult).

Among the seven patients who did not fulfil the 2016 ACR/EULAR criteria, subsequent US-guided CNB of the major SGs was consistent with pSS (focal lesions $\geq 1/4$ mm², LESA or MALT lymphoma) in six patients.

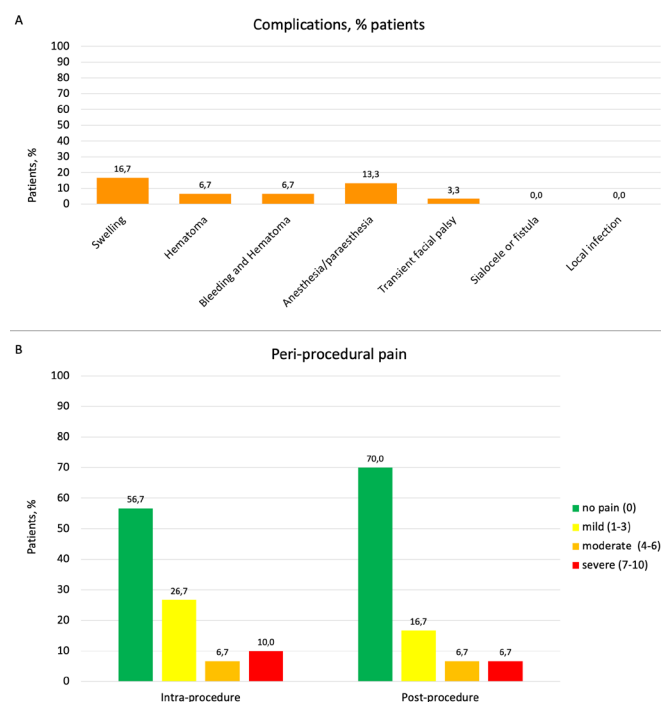


Figure 4 (A) Complications of US-guided CNB; all complications were transient (<12 weeks), and no persistent complications were reported during follow-up. (B): Peri-procedural pain: patients’ reported intra- and post-operative pain. CNB, core needle biopsy; US, ultrasound.

DISCUSSION

Sampling quality tissue for histopathological analysis is crucial for diagnostic, prognostic and research purposes. In pSS cases, quality samples are even more valuable since this autoimmune disease presents the highest risk of lymphoproliferative disorders and, moreover, the exact lymphomagenesis is not yet clearly defined.⁶ Currently,

an effective treatment of pSS is lacking; however, the recent availability of biologic target therapies might offer new treatment options.²⁹

SGUS is frequently used to assess the structural abnormalities typical of pSS.⁸ Furthermore, recent reports have suggested that the sonographic detection of focal lesions or a peculiar sonographic appearance of SGs (eg, large, confluent, hypoechoic areas spread over the gland) could indicate glandular B-cell lymphoma,^{17,18} which has yet to be proven by histology.

For patients without pSS who present SGUS-detected focal lesions of the major SGs, fine-needle aspiration cytology (FNAC) is performed to differentiate between benign and malignant lesions. FNAC is a safe technique, but it frequently fails to provide material sufficient for a diagnosis.³⁰ In patients with pSS at a high risk of lymphoma development, a histological, rather than cytological, sampling is usually needed. Therefore, such other procedures as open surgical biopsy or US-guided CNB may play a role.¹⁸

Open surgical biopsy of the major SGs is a safe technique when performed by expert surgeons but presents several disadvantages, such as the need for an operating room and possible adverse effects (such as facial nerve damage), which could limit its accessibility. Importantly, the focal lesions identified by SGUS may not be precisely identified during surgical biopsy procedures; therefore, this approach cannot accurately perform biopsies of SGUS-identified focal lesions. Furthermore, as reported in the preliminary experience by Zabotti *et al*,¹⁵ the open surgical biopsy approach showed a higher number of persistent complication, compared with US-guided CNB approach.

US-guided CNB could overcome both FNAC and surgical limitations. Recent evidence suggests that, for patients with pSS with major SG enlargement—a significant risk factor for B-cell lymphoma⁶—US-guided CNB can provide sufficient sampling for pathological examination.³¹

The current study completed a preliminary study¹⁵ demonstrating that US-guided CNB of the SGs is accurate and safe for patients with pSS suspected to have lymphoma, providing sufficient material for a histopathological diagnosis in most cases. The safety of US-guided CNB of the parotid glands was recently assessed in a meta-analysis,¹⁹ which reported high diagnostic accuracy for both sensitivity and specificity as well as a very low complication rate and facial nerve paralysis as the most severe complication. The identification of the facial nerve via ultrasound is challenging. Currently, few data are available on ultrasonographic scanning of the facial nerve. High-resolution ultrasonography might play a role in the assessment and scanning of the facial nerve.³² To identify the facial nerve, Tawfik *et al* described the facial nerve's sonographic appearance, providing reference values from 50 healthy volunteers.³³ Meanwhile, other authors^{34–36} have tried to scan the facial nerve in order to manage Bell's palsy. However, the extracranial part of the facial nerve after its emergence from the stylomastoid foramen is only partly

assessable via ultrasound.³⁷ To the best of our knowledge, none of the studies was able to assess by US of the facial nerve on its extracranial emergence when it enters the parotid parenchyma from a longitudinal or transverse view of way.

In the current authors' experience, the sonographic assessment of the facial nerve as it exits the stylomastoid foramen has not been feasible, particularly in cases where the disease affects the parotid gland, leading to ultrasonographic glandular impairment. Therefore, we performed US-guided parotid gland biopsies in the 'safety zone' for our patients.

In the current study, we described our US-guided approach and the technique used to safely perform a US-guided CNB in SGs of patients with pSS in detail, focusing on parotid gland biopsies in the 'safety zone'. In this area, the facial nerve runs deeply in the glandular parenchyma, and the parotid gland's superficial lobe protects the facial nerve at a length of approximately 2 cm (with some variability between individuals), minimising the risk of nerve damage.

The few reports available for submandibular US-guided CNB among patients with pSS^{17,38} have described the procedure's efficacy in providing sufficient material for diagnosis and a good safety profile. Our patient cohort reported no long-term complications, confirming US-guided CNB's safety profile for both parotid and submandibular glands.

Overall, in our opinion, US-guided CNB offers several advantages, the main being its safety and feasibility: in fact, it provides relatively easy access to both the parotid gland and the submandibular gland without a need for surgery, being less invasive and more patient friendly. In the future, the US-guided CNB approach might be performed directly by rheumatologists with expertise in sonography and bioptic procedures, as is now common practice for synovial biopsies. Second, this procedure allows for the targeting of glandular areas with different sonographic patterns in both the parotid and submandibular glands. According to our study, major SG biopsies may provide adequate samples for the early detection of suspected SG lymphoma, thus playing a role in the follow-up of suspected SG lymphoma in pSS.^{24,39} Moreover, the procedure allowed us to improve differential diagnoses for our patients initially suspected to have pSS (such as granulomatous sialadenitis consistent with sarcoidosis and IgG4-related disease). These findings emphasise the importance of SG biopsies—especially in patients with pSS with glandular swelling—in order to detect not only lymphoproliferative disease but also less common diseases that would otherwise be underdiagnosed.^{40–42}

Furthermore, this new sampling technique might provide histological material from the major SGs that offers possible future research implications for tissue sampling.²¹ It may also provide superior diagnostic accuracy while improving prognostic value,³⁹ allowing for the monitoring of disease activity and tissue damage^{10,43} as well as patients' response to treatment.^{44,45} Further studies should better assess US-guided CNB's diagnostic accuracy and safety for patients with pSS, as well as more researches should focus on the relationship between major SG and minor SG histology, and between salivary histology and sonographic appearances in pSS.

CONCLUSION

US-guided CNB represents a novel approach for the management of patients with pSS. This procedure has shown remarkable patient safety and tolerance, allowing for adequate tissue sampling and definite diagnoses for almost all patients who participated in this study.

Author affiliations

¹Rheumatology Clinic, Department of Medical and Biological Sciences, University Hospital 'Santa Maria della Misericordia' c/o University of Udine, Udine, Italy

²Institute of Radiology, Department of Medicine, University Hospital 'Santa Maria della Misericordia' c/o University of Udine, Udine, Italy

³Department of Rheumatology, Hospital of Bruneck, Bruneck, Italy

⁴Institute of Anatomic Pathology, University Hospital 'Santa Maria della Misericordia' c/o University of Udine, Udine, Italy

⁵Department of Rheumatology, Division of Internal Medicine, University Medical Centre Ljubljana, Ljubljana, Slovenia

⁶Department of Rheumatology, Medical University Graz, Graz, Austria

Correction notice This article has been amended since it was first published online. Luca Quartuccio was spelt Quartuccio Luca.

Contributors Conceptualisation: AZ, IG, SZC, CD, AH, ML, EP. Methodology: AZ, ML, EP. Investigation: IG, SZC, VM. Data curation: IG, SZC, VM, AZ, EP. Writing—original draft preparation: IG, AZ. Writing—review and editing: IG, VM, AZ, SDV, ML. Supervision: SDV, LQ, CD, CZ, RG, AH. Guarantors: AZ. All authors have read and agreed to the published version of the manuscript.

Funding The authors have not declared a specific grant for this research from any funding agency in the public, commercial or not-for-profit sectors.

Competing interests None declared.

Patient consent for publication Not applicable.

Ethics approval The study was conducted according to a protocol approved by the Regional Ethical Committee (CEUR-2017-0s-027- ASUIUD). This study involves human participants and was approved by Ethics Committee of Friuli Venezia Giulia. Participants gave informed consent to participate in the study before taking part.

Provenance and peer review Not commissioned; externally peer reviewed.

Data availability statement Data are available upon reasonable request.

Open access This is an open access article distributed in accordance with the Creative Commons Attribution Non Commercial (CC BY-NC 4.0) license, which permits others to distribute, remix, adapt, build upon this work non-commercially, and license their derivative works on different terms, provided the original work is properly cited, appropriate credit is given, any changes made indicated, and the use is non-commercial. See: <http://creativecommons.org/licenses/by-nc/4.0/>.

ORCID iDs

Alojzija Hocevar <http://orcid.org/0000-0002-7361-6549>

Christian Dejaco <http://orcid.org/0000-0002-0173-0668>

Alen Zabotti <http://orcid.org/0000-0002-0573-464X>

REFERENCES

- Goules AV, Tzioufas AG. Primary Sjögren's syndrome: clinical phenotypes, outcome and the development of biomarkers. *Immunol Res* 2017;65:331–44.
- Goules AV, Argyropoulou OD, Pezoulas VC, et al. Primary Sjögren's syndrome of early and late onset: distinct clinical phenotypes and lymphoma development. *Front Immunol* 2020;11:594096.
- Zintzaras E, Voulgarelis M, Moutsopoulos HM. The risk of lymphoma development in autoimmune diseases: a meta-analysis. *Arch Intern Med* 2005;165:2337–44.
- Nocturne G, Pontarini E, Bombardieri M, et al. Lymphomas complicating primary Sjögren's syndrome: from autoimmunity to lymphoma. *Rheumatology* 2019. doi:10.1093/rheumatology/kez052. [Epub ahead of print: 05 Mar 2019].
- Nakamura S, Ponzoni M. Marginal zone B-cell lymphoma: lessons from Western and eastern diagnostic approaches. *Pathology* 2020;52:15–29.
- De Vita S, Gandolfo S. Predicting lymphoma development in patients with Sjögren's syndrome. *Expert Rev Clin Immunol* 2019;15:929–38.
- Alunno A, Leone MC, Bartoloni E, et al. Novel insights on lymphoma and lymphomagenesis in primary Sjögren's syndrome. *Panminerva Med* 2021;63:491–498.
- van Ginkel MS, Glaudemans AWJM, van der Veegt B, et al. Imaging in Primary Sjögren's Syndrome. *J Clin Med* 2020;9:2492.
- Zabotti A, Zandonella Callegher S, Gandolfo S, et al. Hyperechoic bands detected by salivary gland ultrasonography are related to salivary impairment in established Sjögren's syndrome. *Clin Exp Rheumatol* 2019;37 Suppl 118:146–52.
- Zandonella Callegher S, Zabotti A, Giovannini I, et al. Normal-Appearing Salivary Gland Ultrasonography Identifies a Milder Phenotype of Primary Sjögren's Syndrome. *Front Med* 2020;7:602354.
- De Vita S, Lorenzon G, Rossi G, et al. Salivary gland echography in primary and secondary Sjögren's syndrome. *Clin Exp Rheumatol* 1992;10:351–6.
- Jousse-Joulin S, D'Agostino MA, Nicolas C, et al. Video clip assessment of a salivary gland ultrasound scoring system in Sjögren's syndrome using consensual definitions: an OMERACT ultrasound Working group reliability exercise. *Ann Rheum Dis* 2019;78:967–73.
- Zabotti A, Zandonella Callegher S, Tullio A, et al. Salivary Gland Ultrasonography in Sjögren's Syndrome: A European Multicenter Reliability Exercise for the HarmonicSS Project. *Front Med* 2020;7:581248.
- Di Franco FT, Lorenzon M, Zabotti A. Main sonographic features of malt lymphoma in major salivary glands in Sjögren syndrome: our experience. *EcR 2021 EPOS*. Available: <https://epos.myesr.org/poster/esr/ecr2021/C-10893> [Accessed 23 Aug 2021].
- Zabotti A, Zandonella Callegher S, Lorenzon M, et al. Ultrasound-guided core needle biopsy compared with open biopsy: a new diagnostic approach to salivary gland enlargement in Sjögren's syndrome? *Rheumatology* 2021;60:1282–90.
- Lorenzon M, Tulipano Di Franco F, Zabotti A, et al. Sonographic features of lymphoma of the major salivary glands diagnosed with ultrasound-guided core needle biopsy in Sjögren's syndrome. *Clin Exp Rheumatol* 2021;39 Suppl 133:175–83.
- Baer AN, Grader-Beck T, Antiochos B, et al. Ultrasound-Guided Biopsy of Suspected Salivary Gland Lymphoma in Sjögren's Syndrome. *Arthritis Care Res* 2021;73:849–55.
- Baldini C, Zabotti A, Filipovic N, et al. Imaging in primary Sjögren's syndrome: the 'obsolete and the new'. *Clin Exp Rheumatol* 2018;36 Suppl 112:215–21.
- Haldar S, Sinnott JD, Tekeli KM, et al. Biopsy of parotid masses: review of current techniques. *World J Radiol* 2016;8:501.
- Colella G, Cannavale R, Vicidomini A, et al. Salivary gland biopsy: a comprehensive review of techniques and related complications. *Rheumatology* 2010;49:2117–21.
- Pijpe J, Kalk WWI, van der Wal JE, et al. Parotid gland biopsy compared with labial biopsy in the diagnosis of patients with primary Sjögren's syndrome. *Rheumatology* 2007;46:335–41.
- Manfrè V, Giovannini I, Zandonella Callegher S, et al. Ultrasound and Bioptic investigation of patients with primary Sjögren's syndrome. *J Clin Med* 2021;10:1171.
- Witt BL, Schmidt RL. Ultrasound-Guided core needle biopsy of salivary gland lesions: a systematic review and meta-analysis. *Laryngoscope* 2014;124:695–700.
- De Vita S, De Marchi G, Sacco S, et al. Preliminary classification of nonmalignant B cell proliferation in Sjögren's syndrome: perspectives on pathobiology and treatment based on an integrated Clinico-pathologic and molecular study approach. *Blood Cells Mol Dis* 2001;27:757–66.
- Quartuccio L, Salvin S, Fabris M, et al. BlyS upregulation in Sjögren's syndrome associated with lymphoproliferative disorders, higher ESSDAI score and B-cell clonal expansion in the salivary glands. *Rheumatology* 2013;52:276–81.
- HarmonicSS – HARMONization and integrative analysis of regional, national and international Cohorts on primary Sjögren's Syndrome (pSS) towards improved stratification, treatment and health policy making. Available: <https://www.harmonicss.eu/> [Accessed 15 Sep 2021].
- Di Franco FT, Lorenzon M, Zabotti A. Feasibility and safety issues of ultrasound-guided core biopsy of focal lesions of major salivary glands: our experience. *EcR 2021 EPOS*, 2021. Available: <https://epos.myesr.org/poster/esr/ecr2021/C-12973> [Accessed 23 Aug 2021].
- Shiboski CH, Shiboski SC, Seror R, et al. 2016 American College of Rheumatology/European League against rheumatism classification criteria for primary Sjögren's syndrome: a consensus and data-driven methodology involving three international patient cohorts. *Arthritis Rheumatol* 2017;69:35–45.
- Vivino FB, Bunya VY, Massaro-Giordano G, et al. Sjögren's syndrome: an update on disease pathogenesis, clinical manifestations and treatment. *Clin Immunol* 2019;203:81–121.

- 30 Fernandes H, D'souza CRS, Khosla C, *et al.* Role of FNAC in the preoperative diagnosis of salivary gland lesions. *J Clin Diagn Res* 2014;8:FC01–3.
- 31 Parker SH, Jobe WE, Dennis MA, *et al.* US-guided automated large-core breast biopsy. *Radiology* 1993;187:507–11.
- 32 Wegscheider H, Volk GF, Guntinas-Lichius O, *et al.* High-Resolution ultrasonography of the normal extratemporal facial nerve. *Eur Arch Otorhinolaryngol* 2018;275:293–9.
- 33 Tawfik EA. Sonographic characteristics of the facial nerve in healthy volunteers. *Muscle Nerve* 2015;52:767–71.
- 34 Baek S-H, Kim YH, Kwon Y-J, *et al.* The Utility of Facial Nerve Ultrasonography in Bell's Palsy. *Otolaryngology–Head and Neck Surgery* 2020;162:186–92.
- 35 Tawfik EA, Walker FO, Cartwright MS. A Pilot Study of Diagnostic Neuromuscular Ultrasound in Bell's Palsy. *J Neuroimaging* 2015;25:564–70.
- 36 Lo YL, Fook-Chong S, Leoh TH, *et al.* High-resolution ultrasound in the evaluation and prognosis of Bell's palsy. *Eur J Neurol* 2010;17:885–9.
- 37 Gruber H, Kovacs P. Sonographic Anatomy of the Peripheral Nervous System. In: Peer S, Bodner G, eds. *High-Resolution Sonography of the Peripheral Nervous System. Medical Radiology Diagnostic Imaging*. Berlin, Heidelberg: Springer, 2003: 13–36.
- 38 Kim HJ, Kim JS. Ultrasound-Guided core needle biopsy in salivary glands: a meta-analysis. *Laryngoscope* 2018;128:118–25.
- 39 De Vita S, Boiocchi M, Sorrentino D, *et al.* Characterization of prelymphomatous stages of B cell lymphoproliferation in Sjögren's syndrome. *Arthritis Rheum* 1997;40:318–31.
- 40 Fragoulis GE, Zampeli E, Moutsopoulos HM. Igg4-Related sialadenitis and Sjögren's syndrome. *Oral Dis* 2017;23:152–6.
- 41 Hong X, Li W, Xie X-Y, *et al.* Differential diagnosis of IgG4-related sialadenitis, primary Sjögren syndrome, and chronic obstructive submandibular sialadenitis. *Br J Oral Maxillofac Surg* 2017;55:179–84.
- 42 Brito-Zerón P, Pérez-Alvarez R, Feijoo-Massó C, *et al.* Coexistence of immune-mediated diseases in sarcoidosis. frequency and clinical significance in 1737 patients. *Joint Bone Spine* 2021;88:105236.
- 43 Baldini C, Luciano N, Seghieri C. Early damage assessment and prediction of damage accrual in primary Sjögren's syndrome using salivary gland ultrasonography during 2 years of follow-up. *Ann Rheum Dis* 2017;76:589.
- 44 Delli K, Haacke EA, Kroese FGM, *et al.* Towards personalised treatment in primary Sjögren's syndrome: baseline parotid histopathology predicts responsiveness to rituximab treatment. *Ann Rheum Dis* 2016;75:1933–8.
- 45 Jousse-Joulin S, Devauchelle-Pensec V, Cornec D. Ultrasonographic salivary glands response to rituximab in primary Sjögren syndrome patients in the tolerance and efficacy of rituximab in primary Sjogren syndrome study is not associated with the anatomopathology changes. *Arthritis Rheum* 2013;65:S1236.