

Trauma and Reconstruction

Outcome of Kidney Allografts in Recipients With a Femoral Arteriovenous Fistula: Report of Two Cases

Denise M.D. Özdemir-van Brunschot^{a,*}, Ruud G.L. de Sévaux^b, Henk W. van Hamersvelt^b, Michiel C. Warlé^a^a Department of Surgery, Division of Vascular and Transplant Surgery, Radboudumc, Nijmegen, The Netherlands^b Department of Nephrology, Radboudumc, Nijmegen, The Netherlands

ARTICLE INFO

Article history:

Received 28 April 2016

Accepted 13 May 2016

Available online xxx

Keywords:

Renal transplantation

Femoral arteriovenous shunt

Vascular steal

Steal

ABSTRACT

Two patients, who were on hemodialysis over a femoral arteriovenous fistula, were transplanted in our center. Despite adequate blood pressure, perfusion of the renal allograft remained poor after completion of the vascular anastomoses. Ligation of the femoral arteriovenous fistula (1.6 L/min) led to adequate perfusion. Initial graft function was good. Although it remains unclear whether ischemia of a renal allograft is caused by venous hypertension or vascular steal due to a femoral arteriovenous fistula, it might be necessary to ligate a femoral arteriovenous fistula to obtain adequate graft perfusion.

© 2016 The Author(s). Published by Elsevier Inc. This is an open access article under the CC BY-NC-ND license (<http://creativecommons.org/licenses/by-nc-nd/4.0/>).

Introduction

In some patients on hemodialysis, the femoral vessels are required for hemodialysis access due to inaccessibility of the subclavian and jugular vessels. When a renal allograft is placed in the iliac fossa and the renal vessels are anastomosed to the iliac vessels, renal allograft ischemia can occur. This can be caused by “a vascular steal phenomenon” or by venous hypertension.

We present 2 cases of renal transplantation in patients with a pre-existent femoral fistula.

Case presentation

Case 1

A 45-year old woman with end-stage renal disease was admitted to our hospital for a fifth renal transplantation. Recurrent stenosis and occlusions of the arteries of the upper extremities led to the start of hemodialysis via a graft from the right common femoral artery to the junction of the common femoral vein and great saphenous vein. Pre-transplant graft blood flow was 1.6 L/min

in the loop and 1.9 L/min in the common femoral artery. A cadaveric renal allograft was placed in the right hemi-abdomen and the renal artery and vein were anastomosed to the inferior caval vein and aorta.

Despite adequate blood pressure after reperfusion, graft perfusion was poor (blue colored parenchyma). Central venous pressure, measured in the superior caval vein, was 20 mm Hg. Clamping of the arteriovenous fistula or the right common iliac vein led to a decline in central venous pressure (8 mm Hg) and –more importantly- immediate improvement in graft perfusion. Therefore the femoral arteriovenous shunt graft was ligated. Apart from one hemodialysis session in the first week because of hyperkalemia, graft function was good (103 micromol/L at discharge). However, during the following weeks graft function deteriorated and eventually patient died 5 months after renal transplantation due to an abdominal sepsis.

Case 2

A 39-year old woman with end-stage renal disease caused by medullary renal cysts had received 4 renal transplants. After vascular rejection of the fourth renal allograft, she was put back on hemodialysis via a left femoral fistula. Fistula flow was 0.7 L/min. A cadaveric allograft became available for transplantation. Perioperatively, we observed good perfusion and initial graft function was good (eGFR 66 mL/min/1.73 m² at day 7). Unfortunately,

* Corresponding author. Department of Surgery, Division of Vascular and Transplant Surgery, Radboudumc, Geert Grooteplein-Zuid 10, P.O. Box 9101, 6500 HB Nijmegen, The Netherlands. Tel.: +31 24 36517612; fax: +31 24 3654 0501.

E-mail address: od.od.ozdemir@gmail.com (D.M.D. Özdemir-van Brunschot).

Table 1
Overview of literature

Author, year of publication	Contralateral or ipsilateral allograft	Post-operative course	Therapy	Allograft function
Kuwerz, 1988 ⁴	Ipsilateral	Day 11: rejection Week 5: hypertension and convulsions. Scintigraphy and DSA ^a : vascular steal	Ligation of fistula (week 5)	Good
Bloss, 1979 ¹	Contralateral Contralateral	Day 19: scintigraphy: vascular steal Day 9: persistent cardiac decompensation. Radionuclide perfusion study: vascular steal, compression of the shunt improves perfusion	Ligation of fistula (day 19) Ligation of fistula (day 9)	Good Good
Reek, 1997 ³	Ipsilateral	Perioperative: poor perfusion of allograft Doppler: arteriovenous fistula Day 2: DSA ^a : vascular steal	Ligation of fistula (day 2)	Good
Gourlay, 1998 ⁶	Ipsilateral Ipsilateral Ipsilateral	Uncomplicated Uncomplicated Week 16: steroid-responsive acute rejection	No ligation No ligation No ligation	Good Good Good
Chaudri, 2006 ⁵	Ipsilateral	Day 0: almost absent Doppler signals, after compression fistula: substantial improvement of venous and arterial flow.	Ligation of fistula (day 0)	Good
Osband, 2008 ²	Ipsilateral Ipsilateral	Day 0: absent diastolic flow, after compression: diastolic flow Perioperative: poor perfusion of allograft, color returned after occlusion of shunt	Ligation of fistula (day 0) Ligation of fistula (perioperative)	Good Good

^a digital subtraction angiography.

2 months after surgery the patient was re-admitted to the intensive care unit with respiratory failure and died 9 days later.

Discussion

The first two cases of renal allograft dysfunction due to vascular steal by a functioning femoral arteriovenous fistula were described

in 1979 by Bloss et al.¹ Since then 5 other cases have been described (Table 1).^{2–5} In all cases, allograft function dramatically improved after ligation of the femoral arteriovenous fistula. On the contrary, Gourlay et al described three cases in which ipsilateral femoral arteriovenous fistulas did not compromise renal allograft functioning.⁶ In all patients pre-operative venography with venous

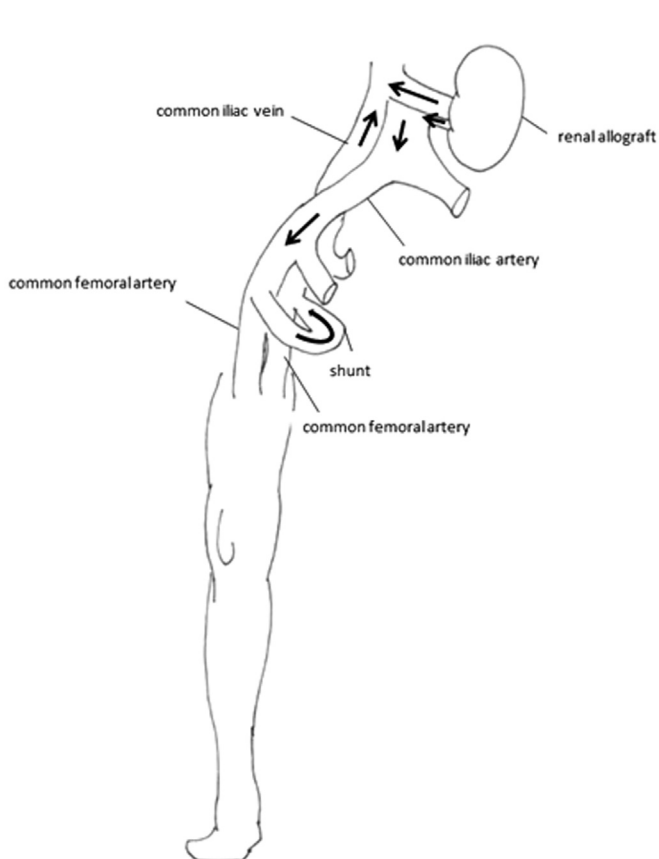


Figure 1. Vascular steal from renal allograft, caused by femoral arteriovenous shunt. Lower resistance in the femoral arteriovenous shunt causes flow to be diverted (“steal”) from the higher resistance circuit (renal allograft) to the lower resistance circuit (arteriovenous shunt). Arrows indicate blood flow.

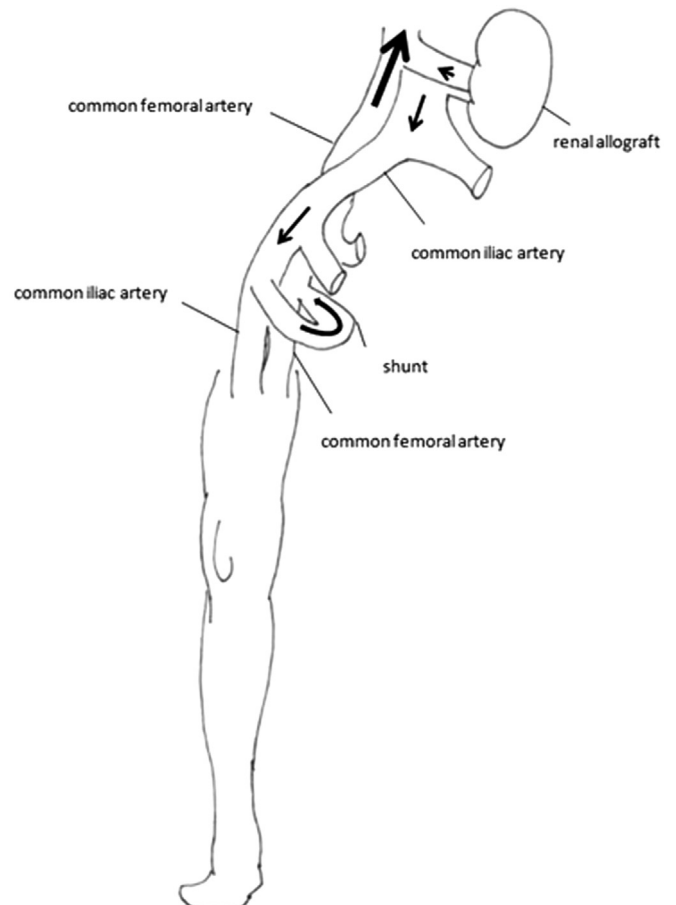


Figure 2. Venous hypertension caused by femoral arteriovenous shunt. Venous hypertension causes an outflow obstruction of the renal allograft. Arrows indicate blood flow.

pressure measurements were performed. Pressures within the fistula ranged from 4 to 12 mm Hg, but the pressure rapidly decreased distal to the venous anastomosis. Unfortunately, Gourlay et al did not report flow volumes of the arteriovenous fistulas.

The question arises whether ischemia of the renal allograft was caused by venous hypertension or by vascular steal induced by the femoral arteriovenous fistula.

Vascular steal is well defined in upper extremity arteriovenous fistulas. When flow in the arteriovenous shunt is high due to very low resistance in the outflow tract of the shunt, the difference in resistance causes arterial blood to divert from the higher to the lower resistance vascular circuit. The result is a steal syndrome, caused by retrograde flow in the higher resistance vascular circuit, e.g. the arteries and capillaries in the hand, toward the shunt. Symptoms caused by dialysis access-related steal syndrome of the hand can be mild, but prolonged severe hypoperfusion can lead to tissue necrosis necessitating amputation of the fingers, hand or even forearm.^{7,8} This same mechanism can cause allograft ischemia in patients with femoral fistulas (Fig. 1).

Another mechanism by which ischemia of the renal allograft could be caused is venous hypertension in the iliac or caval vein, due to a high-flow in the arteriovenous fistula (Fig. 2), which hampers the venous outflow of the kidney.

Interesting is our observation that the allograft functioned well when fistula flow was 0.7 L/min, whereas ligation of the fistula was necessary when the flow was 1.6 mL/min. This suggests that a high-flow fistula may cause increased central venous pressure and outflow obstruction of the allograft. Further research is required to confirm our observation that an ipsilateral, high-flow arteriovenous fistula caused high central venous pressures and poor allograft perfusion.

Conclusion

Initial poor allograft perfusion can be caused by a femoral arteriovenous fistula used for hemodialysis. The question remains whether this poor allograft perfusion is caused by a vascular steal phenomenon or by venous hypertension. Our report supports the hypothesis that the presence of an ipsilateral high-flow volume arteriovenous fistula, may cause high central venous pressure and poor allograft perfusion. Our data indicate that a femoral fistula with a low or moderate flow might be saved during kidney transplantation.

Conflict of interest

No conflict of interest.

References

1. Bloss RS, McConnell RW, McConnell BG, et al. Demonstration by radionuclide imaging of possible vascular steal from a renal transplant. *J Nucl Med.* 1979;20(10):1053–1054.
2. Osband AJ, Jones NI, Zaki RF. *Femoral Arteriovenous Graft Can Complicate Kidney Transplantation.* 2008.
3. Reek C, Tenschert W, Cremaschi L, Nicolas V, Wolf W, Fernandez S. Femoral arteriovenous fistula and transplant malfunction after allogeneic kidney transplantation. A case report. *Urologe A.* 1997;36(1):81–83.
4. Kuwertz-Broking E, Bulla M, Langer K, et al. Steal syndrome after kidney transplantation caused by A-V fistula at the thigh. *Child Nephrol Urol.* 1988;9(3):163–168.
5. Chaudhri Y, Horrow MM, Zaki R. Vascular steal of renal transplant: sonographic diagnosis. *J Ultrasound Med.* 2006;25(7):939–941.
6. Gourlay WA, Legiehn G, Manson DC, Landsberg DN. Successful renal transplantation with ipsilateral femoral arteriovenous grafts. *Transplantation.* 1999 Feb 15;67(3):493–495.
7. Antoniou GA, Lazarides MK, Georgiadis GS, Sfyroeras GS, Nikolopoulos ES, Giannoukas AD. Lower-extremity arteriovenous access for haemodialysis: a systematic review. *Eur J Vasc Endovasc Surg.* 2009;38(3):365–372.
8. Gradman WS, Laub J, Cohen W. Femoral vein transposition for arteriovenous hemodialysis access: improved patient selection and intraoperative measures reduce postoperative ischemia. *J Vasc Surg.* 2005;41(2):279–284.