

REVIEW

Stress echocardiography in patients with morbid obesity

Benoy N Shah BSc MBBS MRCP¹ and Roxy Senior FRCP FESC FACC^{2,3}

¹Department of Cardiology, Wessex Cardiac Centre, University Hospital Southampton, Southampton, UK

²Department of Echocardiography, Royal Brompton Hospital, London, UK

³National Heart & Lung Institute, Imperial College London, London, UK

Correspondence should be addressed to B N Shah
Email
benoy@doctors.org.uk

Abstract

The incidence of significant obesity is rising across the globe. These patients often have a clustering of cardiovascular risk factors and are frequently referred for noninvasive cardiac imaging tests. Stress echocardiography (SE) is widely used for assessment of patients with known or suspected coronary artery disease (CAD), but its clinical utility in morbidly obese patients (in whom image quality may suffer due to body habitus) has been largely unknown. The recently published Stress Ultrasonography in Morbid Obesity (SUMO) study has shown that SE, when performed appropriately with ultrasound contrast agents (whether performed with physiological or pharmacological stress), has excellent feasibility and appropriately risk stratifies morbidly obese patients, including identification of patients who require revascularization. This article reviews the evidence supporting the use of echocardiographic techniques in morbidly obese patients for assessment of known or suspected CAD and briefly discusses other noninvasive modalities, including magnetic resonance and nuclear techniques, comparing and contrasting these techniques against SE.

Key Words

- ▶ obesity
- ▶ stress echocardiography
- ▶ ultrasound contrast
- ▶ cardiac imaging

Introduction

The past 20 years have witnessed a significant worldwide increase in the prevalence of obesity. This phenomenon has been seen in both high- and low-income economies and has been accompanied by a rise in ‘metabolic’ risk factors such as hypertension, hyperlipidemia and diabetes mellitus. Indeed, the global prevalence of obesity has more than doubled over the past 30 years and it is believed that, in the UK, over one-quarter of the population are obese (1). Additionally, the most rapidly rising group of overweight individuals are the severely obese (2).

The BMI is the parameter most frequently used for classification of body weight. A BMI of 20–25 kg/m² is considered normal, 25–30 kg/m² is overweight, and individuals with BMI exceeding 30 kg/m² are classified

as obese. The term ‘morbid obesity’ was first used to describe patients with a BMI >35 kg/m² (3). Such patients often experience exertional symptoms and, due to their adverse risk profile, it is frequently necessary to exclude coronary artery disease (CAD) as a possible underlying cause (e.g. angina equivalent as a cause of dyspnea). The body habitus of such patients often poses significant technical challenges for each of the noninvasive imaging techniques, including stress echocardiography (SE), single-photon emission computed tomography (SPECT), and cardiovascular magnetic resonance (CMR) (4).

This article reviews the evidence underpinning the use of imaging techniques in patients with morbid obesity, with a focus upon echocardiography and recently published studies.

Methods

In order to identify relevant review articles and original scientific papers, we conducted a Medline search from 1980 to 2015, using the key search terms ‘morbid obesity’, ‘significant obesity’ and ‘obesity’ combined with the following: ‘dobutamine echocardiography’, ‘dobutamine stress echocardiography’ (DSE), ‘exercise echocardiography’, ‘stress echocardiography’ (SE), ‘thallium scintigraphy’, ‘technetium scintigraphy’, ‘single photon emission computed tomography’ (SPECT), ‘positron emission tomography’ (PET), ‘magnetic resonance’, and ‘cardiovascular magnetic resonance’ (CMR). Studies not published in the English language or conducted in animals were excluded.

Echocardiography

SE assesses systolic wall thickening at rest and after a stress, and thus allows inferences to be made about the state of the myocardium’s blood supply (i.e. the coronary arteries). In a normal healthy individual, left ventricle (LV) function is observed to be normal at rest with an increase in systolic thickening (accompanied by a reduction in LV cavity size) after stress. In a patient with significant coronary stenosis, at peak stress the myocardium subtended by the stenosed vessel will cease to thicken normally due to ischemia. Thus, the hallmark of ischemia on SE is a systolic wall thickening abnormality, with hypokinesia (reduction in systolic thickening) or akinesia (cessation of systolic thickening).

SE is a widely used investigative tool in clinical practice for diagnosis, risk stratification, and estimating prognosis of patients with CAD. SE has a number of theoretical advantages over other imaging modalities: first, either physiological or pharmacological stress can be employed; secondly, the technique is cheap and widely available; thirdly, it is portable and can be performed at the bedside if required; fourthly, it is very safe; and finally, there is no exposure to ionizing radiation (see [Table 1](#) for full comparison). The ability to perform physiological stress (bicycle or treadmill exercise) is a huge advantage for SE, as in addition to wall thickening information at rest and peak stress, these tests also provide a wealth of other data including physiological response of blood pressure (BP) and heart rate (HR) to exercise, an objective measure of a patient’s functional aerobic exercise capacity and, importantly, the ability to correlate a patient’s symptoms

Table 1 Comparison of noninvasive functional imaging techniques for detection of myocardial ischemia.

	SE	Nuclear (SPECT/PET)	Stress CMR
Availability	+++	++	++
Cost	+	++	+++
Exposure to ionizing radiation	–	++	–
Image quality ^a	++	++	+++
Extracardiac information	+	+	+++
Requirement for intravenous access ^b	+	+	+
Physiological stress possible	+	+	–
Potentially limited by cardiac devices ^c	–	–	++
Potentially limited by renal failure	–	–	+
Potentially limited by asthma	–	+	+
Potentially limited by claustrophobia	–	+	++

^aEchocardiography may still be limited by suboptimal image quality, despite the use of contrast, in some patients. CMR usually has excellent image quality, but this may be impaired in the morbidly obese, who may struggle with repeated prolonged breath holding for CMR sequence acquisitions.

^bExercise echocardiography can be performed without intravenous access, but the vast majority of patients require ultrasound contrast, thus requiring venous cannulation.

^cAll patients with cardiac resynchronization devices, implanted defibrillators and pacemakers implanted more than 5 years ago cannot have CMR scans.

with the physiological parameters (BP and HR), the ECG tracing, and wall motion.

However, before the advent of ultrasound contrast, SE was limited by suboptimal acoustic windows and thus poor endocardial visualization resulting in inconclusive tests and low reader confidence in image interpretation. Although the advent of tissue harmonic imaging and digital loop acquisition (with side-by-side display of rest and stress images) improved the accuracy of SE, it is the advent and uptake of ultrasound contrast that has had the most significant beneficial impact upon the accuracy and reader confidence of SE. Contrast agents improve endocardial border definition, allowing clear assessment of regional systolic thickening.

In the OPTIMIZE trial, in which 108 patients underwent randomized SE twice (once with and once without contrast), it was shown that when ≥ 2 segments were poorly seen on unenhanced imaging, diagnostic accuracy, reader confidence, and interpretability were significantly improved by the addition of contrast (5). A recent observational study involving almost 900 patients presenting with acute chest pain demonstrated that diagnostic image quality was almost 99% with optimal prognostic outcome (6). The use of contrast agents during SE is endorsed in European (7) and American (8) guideline documents.

The SUMO study

The above advances in SE (tissue harmonic imaging, digital acquisition with side-by-side display, and use of ultrasound contrast) have led to widespread use of the technique, but its efficacy in obese patients has hitherto been unproven. Our group has recently reported the findings of the Stress Ultrasonography in Morbid Obesity (SUMO) study, a prospective, multicenter observational study investigating the feasibility, diagnostic accuracy and prognostic value of SE in morbidly obese individuals (9). These results were also presented as an abstract at the British Society of Echocardiography's 2015 Annual Conference in Birmingham, UK.

In this study, all individuals with BMI >35 kg/m², referred for SE on clinical grounds, underwent either physiological (treadmill exercise) or pharmacological (dobutamine) SE. The feasibility of the test (i.e. the ability to start and finish the test and obtain diagnostic quality images in all three coronary territories, permitting the operator to issue a test report), the positive predictive value of the test (i.e. correlation between abnormal SE and angiography findings), and the prognostic value of SE (determined by occurrence of predefined events during follow-up) were all evaluated in the study.

In summary, we found an excellent feasibility of SE in this patient population (96% (200/209)). Ultrasound contrast was required in 96% patients to obtain diagnostic image quality (Fig. 1). In spite of their morbid obesity, we found that almost 40% of these patients were able to perform exercise stress, thus providing the added information of functional exercise capacity, heart rate and BP response to exercise and correlation between exertion and symptoms. Our results showed that most patients with an abnormal SE who subsequently underwent angiography did have the corresponding CAD; positive predictive value 22/25 (88%). Over a follow-up period of 17.8 ± 5.4 months, there were just nine events, which were significantly more common in those with inducible ischemia versus those without ischemia during SE. Patients with a normal SE had an excellent outcome: indeed, of the 153 patients followed up with a normal SE, 151 (99%) were free of any events at 1-year follow-up (9). These results of the SUMO study, the first study to investigate the clinical value of contemporary SE (in almost all cases contrast-enhanced SE) in morbidly obese individuals, are encouraging and support wider use of SE in this potentially technically challenging population.

Comparison with other echocardiographic studies

There are two recently published retrospective studies reporting the use of SE in obese patients that merit discussion. Murphy and coworkers reported on 366 obese patients (any BMI >30 kg/m², mean BMI 37.3 kg/m²) who underwent SE between 2006 and 2009 (10). The purpose of this study was to determine the prognostic impact of a normal SE at 1-year follow-up. As a result, all patients with abnormal or inconclusive SE were excluded and no angiography data were presented, meaning that no results could be derived on overall feasibility or positive predictive value; both of which were determined in the SUMO study. Only 10% patients received ultrasound contrast in this study. Silveira and coworkers reported on the use of SE in 945 obese patients (BMI >30 kg/m²) over a 12-year period (11). However, in this study no apical three-chamber images were acquired, 37% 'patients' were in fact defined as asymptomatic (thus unclear why SE was being performed) and over half of the patients did not attain >85% of the age-predicted target HR. Furthermore, no patients received ultrasound contrast and no angiography data were presented. Thus, in keeping with the study of Murphy and coworkers, overall feasibility and positive predictive value could not be determined.

Two studies have evaluated the feasibility of transthoracic SE specifically in obese patients awaiting bariatric surgery. In a study of 611 patients, Lerakis and coworkers showed that contrast-enhanced SE facilitated acquisition of diagnostic images in almost 97% of patients (12). However, only dobutamine SE was evaluated. More recently, Supariwala and coworkers performed a single-center retrospective analysis in patients with BMI >30 kg/m² referred for bariatric surgery and also found that just 1% of studies were nondiagnostic, specifically due to poor image quality (13).

Transesophageal dobutamine SE has also previously been investigated as an imaging option in obese patients and was reported as safe and accurate (14, 15, 16, 17), but in studies with low patient numbers and generally performed before the widespread availability of ultrasound contrast. Additionally, transesophageal imaging is semi-invasive and, depending on body size, may require anesthetic support.

Comparison with other techniques

Nuclear imaging

Myocardial perfusion scintigraphy or single-photon emission computed tomography (SPECT) is a widely

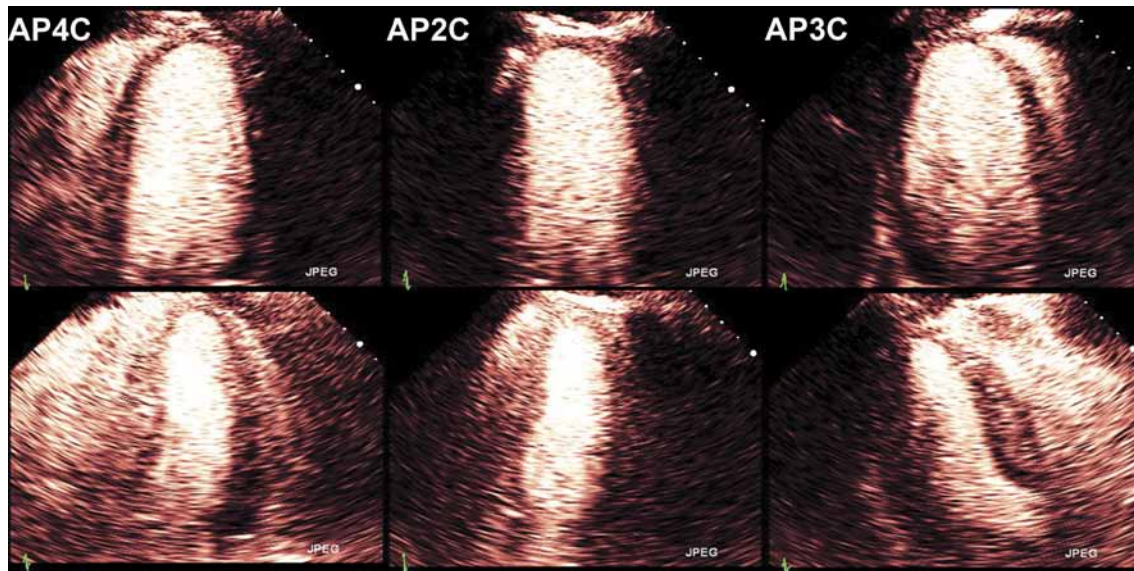


Figure 1

Contrast-enhanced rest (upper panel) and stress (lower panel) end-systolic images from the largest man in the SUMO study (weight 207 kg (456 lbs), BMI 63 kg/m² and BSA 3.2 m²) demonstrating excellent endocardial border visualization in all three apical views. There was no inducible ischemia on this study. Reproduced, with permission, from Shah BN, Zacharias K, Pabla JS, Karogiannis N, Calicchio F, Balaji G, Alhajiri A, Ramzy IS, Elghamaz A, Gurunathan S, *et al.* (2016) The clinical impact of contemporary stress echocardiography in morbid obesity for the assessment of coronary artery disease, *Heart*, vol 102, pp370–375. Copyright 2016 BMJ Publishing Group Ltd and the British Cardiovascular Society (9).

performed technique for assessment of inducible ischemia. The hallmark of ischemia during SPECT is the lack of radiotracer uptake by ischemic myocardium, thus appearing as an area of reduced or absent radioactive tracer count. In obese patients, excess soft tissue attenuation of radioactivity frequently produces an artifactual appearance of myocardial perfusion defects that may reduce the diagnostic accuracy of SPECT. This theoretical limitation has been confirmed in a study examining patients with BMI ≥ 30 kg/m² using quantitative exercise thallium-201 SPECT (18). More recent studies have shown better results with technetium tracers, but have demonstrated the importance of dual-headed or multiheaded cameras and the importance of attenuation correction in such studies (19, 20).

PET is the most advanced form of nuclear myocardial imaging, but is the least widely used technique for assessment of inducible myocardial ischemia. Nonetheless, a recent North American multicenter registry reported upon the prognostic value of cardiac PET in normal, overweight, and obese patients (21). There were 2687 patients with BMI ≥ 30 kg/m² and the authors found that a normal PET study conferred an excellent prognosis irrespective of BMI category. However, unfortunately, the focus of this paper was on outcomes and thus no data on feasibility, diagnostic accuracy or impact on clinical decision-making were presented.

Magnetic resonance imaging

Cardiovascular magnetic resonance (CMR) has become a valuable additional tool in clinical practice for assessment of ventricular size, structure and function not only at rest, but also during stress. Initially, most commonly performed using dobutamine (for assessment of wall thickening) in today's practice the majority of CMR units perform vasodilator stress perfusion CMR, most frequently using adenosine. Studies have shown that stress perfusion CMR can detect underlying CAD with comparable accuracy to other techniques. The greatest obstacle in performing CMR in obese patients is physical space: many morbidly obese individuals cannot fit inside the scanner or would fit very tightly and thus would become uncomfortable or claustrophobic. The feasibility, accuracy and prognostic value of vasodilator stress CMR, in a study of 285 patients with a median follow-up period of 2.1 years, has recently been reported (22). As in our study, the authors found excellent feasibility (although 7% patients required sedation) and favorable outcome following a negative study. The findings of these recent studies in SE (SUMO study), PET and CMR are compared in Table 2.

CT coronary angiography

CT coronary angiography provides anatomical rather than functional information about the coronary blood

supply. Research efforts are underway to validate the accuracy of fractional flow reserve data obtained during CT angiography (CT-FFR), but this technique is not currently used in routine clinical practice and there are no data to support its use in obese patients. CT angiography could be used to image the coronary arteries of patients with morbid obesity, but to obtain diagnostic quality images this is likely to require high-specification CT scanners (e.g. 256 or 320 slice) rather than conventional 64-slice scanners.

Limitations

No test in medicine has 100% feasibility. All of the noninvasive imaging modalities discussed may fail to yield a diagnostic result; for SE, limitations remain in certain individuals despite the advent of ultrasound contrast. In some patients, it is simply not possible to obtain adequate images of the LV, either at rest and/or at peak stress. There is also a very small risk of serious adverse reaction to ultrasound contrast; this is estimated to be 1:10,000 risk of anaphylaxis (23). However, several large studies have confirmed the excellent safety record of contrast agents (24, 25). For CMR, the biggest obstacle in performing the test in morbidly obese individuals is the actual physical ability to fit the patient inside the scanner. In some patients, their body habitus may make them unsuitable for all noninvasive techniques: invasive angiography (usually via the radial artery) may be the only way of confirming the presence of coronary heart disease. However, the recent SUMO study results are very

reassuring and demonstrate that diagnostic information (with prognostic value in addition) can be obtained in the vast majority of patients by contrast-enhanced SE.

Conclusions

SE is an effective, safe and accurate method for noninvasive detection of CAD in morbidly obese individuals. Guideline-directed use of ultrasound contrast permits diagnostic image quality to be obtained in almost all patients. The recent results from the multicenter SUMO study should give reassurance and greater confidence to the cardiological community about use of SE in this challenging patient cohort. Given the excellent feasibility, diagnostic accuracy and risk stratification possible with contrast-enhanced SE, including the option for physiological or pharmacological stress, we propose that SE is the initial technique of choice in significantly obese patients in need of functional assessment for the detection of inducible myocardial ischemia.

Declaration of interest

The authors declare that there is no conflict of interest that could be perceived as prejudicing the impartiality of this review.

Funding

This research did not receive any specific grant from any funding agency in the public, commercial or not-for-profit sector.

Table 2 Comparison of three recently published studies examining the use of stress echocardiography, cardiac PET and stress CMR in obese individuals.

Variable	CMR study	PET study	Stress echocardiography study
Author/Year	Shah <i>et al.</i> (2014) (22)	Chow <i>et al.</i> (2014) (21)	Shah <i>et al.</i> (2016) (9)
n	255	2687	209
Entry criteria	BMI ≥30 kg/m ²	BMI ≥30 kg/m ²	BMI ≥35 kg/m ²
Stressor(s) used	Pharmacological only (adenosine/regadenoson)	Pharmacological only (exact stressors not listed)	Physiological and pharmacological (treadmill/dobutamine)
Mean (±s.d.) age	56	60.0 ± 12.1	59.2 ± 11.6
Male gender (%)	101/255 (40)	1246/2687 (46)	93/209 (44)
Hypertension (%)	171/255 (67)	1986/2687 (74)	166/209 (79)
Hyperlipidemia (%)	150/255 (59)	1820/2687 (68)	138/209 (66)
Diabetes mellitus (%)	82/255 (32)	986/2687 (37)	95/209 (45)
Mean BMI (kg/m ²)	34	36.8 ± 6.3	39.3 ± 4.6
Feasibility (%)	255/285 (89)	Not reported	200/209 (96)
Need for sedation (%)	19 (7%)	None	None
Median follow-up	2.1 years	2.4 years	1.4 years
Annualized MACE rate after normal study (%)	0.30	0.15	0.95

MACE, major adverse cardiac events.

References

- World Health Organization (WHO) 2013 Obesity and overweight. Access date 15 January 2014. Geneva, Switzerland: WHO. (available at: <http://www.who.int/mediacentre/factsheets/fs311/en/>)
- Sturm R 2007 Increases in morbid obesity in the USA: 2000–2005. *Public Health* **121** 492–496. (doi:10.1016/j.puhe.2007.01.006)
- Grundy SM, Barondess JA, Bellegie NJ, Fromm H, Greenway F, Halsted CH, Huth EJ, Kumanyika SK, Reisin E, Robinson MK, et al. 1991 Gastrointestinal surgery for severe obesity. *Annals of Internal Medicine* **115** 956–961. (doi:10.7326/0003-4819-115-12-956)
- Uppot RN 2007 Impact of obesity on radiology. *Radiologic Clinics of North America* **45** 231–246. (doi:10.1016/j.rcl.2007.03.001)
- Plana JC, Mikati IA, Dokainish H, Lakkis N, Abukhalil J, Davis R, Hetzell BC & Zoghbi WA 2008 A randomized cross-over study for evaluation of the effect of image optimization with contrast on the diagnostic accuracy of dobutamine echocardiography in coronary artery disease the OPTIMIZE trial. *JACC: Cardiovascular Imaging* **1** 145–152. (doi:10.1016/j.jcmg.2007.10.014)
- Shah BN, Balaji G, Alhajiri A, Ramzy IS, Ahmadvazir S & Senior R 2013 Incremental diagnostic and prognostic value of contemporary stress echocardiography in a chest pain unit: mortality and morbidity outcomes from a real-world setting. *Circulation: Cardiovascular Imaging* **6** 202–209. (doi:10.1161/CIRCIMAGING.112.980797)
- Sicari R, Nihoyannopoulos P, Evangelista A, Kasprzak J, Lancellotti P, Poldermans D, Voigt JU & Zamorano JL 2008 Stress echocardiography expert consensus statement: European association of echocardiography. *European Journal of Echocardiography* **9** 415–437. (doi:10.1093/ejechocard/jen175)
- Pelikka PA, Nagueh SF, Elhendy AA, Kuehl CA & Sawada SG 2007 American Society of Echocardiography recommendations for performance, interpretation, and application of stress echocardiography. *Journal of the American Society of Echocardiography* **20** 1021–1041. (doi:10.1016/j.echo.2007.07.003)
- Shah BN, Zacharias K, Pabla JS, Karogiannis N, Calicchio F, Balaji G, Alhajiri A, Ramzy IS, Elghamaz A, Gurunathan S, et al. 2016 The clinical impact of contemporary stress echocardiography in morbid obesity for the assessment of coronary artery disease. *Heart* **102** 370–375. (doi:10.1136/heartjnl-2015-308796)
- Murphy M, Krothapalli S, Cuellar J, Kanjanauthai S, Heeke B, Gomadam PS, Guha A, Barnes VA, Litwin SE & Sharma GK 2014 Prognostic value of normal stress echocardiography in obese patients. *Journal of Obesity* **2014** 419724. (doi:10.1155/2014/419724)
- Silveira MG, Sousa AC, Santos MA, Tavares Ida S, Andrade SM, Melo LD, Andrade LS, Santos EL & Oliveira JL 2015 Assessment of myocardial ischemia in obese individuals undergoing physical stress echocardiography. *Arquivos Brasileiros de Cardiologia* **104** 394–400. (doi:10.5935/abc.20150006)
- Lerakis S, Kalogeropoulos AP, El-Chami MF, Georgiopoulou VV, Abraham A, Lynch SA, Lewis AJ, Leach GC, Osier EJ, Veledar E, et al. 2007 Transthoracic dobutamine stress echocardiography in patients undergoing bariatric surgery. *Obesity Surgery* **17** 1475–1481.
- Supariwala A, Makani H, Kahan J, Pierce M, Bajwa F, Dukkupati SS, Teixeira J & Chaudhry FA 2014 Feasibility and prognostic value of stress echocardiography in obese, morbidly obese, and super obese patients referred for bariatric surgery. *Echocardiography* **31** 879–885. (doi:10.1111/echo.12481)
- Bhat G, Daley K, Dugan M & Larson G 2004 Preoperative evaluation for bariatric surgery using transesophageal dobutamine stress echocardiography. *Obesity Surgery* **14** 948–951. (doi:10.1381/0960892041719554)
- Garimella S, Longaker RA & Stoddard MF 2002 Safety of transesophageal echocardiography in patients who are obese. *Journal of the American Society of Echocardiography* **15** 1396–1400.
- Madu EC 2000 Transesophageal dobutamine stress echocardiography in the evaluation of myocardial ischemia in morbidly obese subjects. *Chest* **117** 657–661. (doi:10.1378/chest.117.3.657)
- Legault S, Senechal M, Bergeron S, Arsenault M, Tessier M, Guimond J & Poirier P 2010 Usefulness of an accelerated transoesophageal stress echocardiography in the preoperative evaluation of high risk severely obese subjects awaiting bariatric surgery. *Cardiovascular Ultrasound* **8** 30. (doi:10.1186/1476-7120-8-30)
- Hansen CL, Woodhouse S & Kramer M 2000 Effect of patient obesity on the accuracy of thallium-201 myocardial perfusion imaging. *American Journal of Cardiology* **85** 749–752. (doi:10.1016/S0002-9149(99)00853-X)
- DeCicco AE, Sokil AB, Marhefka GD, Reist K & Hansen CL 2015 Feasibility of spect myocardial perfusion imaging in the super-obese using a multi-head semiconductor camera with attenuation correction. *Journal of Nuclear Cardiology* **22** 344–350. (doi:10.1007/s12350-014-0018-y)
- Duval WL, Croft LB, Corriel JS, Einstein AJ, Fisher JE, Haynes PS, Rose RK & Henzlava MJ 2006 Spect myocardial perfusion imaging in morbidly obese patients: image quality, hemodynamic response to pharmacologic stress, and diagnostic and prognostic value. *Journal of Nuclear Cardiology* **13** 202–209. (doi:10.1007/BF02971244)
- Chow BJ, Dorbala S, Di Carli MF, Merhige ME, Williams BA, Veledar E, Min JK, Pencina MJ, Yam Y, Chen L, et al. 2014 Prognostic value of pet myocardial perfusion imaging in obese patients. *JACC: Cardiovascular Imaging* **7** 278–287. (doi:10.1016/j.jcmg.2013.12.008)
- Shah RV, Heydari B, Coelho-Filho O, Abbasi SA, Feng JH, Neilan TG, Francis S, Blankstein R, Steigner M, Jerosch-Herold M & Kwong RY 2014 Vasodilator stress perfusion CMR imaging is feasible and prognostic in obese patients. *JACC: Cardiovascular Imaging* **7** 462–472. (doi:10.1016/j.jcmg.2013.11.011)
- Khawaja OA, Shaikh KA & Al-Mallah MH 2010 Meta-analysis of adverse cardiovascular events associated with echocardiographic contrast agents. *American Journal of Cardiology* **106** 742–747.
- Wei K, Mulvagh SL, Carson L, Davidoff R, Gabriel R, Grimm RA, Wilson S, Fane L, Herzog CA, Zoghbi WA, et al. 2008 The safety of definity and optison for ultrasound image enhancement: a retrospective analysis of 78,383 administered contrast doses. *Journal of the American Society of Echocardiography* **21** 1202–1206. (doi:10.1016/j.echo.2008.07.019)
- Main ML, Ryan AC, Davis TE, Albano MP, Kusnetzky LL & Hibberd M 2008 Acute mortality in hospitalized patients undergoing echocardiography with and without an ultrasound contrast agent (multicenter registry results in 4,300,966 consecutive patients). *American Journal of Cardiology* **102** 1742–1746. (doi:10.1016/j.amjcard.2008.08.019)

Received in final form 31 March 2016

Accepted 7 April 2016