

Cite this article as: Schibilsky D, Kondov S, Gottardi R, Kreibich M, Lehane C, Berger T *et al.* Endovascular treatment of traumatic aortic rupture using iliac extension stent-grafts in patients with small aortic diameters. *Interact CardioVasc Thorac Surg* 2022;34:885–91.

Endovascular treatment of traumatic aortic rupture using iliac extension stent-grafts in patients with small aortic diameters

David Schibilsky ^{a,b,†}, Stoyan Kondov^{a,b,*†}, Roman Gottardi ^{a,b}, Maximilian Kreibich^{a,b}, Cornelius Lehane^c, Tim Berger^{a,b}, Friedhelm Beyersdorf ^{a,b}, Matthias Siepe ^{a,b}, Martin Czerny^{a,b} and Bartosz Rylski^{a,b}

^a University Heart Center Freiburg - Bad Krozingen, Freiburg, Germany

^b Faculty of Medicine, University of Freiburg, Freiburg, Germany

^c Department of Anesthesiology, University Heart Center Freiburg - Bad Krozingen, Freiburg, Germany

* Corresponding author. University Heart Center Freiburg - Bad Krozingen, Hugstetterstr. 55, 79106 Freiburg, Germany. Tel: +49-761-270-8670; e-mail: stoyan.kondov@universitaets-herzzentrum.de (S. Kondov).

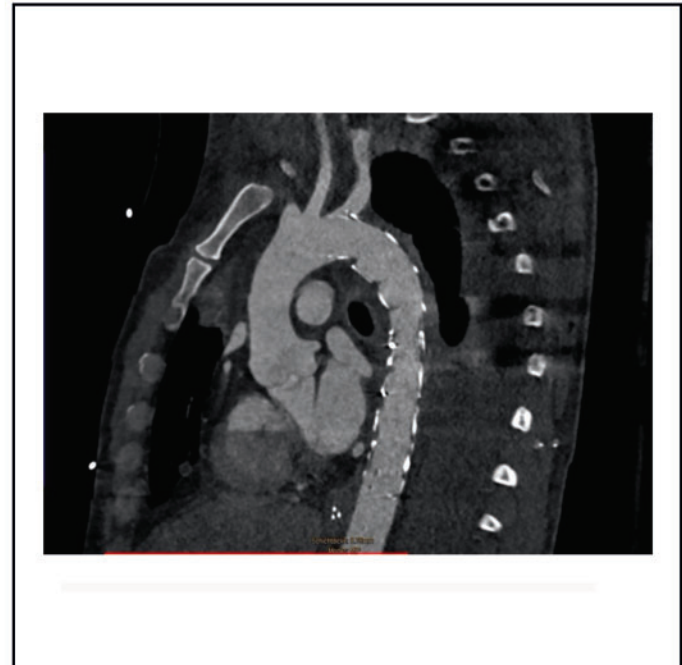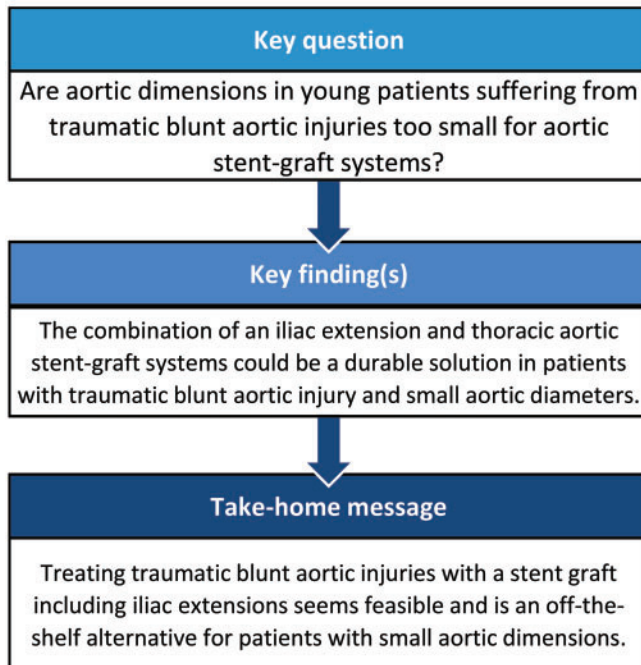
Received 13 April 2021; received in revised form 3 October 2021; accepted 20 November 2021

Abstract

OBJECTIVES: To evaluate outcomes after thoracic endovascular aortic repair in young patients sustaining traumatic blunt aortic injury (BAI) using iliac extension stent-grafts because of small aortic diameters measuring <24 mm.

METHODS: Retrospective analysis regarding clinical presentation, trauma management, endovascular techniques and outcome of patients with a small descending aorta involving an iliac extension stent-graft to treat traumatic BAI.

RESULTS: Among 48 patients who suffered a BAI and underwent thoracic endovascular aortic repair, 7 received iliac extension stent-grafts. They were 27.4 [standard deviation (SD): -13.1] years old and 6 out of 7 were male. The iliac extension stent-graft was used as distal



[†]The first two authors contributed equally to this work.

stent-graft, and a thoracic stent-graft was used in most patients as proximal extension. We achieved overall technical success in all patients during a procedure lasting 92.6 (SD: 54.9) min. One patient died 2 days after the endovascular procedure of hypoxic brain injury, and another died after 17 days of liver failure. That patient had also suffered a spinal cord injury following the procedure, as the stent-graft had been deployed in Ishimaru Zone 2, and the carotid to subclavian bypass had to be omitted because of his critical condition. Control computed tomographic angiographs was available in 6 patients after 7.7 (SD: 5.1) days and showed no endoleak. The surviving patients were discharged after 18.4 (SD: 13.4) days.

CONCLUSIONS: Treating traumatic BAI using iliac extension stent-grafts in young patients with small aortic diameters is feasible. We observed no mortality caused by the BAI or related to endovascular therapy within this small patient cohort.

Keywords: Deceleration trauma • Blunt aortic injury • Thoracic endovascular aortic repair • Iliac extension stent-grafts

ABBREVIATIONS

BAI	Blunt aortic injury
CTA	Computed tomography angiography
SD	Standard deviation
TEVAR	Thoracic endovascular aortic repair

INTRODUCTION

Blunt aortic injury (BAI) can be a life-threatening result of severe trauma, especially deceleration trauma often resulting from high-speed traffic accidents [1, 2]. Compared to open repair years ago [3–5] BAI mortality and paraplegia rates have dropped significantly since the development and clinical establishment of thoracic endovascular aortic repair (TEVAR) [3–5]. The aorta's diameter and length increase with age [6]. As aortic disease is so much more prevalent among older populations, stent-graft dimensions accommodate their larger aortic diameters [7–9]. Although performing TEVAR in younger patients with small aortic diameters requires smaller stent-grafts, none are currently available in TEVAR system platforms.

This dilemma ideally requires custom-made solutions. Custom-made prostheses are unfeasible, as manufacturing them takes weeks to months, making emergency treatment relying on custom-made prosthetics virtually impossible.

PATIENTS AND METHODS

Ethics statement

Permission for retrospective analysis was granted by our local ethics committee (No. 20-1302, Ethics Committee, Freiburg, Germany), and the need for informed consent was waived.

We screened our aortic database for all patients presenting a BAI treated between 2010 and 2020 (Supplementary Material, Fig. S2). Medical and radiological records and operative protocols were evaluated and clinical data were collected retrospectively. The aortic diameter within the proximal landing zone was under 24 mm in all patients. Associate traumas were classified according to the Injury Severity Score (ISS). Preoperative and postoperative aortic diameters were measured using IMPAX EE (Agfa Health Care, Mortsel, Belgium). All measurements were taken in multiplanar reconstruction, using the plane perpendicular to the manually corrected local aortic centreline. The sequences used had a slice thickness measuring <3 mm in all scans. The Ishimaru classification was used to describe the landing zone of

the proximal stent-graft within the aortic arch and descending aorta.

All patients were admitted to the emergency ward. Following our standard trauma evaluation protocol, all underwent electrocardiography-gated polytrauma computed tomography angiography (CTA) using a Somatom scanner (Siemens, Erlangen, Germany). Interdisciplinary involvement was guided by standard treatment procedures to determine the treatment strategy and sequence. Respecting the 'Advanced Trauma Life Support' principle 'treat first what kills first', we treated the immediately life-threatening injuries first of all [10].

Endovascular technique

TEVAR was performed via standard pre-closure technique for the main body delivery site with ProGlide[®] devices (Abbott Vascular, Chicago, IL, USA). The contralateral access site was used for the angiography catheter and was routinely sealed via FemoSeal[®] (Abbott Vascular) after the procedure.

A femoral cut down was done in one patient with very small access vessels. Heparin was administered routinely after establishing the pre-closure system with 100 I.E./kg. In case of cerebral bleeding, we discussed the heparin dose with the attending neurosurgeon; it had to be reduced in 3 patients. Lacking any contraindications, all patients received 100 mg acetylsalicylic acid starting on the first postoperative day. A Ziehm Vision FD detector (Ziehm imaging, Nuernberg, Germany) was used in all cases. Procedural planning aimed for 10–20% oversizing to ensure adequate sealing.

TEVAR for BAI was carried out using 2 stent-grafts to achieve optimal sizing and sealing within the distal and proximal landing zone. Due to the distal landing zone's small diameter, we employed Endurant IIs[®] iliac extension stent-grafts (Medtronic, Minneapolis, MN, USA) at this site and deployed this stent-graft first. Thereafter, the second stent-graft was deployed within the proximal landing zone (Supplementary Material, Fig. S1). In all but 3 patients, the diameter within the proximal landing zone enabled us to use a Relay NBS[®] thoracic stent-graft (Terumo Aortic, Sunrise, FL, USA). Those patients received 2 Endurant IIs extensions as well for the proximal landing zone (Patient #2 and #6 in Table 3).

All patients were subjected to rapid pacing to eliminate pulsatile blood flow and reduce the risk of stent-graft dislocation during stent-graft deployment. CTAs were taken before discharge and scheduled for 6 or 12 months thereafter. Unfortunately, due to the CoVid-19 pandemic, not all follow-up CTAs were performed as requested.

Statistics

Statistics were analysed using Graph Pad Prism Version 8.3 for Mac (Graph Pad Software Inc., San Diego, CA, USA). Data normality was tested using Kolmogorov test. Normally distributed data were presented as mean with \pm standard deviation (SD), if not as median with interquartile range.

Outcome and follow-up

Primary endpoints were endoleak, in-hospital death, and stroke. Secondary endpoints were those associated with procedure complications. Telephone follow-up and ambulatory CTA follow-ups were acquired.

RESULTS

Out of a total of 48 patients with BAI, 7 underwent TEVAR using iliac extension. Those 7 patients underwent the off-label technique involving iliac extension stent-grafts for treating traumatic BAI. Mean age was 27.4 (SD: -13.1) years; 6 of the 7 patients were male. Six patients were intubated at admission. The patients had no other cardiovascular comorbidities. A detailed clinical presentations are shown in Table 1.

Table 1: Demographics of the 7 patients suffering from multiple traumatic injuries including BAI

Variable	Value
Age (years)	27.4 (SD: 13.1)
Sex (male)	6 (85.7%)
Height	176.4 (SD: 5.6)
Mean ASA	3.6 (SD: 0.8)
Mean ISS	56.7 (SD: 7.0)
Intubation at admission	6 (85.7%)
Percutaneous access/iliac intervention	6 (85.7%)
Weight	78.3 (SD: 11.1)
BMI	25.2 (SD: 2.5)
Duration to follow-up (telephone) months	21.9 (SD: 16)

ASA: American Society of Anesthesiologist Classification; BAI: blunt aortic injury; BMI: body mass index; ISS: Injury Severity Score; SD: standard deviation.

Table 2: Treatment sequence and perioperative management

Patient	Trauma	Cerebral bleeding	Delayed TEVAR	Traumatic aortic injury grade	Heparin Administration (I.U.)	ASS 100 mg POD	Associated injuries
#1	Suicide	No	No	3	5000	1	Pelvis, diaphragm
#2	Car crash	Yes	No	3	2000	0	Pelvis, ICB
#3	Motorcycle	No	No	3	7000	0	Spleen, thorax, oesophagus
#4	Car crash	No	No	3	4000	1	Liver, abdomen apertum, thorax trauma
#5	Motorcycle	Yes	Yes	3	3000	0	Liver, spleen, pelvis
#6	Car crash	No	Yes	3	4000	1	Pelvis, thorax
#7	Motorcycle	Yes	No	3	2500	0	Spleen, lung

ASS: acetylsalicylic acid; ICB: intracerebral bleeding; I.U.: International units; POD: postoperative day; TEVAR: thoracic endovascular repair.

Preoperative details and trauma management

The trauma mechanism was a car-induced deceleration trauma (3 patients) and motorcycle accident (3 patients). The remaining patient had attempted suicide by jumping from the fourth floor. All patients revealed grade 3 BAI.

Five out of 7 patients underwent TEVAR for BAI before their additional concomitant trauma sequelae were treated. The 2 other patients were initially stabilized, and/or other organs were surgically managed. One patient's severe liver laceration (Injury Severity Score 51) was given priority, and a severe pelvis fracture type C (Injury Severity Score 57) in a second patient underwent external fixation prior to TEVAR.

Cerebral bleeding was detected via polytrauma CTA in 3 patients who were then given a reduced heparin dose of 2000 I.U., 2500 I.U. and 3000 I.U., respectively. Treatment with aspirin 100 mg in 4 out of 7 patients starting on the first postoperative day proved sufficient. Detailed overview of perioperative management is illustrated in Table 2.

Endovascular details and technical success

The stent-graft was proximally deployed in Ishimaru Zone 2 in 3 patients, and in Zone 3 in 4 patients. Of the 3 patients receiving stent-graft implantation in Ishimaru zone 2, 2 underwent carotid subclavian bypass, as Patient #5's clinical condition was instable.

Four patients received iliac extension stent-grafts with proximal and distal diameters of 20 mm. A stent-graft of 16 mm proximal and distal diameter was used in 1 patient. Another patient underwent inversed implantation of a 16 \times 20 mm stent-graft device (Patient #2). To achieve this, the iliac extension (16 \times 20 mm) was developed back-table and returned into the sheath rotated by 180° (Video 1). One patient received an iliac extension of 24 mm proximal and distal diameter. The patient who received the 16 \times 16 mm iliac extension stent-graft also underwent implantation of a second iliac extension stent-graft of 20 mm diameter as the proximal stent-graft. This patient also presented a proximal bird beak phenomenon (Figs 1 and 2).

All other patients received NBS Relay stent-grafts as the second proximal stent-graft, as exemplified in Fig. 3. The stent-graft diameters we employed are specified in Table 3. Oversizing was 18.2% (SD: -6.0) within the distal landing zone and 16.1% (SD: 6.5) in the proximal landing zone, respectively.

We observed overall endovascular technical success in all patients. Procedural time was 92.6 min (34–186 min) and under 2 h in all 5 patients not requiring carotid to subclavian artery

Table 3: Endovascular treatment

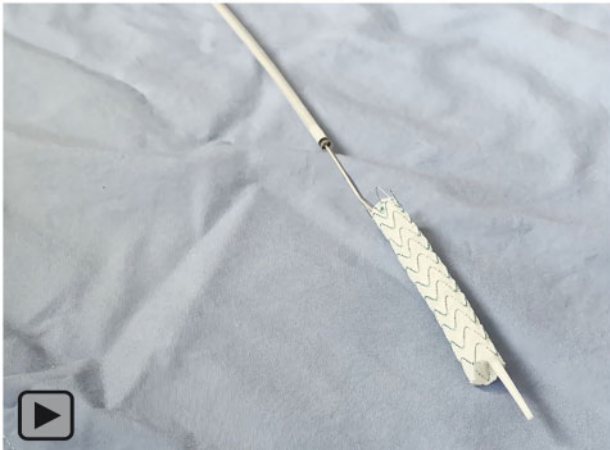Patient	Proximal Landing (Ishimaru Zone)	Iliac extension stent-graft proximal diameter (mm)	Iliac extension stent-graft distal diameter (mm)	Iliac extension stent-graft length (mm)	2nd proximal stent-graft proximal diameter (mm)	2nd proximal stent-graft distal diameter (mm)	2nd proximal Stent-graft length (mm)	Carotid- to-subclavian bypass
#1	3	20	20	82	28	24	100	No
#2	2	20 ^a	16 ^a	82 ^a				Yes
#3 ^c	2	20	20	82	24	24	100	Yes
#4	3	20	20	82	24	24	100	No
#5	2	20	20	82	26	26	100	No
#6	3	16	16	93	20 ^b	20 ^b	82 ^b	No
#7	3	24	24	82	28	28	150	No

^aRe-uploaded and delivered inverted.

^bSecond iliac extension; C-S Bypass (carotid to subclavian bypass).

^cDeath from extensive injuries 72 h after TEVAR.

TEVAR: thoracic endovascular repair.



Video 1: Backable deployment and reversed re-upload of iliac extension.

bypass. There was no endoleak evident in the first postoperative CTA control in any of those who survived. A detailed overview of endovascular treatments is presented in Table 3.

Clinical outcome

We observed no mortality associated with the aortic injury or TEVAR treatment within this patient cohort, fatalities resulted from otherwise extensive concomitant injuries in 2 patients. Patient #3 succumbed to hypoxic brain damage due to extensive brain trauma 72 h after the accident: he had suffered a traumatic amputation of his left leg and half of his pelvis, as well as a severe traumatic brain injury. After the confirmation of brain death, organ donation was initiated. A second patient (#5) died 17 days after TEVAR of liver failure caused by excessive liver damage resulting from the initial trauma. There was also clinical evidence of spinal cord injury in this patient following TEVAR. That patient had received the stent-graft deployed in Ishimaru Zone 2; we had had to forego carotid to subclavian bypass because of his critical condition.

We observed no stroke associated with TEVAR implantation. The total length of covered aorta was 123.3 (SD: 27.4) mm. The

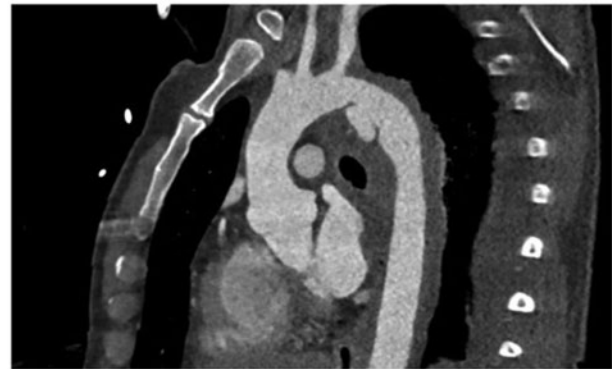


Figure 1: Blunt aortic injury pathology in Patient #2.

remaining 5 patients survived their severe trauma sequelae and were discharged (Table 4). Mean length intensive care unit stay was 12.7 (SD: 12.3) and overall length of hospital stay was 18.6 (SD: 13.8). There were no vascular or cardiac complications.

Follow-up

Control CTAs were available during the initial hospital stay in 6 out of 7 patients after 7.7 (SD: -5.1) days. As Patient #3 died 2 days post-TEVAR, there was no follow-up CTA. Patient #2 underwent a follow-up CTA after 410 days, which revealed no endoleak and a stable situation regarding the proximal bird beak. At their most recent clinical or telephone follow-ups of 21.9 (SD: 16) months, the 5 discharged patients were all alive (Fig. 4). There were no reinterventions or complications during follow-up.

DISCUSSION

This retrospective study enabled by a large institutional aortic database suggests that treating a BAI via an iliac extension stent-graft can be feasible and safe. To our knowledge, this manuscript is the first to describe TEVAR involving the employment of an iliac extension stent-graft to treat BAI patients.

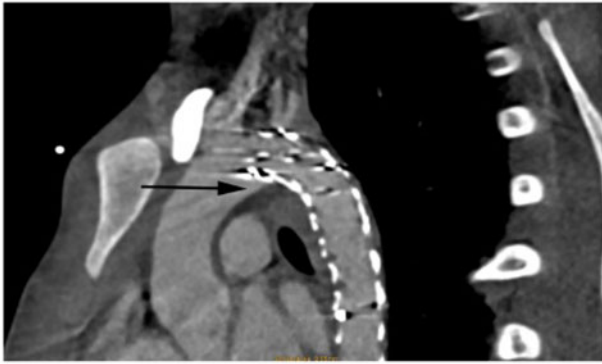


Figure 2: Result in Patient #2 showing a bird beak phenomenon (see black arrow). In that patient only one iliac extension was used to cover the blunt aortic injury.

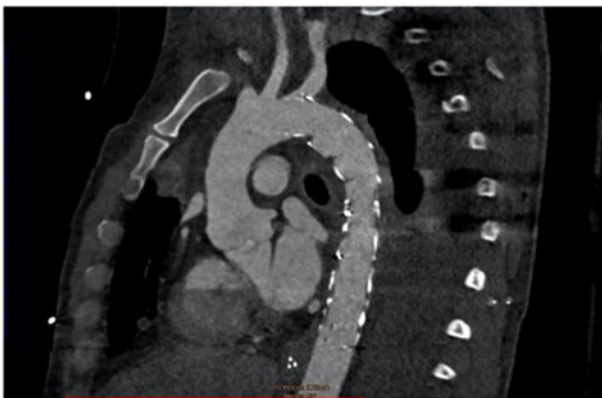


Figure 3: Result in Patient #5. In that patient iliac extension was used for distal sealing and afterwards thoracic endovascular aortic repair was implanted in zone.

Demographics

The age groups reported in larger institutional series of endovascular BAI treatments are considerably older than those in our retrospective series. Xenos *et al.* [5] report on 23 patient cohorts aged a mean 45.8 (SD: 4) years in patients undergoing endovascular therapy. Our cohort was 27.4 (SD: 13.1) years old, thereby reflecting the need to employ off-label iliac extension stents in what is a very young patient subgroup possessing the smallest aortic diameters. The smallest aortic diameter in the proximal landing zone was 18 mm and of the distal landing zone 13 mm. Summarized the mean diameter of the proximal landing zone was 20.9 mm (SD: 2.1) for the proximal landing zone and 16.5 mm (SD: 2.6) for the distal landing zone.

Technical aspects

The impact of heparin use when treating BAI is an ongoing controversy. Kenel-Pierre *et al.* [11] recently reported no differences in clinical outcomes for patients experiencing full, low or no heparin administration. We gave 2 patients a reduced heparin dose after having consulted with neurosurgeons, as most of our interventions took place before the aforementioned manuscript was published. We believe it will prove feasible to administer heparin

Table 4: Outcome—stent-graft sizing and adverse events

Patient	#1	#2	#3	#4	#5	#6	#7
Proximal oversizing (%)	16.7	11.1	20	14.3	23.8	5.3	21.8
Distal oversizing (%)	14.3	23.1	25	11.1	11.1	23.1	20
Endoleak	No	No	No	No	No	No	No
'Bird Beak' sign	No	Yes	No	No	No	No	No
Total length covered (mm)	120	82	150	120	135	100	165
Spinal cord ischaemia	No	No	No	No	Yes	No	No
Paraplegia	No	No	No	No	Yes	No	No
In-hospital death	No	No	Yes (×)	No	Yes (+)	No	No
Stroke	No	No	No	No	No	No	No
Days of intensive care unit	6	40	4	8	8	12	11
Total hospital stay	25	40	4	8	8	32	13
Vascular complications	No	No	No	No	No	No	No
Renal failure	No	No	No	No	No	No	No
Early reinterventions	No	No	No	No	No	No	No

× Death due to ischaemic brain injury 72 h after TEVAR.

+ Death due to liver failure 7 days after TEVAR.

TEVAR: thoracic endovascular repair.

even more restrictively to accommodate individual patients' clinical situations. The use of devices not designed for their use as a thoracic stent-graft implies numerous technical and clinical challenges, like the delivery system's short length and lack of de-airing options. Interestingly, although our delivery system lacks a de-airing option (like those available in delivery systems designed for the thoracic aorta), we detected no stroke or embolic events. Implantation was feasible in all patients despite the short length (only 57 cm) of the Medtronic iliac extension stent-graft device's delivery system shaft. However, this could be a problem in patients taller than our study's (ours were 176.4 ± 5.6 cm tall; the tallest measuring 180 cm).

The available stent-grafts are usually made for treating different aortic pathologies and are not focussed for healthy individuals. In our patient group, all patients had aorta smaller than 24 mm and the patients did not have any kind of aortic disease in the medical history. Treating such patients requires armamentarium of stent-grafts with smaller diameter. Therefore, we used the bailout solution with the iliac extensions which are implanted in as distal extensions during a standard EVAR procedure. Probably, developing smaller grafts for the thoracic aorta could be beneficial for such patients.

Recently, Berger *et al.* [12] showed that the aortic diameter is significantly reduced as compared with the aortic diameter at discharge in patients with BAI compared at discharge. We are aware of no scientific reports regarding the radial force of the self-expandable iliac stent-grafts and especially in the thoracic aorta.

Outcome

One patient presented a bird beak phenomenon at the proximal landing zone. He was the only patient to get an iliac extension stent-graft in the proximal landing zone within Ishimura zone 2, facilitated by carotid to subclavian artery bypass. This confirms our impression that iliac extensions are less suitable for proximal landing in the curved aorta. This is attributable to the proximal

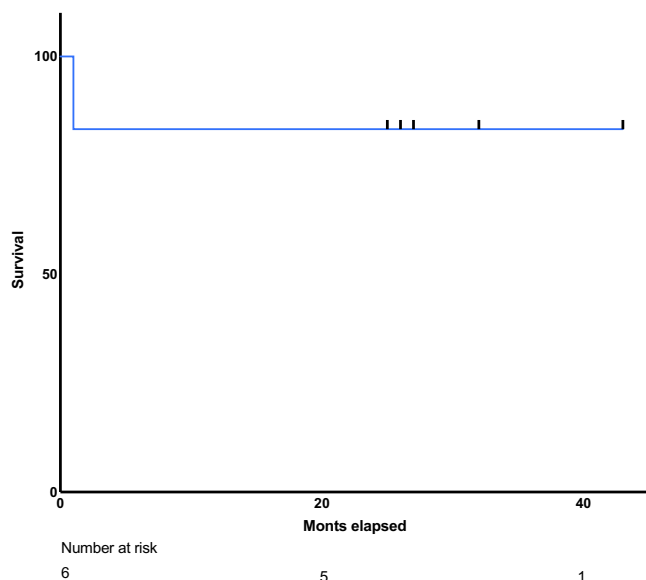


Figure 4: Kaplan–Meier analyse showing the overall survival in the group.

bare-spring design of iliac extension stent-grafts, which are designed as a stent-graft extension, rather as a stand-alone stent-graft. Therefore, our first choice for the proximal landing zone was to employ a thoracic stent-graft wherever possible. The iliac extension stent-graft was used for distal sealing in smaller aortic segments within the descending aorta. This was done before we implanted the proximal thoracic stent-graft within the larger proximal aortic segment.

Spinal cord injury was apparent in one patient after the thoracic stent-graft placement covering 135 mm of the thoracic aorta. This patient also presented with severe liver, spleen and cerebral bleeding that necessitated immediate surgery. He therefore underwent delayed TEVAR, and although the left subclavian artery was covered by the stent-grafts, carotid to subclavian artery bypass was unfeasible due to his critical medical condition and the drawback that he had needed such high heparin doses. His situation exemplifies the importance of left subclavian revascularization to prevent spinal cord ischaemia.

The endovascular treatment option for BAI is well described in the current literature. Endovascular repair has proven to result in reduced mortality for over 10 years, as well as less paraplegia and stroke than open surgical treatment of BAI [3]. This fact has recently been confirmed through longer follow-ups, although endovascularly treated patients also reveal higher reintervention rates. In our opinion, the use of iliac extensions for BAI in patients with a small aorta is a potentially beneficial approach. However, ours is a small cohort of only 7 patients and with short-term follow-up—a major study limitation. Our group's small size and the short-term follow-up might reflect a bias regarding the reliability of the iliac extension used in the descending aorta.

Follow-up

During the short-term follow-up reported in this analysis, no reintervention was needed, and none of the 6 surviving patients had suffered an endoleak by the time of their control CTA following extensive traumatic injuries. The reintervention rate until hospital discharge in a recent meta-analysis is around 5% [9]. The

absence of reinterventions in our cohort is obviously not meaningful due to our patient group's small size. However, the fact that our 6 survivors required no reintervention proves the feasibility and safety of our endovascular approach involving iliac extension stent-grafts.

Study limitations

This work is limited by the low number of patients and the heterogeneity of patients suffering from severe deceleration trauma associated with BAI. Aortic therapy often involving critical neurosurgical or emergent abdominal interventions therefore needs to be carefully considered and well-timed. We call attention to the fact that our aortic database unfortunately excludes BAI patients who died before they could undergo endovascular therapy. However, none of our patients died during endovascular treatment. As the consequences of these patients' additional injuries require urgent care, quick, efficacious surgical resolution of a BAI is likely to benefit their entire clinical course. Note that endovascular treatment's procedural time was under 2 h in all patients without carotid to subclavian artery bypass, and that 186 min was the longest procedural duration in a patient requiring carotid to subclavian artery bypass.

CONCLUSION

In conclusion, it remains challenging to successfully treat a small aorta that has suffered a blunt injury. Endovascular strategies involving the off-label use of iliac extension stent-grafts as the distal device in a 2-stent strategy are feasible and safe in young patients with a small aorta measuring <24 mm.

SUPPLEMENTARY MATERIAL

Supplementary material is available at *ICVTS* online.

Conflict of interest: Bartosz Rylski discloses proctoring fees from Terumo Aortic. Martin Czerny discloses Consulting Fees from Terumo Aortic, CryoLife, Medtronic, speaking fees from Bentley and Shareholdership from TEVAR Ltd.

Data availability statement

All relevant data are within the manuscript and its Supporting Information files.

Author contributions

David Schibilsky: Conceptualization; Formal analysis; Investigation; Visualization; Writing—original draft; Writing—review & editing. **Stoyan Kondov:** Formal analysis; Investigation; Writing—original draft; Writing—review & editing. **Roman Gottardi:** Conceptualization; Investigation; Writing—review & editing. **Maximilian Kreibich:** Conceptualization; Formal analysis; Investigation; Writing—review & editing. **Cornelius Lehane:** Formal analysis; Supervision; Writing—review & editing. **Tim Berger:** Investigation; Writing—review & editing. **Friedhelm Beyersdorf:** Conceptualization; Investigation; Supervision; Writing—review & editing. **Matthias Siepe:** Conceptualization; Investigation; Supervision; Writing—review & editing. **Martin Czerny:** Conceptualization; Investigation; Supervision; Writing—review & editing. **Bartosz Rylski:** Conceptualization; Data curation; Investigation; Supervision; Writing—original draft; Writing—review & editing.

Reviewer information

Interactive CardioVascular and Thoracic Surgery thanks Gokhan Arslan, Nikolaos Bonaros, Tomislav Kopjar and the other anonymous reviewer(s) for their contribution to the peer review process of this article.

REFERENCES

- [1] Clancy TV, Maxwell JG, Covington DL, Brinker CC, Blackman D. A state-wide analysis of level I and II trauma centers for patients with major injuries. *J Trauma* 2001;51:346–51.
- [2] Richens D, Field M, Neale M, Oakley C. The mechanism of injury in blunt traumatic rupture of the aorta. *Eur J Cardiothorac Surg* 2002;21:288–93.
- [3] Tang GL, Tehrani HY, Usman A, Katariya K, Otero C, Perez E *et al.* Reduced mortality, paraplegia, and stroke with stent graft repair of blunt aortic transections: a modern meta-analysis. *J Vasc Surg* 2008;47:671–5.
- [4] Hoffer EK, Forauer AR, Silas AM, Gemery JM. Endovascular stent-graft or open surgical repair for blunt thoracic aortic trauma: systematic review. *J Vasc Interv Radiol* 2008;19:1153–64.
- [5] Xenos ES, Minion DJ, Davenport DL, Hamdallah O, Abedi NN, Sorial EE *et al.* Endovascular versus open repair for descending thoracic aortic rupture: institutional experience and meta-analysis. *Eur J Cardiothorac Surg* 2009;35:282–6.
- [6] Rylski B, Desjardins B, Moser W, Bavaria JE, Milewski RK. Gender-related changes in aortic geometry throughout life. *Eur J Cardiothorac Surg* 2014;45:805–11.
- [7] Redheuil A, Yu W-C, Mousseaux E, Harouni AA, Kachenoura N, Wu CO *et al.* Age-related changes in aortic arch geometry relationship with proximal aortic function and left ventricular mass and remodeling. *J Am Coll Cardiol* 2011;58:1262–70.
- [8] O'Rourke M, Farnsworth A, O'Rourke J. Aortic dimensions and stiffness in normal adults. *JACC Cardiovasc Imaging* 2008;1:749–51.
- [9] Harky A, Bleetman D, Chan JSK, Eriksen P, Chaplin G, MacCarthy-Ofosu B *et al.* A systematic review and meta-analysis of endovascular versus open surgical repair for the traumatic ruptured thoracic aorta. *J Vasc Surg* 2020;71:270–82.
- [10] Styner JK. The birth of advanced trauma life support. *J Trauma Nurs* 2006;13:41–4.
- [11] Kenel-Pierre S, Ramos Duran E, Abi-Chaker A, Melendez F, Alghamdi H, Bornak A *et al.* The role of heparin in endovascular repair of blunt thoracic aortic injury. *J Vasc Surg* 2019;70:1809–15.
- [12] Berger T, Voetsch A, Alaloh D, Kreibich M, Kromholz-Reindl P, Winkler A *et al.* Diameter changes in traumatic aortic injury: implications for Stent-Graft sizing. *Thorac Cardiovasc Surg* 2020. <https://doi.org/10.1055/s-0040-1713425>.