

CASE REPORT

Dens invaginatus (dilated odontome) in mandibular canine

Sangamesh S Halawar, Satyakiran GVV, Krishnanand PS, Prashanth R*Department of Oral and Maxillofacial Pathology, Krishnadevaraya College of Dental Sciences, Bangalore, Karnataka, India***Address for correspondence:**

Dr. G. V. V Satyakiran,
Post Graduate Student, Department of Oral
and Maxillofacial Pathology, Krishnadevaraya
College of Dental Sciences, Sir MVIT Campus,
Off International Airport Road,
Hunasamaranahalli via Yelahanka,
Bangalore - 562 157, Karnataka, India.
E-mail: kirangadavalli@gmail.com

Received: 01-09-2014

Accepted: 09-09-2014

ABSTRACT

Dens invaginatus is a developmental malformation of teeth related to shape of the teeth. Affected teeth show a deep infolding of enamel and dentin starting from the tip of the cusps and may extend deep into the root. It results from the invagination of the enamel organ into the dental papilla before calcification has occurred. Teeth most affected are maxillary lateral incisors. The presence of dens invaginatus in mandibular canine is extremely rare. The tooth was symptomatic in that it was mobile and was oriented horizontally. This article presents a case of symptomatic dens invaginatus in mandibular canine.

Key words: Dens in dente, dilated composite odontome, mandibular canine**INTRODUCTION**

Dens invaginatus (DI) is a developmental anomaly resulting from the invaginations of the coronary or root surface of the enamel organ into dental papilla before calcification occurs.^[1-4]

This anomaly was first described by Ploquet in 1794 in a whale's tooth. It was subsequently described by Socrates in human tooth in 1856.^[5] In 1873 Mühl Reiter reported on 'anomalous cavities in human teeth', Baume in 1874 and Busch in 1897 published on this malformation.^[1,2]

Diverse synonyms given to this anomaly and reason for which it is called so [Table 1]. The most appropriate term to use would be 'dens invaginatus' as it reflects the infolding of the outer portion (enamel) into the inner portion (dentin) with the formation of a pocket and dead space.^[1,2]

Depending upon the degree of invagination, Oehlers FA (1957) has classified Dens-in-dente as^[5]

- Type I: Invagination confined to crown
- Type II: Invagination extending beyond cemento-enamel junction (CEJ). Large invaginations may become dilated and contain dystrophic enamel in the base of dilation
- Type III: Invagination extending beyond CEJ penetrating

the root and exhibiting a second foramina in the apical third.

The prevalence of DI ranges from 0.04-10%.^[2]

The study conducted by Cakici *et al.*, (2010) in a sample size of 1012. Full-mouth surveys concluded that the frequency of DI was 1.3% and most commonly observed was type I DI (81.25%).^[2]

Authors have put forth various theories to describe the etiology of this anomaly [Table 2]. Most authors, meanwhile consider DI as a deep folding of the foramen cecum (or may start from incisal edge of the tooth) during tooth development which in some cases may result in a second apical foramen (Schulze, 1970). Generic factors cannot be excluded. (Grahnen, 1962, Casamassimo *et al.*, 1975, Ireland *et al.*, 1987, Hosey and Bedi, 1996).^[6]

The teeth most affected are permanent maxillary lateral incisors followed by maxillary central incisors, premolars, canines and less frequently in the molars. Bilateral occurrence is not uncommon and occurs in 43% of all cases. The posterior teeth are less likely to be affected. The female to male predilection is 3:1.^[2,9,10]

Here we present a case of unilateral type 2 dens-in-dente in the mandibular canine. The tooth was mobile and was oriented horizontally, thus being symptomatic.

CASE REPORT

A 53-year-old female patient reported to our outpatient department seeking treatment for her mobile tooth. No other abnormalities were noted.

Access this article online**Quick Response Code:****Website:**www.jomfp.in**DOI:**

10.4103/0973-029X.141379

Table 1: Synonyms for Dens invaginatus^[1,2,5]

Synonyms	Who	Why
Dens in dente	Busch <i>et al.</i> , 1897	Radiographic appearance of tooth within the tooth
Invaginated odontome		Invagination of outer portion of enamel into the inner dentinal portion
Dilated composite odontome	Hunter, 1951	Abnormal dilation of dental papilla
Dilated odontome	Oehlers FA, 1957	The invagination becomes dilated and disturbs the formation of tooth. The name may not be appropriate in cases where there is no dilation
Gestant anomaly	Colby, 1956	Since the tooth looks like it is pregnant

On clinical examination, Extra-oral findings were unremarkable.

Intra oral examination showed grade III mobility *Interim restorative treatment (IRT)* to 43 (Right mandibular canine), spacing between 43 and 44 and horizontal orientation of 43.

Radiographic examination revealed well circumscribed radiopaque – radiolucent mass, surrounded by a zone of radiolucency and a sclerotic border separating the basal bone in the region of 43 [Figure 1]. The tooth was extracted under local anesthesia and subjected to histopathological examination.

Grossing

On grossing, a hard tissue tooth specimen measuring 2.5×2 cm, creamish white in color, oval in shape was obtained. The specimen showed a smooth outline of crown and root of a canine tooth labially. Lingually, the tooth looked dilated in mesiodistal direction starting from cingulum till the root apex with an irregular surface [Figure 2a-c].

The specimen was cut into two equal halves in labio-lingual direction using metal disc, The cut specimen revealed dilated central core containing amorphous debris. The invagination seemed to have encroached the pulpal space which has been reduced to slit like spaces around the invagination. (Somaes and sothoum) [Figure 3].

One half of the specimen was taken for ground section and the other was subjected to decalcification and routine processing.

Ground section

Examination of the ground section under the microscope revealed a dilated tooth specimen [Figure 4a] with an outer and inner layer of enamel. The dentin between the two zones was normal [Figure 4b]. The dilation extended from the cingulum

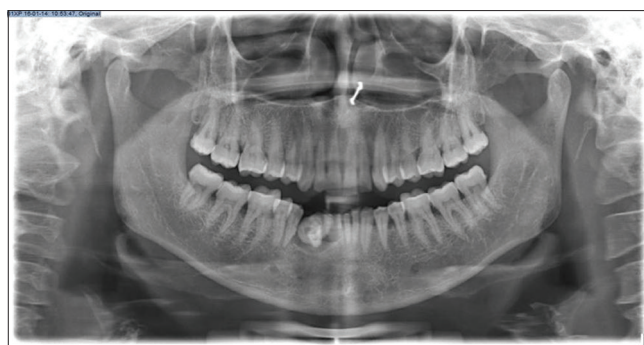


Figure 1: Orthopantomogram reveals well circumscribed radiopaque – radiolucent mass, surrounded by a zone of radiolucency and a sclerotic border separating the basal bone in the region of 43

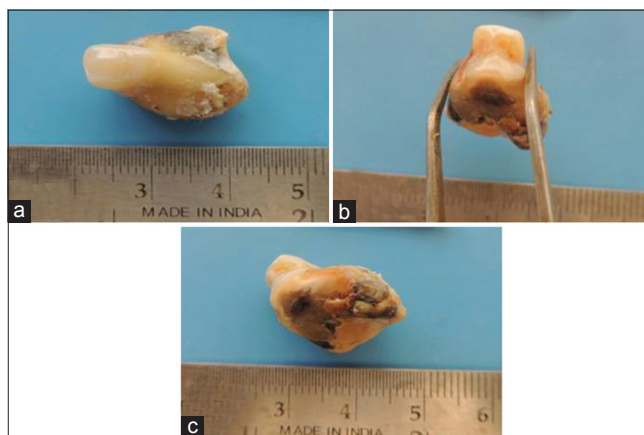

Figure 2: Grossing specimen of the hard tooth specimen showing (a) Labial surface (b) Incisal surface (c) Lingual surface

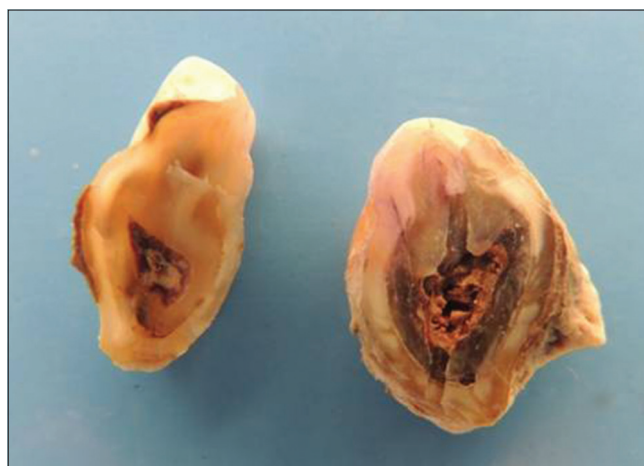

Figure 3: Gross specimen cut into two halves in labio-lingual direction. The cut specimen show central core containing amorphous debris

area to the apical one third of the root. No communication with the periapical region was detected. The area of dilation which was previously occupied by amorphous debris, before ground sectioning, was lost. The base of the dilation was lined by both enamel and cellular cementum [Figure 4c]. On either side of the dilation, pulpal space was appreciated surrounded by well-formed dentin with dentinal tubules. The

Table 2: Theories proposed to describe the etiology of dens invaginatus^[1,2,7,8]

Name	Year	Reason
Kronfeld	1934	Failure in growth of the internal dental epithelium
Fischer and Sprawson	1936 and 1937	Infection was considered to be responsible for the malformation
Rushton	1937	A result of rapid and aggressive proliferation of a part of the internal enamel epithelium invading the dental papilla
Oehlers	1957	Considered that the distortion of the enamel organ during tooth development and the subsequent protrusion of a part of enamel organ into dental papilla was the cause
Euler and Atkinson	1939	Growth pressure from the adjacent tooth germs leads to buckling of the enamel organ
Bruszt	1950	“twin-theory” suggested a fusion of two tooth-germs
Gustafson and Sundberg	1950	Trauma as a causative factor
Dassule <i>et al.</i>	2000	Caused due to absence of certain intercellular signals during tooth development
Grahnen, Casamassimo <i>et al.</i> , Ireland <i>et al.</i> , Hosey and Bedi	1962, 1978, 1987, 1996 respectively	Genetic factors, supported by a case lacking chromosome 7q32 and the studies that show occurrence of the condition in parents and siblings

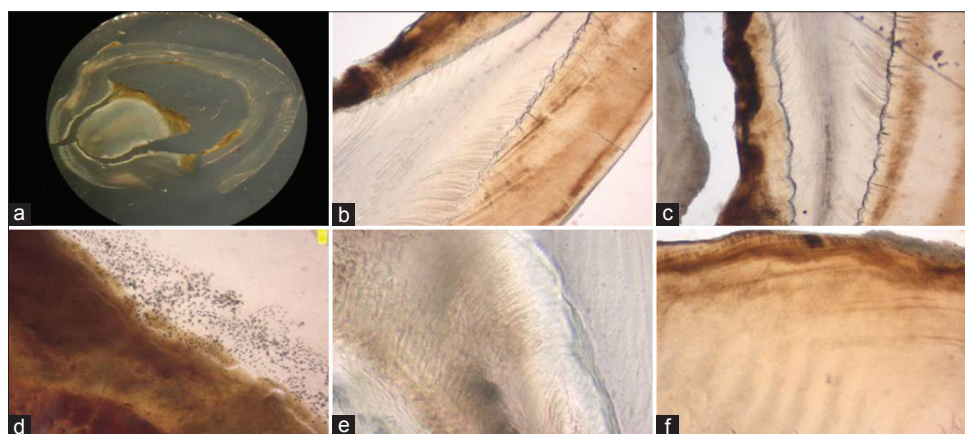


Figure 4: (a) Ground section shows a central dilated area with dentin surrounded by pulp space (b and c): Ground section revealed an outer layer of enamel with incremental lines of Retzius, enamel lamellae and well formed DEJ around the central space. The inner wall of the dilation has haphazardly arranged amorphous material and lacked any incremental lines with dentin between the two layers (x100) (d) Ground section showing dilated space lined by both cellular cementum and enamel (x200) (e) Ground section revealing outer layer of enamel showing fish scale pattern (x400) (f) The inner layer of enamel without DEJ

outer enamel was well- formed with incremental lines, enamel spindles, enamel lamellae and fish scale pattern of enamel was observed [Figure 4c and e]. A well formed dentino-enamel junction could also be appreciated. The enamel that lined the dilated space was amorphous. Most of the inner enamel did not reveal any incremental lines. The lining of the enamel close to the cingulum showed dentino-enamel junction (DEJ), but as it approached the root apex the DEJ distinguishing enamel and dentin was not appreciated [Figure 4f].

Decalcified section

Examination of the hematoxylin and eosin (H and E) section under microscope revealed dentin made up of several dentinal tubules in cross section [Figure 5a] and invaginated portion of the tooth lined by dentin [Figure 5b]. Focal areas show cementodentinal junction with clear dentin and acellular cementum on the other sides [Figure 5b]. Focal

areas of pulpal spaces surrounded by dentin were also evident [Figure 5d].

Based on the above ground section features along with decalcified sections a diagnosis of type 2 dens-in-dente was given.

DISCUSSION

DI is a developmental malformation of teeth. Affected teeth show deep infolding of enamel and dentin starting from the tip of the cusps or incisal edges and which may extend deep into the root. Which was seen in our case. The prevalence of DI ranges from 0.04-10%.

Clinically, a morphologic alteration of the crown (dilated, peg-shaped, barrel-shaped) or a deep foramen cecum can serve as an indication for the diagnosis of DI.^[11] But, most cases of DI are detected after a routine radiographic evaluation

with a panoramic X-ray and confirmed with a periapical film.^[6,11] Upon detection of DI in one tooth the contralateral tooth should also be examined as bilateral occurrence of this anomaly have been reported.^[1,2]

Classification of dens invaginatus^[1,2,12]

DI has been classified into the following types according to the depth of the invagination and the degree of communication with the periodontal ligament or the periradicular tissue [Figure 6].

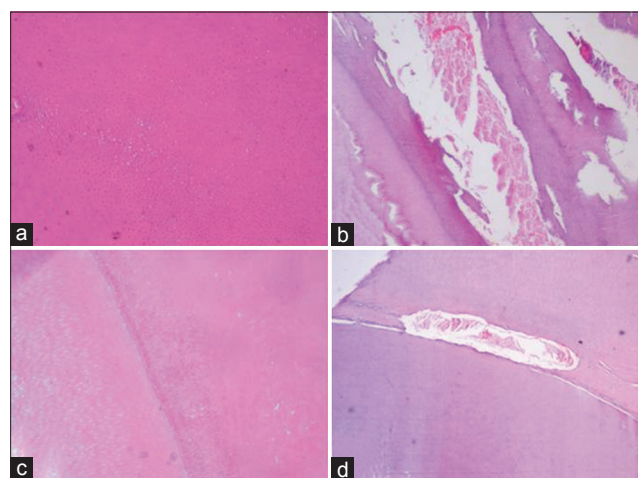


Figure 5: (a) Decalcified section revealed dentin made up of several dentinal tubules in cross section (H&E, x200) (b) Decalcified section showing areas of enamel covering dentin on ether sides and invagination of the enamel in the central area (H&E, x100) (c) Decalcified section showing focal areas of cementodentinal junction with clear dentin and acellular cementum on the ether sides (H&E, x100) (d) Decalcified section showing focal areas of pulpal spaces surrounded by dentin (H&E, x100)

Type I: An enamel-lined invagination occurring within the confines of the crown not extending beyond the cemento-enamel junction.

Type II: An enamel-lined form which invades the root but remains confined as a blind sac. It may or may not communicate with the dental pulp.

Type III A: A form which penetrates through the root and communicates laterally with the periodontal ligament space through a pseudo-foramen. There is usually no communication with the pulp, which lies compressed within the root.

Type III B: A form which penetrates through the root, perforating at the apical area through a pseudoforamen. The invagination may be completely lined by enamel, but frequently cementum will be found lining the invagination.

Bhaskar describes two variations of DI as Coronal type and Radicular type.

The Coronal type is caused by an invagination of all layers of the enamel organ into the dental papilla. The pulp is usually exposed and becomes necrotic or inflamed. Not infrequently, periapical lesions are associated with this type, necessitating endodontic therapy.

In the Radicular type of DI there is a folding of Hertwig's sheath into the developing root, much like the coronal type. Associated pulpal necrosis and apical lesions are often noticed.^[6]

Our case belongs to the Coronal type in which the enamel organ contents were seen extending into the root, but there was no pulp exposure. But tooth was symptomatic.

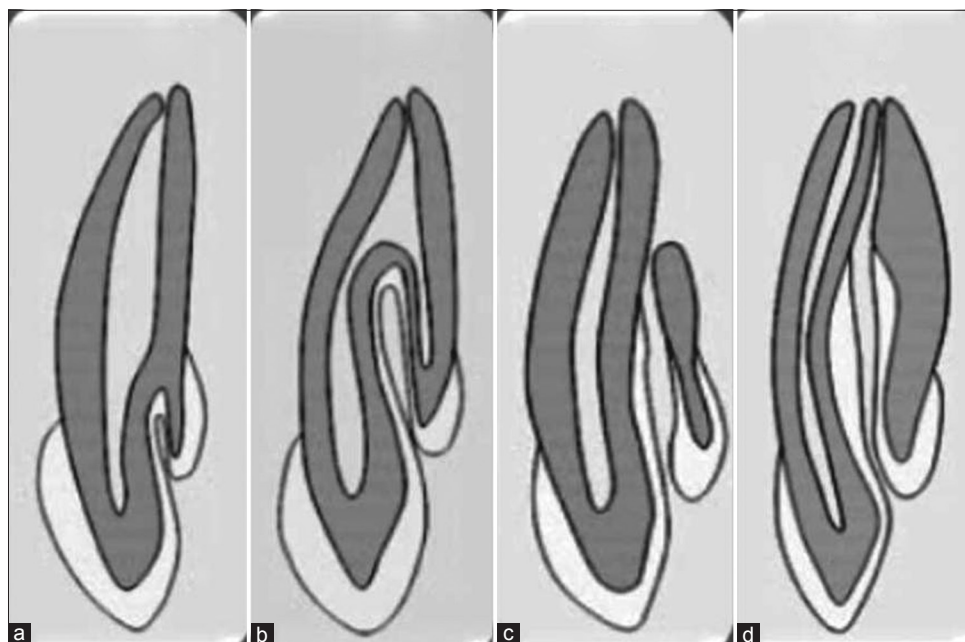


Figure 6: (a) Schematic diagrams of Dens invaginatus : Type I, (b) Dens invaginatus: Type II, (c) Dens invaginatus: Type II, (d) Dens invaginatus: Type III

Radiographic features^[1,2,11,13,14]

A radiopaque invagination, the density of which is equal to enamel can be seen extending from the coronal portion of the tooth usually the cingulum into the root canal. The invagination may vary in size and shape from being slightly radiolucent to loop-like to pear shaped to a dilated uniglobular mass. This invagination may end in coronal portion (Oehler's type I) extends into the root without any communication with the pulp (Oehler's type II) or may extend deep into the root canal opening through a lateral canal into the periapical region (Oehler's type III). The roots of the affected tooth may present smaller dimensions.

Histological findings^[1,2]

The enamel lining the invagination is continuous with that of the enamel lining the external surface. It is often defective and is poorly mineralized or absent in the areas particularly near the bottom of the cavity (Soames and Southam). The structure and thickness of the enamel lining the invagination also may vary widely. The enamel was described as irregularly structured by Atkinson (1943), Beynon (1982) and Piatelli and Trisi (1993). Beynon (1982) reported hypomineralized enamel at the base of the invagination whereas Morfis (1992), in a chemical analysis, detected up to eight times more phosphate and calcium with absence of magnesium when compared with the outer enamel. Bloch-Zupan *et al.*, (1995) found differences in structure and composition between the external and internal enamel. The internal enamel exhibited atypical and more complex rod shapes and its surface presented the typical honeycomb pattern but no perikymata, which, however, were observed on the outer surface of the tooth.

The dentin below the invagination may be intact without irregularities (Brabant and Klees 1956, Omnell *et al.*, 1960, Piatelli and Trisi, 1993) but also may contain strains of vital connective tissue (Omnell *et al.*, 1960) or even fine canals with communication to the dental pulp (Kronfeld 1934, Fischer 1936, Hoepfel 1936, Gustafson and Sundberg 1950, Hitchin and McHugh 1954, Oehlers 1957a, Rushton 1958). Some authors reported hypomineralized or irregularly structured dentine (Omnell *et al.*, 1960, Vincent-Townend, 1974, Beynon, 1982).

As the invagination impinges upon the pulp cavity the latter may be reduced to slit-like spaces around the sides of the invagination.

Clinical implication

The most significant clinical concern of DI is the risk of developing pulpal pathology. The invagination commonly communicates with the oral cavity, allowing the entry of irritants and microorganisms into the pulpal tissue which

is separated by only a thin layer of enamel and dentin that may be hypomineralized.^[7] This defect predisposes a tooth to dental caries and to subsequent pulpal pathologies.

Sometimes fine canals extend between the invagination and the pulp chamber, resulting in pulpal and periapical pathology even in the absence of dental caries.^[1]

Upon radiographic evidence of DI, the apical periodontium should be examined because fine channels or cracks may run between the invagination and the pulp microorganisms may pass from oral cavity through DI into the pulp.^[15]

Dental anomalies described in association with DI are microdontia, macrodontia, hypodontia, oligodontia, taurodontism, gemination and fusion, supernumerary teeth, dentinogenesis imperfecta,^[15] amelogenesis imperfecta, invagination in an odontome, multiple odontomes, coronal agenesis, and Williams syndrome, dens evaginatus, talon's cusp, short roots.^[13,16]

Syndromic association of DI has been reported in Ekman-Westborg-Julin syndrome, Williams syndrome and Nance Huran syndrome.^[9]

Treatment^[5,17-21]

Clinical management of these anomalies varies from case to case and is related to the degree of complexity of anatomy of the tooth. Treatment of DI ranges from conservative restoration of the opening to non-surgical endodontic treatment, endodontic surgery, intentional replantation, and finally extraction. Large and extremely dilated invaginations often have abnormal crowns and need to be extracted.

In cases in which there is an immature apex, the use of calcium hydroxide inside the root canal has been proposed to stimulate apexification.

REFERENCES

1. Hulsmann M. Dens invaginatus: Aetiology, classification, prevalence, diagnosis, and treatment considerations. *Int Endod J* 1997;30:79-90.
2. Munir B, Tirmazi SM, Majeed HA, Khan AM, Iqbalbangash N. Dens invaginatus: Aetiology, classification, prevalence, diagnosis and treatment considerations. *Pakistan Oral Dent J* 2011;31:191-8.
3. Rakes GM, Aiello AS, Kuster GC, Labart WA. Complications occurring resultant to dens invaginatus: Case report. *Pediatr Dent* 1988;10:53-6.
4. Sousa Neto MD, Zuccolotto WG, Saquy PC, Grandini SA, Pécora JD. Treatment of dens invaginatus in a maxillary canine case report. *Braz Dent J* 1991;2:147-50.
5. Neville BW. Abnormalities of teeth. In: Neville B, Damm DD, Allen CM, Bouquot J, editors. *Oral and Maxillofacial Pathology*. 2nd ed. Philadelphia: W.B. Saunders; 2002. p. 80-2.
6. Sisodia S, Maria R, Maria A. Dens invaginatus: A review and

- case report. Endodontology. Available from: <http://medind.nic.in/eea/t10/i2/eaat10i2p73.pdf>.
7. Pradeep K, Charlie M, Kuttappa MA, Rao PK. Conservative management of type III dens in dente using cone beam computed tomography. *J Clin Imaging Sci* 2012;2:51.
 8. Khanna S, Purwar A, Gulati R, Sharma D. Concurrence of dens invaginatus and evaginatus involving all maxillary anteriors: A rare case with comprehensive review. *IOSR J Dent Med Sci* 2013;6:59-62.
 9. Kallianpur S, Sudheendra S, Kasetty S, Joshi P. Dens invaginatus (Type III B). *J Oral Maxillofac Pathol* 2012;16:262-5.
 10. Jaramillo A, Fernández R, Villa P. Endodontic treatment of dens invaginatus: A 5-year follow-up. *Oral Surg Oral Med Oral Pathol Oral Radiol Endod* 2006;101:e15-21.
 11. Alani A, Bishop K. Dens invaginatus. Part 1: Classification, prevalence and aetiology. *Int Endod J* 2008;41:1123-36.
 12. Oehlers FA. Dens invaginatus. I. Variations of the invagination process and associated anterior crown forms. *Oral Surg Oral Med Oral Pathol* 1957;10:1204-18.
 13. Bansal AV, Bansal A, Kulkarni VK, Dhar RS. Dens invaginatus in primary maxillary molar: A rare case report and review of literature. *Int J Clin Pediatr Dent* 2012;5:139-41.
 14. White SC, Pharoah MJ. Oral radiology principles and interpretation. 4th ed. St Louis: Mosby; 2000. p. 314-5.
 15. Zengin AZ, Sumer AP, Celenk P. Double dens invaginatus: Report of three cases. *Eur J Dent* 2009;3:67-70.
 16. Das A, Sivakumar K. A case of dens in dente in maxillary lateral incisor. *J Indian Acad Dent Specialists* 2010;1:47-8.
 17. Yadav M, Meghana SM, Kulkarni SR. Concomitant occurrence of dens invaginatus and talon cusp: A case report. *Rev Odonto Cienc* 2011;26:187-90.
 18. Tagger M. Nonsurgical endodontic therapy of tooth invagination. Report of a case. *Oral Surg Oral Med Oral Pathol* 1977;43:124-9.
 19. Neves FS, Bastos LC, de Almeida MS, Bóscolo NF, Haiter-Neto F, Campos PS. Dens invaginatus: A cone beam computed tomography case report. *J Health Sci Inst* 2010;28:249-50.
 20. Szajkis S, Kaufman AY. Root invagination treatment: A conservative approach in endodontics. *J Endod* 1993;19:576-8.
 21. Ferguson FS, Friedman S, Frazetto V. Successful apexification technique in an immature tooth with dens in dente. *Oral Surg Oral Med Oral Pathol* 1980;49:356-9.

How to cite this article: Halawar SS, Satyakiran G, Krishnanand PS, Prashanth R. Dens invaginatus (dilated odontome) in mandibular canine. *J Oral Maxillofac Pathol* 2014;18:157-62.

Source of Support: Nil. **Conflict of Interest:** None declared.