

Multiple Tracheobronchial Polyposis Caused by Tracheobronchopathia Osteochondroplastica

Keigo Uchimura¹, Kei Yamasaki¹, Kazuhiro Yatera¹, Aya Nawata²,
Hiroshi Ishimoto¹ and Hiroshi Mukae¹

Abstract

Tracheobronchopathia osteochondroplastica (TO) is a rare benign airway disease that is characterized by the presence of multiple rock-garden-like nodules on bronchoscopy. TO is a slowly progressive disease of the trachea and major bronchi, which is typically characterized by such symptoms as a persistent nonproductive cough, dyspnea and wheezing. The clinical features of TO are variable, and asymptomatic patients may incidentally be diagnosed during the work-up for other diseases. We herein report a rare case of TO accompanying multiple tracheobronchial polyposis in which bronchoscopic resection of the airway polyp using a high-frequency snare was successfully performed.

Key words: tracheobronchopathia osteochondroplastica, polyposis, bronchoscopy, high-frequency snare

(Intern Med 55: 3165-3167, 2016)

(DOI: 10.2169/internalmedicine.55.6774)

Introduction

Tracheobronchopathia osteochondroplastica (TO) is a rare benign airway disease typically characterized by the presence of multiple rock-garden-like nodules in the lower trachea and upper main bronchi (1). Because of the absence of cartilage in this region of the airway, these nodules involve the anterior and lateral walls of the trachea and the bronchus, sparing the posterior membranous wall (2). Several reported cases have demonstrated successful surgical intervention and bronchoscopic laser therapy for advanced symptomatic patients (2, 3). We herein report the successful bronchoscopic resection of a symptomatic localized polyp due to TO using a high-frequency snare.

Case Report

An 80-year-old Japanese man was admitted to our hospital for the evaluation and management of multiple tracheobronchial polyposis and right middle lobe atelectasis. He had a history of polyarteritis nodosa and had been treated with corticosteroids (prednisolone 6 mg/day). Chest

computed tomography (CT) revealed diffuse calcified lesions throughout the cartilaginous regions of the trachea and bronchi, right middle atelectasis, and airway polyps (4-9 mm) in the left trachea and the left main bronchus (Fig. 1). The bronchoscopic findings showed diffuse edematous mucosal lesions with polyposis on the left side of the trachea, the right middle bronchus and the left main bronchus (Fig. 2). A spirometric analysis demonstrated an obstructive impairment, and the forced expiratory volume in one second (FEV₁) was 1.36 L, and FEV₁% was 43%. A transbronchial biopsy to make a diagnosis of the airway polyp was performed, and endoscopic mucosal resection was also carried out using a high-frequency snare to improve ventilatory insufficiency. TO was pathologically confirmed in the resected submucosal cartilaginous tissue, and mature ossifications were also observed in the tissue (Fig. 3). After resecting the airway polyp, the spirometric data of the FEV₁ and FEV₁% improved from 1.36 L to 1.69 L and from 43% to 93%, respectively.

Discussion

The comprehensive etiology of TO remains to be eluci-

¹Department of Respiratory Medicine, University of Occupational and Environmental Health, Japan and ²Department of Pathology and Cell Biology, University of Occupational and Environmental Health, Japan

Received for publication October 31, 2015; Accepted for publication May 9, 2016

Correspondence to Dr. Kei Yamasaki, yamasaki@med.uoeh-u.ac.jp

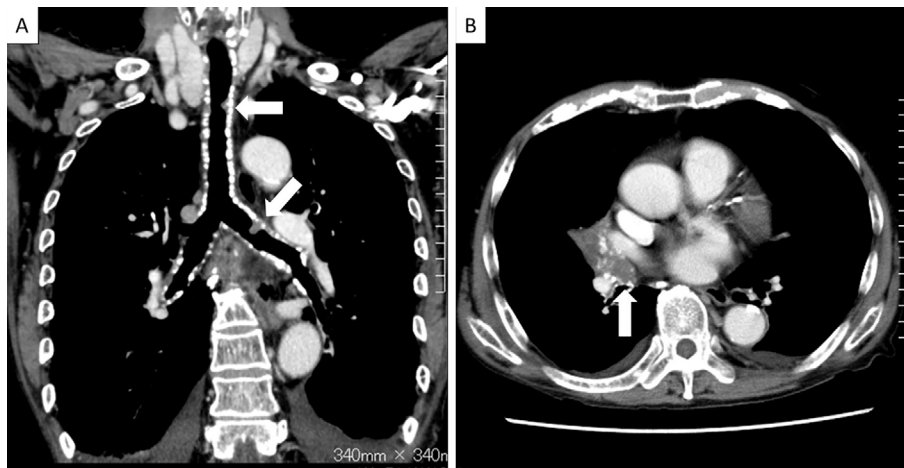


Figure 1. Chest computed tomography (CT) of this patient. A: A coronal view of the chest mediastinal window shows diffuse calcified lesions throughout the cartilaginous regions of the trachea and bilateral bronchi. Noncalcified endobronchial airway polyps are also seen on the left side of the trachea and the upper side of the left main bronchus (white arrows). B: A transverse view of the chest mediastinal window demonstrates right middle lobe atelectasis and an endobronchial airway polyp with small calcified lesions (white arrow) in the right middle lobe bronchus.

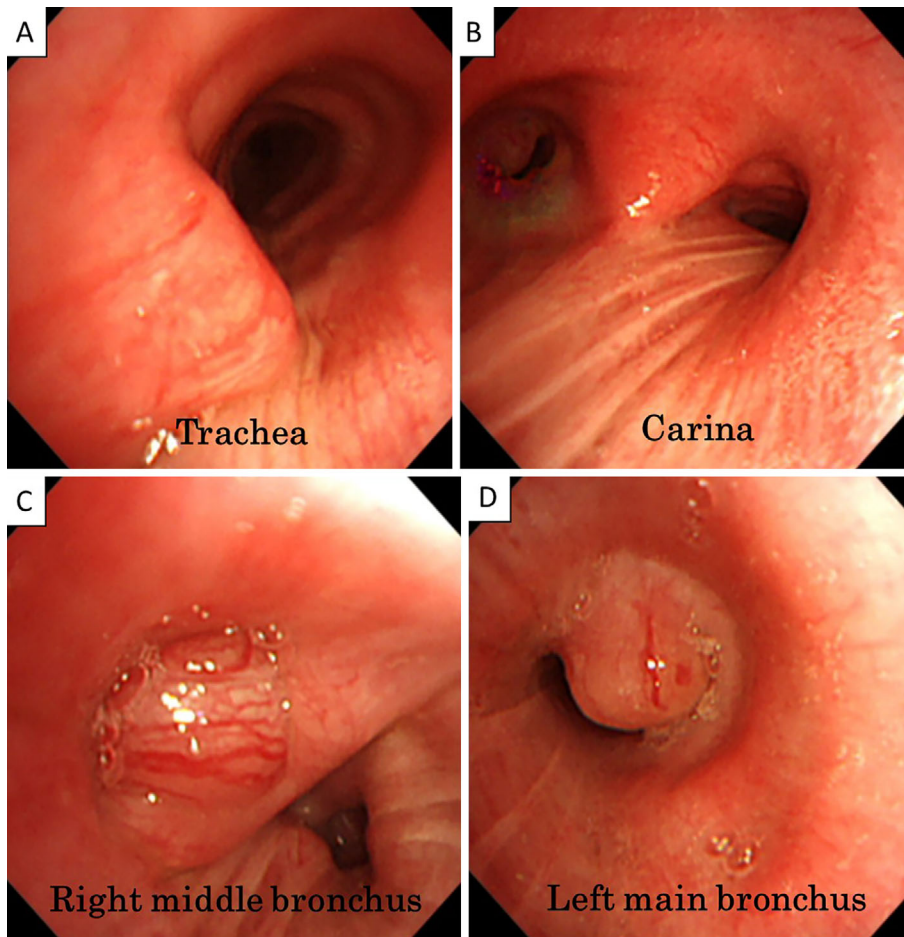


Figure 2. Endobronchial findings of this patient. There are no remarkable abnormal findings in the trachea (A) and carina (B), however, bronchoscopy showed a diffuse edematous mucosa with polypoid changes in the trachea (A), carina (B), right middle bronchus (C) and left main bronchus (D).

dated, however, chronic airway infections, irritant exposure, several metabolic disorders and genetic factors have been proposed to be causative factors of TO (3, 4).

This patient showed typical chest CT findings (Fig. 1) and unusual bronchoscopic features (Fig. 2) of TO in that a large polyp was observed. Long-term corticosteroid admin-

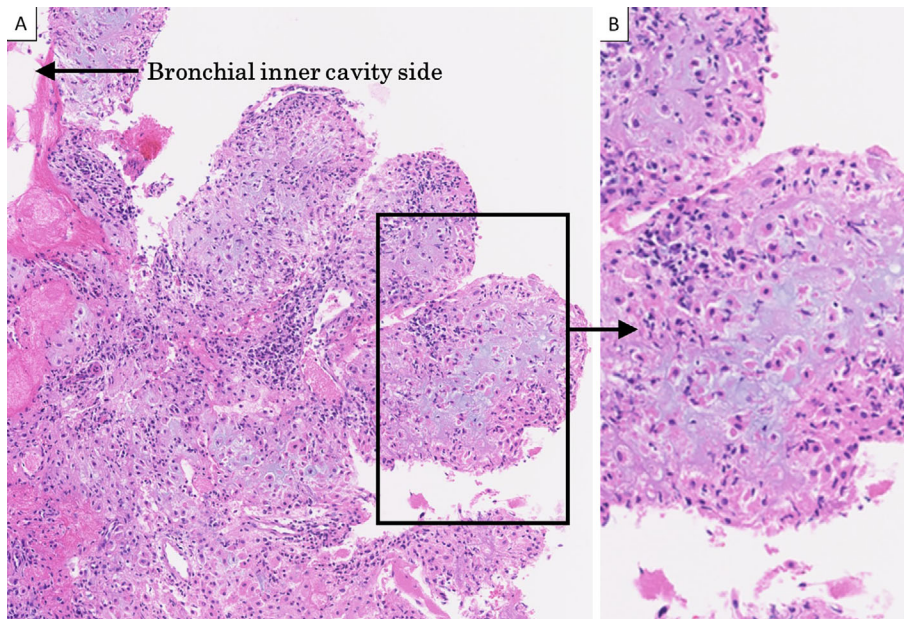


Figure 3. Histopathological findings of the airway polyp. **A:** An endobronchial polyp lesion obtained from the left main bronchus demonstrated submucosal calcification, ossification and cartilage formation surrounded by chronic airway inflammatory cells. **B:** An enlarged view shows the polyp lesion to consist of submucosal ossification and inflammatory cells.

istration might be a potential explanation for the atypical bronchoscopic findings. Tajima et al. reported that bone morphogenetic protein-2 (BMP-2) played an important role in nodule formation and might synergistically act with transforming growth factor β 1 (TGF-1) to promote an inductive cascade of TO nodules (5). The airway polyp in our patient did not include mature ossifications in contrast to the previously reported cases (2, 4), and the long-term corticosteroid administration in this patient might be related to these pathological atypical findings, such as the suppression of calcified lesion formation. However, there has so far been no report describing the effects of corticosteroids on initiating and enlarging airway polyp formation; thus, further studies are necessary to clarify the mechanism of airway polyp formation and effective treatment.

Ying et al. reported that chronic airway inflammation might be an important factor in the formation of TO, and they discussed the potential clinical effects of inhaled corticosteroids to improve the symptoms in patients in the early stage of this disease (3). However, the authors did not discuss airway polyps. No guidelines have yet been established for the management of TO, and systemic or inhaled corticosteroid treatment might be one of treatment choices for TO without any problematic clinical symptoms, as seen in the present patient.

In conclusion, we herein reported a rare case of TO accompanied by unusual bronchoscopic features, such as multiple tracheobronchial polyposis, which was successfully treated using a high-frequency snare. TO is a benign disorder,

however, TO may cause various clinical symptoms and spirometric impairments that necessitate the resection of airway polyps. Physicians should therefore be aware of this disease and its clinical symptoms and include it in the differential diagnosis.

The authors state that they have no Conflict of Interest (COI).

References

1. Prakash U. Tracheobronchopathia osteochondroplastica. *Semin Respir Crit Care Med* **23**: 167-175, 2002.
2. Abu-Hijleh M, Lee D, Braman SS. Tracheobronchopathia osteochondroplastica: a rare large airway disorder. *Lung* **186**: 353-359, 2008.
3. Zhu Y, Wu N, Huang HD, et al. A clinical study of tracheobronchopathia osteochondroplastica: findings from a large Chinese cohort. *PLoS ONE* **9**: e102068, 2014.
4. Danckers M, Raad RA, Zamuco R, Pollack A, Rickert S, Caplan-Shaw C. A complication of tracheobronchopathia osteochondroplastica presenting as acute hypercapnic respiratory failure. *Am J Case Rep* **16**: 45-49, 2015.
5. Tajima K, Yamakawa M, Katagiri T, Sasaki H. Immunohistochemical detection of bone morphogenetic protein-2 and transforming growth factor beta-1 in tracheopathia osteochondroplastica. *Virchows Arch* **431**: 359-363, 1997.

The Internal Medicine is an Open Access article distributed under the Creative Commons Attribution-NonCommercial-NoDerivatives 4.0 International License. To view the details of this license, please visit (<https://creativecommons.org/licenses/by-nc-nd/4.0/>).