

Optical Coherence Tomography Angiography Findings in Ocular Toxoplasmosis with Multiple Recurrences

Ovi Sofia ^{1,2}, I Nyoman Surya Ari Wahyudi ³, Loeki Enggar Fitri ⁴, Seskoati Prayitnaningsih², Hani Susianti⁵

¹Doctoral Program in Medical Science, Faculty of Medicine, Universitas Brawijaya, Malang, Indonesia; ²Department of Ophthalmology, Faculty of Medicine, Universitas Brawijaya, Dr. Saiful Anwar General Hospital, Malang, Indonesia; ³Residency Training Program, Department of Ophthalmology, Faculty of Medicine, Universitas Brawijaya, Dr. Saiful Anwar General Hospital, Malang, Indonesia; ⁴Department of Clinical Parasitology, Faculty of Medicine, Universitas Brawijaya, Dr. Saiful Anwar General Hospital, Malang, Indonesia; ⁵Department of Clinical Pathology, Faculty of Medicine, Universitas Brawijaya, Dr. Saiful Anwar General Hospital, Malang, Indonesia

Correspondence: Loeki Enggar Fitri, Department of Clinical Parasitology, Faculty of Medicine, Universitas Brawijaya, Dr. Saiful Anwar General Hospital, Malang, Indonesia, Email lukief@ub.ac.id

Abstract: Ocular toxoplasmosis is the most common cause of posterior uveitis that is caused by *Toxoplasma gondii* infection. Humans can be infected congenitally or postnatally. The typical lesion of ocular toxoplasmosis is focal necrotizing retinitis with overlying vitritis, which lead to hyperpigmented retinochoroidal scar at resolution of lesion. Macula involvement can cause substantial visual impairment. The high incidence of disease reactivation may lead to greater risk of vision loss. Optical coherence tomography angiography (OCTA) is a non-invasive imaging method to visualize the vascular and density perfusion of the retina and choroid, which cannot be obtained by conventional Optical Coherence Tomography (OCT). In this case report, we present two cases of active ocular toxoplasmosis with multiple recurrences to study pathological changes in retinal and choroidal microvasculature. The findings reveal the involvement of all of the retinal layers in the choroid, with distinct changes in the deep retinal layer.

Keywords: ocular toxoplasmosis, retinochoroiditis, recurrent, optical coherence tomography angiography

Introduction

Ocular toxoplasmosis represents the leading cause of posterior uveitis worldwide,¹ with the highest incidence reported in Brazil was 20%.² In immunocompetent individuals, ocular toxoplasmosis is responsible for 30–50% of all cases of posterior uveitis.^{2,3} A study by La Distia Nora et al reported that ocular toxoplasmosis is the cause of 63% of all infectious uveitis.⁴ Individuals can be infected congenitally or acquired postnatally, even though recent studies have reported that acquired infection is more common.^{3,5,6} Typical features of congenital ocular toxoplasmosis predominantly affect the macula and its high tendency for recurrence increases the burden of this disease.^{3,5} Congenital infection tends to produce larger macular scars that are more likely to be bilateral, which may cause significant loss of vision.^{5,7} In spite of the presence of blood-retinal barriers, parasites are still capable of reaching the eye through several mechanisms. Once inside, it remains encysted lifelong within the retina, and recurrences of the disease cannot be completely avoided.⁸

Diagnosis of ocular toxoplasmosis is made based on typical clinical features, the focal necrotizing retinitis that is mostly found in the macula, and it has an overlying vitreous haze, with or without adjacent hyperpigmented retinochoroidal scar, that is called classic “headlight in the fog” appearance.^{3,6} Serologic titer helps to confirm exposure to the parasite but only has value in ruling out diagnosis if immunoglobulin titer is negative.⁹ Other examinations that can help to establish a diagnosis in atypical cases are Polymerase Chain Reaction (PCR) and Goldman-Witmer Coefficient (GWC).¹⁰ The new imaging modalities that are commonly used to visualize retinal and choroidal layers anatomy is OCT ie, spectral domain optical coherence tomography (SD-OCT) and the OCTA.^{10,11} The OCTA has some advantages:

the shorter acquisition time and that it is a non-invasive procedure, compared to the conventional fluorescein and indocyanine-green angiography (FA/ICGA) that requires an injectable dye which takes time to reach retinal vessels and may be associated with systemic adverse effects and even anaphylactic reactions.¹²

Optical coherence tomography angiography is the newest non-invasive imaging technique that utilizes motion contrast imaging for high-resolution volumetric blood flow data to produce angiographic images.⁷ Optical coherence tomography provides visualization of individual vascular plexus and determines which vascular layers are affected.¹³ OCTA may provide information about microvascular changes in ocular toxoplasmosis, which cannot be gathered in conventional OCT. Studies reporting analysis of retinal and choroidal vascular changes in ocular toxoplasmosis are limited. Previous studies compared OCTA findings in acute, recurrent, and inactive ocular toxoplasmosis,¹³ or demonstrated OCTA findings for treatment follow-up.⁷ We report OCTA findings in two cases of recurrent toxoplasmic retinochoroiditis with distinct nature of the infection.

Case Description

Case #1

A 19-years-old woman was admitted to the outpatient clinic with a complaint of floaters on both eyes that have been increasing in the last few weeks on the left eye. She also complained of blurred vision in both eyes for a few years, which was more severe in the right eye, but the left eye became blurrier after 3 weeks. The patient had the same symptoms about 4 years earlier and was given topical eye drops at a remote hospital, but no significant improvement was experienced by the patient. There was no history of family eye diseases. Further history revealed that the patient was born with normal spontaneous delivery and the toxoplasmosis infection was denied. The patient had no pets and used the water spring as a source of water for daily consumption and needs.

Ophthalmology examination revealed visual acuity (VA) of the right eye was 0.25 and the left eye was 0.63, both were unable to be corrected. The anterior segment examination in both eyes was unremarkable. The vitreous was clear in the right eye but 1+ vitreous cells were found in the left eye. The intraocular pressure (IOP) examination on the right eye was 15 mmHg and the left eye was 14 mmHg. Indirect ophthalmoscopy examination revealed a wagon-wheel retinochoroidal scar on the macula and a pale optic disc on the right eye, and on the left eye we found multiple retinochoroidal scars in the perifoveal area with perivascular sheathing and mild exudate noted at the outer margin of the previous retinochoroidal scar (Figure 1).

The SD-OCT of both eyes showed macular thinning, where the thickness of central subfield on the right eye was 85 μm and the left eye was 162 μm , but the average thickness was thicker on the left eye (273 μm) compared to the right eye

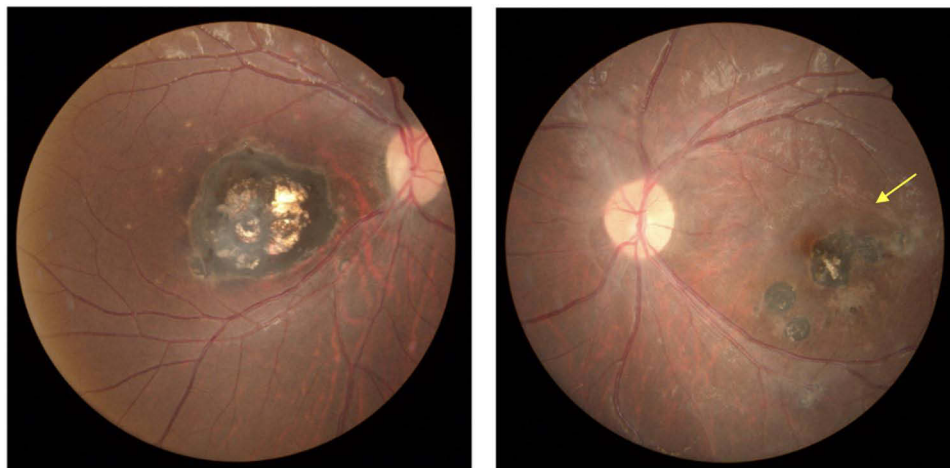


Figure 1 Color fundus photographs of the first case. (Left) Fundus photograph of the right eye indicated a wagon-wheel retinochoroidal scar in the macula, with no active lesions. (Right) Fundus photograph of the left eye showed multiple retinochoroidal scars in the parafoveal area, with retinal exudates and vascular sheathing noted at the temporal margin of the previous scar (yellow arrow).

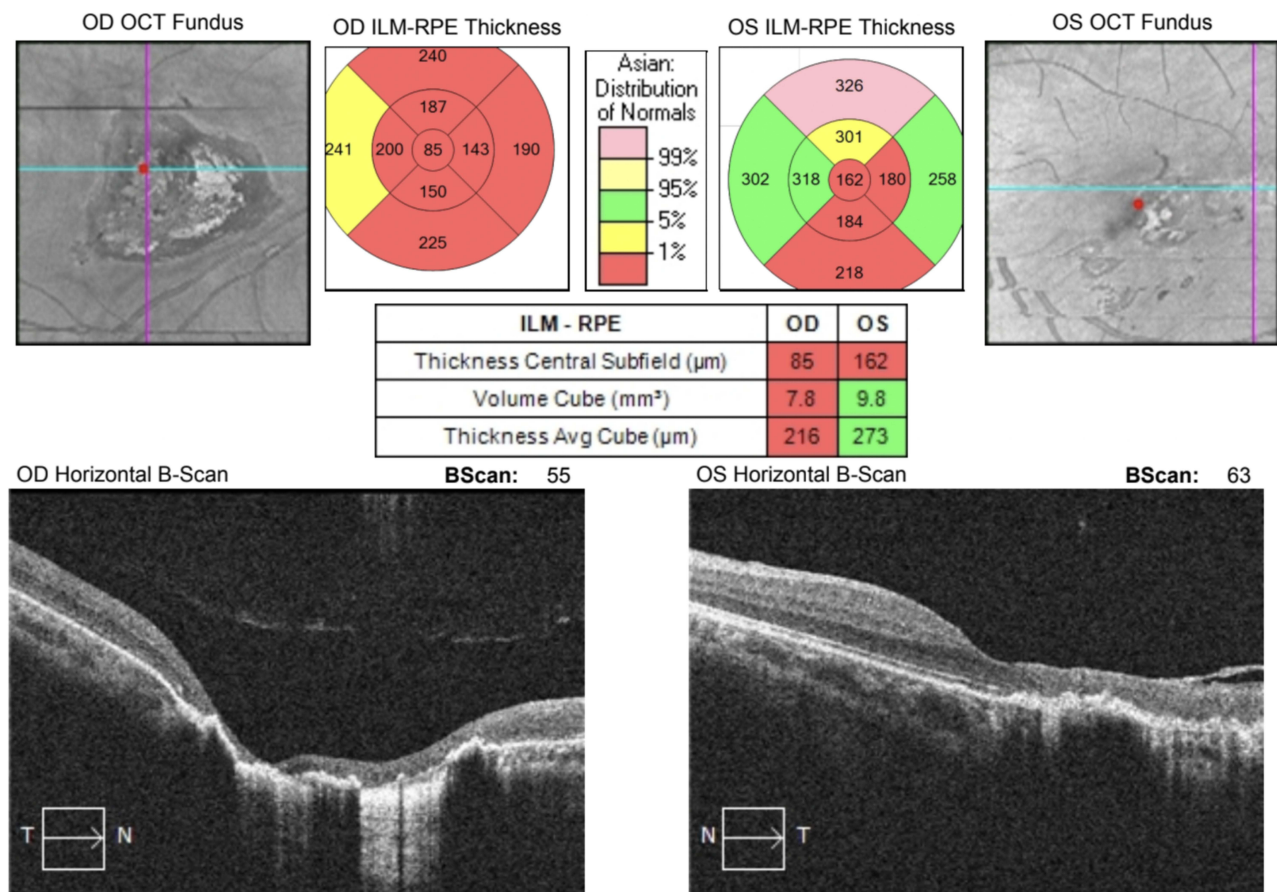


Figure 2 The OCT image of the first case. The examination revealed macular thinning in both eyes. The average thickness of the left eye (right) was thicker than the right eye (left). The SD-OCT reveals thinning of retinal layers and epiretinal membrane formation in the left eye.

(216 μm). Horizontal brightness scan (B-scan) of the left eye showed full thickness retinal thinning and epiretinal membrane formation (Figure 2).

The OCTA image of the left eye (Figure 3A–D) showed hypointense areas in the superficial and deep retinal layers, which revealed decrease in perfusion, and it was also found in the choriocapillaris layer, while choroidal layer only showed multiple dark spots. The horizontal section of retinal layers (Figure 3E) showed full thickness retinal thinning with disruption of the retinal pigment epithelium (RPE) with formation of epiretinal membrane. A quantitative analysis of the vessel density of superficial retinal capillary plexus was conducted in 6×6 mm area using Cirrus HD-OCT 5000 (Zeiss). The right-eye examination was focused on the center of the retinochoroidal scar and focused on the active lesion in the left eye. Using the Angioplex Metrix, the vessel density was 15.5 mm/mm^2 and 13.9 mm/mm^2 in the right and left eye, respectively.

Serological titers were also measured to confirm the exposure. Serum IgM anti-*Toxoplasma gondii* was negative, and IgG anti-*Toxoplasma gondii* was 635.2 IU/mL. The patient was diagnosed with inactive ocular toxoplasmosis in the right eye and recurrent toxoplasmic retinochoroiditis in the left eye. The patient was then treated with oral Cotrimoxazole (80 mg trimethoprim and 400 mg sulfamethoxazole) 2 tablets twice daily, followed by oral prednisone 30 mg daily with a tapered dose, which started on the third day after initiating oral antibiotics and is planned for regular follow-up.

Case #2

A 42-year-old woman was presented to our outpatient clinic because of blurred vision in right eye that worsened in the last 2 months. She also complained of intermittent redness and floaters in the right eye over the last 2 years. The patient

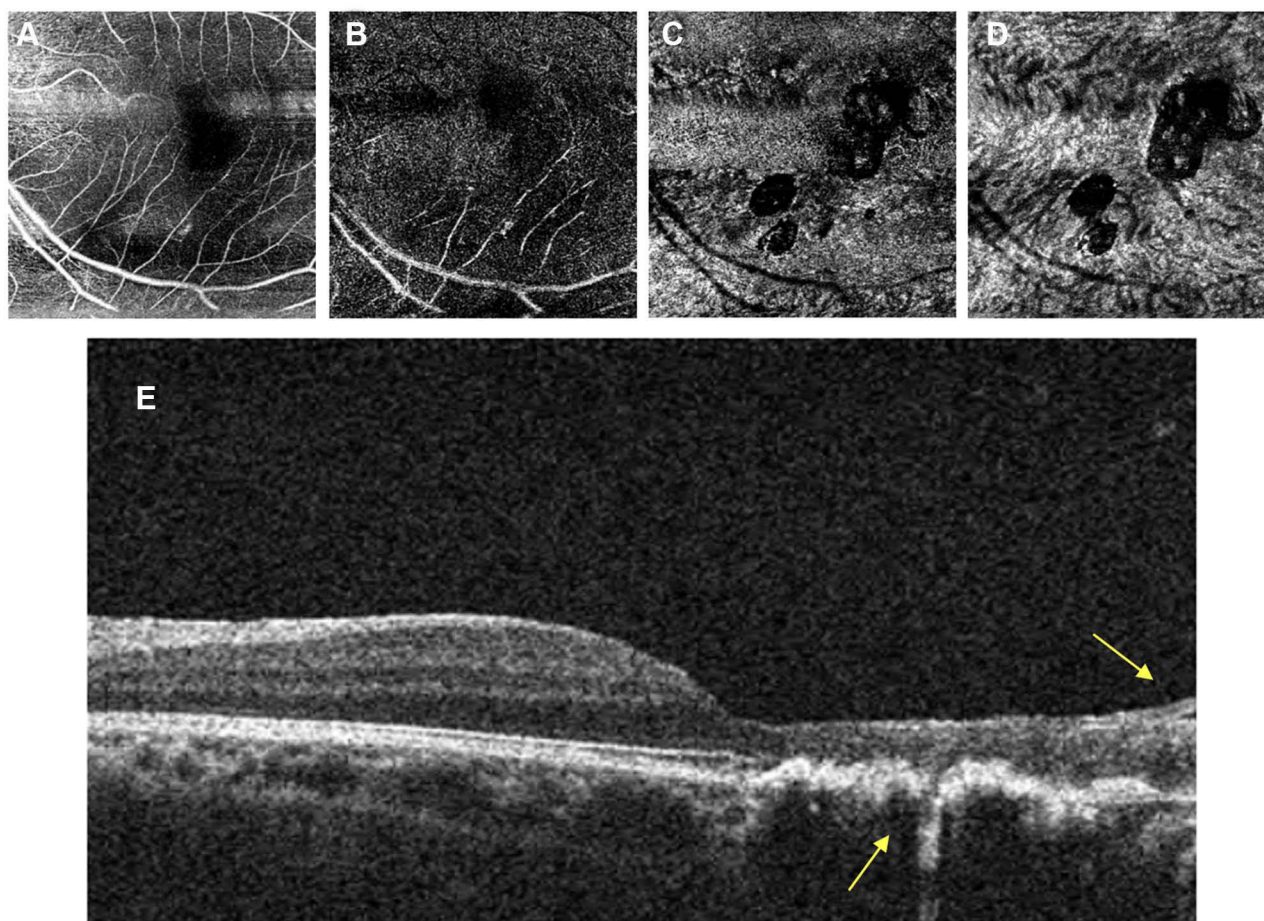


Figure 3 The left eye OCTA image of the first case. The analysis of the superficial retinal layer (**A**) and deep retinal layer (**B**) showed hypointense areas marked as dark areas, which revealed decreased perfusion. These findings are also noted in choriocapillaris (**C**), but the choroidal layer (**D**) only showed multiple dark spots due to the previous retinochoroidal scar. The horizontal section of retinal layer (**E**) showed full thickness retinal thinning with disruption of the RPE and epiretinal membrane formation (yellow arrow).

had no complaint in the left eye. There was no history of treatment. She had no family history of eye disease. She had cats as pets with no history of vaccination. They also had some goats as livestock not far from the living house.

Ophthalmology examination revealed the VA of the right eye was 0.1 and unable to be corrected and best corrected VA of the left eye was 1.0. The anterior segment examination of both eyes was unremarkable. There was 1+ vitreous cells in the right eye. Indirect ophthalmoscopy examination showed multiple retinochoroidal scars in the right eye, with retinal exudate at the outer margin of the previous scar (Figure 4). The examination of the left eye was normal. The IOP of the right and left eye was 17 mmHg and 14 mmHg, respectively. The SD-OCT examination (Figure 5) shows a marked decrease in central thickness in the right eye (96 μm) with the average thickness was 234 μm . There was also an obvious disorganization of the retinal structures in the active lesion (right eye) compared to the normal condition (left eye).

The OCTA in 6 \times 6 mm area using Cirrus HD-OCT 5000 by Zeiss examination revealed a lack of perfusion marked with hypointense area, which was less visible in superficial retinal layer and becomes more distinct in the deeper layer, as shown in Figure 6A–D. We also noted other pathological conditions caused by the presence of epiretinal membrane, retinal thinning, and choroidal shadowing (Figure 6E). Quantitative analysis by Angioplex Metrix in the active lesion area showed the vessel density was 13.6 mm/mm^2 , less dense compared to the fellow eye (16.8 mm/mm^2).

The serological titers were negative for IgM anti-*Toxoplasma gondii* and positive for IgG anti-*Toxoplasma gondii* (571.0 IU/mL). The patient was diagnosed with recurrent ocular toxoplasmosis in the right eye and treated with oral Cotrimoxazole (80 mg trimethoprim and 400 mg sulfamethoxazole) 2 tablets twice daily, followed by oral prednisone 40 mg daily in tapered dose.

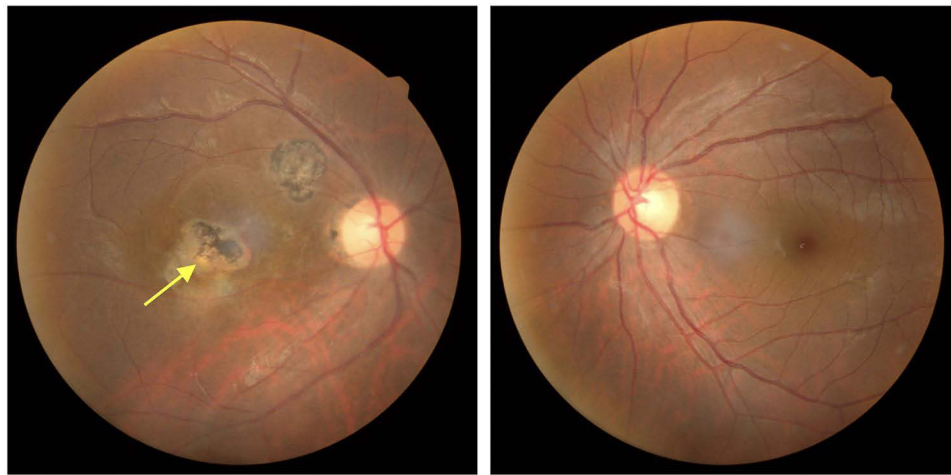


Figure 4 Color fundus Photograph of the second case. (Left) The posterior pole of the right eye showed multiple retinochoroidal scars in the parafoveal area and yellowish exudate adjacent to the previous hyperpigmented scar (yellow arrow) represented recurrent infection. (Right) The fundus of the left eye was unremarkable.

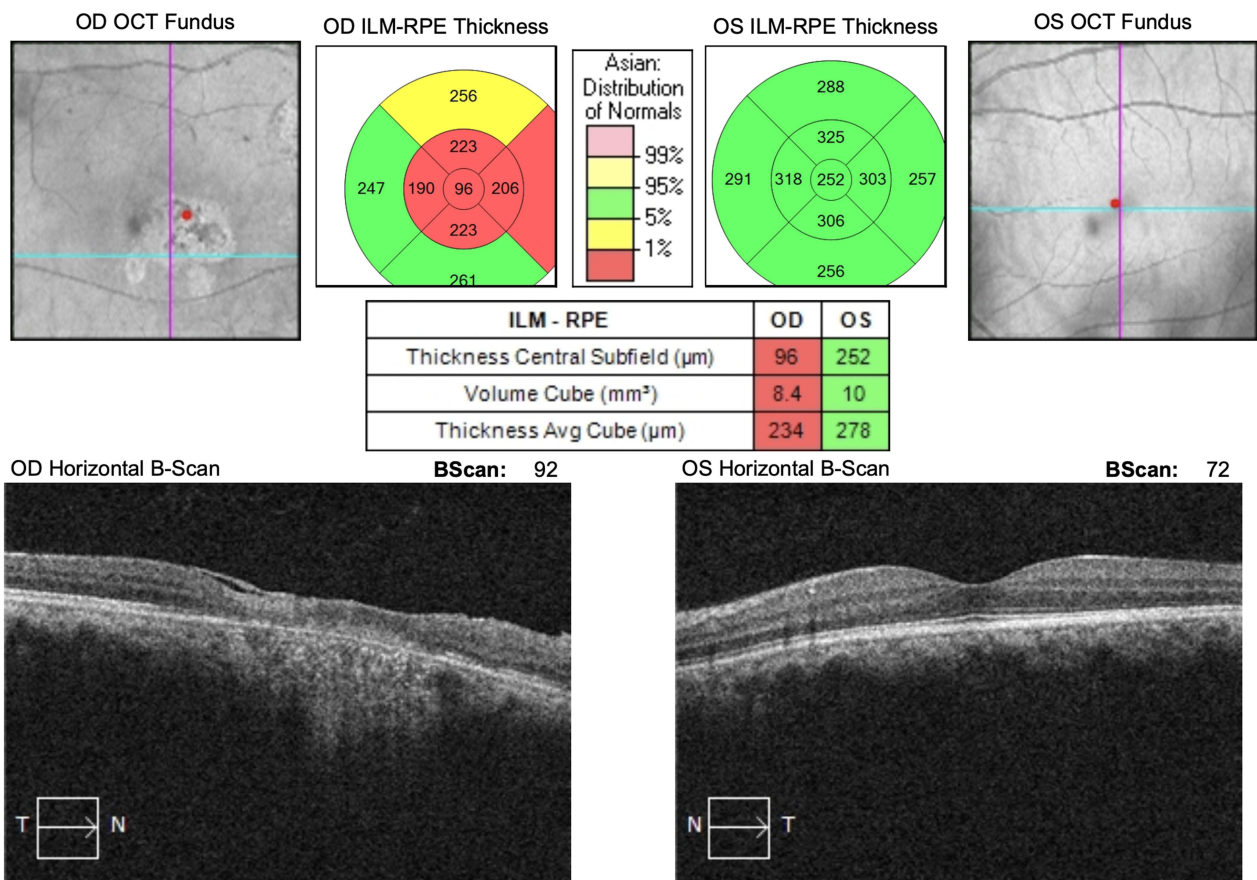


Figure 5 The OCT finding of the second case. (Left) The result revealed macular thinning in the right eye and epiretinal membrane formation, with choroidal shadowing. (Right) The left eye image was unremarkable.

The Discussion

The first case was presented with a large macular retinochoroidal scar in the right eye, which may indicate a congenital lesion, and multiple retinochoroidal scar in the left eye due to multiple reactivations. An active lesion. noted at the outer

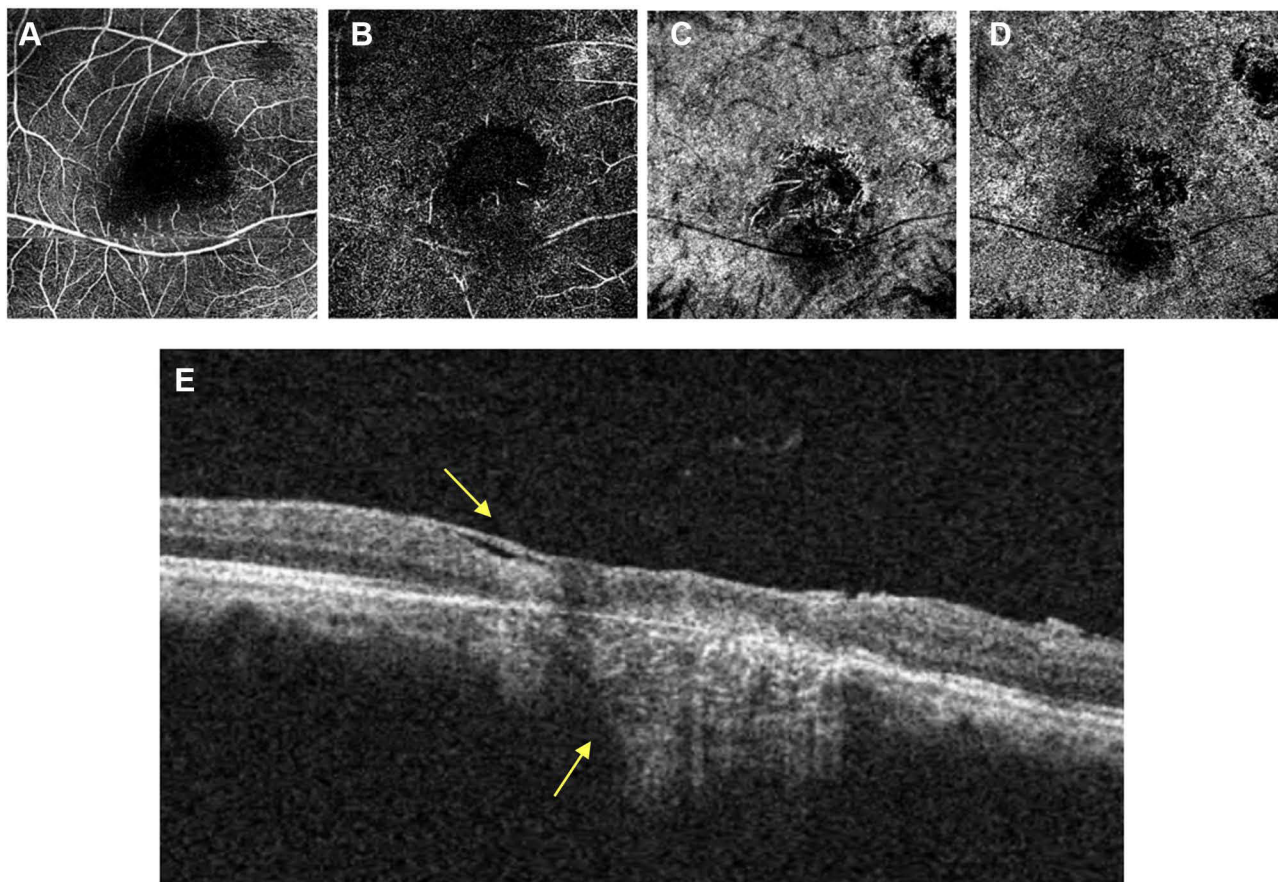


Figure 6 The OCTA image in the active lesion showed perfusion loss that marked with hypointense area. The lack of perfusion area related to the active lesion is shown in the superficial retinal layer (A) and more distinct in the deep retinal layer (B). It is also noted in the choroidal layer (C) and the choriocapillaris (D). The horizontal section of retinal layer (E) showed full thickness retinal thinning with choroidal shadowing and formation of epiretinal membrane (yellow arrow).

margin of the largest retinochoroidal scar in the left eye, manifested as mild exudate with perivascular sheathing and minimal overlying vitritis. The second case was most likely an acquired ocular toxoplasmosis, representing unilateral recurrent ocular toxoplasmosis in older patient, with two retinochoroidal scars and an active lesion noted at the inferotemporal margin of the previous retinochoroidal scar, accompanied by vascular sheathing and minimal vitritis. Both active lesions in these cases have similar clinical features. Identifying whether the origin of the ocular toxoplasmosis is pre- or postnatal is difficult. Postnatal acquired ocular toxoplasmosis is more common. A postnatal infection could be confirmed by exclusion of maternal infection.¹⁴

Retinal vasculitis is another common finding of ocular toxoplasmosis, in addition to typical focal necrotizing retinitis. The retinal vascular endothelium is more vulnerable to *Toxoplasma gondii* infection compared to other tissues in the body.¹⁵ As seen in this report, these two cases were presented with mild grade of retinitis and vitritis, accompanied by retinal vasculitis, at the outer margin of previous hyperpigmented scar. The involvement of a deeper retinal layer may explain a milder degree of vitritis.⁶ Both cases showed multiple retinochoroidal scars that indicated a recurrence process. Recurrence is an important feature of ocular toxoplasmosis. This term refers to the fact that the new focus of active retinochoroiditis develops, usually around the scar of the previous lesion. The hyperpigmented scar has been described to harbor cysts that remain dormant from previous infections until the cyst ruptures and releases the organisms into the surrounding retina, inducing new foci of retinitis.¹⁶ Thereby, with each relapse, the likelihood of successive visual disturbances is increased.³

The diagnosis of ocular toxoplasmosis relies most heavily on typical clinical findings on the retina; laboratory examination can support a presumptive clinical diagnosis in the case of positive *Toxoplasma gondii* serology, or rule it

out in the case of negative serology.^{6,14} In these cases, titers of IgM anti-*Toxoplasma gondii* were negative, however both showed positive IgG anti-*Toxoplasma gondii*. The positive result of IgG anti-*Toxoplasma gondii* showed a history of past infection, and the high titers of IgG anti-*Toxoplasma gondii* may be related to reactivation of infection.⁶

Conventional OCT findings in both cases were decreased retinal thickness and epiretinal membrane formation. These findings may relate to the area of reactivation that is adjacent to the scar of the previous lesion. Reactivated lesions give the features of increased retinal reflectivity near the retinal thinning due to atrophic scar. The OCT findings of active toxoplasmosis lesions include highly reflective intraretinal area corresponding to the retinitis area, thickening and detachment of the posterior hyaloid overlying the lesion, irregular hyperreflective formation, and shadowing of the underlying choroidal tissue, while the retinochoroidal scar shown decreased retinal thickness, focal choriocapillaris/choroidal relative hyperreflectivity, and complete posterior vitreous detachment. In congenital toxoplasmosis, structural changes in the macula consist of retinal thinning, RPE hyperreflectivity, excavation, intraretinal cysts, and fibrosis.¹⁷

The use of OCTA for the description of retinochoroidal toxoplasmic lesions has recently been introduced. It constitutes an interesting approach that may be helpful in providing useful information and potential biomarkers. OCTA is a useful imaging tool for evaluating retinochoroidal inflammatory diseases. The OCTA may describe the disease process in the retinal layers, starting from the superficial retinal plexus to the choroid. In ocular toxoplasmosis, OCTA can help to provide information to evaluate the presence of abnormal retinal vascularization.¹⁸ OCTA imaging of active lesions showed loss of retinal and choroidal vascular network in the area of inflammation.^{15,19} It gives more comprehensive information compared to conventional OCT, which is very beneficial to evaluate disease progression, treatment follow-up, and even to differentiate clinical findings from other causes of necrotizing retinitis.^{15,19} Resolution of lesion resulted in hyperpigmented retinochoroidal scar, which may present the features of 'satellite dark dots' in cases with multiple scars.¹⁹

Below we summarize recent studies reporting the OCTA findings in ocular toxoplasmosis (Table 1). The findings in each study vary, indicated that the ocular toxoplasmosis infection may affect any layer of retina.^{15,20–22}

The OCTA findings in our cases showed structural changes in all retinal layers and choroidal layers and showed that the lack of perfusion occurs more distinctly in the deep retinal layer. This condition correlated with a study by Greigert et al that more *Toxoplasma gondii* parasites are present in the inner retinal layer.³ Condition affecting all layers of the retina may be caused by the mobility of tachyzoites that move across the layers of the retina.^{3,5} The study conducted by Furtado et al and Rodriguez et al also mentioned that the tachyzoites were concentrated in the inner retina and in the nerve fiber layer, and others can also be found in the other retinal layers such as inner plexiform, inner nuclear, outer plexiform, and outer nuclear layers. This indicates that tachyzoites can actively move through the human retina. This is also possible through the facilitation of leukocytes, based on the theory of leukocyte transport route infection of ocular toxoplasmosis. It is shown that even though all dendritic cells (DCs) are able to transmigrate through the retinal endothelium, those infected by *T. gondii* display hypermotility and, therefore, have a better capacity to transmigrate compared to uninfected ones.^{23–25}

Table 1 Studies Presenting Results of OCTA Examination in Ocular Toxoplasmosis

Authors	Year	Type of Study	Number of Patients	The OCTA Findings
Türkcü et al ²⁰	2016	Case Series	2	- Vascularization patterns was observed in the outer retinal and choriocapillary layer consistent with choroidal neovascular membrane (CNVM).
Park et al ²¹	2019	Case Report	1	- Congested choroidal vasculature. - Fifteen weeks after treatment, choroidal vasculature are visible within the atrophic macular lesion.
Perez et al ¹⁵	2020	Case Report	1	An area of absent perfusion at superficial and deep retinal vascular complexes, including the choriocapillaris.
de Oliveira Dias et al ²²	2020	Case Series	15	- All patients showed no OCTA decorrelation signal, suggestive of reduced blood flow. - One patient presented with retinal neovascularization.

As studies regarding OCTA findings in ocular toxoplasmosis are very limited, this report provides information to understand pathophysiology of ocular toxoplasmosis, and highlights OCTA utilization in assessing ocular findings that could not be obtained by conventional OCT.

Conclusion

OCTA is a non-invasive tool that can help to investigate retinal lesions in recurrent infection of ocular toxoplasmosis. The findings in the cases presented can give us more information to understand about the pathology of the disease and the visual prognosis. Involvement of multiple layers, locations, and structures of the retina, and associated changes, may be caused by the multiple recurrences and the ability of the parasite activity to navigate across retinal layers.

Informed Consent for Publication

Written consent for publication of case details and accompanying images was obtained from the patients. Institutional approval to publish the case details has been obtained from Health Research Ethics Commission of Dr. Saiful Anwar General Hospital Malang number 400/155/K.3/102.7/2022.

Funding

This work was supported by The National Competitive Research Funding Year 2022 from The Ministry of Education, Culture, Research, and Technology, Indonesia, under The Postgraduate Program-Doctoral Dissertation Research (PPS-PDD) scheme.

Disclosure

The authors declare that they have no competing interests to disclose for this work.

References

1. Feliciano-Alfonso JE, Muñoz-Ortiz J, Marin-Noriega MA, et al. Safety and efficacy of different antibiotic regimens in patients with ocular toxoplasmosis: systematic review and meta-analysis. *Syst Rev*. 2021;10(1):1–4. doi:10.1186/s13643-021-01758-7
2. Grigg ME, Dubey JP, Nussenblatt RB. Ocular toxoplasmosis: lessons from Brazil. *Am J Ophthalmol*. 2015;159(6):999–1001. doi:10.1016/j.ajo.2015.04.005
3. Greigert V, Bittich-Fahmi F, Pfaff AW, Taylan Ozkan A. Pathophysiology of ocular toxoplasmosis: facts and open questions. *PLoS Negl Trop Dis*. 2020;14(12):e0008905. doi:10.1371/journal.pntd.0008905
4. La Distia Nora R, Sitompul R, Bakker M, et al. Tuberculosis and other causes of uveitis in Indonesia. *Eye*. 2018;32(3):546–554. doi:10.1038/eye.2017.231
5. Smith JR, Ashander LM, Arruda SL, et al. Pathogenesis of ocular toxoplasmosis. *Prog Retin Eye Res*. 2021;1(81):100882.
6. Kalogeropoulos D, Sakkas H, Mohammed B, et al. Ocular toxoplasmosis: a review of the current diagnostic and therapeutic approaches. *Int Ophthalmol*. 2021;9:1–27.
7. Vezzola D, Allegrini D, Borgia A, et al. Swept-source optical coherence tomography and optical coherence tomography angiography in acquired toxoplasmic chorioretinitis: a case report. *J Med Case Rep*. 2018;Dec;12(1):1–4.
8. Kalogeropoulos D, Kalogeropoulos C, Sakkas H, et al. Pathophysiological aspects of ocular toxoplasmosis: host-parasite interactions. *Ocul Immunol Inflamm*. 2022;30(3):560–569. doi:10.1080/09273948.2021.1922706
9. Papadia M, Aldigeri R, Herbort CP. The role of serology in active ocular toxoplasmosis. *Int Ophthalmol*. 2011;31(6):461–465. doi:10.1007/s10792-011-9507-z
10. Ozgonul C, Besirli CG. Recent developments in the diagnosis and treatment of ocular toxoplasmosis. *Ophthalmic Res*. 2017;57(1):1–2. doi:10.1159/000449169
11. Invernizzi A, Cozzi M, Staurenghi G. Optical coherence tomography and optical coherence tomography angiography in uveitis: a review. *Clin Experiment Ophthalmol*. 2019;47(3):357–371. doi:10.1111/ceo.13470
12. Koustenis A, Harris A, Gross J, Januleviciene I, Shah A, Siesky B. Optical coherence tomography angiography: an overview of the technology and an assessment of applications for clinical research. *Br J Ophthalmol*. 2017;101:16–20. doi:10.1136/bjophthalmol-2016-309389
13. Azar G, Favard C, Salah S, Brézin A, Vasseur V, Mauget-Faÿsse M. Optical coherence tomography angiography analysis of retinal and choroidal vascular networks during acute, relapsing, and quiescent stages of macular toxoplasma retinochoroiditis. *Biomed Res Int*. 2020;2020:1–8. doi:10.1155/2020/4903735
14. Lijeskić O, Štajner T, Srbljanović J, et al. Postnatal ocular toxoplasmosis in immunocompetent patients. *J Infect Dev Ctries*. 2021;15(10):1515–1522. doi:10.3855/jidc.14824
15. Perez AL, Lozada RA, Emanuelli A, Oliver AL. Optical coherence tomography angiography findings in macular toxoplasma retinochoroiditis: a case report. *Am J Ophthalmol Case Rep*. 2020;1(19):100764. doi:10.1016/j.ajoc.2020.100764
16. Gerges TK. Ocular toxoplasmosis: an update on diagnosis, multimodal imaging and therapy. In: *Infectious Eye Diseases: Recent Advances in Diagnosis and Treatment*. Books on Demand; 2021:81.

17. Onal S, Tugal-Tutkun I, Neri P, Herbort C. Optical coherence tomography imaging in uveitis. *Int Ophthalmol*. 2014;34(2):401–435. doi:10.1007/s10792-013-9822-7
18. Tranos P, Karasavvidou EM, Gkorou O, Pavesio C. Optical coherence tomography angiography in uveitis. *J Ophthalmic Inflamm Infect*. 2019;9(1):1–3. doi:10.1186/s12348-019-0190-y
19. Cunningham ET, Smit DP, Zierhut M. Imaging ocular toxoplasmosis. *Ocul Immunol Inflamm*. 2022;30(3):525–526. doi:10.1080/09273948.2022.2086395
20. Türkcü FM, Şahin A, Yüksel H, Şahin M, Karaalp Ü. OCTA imaging of choroidal neovascular membrane secondary to toxoplasma retinochoroiditis. *Ophthalmic Surg Lasers Imaging Retina*. 2017;48(6):509–511. doi:10.3928/23258160-20170601-11
21. Park JH, Lee SY, Lee EK. Morphological characteristics of ocular toxoplasmosis and its regression pattern on swept-source optical coherence tomography angiography: a case report. *BMC Ophthalmol*. 2019;19(1):1–6. doi:10.1186/s12886-019-1209-8
22. de Oliveira Dias JR, Campelo C, Novais EA, et al. New findings useful for clinical practice using swept-source optical coherence tomography angiography in the follow-up of active ocular toxoplasmosis. *Int J Retin Vitr*. 2020;6(1):1. doi:10.1186/s40942-020-00231-2
23. Furtado JM, Ashander LM, Mohs K, Chipps TJ, Appukuttan B, Smith JR. Toxoplasma gondii migration within and infection of human retina. *PLoS One*. 2013;8(2):e54358. doi:10.1371/journal.pone.0054358
24. Rodriguez Fernandez V, Casini G, Bruschi F. Ocular toxoplasmosis: mechanisms of retinal infection and experimental models. *Parasitologia*. 2021;1(2):50–60. doi:10.3390/parasitologia1020007
25. Drewry LL, Jones NG, Wang Q, Onken MD, Miller MJ, Sibley LD. The secreted kinase ROP17 promotes Toxoplasma gondii dissemination by hijacking monocyte tissue migration. *Nature Microbiol*. 2019;4(11):1951–1963. doi:10.1038/s41564-019-0504-8

International Medical Case Reports Journal

Dovepress

Publish your work in this journal

The International Medical Case Reports Journal is an international, peer-reviewed open-access journal publishing original case reports from all medical specialties. Previously unpublished medical posters are also accepted relating to any area of clinical or preclinical science. Submissions should not normally exceed 2,000 words or 4 published pages including figures, diagrams and references. The manuscript management system is completely online and includes a very quick and fair peer-review system, which is all easy to use. Visit <http://www.dovepress.com/testimonials.php> to read real quotes from published authors.

Submit your manuscript here: <https://www.dovepress.com/international-medical-case-reports-journal-journal>